




Contents lists available at ScienceDirect

Asian Pacific Journal of Tropical Biomedicine

journal homepage: www.elsevier.com/locate/apjtb

Document heading doi:10.1016/S2221-1691(11)60017-8 © 2011 by the Asian Pacific Journal of Tropical Biomedicine. All rights reserved.

Intraductal papilloma of the breast in association with preoncogenic gene of breast cancer

Tuenchit Khammapirad¹, Jenjeera Prueksadee^{2*}, Concepcion Diaz–Arrastia³, Shaleen K Botting³, Morton Leonard¹, Louisea Bonoan–Deomampo¹, Mahmoud A Eltorkey⁴

¹Department of Radiology, University of Texas Medical Branch at Galveston, Texas, United States 77555

²Department of Radiology, King Chulalongkorn Memorial Hospital, Faculty of Medicine, Chulalongkorn University, Bangkok 10330, Thailand

³Department of Obstetric–Gynecology, University of Texas Medical Branch at Galveston, Texas, United States 77555

⁴Department of Pathology University of Texas Medical Branch at Galveston, Texas, United States 77555

ARTICLE INFO

Article history:

Received 11 February 2011

Received in revised form 28 February 2011

Accepted 20 March 2011

Available online 1 April 2011

Keywords:

Human papilloma virus

Preoncogenic gene

Breast cancer

Mammography

Ultrasound

ABSTRACT

We reported a case of an African American woman who went to the hospital with palpable right breast lump with bloody nipple discharge at University of Texas Medical Branch at Galveston. The modalities of breast imagings included mammography and ultrasonography. The method used for viral identification was Linear Array HPV genotyping test. Intraductal papilloma revealed as high density tubular or rounded lobular masses with partially circumscribed, obscured margins and clustered punctate microcalcifications on mammograms. Ultrasound showed as intraductal masses with dilated ducts. The core biopsy demonstrated duct filled with papillary lesion and post excision revealed intraductal papilloma. HPV DNA types 16, 33, 58 and 71 were detected after use of Linear Array HPV genotyping test.

1. Introduction

Breast cancer is the most prevalent cancer among women in the United States and the second most common cause of cancer death in women (after lung cancer). In 2007, breast cancer is expected to cause 40 910 deaths (7% of cancer deaths; almost 2% of all deaths) in the US[1,2]. Many risk factors have been associated with the pathogenesis of this disease, including family history, viral infection, environmental pollutants, hormones and alcohol consumption[3–8]. There is a strong inherited familial risk in only 5% of breast cancer case[9] with two autosomal dominant genes, BCRC1 and BCRC2. The association between the Human Papillomavirus (HPV) and cervical cancer is well-known and well-documented[10]. More recently, HPV has been shown to be present in 11%–86% of breast carcinoma, the number varying depending on racial, epidemiological factors and experimental factors[11]. In this report, we presented a case of benign intraductal papilloma which had HPV type 16 that can be possible opportunity of breast cancer.

2. Case report

A 49– year old African American woman went to the hospital with palpable right breast lump with bloody nipple discharge. No family history of breast cancer was found. Physical examination showed retroareolar mass at 7 o'clock, measuring about 50 mm. She has been palpated her right breast mass since 1997, data record revealed subareolar mass with hard consistency and slightly mobile, size about larged bean. She was loss follow-up on that time.

Mammograms demonstrated slightly high density tubular and rounded lobular masses with partially circumscribed, obscured margins measuring 50 mm involving in right lower outer quadrant (Figure 1A, 1B). On magnification views (craniocaudal and mediolateral projections) presented greater than ten clustered punctate microcalcifications scatter at lower outer quadrant (Figure 2). Ultrasound showed numerous intraductal masses and dilated ducts with dimension subcentimeter at the site of masses on mammograms (Figure 3A, B). The core biopsy revealed duct filled with papillary lesions. She underwent excisional biopsy with bracket wire-localization of the affected area. The pathological report demonstrated benign intraductal papilloma with associated post obstructive changes, cystic secretory hyperplasia associated with calcification (Figure 4). HPV DNA types 16, 33, 58 and 71 were also detected (Figure 5). There was no malignancy indentified.

*Corresponding author: Jenjeera Prueksadee, MD, Department of Radiology, King Chulalongkorn Memorial Hospital, Faculty of Medicine, Chulalongkorn University, Bangkok 10330, Thailand.

E-mail: jenjeera@hotmail.com

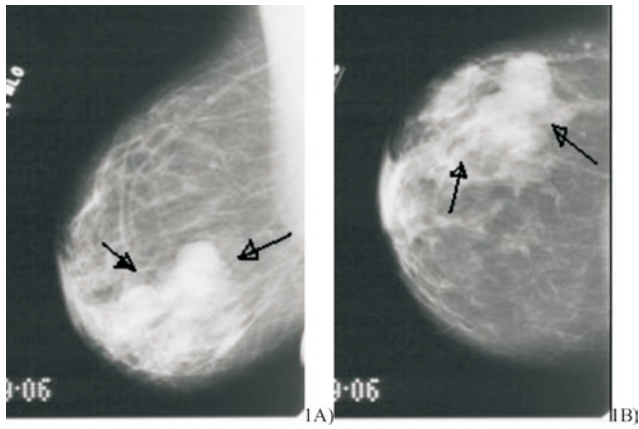


Figure 1. Mammograms of mediolateral (A) and craniocaudal (B). It showed a slightly high density tubular and rounded lobular masse with partially circumscribed, obscured margins, measuring 50 mm almost involving the entire lower outer quadrant of right breast.

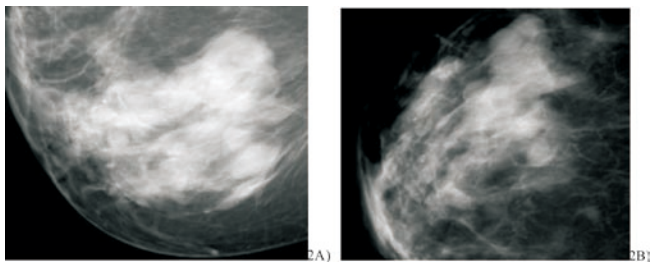


Figure 2. Right magnification views. Mediolateral (A) and craniocaudal (B) demonstrated multiple clusters of punctate microcalcifications at lower outer quadrant anterior and middle depth.

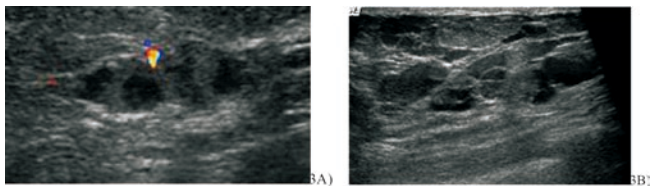


Figure 3. Ultrasonography revealed numerous intraductal lesions with dimation subcentimeter at the site of mammographic findings.

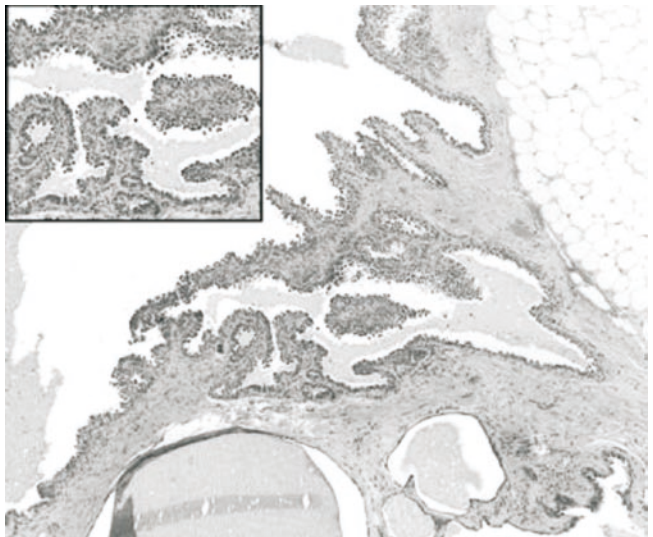


Figure 4. Photomicrograph of the intraductal papillary lesion showing multiple fibrovascular core and epithelial proliferation.

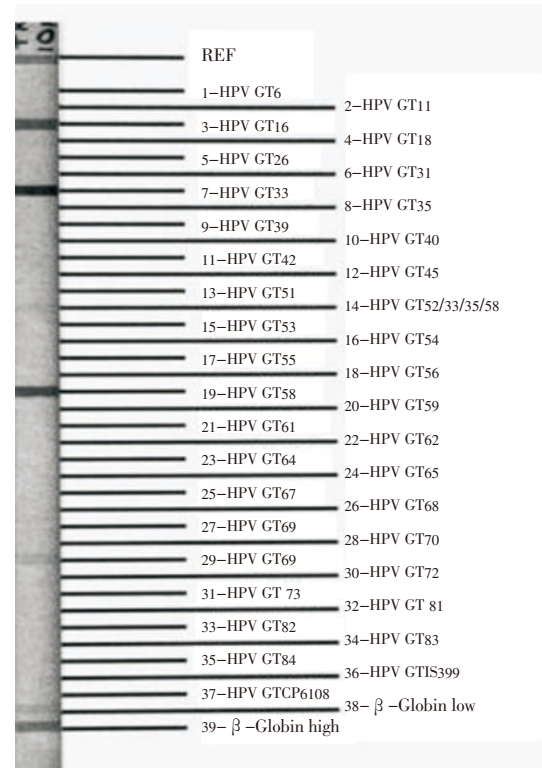


Figure 5. HPV genotyping was positive for genotypes 16, 33, 58, and 71.

3. Discussion

Human papilloma virus infections vary in United States of America, with one reviewed finding reported values anywhere from 14% to 90%[12]. It has been shown that HPV types 16 and 18 can immortalize normal breast epithelium[13]. This raised the possibility that HPV may be etiologically related to some cases of breast cancer. There is some evidence that breast carcinogenesis may in some cases be initiated or promoted by a viral agent. The relationship between virus and mammary tumors is known from induction of mammary cancer in mice with the mouse mammary tumor virus (MMTV)[14,15]. The intermediate DNA of MMTV can integrate into the genomes and perturb the activity of a proto-oncogene, inducing accelerated cell growth[14]. Particles similar to this mouse virus were also observed in human breast cancer tissue, indicating a possible viral etiology in human breast cancer[16]. More recently, a number of researchers have detected HPV DNA in breast carcinoma. A majority of these studies used paraffin embedded tissue samples of invasive carcinoma, benign lesions and normal tissue, and detected and typed the HPV DNA by PCR-based methods. These studies cover geographically and racially diverse populations[11,17-27]. The breast carcinoma cases that were found to be associated with HPV varied from 11% in the Japanese study[19] to 86% in the German study[20]. This correlation was relatively high up to 64% (seven out of 11) when the breast cancer patient had a known history of cervical carcinoma[28]. Six patients had the same HPV type (HPV-16) in cervical cancer, and in the corresponding breast cancer and/or axillary lymph node tissue[28]. HPV DNA might be transported from the original site of infection to breast tissue by the bloodstream, and may possibly be involved in the carcinogenesis of breast neoplasia in some patients[28]. The author believed of the direct contact of HPV to the nipple since there were many studies also detected the other

types of HPV DNA which not commonly seen from cervix. De Villiers *et al* and Yu *et al* also reported positive for HPV DNA in benign breast tumor^[19–20], but other reports did not. These maybe due to most published studies therefore used methods restricted to the detection of specific, single, or combinations or groups of HPV types. Only in the study of de Villiers *et al* was primer combinations used, which allowed the detection of a wide range of HPV types^[20].

We report a case of benign intraductal papilloma of the breast. HPV types 16, 33, 58 and 71 were identified by Linear Array HPV genotyping test, which can detect up to 37 different HPV genotypes. The HPV type 16 was the same as other reported of breast carcinoma^[19,21,22,24–25], indicating possible etiology or preoncogenic gene of breast cancer by this virus^[14,16]. The HPV 33 was detected in this case found in benign breast tumor in Yu *et al*^[19]. The HPV 58 and 71 had never reported in other studies also detected in our case. This case report also emphasized detection of papilloma virus infections in tissues largely depends on the method used^[20].

The HPV types 6, 11, 16, 18, 31, 33, 35, 39, 52 and 58 are frequently associated with genital lesions and are therefore most often targeted for HPV detection. The use of type-specific primers may increase the number of positive samples but is biased with regard to the HPV types involved, because other HPV types present cannot be detected^[20].

In conclusion, human papilloma viruses related to breast cancer are controversial. Although many studies supported the possibility of HPV associated with breast carcinoma. The presence of preoncogenic gene in our case probably illustrates the potential to have subsequent breast cancer and the patient should have been follow-up regularly after excision. Further larger epidemiologic studies are still indicated with the used of detected methods which have greater sensitivity and specificity.

Conflict of interest statement

We declare that we have no conflict of interest.

References

- [1] American Cancer Society. *Cancer facts & figures 2007*. Atlanta: American Cancer Society; 2007.
- [2] American Cancer Society. *What are the key statistics for breast cancer?* Atlanta: American Cancer Society; 2006.
- [3] Longnecker MP, Bernstein L, Paganini-Hill A, Enger SM, Ross RK. Risk factors for in situ breast cancer. *Cancer Epidemiol Biomarkers Prev* 1996; **5**: 961–965.
- [4] Trentham-Dietz A, Newcomb PA, Storer BE, Remington PL. Risk factors for carcinoma in situ of the breast. *Cancer Epidemiol Biomarkers Prev* 2000; **9**: 697–703.
- [5] Band PR, Nhu DL, Fang R, Deschamps M. Carcinogenic and endocrine disrupting effects of cigarette smoke and risk of breast cancer. *Lancet* 2002; **360**: 1044–1049.
- [6] Brinton L, Lacey J Jr, Devesa SS. Epidemiology of breast cancer. In: Donegan WL, Spratt JS, editors. *Cancer of the Breast*. 5th ed. London: Saunders Elsevier Science; 2002, p.111–132.
- [7] Hamajima N, Hirose K, Tajima K, Rohan T, Calle EE, Health CW Jr, et al. Alcohol, tobacco and breast cancer –collaborative reanalysis of individual data from 53 epidemiological studies, including 58,515 women with breast cancer and 96,057 women without the disease. *Br J Cancer* 2002; **87**: 1234–1245.
- [8] Hemminki K, Granström C, Czene K. Attributable risks for familial breast cancer by coband status and morphology: a nationwide epidemiologic study from Sweden. *Int J Cancer* 2002; **100**: 214–219.
- [9] Malone KE, Daling JR, Thompson JD, Obrien CA, Francisco LV, Ostrander EA. BRCA1 mutations and breast cancer in the general population: analyses in women before age 35 years and in women before age 45 years with first-degree family history. *JAMA* 1998; **279** (12): 922–929.
- [10] Hausen H. Papillomaviruses and cancer: from basic studies to clinical application. *Nat Rev Cancer* 2002; **2**: 342–350.
- [11] Lindel K, Forster A, Altermatt HJ, Greiner R, Gruber G. Breast cancer and human papillomavirus (HPV) infection: no evidence of a viral etiology in a group of Swiss women. *The breast* 2007; **16**(2): 172–177.
- [12] Revzina NV, DiClemente RJ. Prevalence and incidence of human papillomavirus infection in women in the USA: a systematic review. *Int J STD AIDS* 2005; **16**(8): 528–537.
- [13] Band V, Zajchowski D, Kulesa V, Sager R. Human papilloma virus DNAs immortalize normal human mammary epithelial cells and reduce their growth factor requirements. *Proc Natl Acad Sci USA* 1990; **87**: 463–467.
- [14] Dickson C. Role of the int–genes in murine mammary tumor development and implications for human breast cancer. *Int J Cancer Suppl* 1990; **5**: 51–54.
- [15] Medina D. Preneoplastic lesions in murine mammary cancer. *Cancer Res* 1976; **36**: 2589–2895.
- [16] Vokaer A. Viruses and mammary carcinogenesis. *J Gynecol Obstet Biol Reprod* 1975; **4**(Suppl 2): 199–205.
- [17] Bratthauer GL, Tavassoli FA, O’Leary TJ. Etiology of breast carcinoma: no apparent role for papillomavirus types 6/11/16/18. *Pathol Res Pract* 1992; **3**: 384–386.
- [18] Wrede D, Luqmani YA, Coombes RC, Vousden KH. Absence of HPV 16 and 18 DNA in breast cancer. *Br J Cancer* 1992; **6**: 891–894.
- [19] Yu Y, Morimoto T, Sasa M, Okasaki K, Harada Y, Fujiwara V, et al. HPV33 DNA in premalignant and malignant breast lesions in Chinese and Japanese populations. *Anticancer Res* 1999; **19**(6B): 5057–5061.
- [20] De Villiers EM, Sandstrom RE, zur Hausen H, Buck CE. Presence of papillomavirus sequences in condylomatous lesions of the mamillae and in invasive carcinoma of the breast. *Breast Cancer Res* 2005; **7**(1): R1–R11.
- [21] Di Lonardo A, Venuti A, Marcante ML. Human papillomavirus in breast cancer. *Breast Cancer Res Treat* 1992; **21**(2): 95–100.
- [22] Hennig EM, Suo Z, Thoresen S, Holm R, Kvinnsland S, Nesland JM. Human papillomavirus 16 in breast cancer of women treated for high grade cervical intraepithelial neoplasia (CIN III). *Breast Cancer Res Treat* 1999; **52**(2): 121–135.
- [23] Czerwenka K, Heuss F, Hosmann JW, Manavi M, Lu Y, Jelincic D, et al. Human papilloma virus DNA: a factor in the pathogenesis of mammary Paget’s disease? *Breast Cancer Res Treat* 1996; **41**(1): 517.
- [24] Damin AP, Karam R, Zettler CG, Caleffi M, Alexandre CO. Evidence for an association of human papillomavirus and breast carcinomas. *Breast Cancer Res Treat* 2004; **84**(2): 131–137.
- [25] Liu Y, Klimberg VS, Andrews NR, Hicks CR, Peng H, Chiriva – Internati M, et al. Human papillomavirus DNA is present in a subset of unselected breast cancers. *J Hum Virol* 2001; **4**(6): 329–334.
- [26] Tsai JH, Tsai CH, Cheng MH, Lin SJ, Xu FL, Yang CC. Association of viral factors with non-familial breast cancer in Taiwan by comparison with non-cancerous, fibroadenoma, and thyroid tumor tissues. *J Med Virol* 2005; **75**(2): 276–281.
- [27] Kan CY, Iacopetta BJ, Lawson JS, Whitaker NJ. Identification of human papillomavirus DNA gene sequences in human breast cancer. *Br J Cancer* 2005; **93**(8): 946–948.
- [28] Widschwendter A, Brunhuber T, Wiedemair A, Mueller-Holzner E, Marth C. Detection of human papillomavirus DNA in breast cancer of patients with cervical cancer history. *J clinical virology* 2004; **31**(4): 292–297.