


Asian Pacific Journal of Tropical Biomedicine

journal homepage: www.apjtb.com



Document heading

doi:10.12980/APJTB.4.2014D126

© 2013 by the Asian Pacific Journal of Tropical Biomedicine. All rights reserved.

A rare case of Weil's disease with alveolar haemorrhage

Abhiram Chakrabarti¹, Manab Nandy^{2*}, Dipankar Pal³, Sudesna Mallik³¹Department of Radiodiagnosis, Calcutta School of Tropical Medicine, Kolkata, India²Department of Pharmacology, Calcutta National Medical College, Kolkata, India³Department of Tropical Medicine, Calcutta School of Tropical Medicine, Kolkata, India

PEER REVIEW

Peer reviewer

Prof. Bibhuti Saha, DTM&H, MD (Tropical Medicine). Department of Tropical Medicine, Calcutta School of Tropical Medicine, West Bengal, India. Tel: 9831296071
E-mail: s_bibhuti@hotmail.com

Comments

This case report highlights the importance of leptospirosis in a patient presenting with fever and multiorgan involvement. Pulmonary hemorrhage is an important document which should be brought to the notice of the clinicians working in the tropics. Details on page S68

ABSTRACT

Leptospirosis, a disease of protean manifestations occurs sporadically throughout the year with a peak seasonal incidence during the rainy season mimicking other febrile viral illness. In the rare case, the disease leads to renal and hepatic involvement with hemorrhage which may be associated with multisystem organ dysfunction in form of pulmonary, cardiac and central nervous system, when it is known as Weil's disease. Rarely haemorrhagic manifestations are associated. Early diagnosis is important as sometimes the disease may be life threatening. Proper antibiotics results in dramatic improvement. We hereby presented a case that had clinical features of Weil's disease with cough, dyspnoea and haemoptysis. Leptospirosis was detected on ELISA testing. Patient was cured rapidly with antibiotics.

KEYWORDS

Leptospirosis, Weil's disease, Alveolar haemorrhage

1. Introduction

Weil's disease is a severe form of leptospirosis, usually caused by *Leptospira interrogans* serotype icterohaemorrhagiae and occasionally other serotypes. Leptospirosis, a zoonotic disease, is prevalent in tropical countries with rainfall, rat, rice field popularly known as 3Rs[1]. The organism infects a variety of animals, especially rodents and animals associated with farming. Humans represent only incidental infection usually through work-related contact through

skin or mucous membranes, typically after exposure to water or soil contaminated with urine from an infected animal or via drinking of or bathing in contaminated water[2]. The main occupational groups at risk are farm workers, field agricultural workers, plumbers, sewer workers, sanitation workers and military troops[3]. Leptospirosis results in an acute febrile illness that cannot be distinguished from other viral illnesses, as symptoms commonly seen are fever, headache, vomiting and nausea. In rare occasions, multisystem organ involvement leads to Weil's disease which may

*Corresponding author: Dr. Manab Nandy, 95B, Bidhannagar Road, HUDCO Housing Estate, Block 18, Flat 234Kolkata 700 054, West Bengal, India.
Tel: 09830835743
E-mail: manabn@gmail.com

Article history:

Received 12 Jan 2014

Received in revised form 17 Jan, 2nd revised form 20 Jan, 3rd revised form 27 Jan 2014

Accepted 20 Feb 2014

Available online 28 Mar 2014

be serious in nature, especially where haemorrhage from different organs are associated^[4]. Weil's disease is listed as a "rare disease" by the Office of Rare Diseases (ORD) of the National Institutes of Health (NIH) of America^[5].

2. Case report

A 21-year-old non-alcoholic, non-smoker, non-*i.v.* drug user, healthy sanitation worker with no prior comorbidity developed fever with chill and rigor. Fever was high grade, continuous and relieved partially by taking anti-pyretic. Fever was associated with cough and streaky haemoptysis. Initially, he was treated with oral antibiotic ofloxacin by local practitioners as an outpatient basis. Meanwhile, his fever was continued and dyspnea increased. He also developed icterus and decreased volume of urine.

He got admitted in Calcutta School of Tropical Medicine Hospital, where he was thoroughly investigated. Routine blood picture showed neutrophilic leucocytosis 17 400/cu mm, and thrombocytopenia 40 000/cu mm with high serum creatinine 6.2 mg/dL. Routine urine examination showed pus cells 4–5/hpf, red blood cell 3–4/hpf. Chest X-ray revealed bilateral non-homogenous opacities in both lower zone and right mid zone (Figure 1). Tests for malaria, dengue and chickungunya were negative.

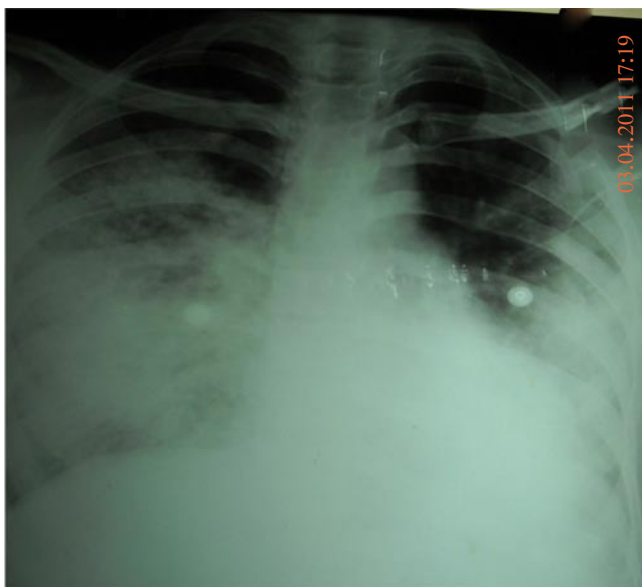


Figure 1. Chest X-ray showing bilateral non-homogenous opacities.

Symptomatic treatment started with oxygen

inhalation, nebulisation of bronchodilators, intravenous fluids. Sputum for acid-fast bacilli and test for HIV were negative. Without getting the proper diagnosis, further investigation was done.

Repeat complete haemogram revealed Hb–9.8 g%, with similar above picture of neutrophilic leucocytosis (16 200/ cu mm) and thrombocytopenia (90 000/cu mm). No abnormal cells were detected. Liver enzyme alanine transaminase (ALT) was elevated (200 IU), his serum bilirubin was 2.2 mg/dL. His abdominal sonography was normal. The serum calcium level was at 7.4 mg/dL and serum sodium, potassium and chloride levels were at 139, 4, and 111 mEq/L respectively. His lipid profile was normal. A 24-hour urine analysis revealed 1+ proteinuria with a volume of 1 500 mL. The electrocardiogram and 2-D echo were within normal limits. Arterial blood gases revealed a pH of 7.36, pCO₂ of 28.3 mmHg and pO₂ of 87.2 mmHg. HRCT thorax showed alveolar opacities in bilateral lower zone and right mid zone with few areas of bronchial dilatation suggestive of alveolar haemorrhage (Figure 2). Involvement of multisystem with no conclusion led to a diagnostic dilemma.

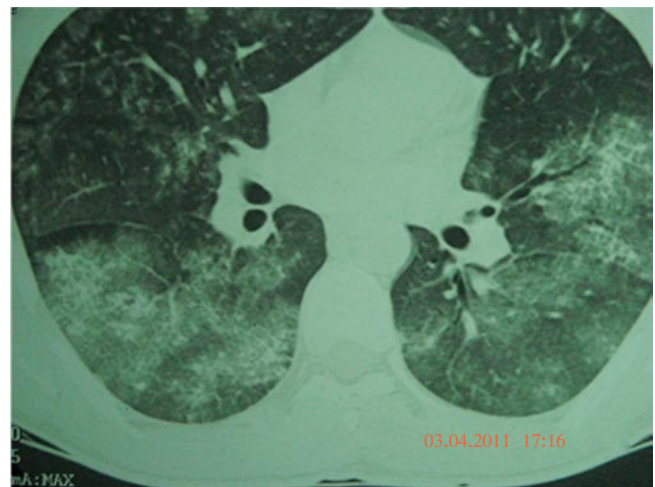


Figure 2. HRCT thorax showing alveolar opacities.

Thorough history was taken again revealing that patient was residing in Dumdum, an area near Kolkata, West Bengal, India, having poor sewerage drainage. A few weeks ago, the area was flooded after heavy rain. The idea of Weil's disease came into differential diagnosis. Then serum IgM leptospira was done, result was 1.822 optical density units (cut-off: 1 OD unit).

Intravenous piperacillin-tazobactam started immediately^[6]. Within 72 h, patient became afebrile,

hemoptysis stopped, dyspnea disappeared, and bilirubin came down to normal range (0.9 mg/dL). Patient discharged after 7 d with all normal parameters. One week after discharge, he attended out patient department with absolutely unremarkable features.

3. Discussion

Leptospirosis is a disease with varied clinical manifestations, the incubation period being 2 to 26 d. There are two distinct phases of leptospiral infection in the body. First, septicemia, and second, the immune phase. The septicemic phase is a result of vascular injury with features of fever and body ache[7]. The immune phase is due to the immune complexes deposition leading to endothelial cell damage affecting organs such as kidneys, liver, heart, lungs and meninges[8].

Weil's disease is the severe form of leptospirosis. Patients can present with high fever (>40 °C), significant jaundice, renal failure, hepatic necrosis, pulmonary involvement, cardiovascular collapse, neurologic changes and hemorrhagic diathesis, with a variable clinical course. A particularly serious type of lung involvement called severe pulmonary hemorrhagic syndrome is considered to be a major cause of death in patients with Weil's disease in developing countries, with profuse lung hemorrhage dominating the clinical picture[9]. Hepatic dysfunction is usually mild and reversible. Liver dysfunction in severe leptospirosis can be seen as conjugated serum bilirubin levels accompanied by modest elevations in transaminases, which rarely exceed 200 IU/L[10]. Overall, Weil's syndrome has a mortality rate of 5% to 10%. Important causes of death include renal failure, cardiopulmonary failure and widespread hemorrhage[11]. Icteric leptospirosis should be differentiated from other viral hepatitis with fulminant hepatitis such as hepatitis A and E. The important differentiating feature is the presence of renal failure very early and thrombocytopenia. Viral hepatitis fever usually disappears on appearance of jaundice[12].

Meticulous history taking, profession and habitat of the patient and multisystem organ involvement lead to high suspicion which correlates with the appearance

of IgM antibodies of *Leptospira* in the serum. Following the administration of antibiotics the patient improved dramatically within 4 to 5 d[13].

In conclusion, leptospirosis has recently come to international attention as a globally important reemerging infectious disease in not only developing countries but industrialized nations. In July 2007, a suspected leptospirosis outbreak was recognized among strawberry harvesters in Germany and was found to be the largest leptospirosis epidemic to occur in Germany since the 1960s[14]. Leptospirosis has also been documented as a militarily relevant infectious disease during times of troop deployment[15]. The implications of this case are noteworthy as recognition of fulminant leptospirosis is especially important because antimicrobial agents can reduce its severity and duration as well as lead to a favorable outcome of this potentially lethal condition. A high index of suspicion would be necessary especially in the monsoons.

Conflict of interest statement

We declare that we have no conflict of interest.

Acknowledgements

The authors are grateful to Prof. Bibhuti Saha, Head of the Department of Tropical Medicine, Calcutta School of Tropical Medicine for his encouragement and help.

Comments

Background

Weil's disease is a severe form of leptospirosis, usually caused by *Leptospira interrogans* serotype icterohaemorrhagiae and occasionally other serotypes. Leptospirosis, a zoonotic disease is prevalent in tropical countries with rainfall, rat, rice field popularly known as 3Rs1. The organism infects a variety of animals, especially rodents and animals associated with farming.

Research frontiers

This paper presented a case that had clinical

features of Weil's disease with cough, dyspnoea and haemoptysis. Documentation of alveolar hemorrhage in this patient of leptospirosis is very important information provided by the authors.

Related reports

Authors have highlighted the importance of leptospirosis by citing various articles (Suputtamongkol *et al.*, 2004; Shah, 2009). They have also stressed on having a high index of suspicion for patients presenting with this constellation of signs and symptoms during the monsoon. However, they could have cited reference for increasing reports of pulmonary hemorrhage in leptospirosis from various tropical countries.

Innovations & breakthroughs

The innovation of this study is the occurrence of alveolar hemorrhage as a component of multisystem involvement of leptospirosis.

Applications

Clinicians studying this case report will be reminded to suspect leptospirosis in appropriate clinical settings and manage accordingly.

Peer review

This case report highlights the importance of leptospirosis in a patient presenting with fever and multiorgan involvement. Pulmonary hemorrhage is an important document which should be brought to the notice of the clinicians working in the tropics.

References

- [1] The Leptospirosis Information Center. The history of leptospirosis and Weil's disease. [Online] Available from: <http://www.leptospirosis.org/topic.php?t=36> [Accessed on 11th February, 2012].
- [2] Medscape. Hickey PW. Pediatric leptospirosis. [Online] Available from: <http://emedicine.medscape.com/article/965698-overview> [Accessed on 4th March, 2012]
- [3] Levett PN, Haake DA. *Leptospira* species (leptospirosis). In: Mandell GL, Bennett JE, Dolin R, editors. *Principles and practice of infectious diseases*. Philadelphia: Churchill Livingstone Elsevier; 2010, p. 3059–3065.
- [4] Maroun E, Kushawaha A, Charabaty E, Mobarakai N, El-Sayegh S. Fulminant leptospirosis (Weil's disease) in an urban setting as an overlooked cause of multiorgan failure: a case report. *J Med Case Rep* 2011; **5**: 7.
- [5] Bracho G, Varela E, Fernández R, Ordaz B, Marzoa N, Menéndez J, et al. Large-scale application of highly-diluted bacteria for leptospirosis epidemic control. *Homeopathy* 2010; **99**(3): 156–166.
- [6] Suputtamongkol Y, Niwattayakul K, Suttinont C, Losuwanaluk K, Limpaboon R, Chierakul W, et al. An open, randomized, controlled trial of penicillin, doxycycline, and cefotaxime for patients with severe leptospirosis. *Clin Infect Dis* 2004; **39**(10): 1417–1424.
- [7] Gaynor K, Katz AR, Park SY, Nakata M, Clark TA, Effler PV. Leptospirosis on Oahu: an outbreak associated with flooding of a university campus. *Am J Trop Med Hyg* 2007; **76**: 882–885.
- [8] Shah I. Non oliguric renal failure—a presentation of leptospirosis. *Ann Trop Med Parasitol* 2009; **103**: 53–56.
- [9] Vijayachari P, Sehgal SC, Goris MG, Terpstra WJ, Hartskeerl RA. *Leptospira interrogans* serovar Valbuzzi: a cause of severe pulmonary haemorrhages in the Andaman Islands. *J Med Microbiol* 2003; **52**: 913–918.
- [10] Shah I. Leptospirosis. *Pediatr Infect Dis* 2012; **4**(1): 4–8.
- [11] Palaniappan RV, Ramanujam S, Chang YF. Leptospirosis: pathogenesis, immunity and diagnosis. *Curr Opin Infect Dis* 2007; **20**: 284–292.
- [12] Dursun B, Bostan F, Artac M, Varan HI, Suleymanlar G. Severe pulmonary haemorrhage accompanying hepatorenal failure in fulminant leptospirosis. *Int J Clin Pract* 2007; **61**(1): 164–167.
- [13] Costa E, Lopes AA, Sacramento E, Costa YA, Matos ED, Lopes MB, et al. Penicillin at the late stage of leptospirosis: a randomized controlled trial. *Rev Inst Med Trop Sao Paulo* 2003; **45**: 141–145.
- [14] Desai S, van Treeck U, Lierz M, Espelage W, Zota L, Sarbu A, et al. Resurgence of field fever in a temperate country: an epidemic of leptospirosis among seasonal strawberry harvesters in Germany in 2007. *Clin Infect Dis* 2009; **48**(6): 691–697.
- [15] Murray CK, Horvath LL. An approach to prevention of infectious diseases during military deployments. *Clin Infect Dis* 2007; **44**(3): 424–430.