

TANDEM COMPRESSION OF MEDULLA SPINALIS AND CAUDA EQUINA

Zhelyazkov Christo,¹ Davarski Atanas,¹ Kitova Tanya,² Kehayov Ivo,¹ Kitov Borislav¹

¹ Department of Neurosurgery, Medical University, Plovdiv, Bulgaria

² Department of Anatomy, Histology and Embriology, Medical University, Plovdiv, Bulgaria

Primljen/Received 21. 01. 2015. god.

Prihvaćen/Accepted 18. 02. 2015. god.

Abstract: Objective: To analyze and present cases of tandem compression of medulla spinalis and cauda equina.

Material and Methods: The subjects of observation were four patients with simultaneous compression of medulla spinalis and cauda equina, admitted to the Neurosurgery Clinic of the St George University Hospital, Plovdiv, Bulgaria during the period March 2012 — March 2014. The average age of the patients was 60.5 years (47–72).

In one case, left-sided paramedian herniated discs were found at levels L₁₋₂ and L₄₋₅ combined with a concomitant stenosis, in another case — right-sided paramedian herniated discs on the level of Th₁₂ — L₁ and a degenerative stenosis at level of L₃₋₄, in the third case — pronounced degenerative compression at level Th₇₋₈ and a central stenosis at level of L₄₋₅, and in the last case — degenerative stenosis at level L₃₋₅ and spinal meningioma at level Th₉₋₁₀.

Results: The clinical signs of the simultaneous compression of the spinal cord and cauda equina have been examined. These signs may mislead the physician in the diagnosis of the spinal lesion, thus, resulting in inappropriate surgical strategy.

Conclusion: The involvement of the spinal cord must be clinically confirmed to rule out lesions in the thoracic region. When the lumbar imaging examinations are inconclusive or cannot explain the clinical symptoms of a certain patient, it is advisable to perform a magnetic resonance imaging of the entire spine.

Key words: tandem compression, spinal tumor, thoracic stenosis, lumbar stenosis.

INTRODUCTION

The term ‘tandemspinal stenosis’ was first introduced by P. Teng and C. Papatheodorou in 1964 in an attempt to describe the simultaneous compression in

the cervical and lumbar regions (1). Subsequently, several publications have been published in the specialized literature that discuss the simultaneous compression in the thoracic, thoraco-lumbar and lumbar regions (2, 3), resulting from degenerative stenosis (4), disc herniation (3), arachnoid cysts (5) or spinal tumors (6). In some cases, surgeons first operate on the lumbar lesion due to its apparent clinical and imaging manifestation. Nevertheless, neurological complications are sometimes possible resulting from the superiorly located lesion (3).

Objective

Analyzing and presenting cases of tandem compression of medulla spinalis and cauda equina.

MATERIAL AND METHODS

We present 4 cases (3 male and 1 female) that were treated in the Clinic of Neurosurgery at St George University Hospital, Plovdiv, Bulgaria between March 2012 and March 2014. The mean age of the patients was 60.5 years (47–72). All cases have long-lasting medical history of back pain irradiating unilaterally or bilaterally to the legs which was subsequently overlapped by stiffness and weakness in the lower extremities (Table 1).

In one of our cases, the clinical presentation was dominated solely by lower back pain accompanied by radicular sensory and motor deficit. All other three cases presented with combined symptoms of central and peripheral system damage (Table 2).

CASE DESCRIPTIONS

All four cases are systematically presented on Tables 1, 2 and 3.

Table 1. Affected spinal segments and initial symptoms

Patient/Gender/Age	Reported initial symptoms	Level of compromise of caudaequina	Level of compromise of medullaspinalis
1. Female, 72	Back pain, left leg pain and numbness	Stenosis L ₄ -L ₅ (HIJ + HYL + DH)	Stenosis L ₁ -L ₂ (HIJ + HVL + DH)
2. Male, 58	Pain in the thoraco-lumbar region and leg stiffness	Stenosis L ₃ -L ₄ (HIJ + HVL + DH)	Disc herniation at Th ₁₂ -L ₁ level
3. Female, 65	Pain in the back and legs. Numbness across L ₅ and S ₁ dermatomes bilaterally	Stenosis L ₄ -L ₅ (HIJ + HYL + DH)	Stenosis Th ₇ -Th ₈ (HIJ + HYL + DH)
4. Female, 47	Pain in the back and legs. Progressive weakness in the legs	Stenosis L ₃ -L ₄ and L ₄ -L ₅ (HIJ + DH)	Meningioma at Th ₉₋₁₀ level

HIJ — hypertrophy of the intervertebral joint; **HYL** — hypertrophy of the yellow ligament; **HVL** — hypertrophy of the vertebral lamina; **DH** — disc herniation;

Table 2. Neurological status of the patients at hospital admission

Patient/Gender/Age	Neurological status
1. Female, 72	Lumbar vertebral syndrome: Positive Lassegue sign at 30° on the left. Pain and hypesthesia across L ₂ -S ₁ dermatomes on the left. Loss of knee-jerk and ankle-jerk reflexes on the left. Fibular nerve plegia and tibial nerve paresis on the right side (Grade C on the Frankel Scale). Hypotrophy of the muscles of the left thigh and calf.
2. Male, 58	Thoraco-lumbar vertebral syndrome. Pain and hypesthesia across L ₅ and S ₁ dermatomes bilaterally. Increased knee-jerk and ankle-jerk reflexes. Positive Babinski sign bilaterally, latent inferior paraparesis (Grade D on the Frankel Scale).
3. Female, 65	Thoraco-lumbar vertebral syndrome. Pain and hypesthesia across L ₅ and S ₁ dermatomes bilaterally. Inferior paraplegia (Grade A on the Frankel Scale). Positive Babinski sign bilaterally. Conductive hypesthesia distally from Th ₉ dermatome. Bowel and bladder retention.
4. Female, 47	Lumbar vertebral syndrome: Pain and hypesthesia across L ₅ and S ₁ dermatomes on the left. Inferior spastic paraparesis, more severe on the left (Grade C on the Frankel Scale). Increased knee-jerk but diminished ankle-jerk reflexes. Positive Babinski sign bilaterally. Conductive hypesthesia distally from Th ₁₂ dermatome.

Table 3. Patients' neurological outcome

Patient/Gender/Age	Neurological outcome
1. Female, 72	Substantial relief from the pain and vertebral syndromes. Mild reduction of the sensory deficit. Reduction of the right-sided fibular palsy and tibial paresis.
2. Male, 58	Substantial relief from the pain and vertebral syndromes. No motor and sensory deficit of the lower extremities (Grade D on the Frankel) Persistent hypesthesia across L ₅ and S ₁ dermatomes.
3. Female, 65	Postoperative recovery was satisfactory with alleviation of the vertebral and radicular syndromes together with reduction of the inferior paraplegia to Grade C according to Frankel Scale. Bowel and bladder disturbances were persistent.
4. Female, 47	The neurological examination at 24 th postoperative month revealed substantially improved neurological function to Grade D on the Frankel Scale; substantial relief of the pain syndrome; persistent hypesthesia across the left S ₁ dermatome, absent left ankle-jerk reflex and mild difficulty in the plantar flexion of the toe resulting from the peripheral damage due to the lumbar pathology. The patient is able to perform her previous duties. The postoperative MRI of the thoraco-lumbar spine showed no tumor recurrence and adequate decompression of the lumbar spinal stenosis.

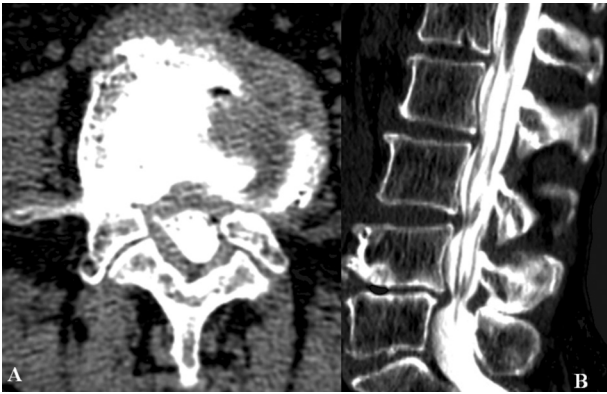


Figure 1. CT-assisted myelography: (A) axial view at L₄₋₅ level; (B) sagittal reconstruction — degenerative stenosis at L₄₋₅ level

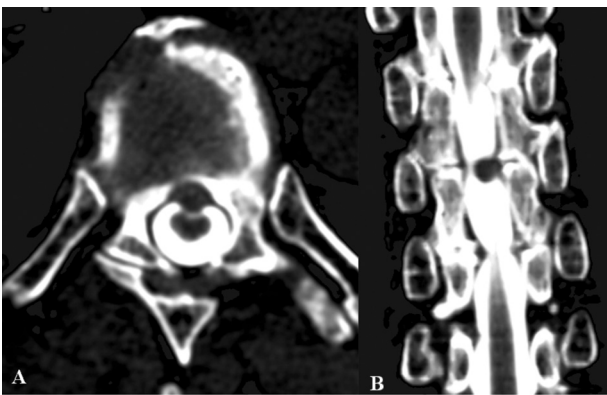


Figure 2. CT-assisted myelography: (A) axial view at Th₇₋₈ level; (B) sagittal reconstruction — degenerative stenosis at Th₇₋₈ level

Case 3: Sixty-five year old female who suffered from long-lasting back pain that, occasionally, irradiated to the gluteal region and the antero-lateral surface of both thighs accompanied by numbness. One day prior to hospitalization, upon physical exertion she felt acute intensive pain in the thoraco-lumbar region, followed by numbness, stiffness and weakness of the legs that got completely paralyzed within hours. The lumbo-dorsal CT-assisted myelography demonstrated degenerative compression at Th₇₋₈ level with laminar, facet and yellow ligament hypertrophy accompanied by severe central degenerative stenosis at L₄₋₅ causing complete lower stop of the contrast agent (Figure 1 and 2).

One-stage surgical decompression was performed at Th₇₋₈ followed by L₄₋₅ level. Degenerative stenosis with laminar, facet and yellow ligament hypertrophy was found at both levels.

DISCUSSION AND CONCLUSIONS

According to the published data, the variety of clinical symptoms typical of the tandem compression of the spinal cord and cauda equina can lead to incomplete diagnosis (2, 3, 7). In these cases, the detection of the thoracic compression can be omitted due to different factors:

1. The hyperreflexia and leg spasticity caused by the myelopathy can be overlapped by the symptoms resulting from the compression of the cauda equina and the nerve roots (3, 7). All patients in our series demonstrate excitatory and depressed sensory radicular symptoms. Two of the patients showed motor deficits and absent tendon reflexes of the lower extremities, and three of them presented with more or less obvious signs of myelopathy.

2. Patients with compression of the epiconus and conus medullaris (from Th₁₀ to L₂) resemble the clinical presentation of lumbar radiculopathy (8, 9). Toribatake et al. published a series of 15 patients with similar lesion localizations. All patients presented with unilateral or bilateral muscle atrophy and sensory deficit, in 87% — absence of tendon reflexes, in 67% — bowel and bladder disturbances and in only 20% — pathological reflexes (9). The compression at L₁–L₂ level typically presents with pain in the gluteal region and the antero-lateral surface of the thighs as well as positive femoral nerve stretch test, especially, when LasPgue sign is negative (9). Similar clinical presentation was observed in our patient N°1.

3. Primary degenerative stenosis of the thoracic spine is relatively rare. Older patients often harbor asymptomatic cervical and/or thoracic degenerative stenosis that are not amenable to surgical intervention (1, 9). This is why physicians are focused on the clinically manifested lumbar pathology and, occasionally, omit the more superior compression (10).

All cases with clinically manifested lumbar spinal stenosis must undergo thorough neurological examination. If any minor myelopathic signs are present, it is mandatory to perform MRI of the entire spine to rule out compression of the spinal cord that can eventually compromise the treatment strategy and result in poor outcomes.

The timing and the surgical strategy in cases with tandem compression of the spinal cord and cauda equina that lead to neurological deficits in the lower extremities is a matter of debate. Some authors advocate initial surgery of the spinal cord compression, especially in urgent cases that are not suitable for one-staged procedure. In our series, we performed one-staged procedures in all cases with tandem thoracic and lumbar degenerative compression. We first addressed the thoracic lesion. We operated on the patient with combined thoracic meningioma and degenerative lumbar spinal stenosis at two separate stages as we first removed the thoracic compression.

Abbreviations:

HIJ — hypertrophy of the intervertebral joint;
HYL — hypertrophy of the yellow ligament;
HVL — hypertrophy of the vertebral lamina;
DH — disc herniation

Sažetak**TANDEM KOMPRESIJA KIČMENE MOŽDINE I KAUDE EKVINE**Zhelyazkov Christo,¹ Davarski Atanas,¹ Kitova Tanya,² Kehayov Ivo,¹ Kitov Borislav¹¹ Department of Neurosurgery, Medical University, Plovdiv, Bulgaria² Department of Anatomy, Histology and Embriology, Medical University, Plovdiv, Bulgaria

Cilj: Analiza i prikaz slučajeva tandem kompresije kičmene moždine i kaude ekvine.

Materijal i metode: Predmet posmatranja su četiri pacijenta sa istovremenom kompresijom kičmene moždine i kaude ekvine, koji su primljeni na Kliniku za neurohirurgiju Univerzitetske bolnice Sveti George, Plovdiv, u Bugarskoj, tokom perioda Mart 2012 — Mart 2014. Prosečna starost pacijenata je 60,5 godina (47–72).

U prvom slučaju levostrana paramedijalna diskus hernija, pronađena je na nivou L₁₋₂ i L₄₋₅ u kombinaciji sa pratećom stenozom, u drugom slučaju, desnostrana paramedijalna diskus hernija na nivou Th₁₂–L₁ kao i degenerativna stenoza na nivou od L₃₋₄. U trećem slučaju, nađena je naglašena degenerativna kompresija na

nivou Th₇₋₈ i centralna stenoza na nivou L₄₋₅, a u poslednjem slučaju degenerativna stenoza na nivou L₃₋₅ i kičmeni meningeom na nivou Th₉₋₁₀.

Rezultati: Klinički znaci istovremene kompresije kičmene moždine i kaude ekvine su bili ispitani. Ovi znaci mogu obmanuti lekara u dijagnostici kičmene lezije i tako rezultirati neodgovarajućim hirurškim strategijama.

Zaključak: Uključivanje kičmene moždine mora biti klinički potvrđeno da bi isključilo lezije u grudnom regionu. Kada su lumbalni pregledi nepotpuni ili ne uspeavaju da objasne kliničke simptome određenog pacijenta, savetuje se magnetna rezonanca cele kičme.

Cljučne reči: tandem kompresija, spinalni tumor, torakalna stenoza, lumbalna stenoza.

REFERENCES

1. Teng P, Papatheodorou C. Combined cervical and lumbar spondylosis. Arch Neurol. 1964; 10: 298–307.
2. Hioki A, Miyamoto K, Hosoe H, Fukuta S, Shimizu K. Two-stage decompression for combined epiconus and cauda equina syndrome due to multilevel spinal canal stenosis of the thoracolumbar spine: a case report. Arch Orthop Trauma Surg. 2008; 128(9): 955–8.
3. Takeuchi A, Miyamoto K, Hosoe H, Shimizu K. Thoracic paraplegia due to missed thoracic compressive lesions after lumbar spinal decompression surgery: report of three cases. J Neurosurg. 2004; 100 (1 Suppl Spine): 71–4.
4. Kim BS, Kim J, Koh HS, et al. Asymptomatic cervical or thoracic lesions in elderly patients who have undergone decompressive lumbar surgery for stenosis. Asian Spine J. 2010; 4(2): 65–70.
5. Valls PL, Naul LG, Kanter SL. Paraplegia after a routine lumbar laminectomy: report of a rare complication and successful management. Neurosurgery. 1990; 27(4): 638–40.
6. Ko SB, Lee SW, Shim JH. Paraplegia due to missed thoracic meningioma after laminotomy for lumbar spinal stenosis: report of two cases. Asian Spine J. 2011; 5(4): 253–7.
7. Fushimi K, Miyamoto K, Hioki A, Hosoe H, Takeuchi A, Shimizu K. Neurological deterioration due to missed thoracic spinal stenosis after decompressive lumbar surgery: A report of six cases of tandem thoracic and lumbar spinal stenosis. Bone Joint J. 2013; 95–B(10): 1388–91.
8. Toribatake Y, Baba H, Kawahara N, Mizuno K, Tomita K. The epiconus syndrome presenting with radicular-type neurological features. Spinal Cord. 1997; 35(3): 163–70.
9. Lee S-Ho, Seokmin Choi S. L1-2 Disc Herniations: Clinical Characteristics and Surgical Results. J Korean Neurosurg Soc. 2005 (38): 196–201.
10. Wood KB, Garvey TA, Gundry C, Heithoff KB. Magnetic resonance imaging of the thoracic spine: evaluation of asymptomatic individuals. J Bone Joint Surg. 1995; 77(11): 1631–8.
11. Barnett GH, Hardy RW Jr, Little JR, Bay JW, Sybert GW. Thoracic spinal canal stenosis. J Neurosurg. 1987; 66(3): 338–44.

Correspondence to/Autor za korespondenciju

Ivo Kehayov

Department of Neurosurgery

15A Vassil Aprilov Blvd, Plovdiv 4000, Bulgaria

Email dr.kehayov@gmail.com