

AIDS cholangiopathy as a first presentation of HIV infection: Case report

Erwa Elmakki* and Hussein Aqeely

Department of Internal Medicine, Faculty of Medicine, Jazan University, Saudi Arabia.

Accepted 26 February, 2013

ABSTRACT

AIDS is the end spectrum of HIV infection. AIDS patients are susceptible to many opportunistic infections such as cryptosporidiosis and cryptosporidial cholangiopathy. The main aim of reporting this case is to show that AIDS can take a different form of presentation. We reported a rare case of cryptosporidia-related AIDS cholangitis as a first presentation of HIV infection in a 35-year-old female. The diagnosis was established by clinical findings in addition to extensive investigations, including radiological imaging and colonic biopsy. Cryptosporidial AIDS cholangiopathy can be a first presentation of HIV infection. HIV infection should be considered in all patients presenting with unexplained cholestasis.

Keywords: Cryptosporidium, AIDS cholangiopathy.

*Corresponding author. E-mail: erwamakki@gmail.com.

CASE REPORT

A 35-year-old female was referred to our hospital because of a one month history of jaundice, right hypochondriac pain, pruritis and dark urine. Liver biochemistry showed a cholestatic pattern, with high total bilirubin (80 mmol/L), high alkaline phosphatase (650 u/L) and GGT (330 u/L) and normal transaminases levels (ALT and AST). Abdominal ultrasonography and CT with contrast reported dilated intra and extra hepatic biliary radicles with no stone or masses in CBD or pancreas. MRCP showed a dilated gall bladder and common bile duct (CBD) with stricturing of the intra-hepatic biliary radicles (Figure 1). Systemic review also revealed that she has fever, hemoptysis, watery diarrhea, and headaches. Physical examination revealed a sick patient with generalized muscle wasting, oral candidiasis, bronchial breathing and crepitations at the left upper lobe, soft abdomen with no organomegaly. These new clinical findings led to us to screen her for HIV infection. HIV infection was confirmed by ELISA and western blot testing. CD4 count was only 65 /mm³ and she had a viral load of 100,032 copies/ml. She underwent upper and lower GI endoscopies. Colonoscopy showed flat colonic mucosa. A biopsy was obtained and proved to be positive for cryptosporidium parvum (Figure 2). Chest X-ray and CT showed a round, well-defined opacity in the left upper lobe with an impression of Aspergilloma (Figure 3).

Autoantibodies including antinuclear antibodies (ANA), anti-smooth muscles antibodies (ASMA), peri-nuclear neutrophil cytoplasmic antibodies (P-ANCA) were negative. Unfortunately her condition deteriorated and she died of respiratory failure before starting antiretroviral therapy (ART).

INTRODUCTION

AIDS cholangiopathy (AC) is a syndrome of biliary obstruction due to infection-related strictures of the biliary tree (Margulis et al., 1986). The organism most commonly associated with AIDS cholangiopathy is cryptosporidium parvum. Cryptosporidiosis is usually seen in advanced HIV infection (when CD4 count declined below 100/mm³). Other organisms that have been isolated include Microsporidium, Cytomegalovirus (CMV) and Cyclospora Cayetanensis (Forbes et al., 1993). AC occurred in as many as 26% of AIDS patients prior to the advent of ART (Vakil et al., 1996).

DISCUSSION

HIV-biliary disease was first described by Cello in 1989.

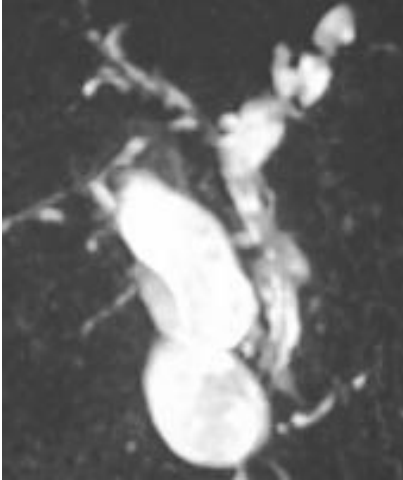


Figure 1. MRCP shows strictures and dilatation of hepatic ducts with dilatation of gall bladder and CBD.

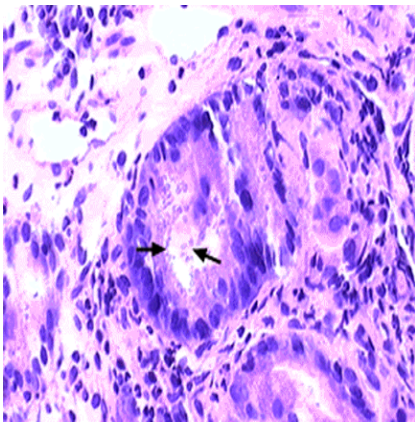


Figure 2. Section of colonic mucosa showing numerous cryptosporidia.

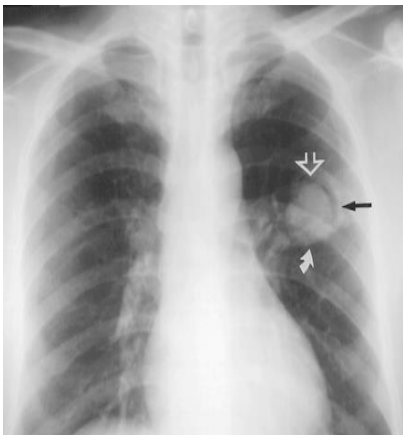


Figure 3. CXR showing a round-well defined radiopacity in the left upper lobe suggestive of mycetoma.

The disease is more present in male homosexual individuals. Under normal circumstances the human biliary tree is sterile despite its junction with the enteric flora of the small intestine. One study of an *in vitro* model of human biliary tract cryptosporidiosis demonstrated that recombinant HIV-1 Tat protein decreases cholangiocyte expression of Toll-like receptor (TLR) 4, an important pathogen-recognition receptor. So patients with AIDS are more susceptible to *Cryptosporidium parvum*, as well as other opportunistic infections (Sharma et al., 2006; O'Hara et al., 2009).

The two most common presentations of HIV-related biliary disease are AC and acalculous cholecystitis. The four cholangiographic abnormalities that can be seen in AC are papillary stenosis, intra or extra hepatic sclerosing cholangitis, combination of papillary stenosis and sclerosing cholangitis as well as extrahepatic duct stricture. AC has been shown as a presenting feature of advanced AIDS.

In the literature, many cases of HIV cholangiopathy have been reported, but AC as a first presentation of HIV infection is a rare clinical condition. Very few cases are reported with such presentation (Mukhopadhyay et al., 2001). An interesting fact in our case is that AC was seen in association with other AIDS related conditions such as oral candidiasis and aspergilloma.

The diagnosis of AC is dependent on clinical, biochemical and radiologic evidence of bile ducts abnormalities. Regardless of the causative opportunistic organism, the clinical manifestations of AC are similar. Specifically, AC present with right upper quadrant or epigastric abdominal pain in 90% of patients. Other symptoms include jaundice, fever, nausea, vomiting and diarrhea. Diarrhea occurs because of small bowel involvement. In one study of AIDS patients with diarrhea due to cryptosporidium, 23% developed biliary tract disease. Patients with AC typically present with CD4 count of less than $100/\text{mm}^3$. A cholestatic pattern of liver enzymes abnormality is seen in most patients. MRCP has been recommended to diagnose AC; however, there are no established diagnostic criteria. MRCP shows dilatation of the common bile duct with distal tapering that is associated with papillary stenosis (Bilgin et al., 2008). ERCP is the most definitive investigation for AC, as well as a therapeutic option to provide symptomatic relief by papillotomy to patients with papillary stenosis (Mahajani and Uzer, 1999). Cholangiopathy secondary to AIDS usually responds to antiretroviral medications (Devabhavi et al., 2010; Brun and Pitchumoni, 2010).

Unfortunately, the case described here deceased before starting such medications and she received only supportive treatment.

Diagnosis of cryptosporidium-associated AC in our case was established by: clinical features (right upper quadrant pain and fever), biochemical features (raised alkaline phosphatase), radiological features (MRCP findings), identification of cryptosporidium in colonic

biopsy, plus absence of auto-antibodies and other identifiable causes of cholangiopathy.

CONCLUSION

Cryptosporidial AIDS cholangiopathy can be a first presentation of HIV infection. HIV infection should be considered in all patients presenting with unexplained cholestasis.

REFERENCES

- Bilgin M, Balci NC, Erdogan A, Momtahan AJ, Alkadee S, Rau WS, 2008. Hepatobiliary and pancreatic MRI and MRCP findings in patients with HIV infection. *Am J Roenterol*, 191(1):228-232.
- Brun A, Pitchumoni CS, 2010. Biliary disease in HIV. *Practical Gastroenterol*, pp: 24-32.
- Devarbhavi H, Dierkhising R, Kremers WK, Sandeep MS, Karanth D, Adarsh CK, 2010. Single center experience with drug-induced liver injury from India: Causes, outcome, prognosis and predictors of mortality. *Am J of Gastroenterol*, 105(11):2396-404.
- Forbes A, Blanshard C, Gazzard B, 1993. Natural history of AIDS-related sclerosing cholangitis: A study of 20 cases. *Gut*, 34:116.
- Mahajani RV, Uzer MF, 1999. Cholangiopathy in HIV- infected patients. *Clin Liv Dis*, 3(3):669-684.
- Margulis SJ, Honig CL, Soave R, Govoni AF, Mouradian JA, Jacobson IM, 1986. Biliary tract obstruction in the acquired immuno-deficiency syndrome. *Ann Intern Med*, 105:207.
- Mukhopadhyay S, Monga A, Rana SS, Kar P, 2001. AIDS cholangiopathy as initial presentation of HIV infection. *Trop Gastroenterol*, 22(1):29-30.
- O'Hara SP, Small AJ, Gajdos GB, Badley AD, Chen XM, Larusso NF, 2009. HIV-1 Tat protein suppresses cholangiocyte toll-like receptor 4 expression and defense against *Cryptosporidium parvum*. *J Infect Dis*, 199(8):1195-1204.
- Sharma A, Duggal L, Jain N, Jupta S, 2006. AIDS cholangiopathy. *JACM*, 7(1):49-5.
- Vakil NB, Schwartz SM, Buggy BP, Brummitt CF, Kherallah M, Letzer DM, Gilson IH, Jones PG, 1996. Biliary cryptosporidiosis in HIV-infected people after the waterborne outbreak of cryptosporidiosis in Milwaukee. *N Engl J Med*, 334:19.