

## “Vertical infraclavicular block with Dexmedetomidine as an adjuvant to local anesthetics- multifaceted quality enhancement effort”

Madhavi Sanjay Chaudhari<sup>1,\*</sup>, Naresh Dilipkumar Vaswani<sup>2</sup>, Birva Nimit Khara<sup>3</sup>

<sup>1</sup>Professor, <sup>2</sup>3<sup>rd</sup> Year Resident, <sup>3</sup>Associate Professor, Dept. of Anesthesia, Pramukhswami Medical College, Anand, Gujarat

\*Corresponding Author:

Email: madhavic@charutarhealth.org

### Abstract

**Introduction:** For regional anesthesia, various adjuvants have been used along with local anesthetics (LA). We studied the effect of addition of Dexmedetomidine to LA in vertical infraclavicular brachial plexus block (ICB). The primary goal was to study the onset and duration of sensory and motor block. The secondary goal was to note the time for first rescue analgesic and quality of block.

**Materials and Method :** Sixty patients ( 18 to 60 years) posted for below elbow orthopaedic surgeries were given vertical ICB using PNS, after computerized randomization into two equal groups: **Group S:** Bupivacaine 0.375% (18 cc) + lignocaine 1.5% 20 cc + 2cc normal saline. **Group D:** Bupivacaine 0.375% (18 cc) + lignocaine 1.5% 20cc + dexmedetomidine 1 µg/kg (2ml volume). All the patients were observed for onset of sensory and motor block, total sensory and motor block duration, time to first rescue analgesic and side effects if any.

**Results:** The demographic data in two groups was statistically comparable. The onset of sensory and motor block in Group D was faster ( $p < 0.001$ ). The duration of sensory and motor block in Group D was longer [ $p < 0.001$ ]. The quality of block in Group D was better ( $p < 0.005$ ).

**Conclusion:** Dexmedetomidine as an adjuvant to local anesthetic agents in vertical infraclavicular block has early onset of sensory and motor blockade. The duration of sensory and motor blockade is significantly longer. The time for first postoperative rescue analgesic is also more and the quality of anesthesia as judged by the patients is better.

**Keywords:** Vertical infraclavicular brachial plexus block; Dexmedetomidine; Bupivacaine; Lignocaine

Access this article online	
Quick Response Code:	Website: www.innovativepublication.com
	DOI: 10.5958/2394-4994.2016.00036.6

### Introduction

Infraclavicular block (ICB) is easy to perform even in obese patients, avoids neurovascular structures in the neck, provides dense anesthesia for procedures below the shoulder with minimal risk of pneumothorax.<sup>(1,2)</sup> It is ideal for continuous catheter placement and fixation with less chances of infection. There has always been a search for adjuvants to local anesthetics (LA) that prolong the duration of analgesia and have less adverse effects so that long surgeries can be conducted with a single shot Brachial Plexus block and a need for continuous catheter is avoided. Alpha-2 adrenergic receptor agonists have been the focus of interest for their sedative, analgesic, perioperative sympatholytic and cardiovascular stabilizing effects with reduced anesthetic requirements<sup>(3,4,5)</sup>. So the current study was designed to test the effect of dexmedetomidine as an adjunct to local anesthetics in ICB.

The aims and objectives were to study the onset and duration of sensory and motor block, quality of

block, time to first analgesic request and to analyse side effects if any.

### Materials and Methods

A prospective randomized controlled study of sixty patients was carried out in the department of anaesthesiology of a tertiary care rural hospital after obtaining the institutional ethics committee approval. Patients of ASA I and ASA II physical status, between ages 18 to 60 years, posted for below elbow surgeries were included in the study.

Patients having sinus bradycardia, local site infection, deranged coagulation profile, hypotension, uncontrolled diabetes mellitus, pregnancy, pre-existing peripheral neuropathy and beta-blocker therapy were excluded from the study.

All patients underwent thorough pre-anesthetic evaluation and were kept nil by mouth for eight hours. Basic routine laboratory investigations were conducted. The anesthetic procedure to be carried out was explained and patients were reassured to alleviate their anxiety. They were educated regarding the VAS for pain. A written informed consent was taken.

The patients were assigned to one of the following groups based on the computer generated randomization table. **Group S:** Bupivacaine 0.375% (18 cc) + lignocaine 1.5% 20 cc + 2cc normal saline (NS). **Group D:** Bupivacaine 0.375% (18 cc) + lignocaine 1.5% 20cc + dexmedetomidine 1 µg/kg (2ml volume).

ECG, SpO<sub>2</sub> and NIBP were attached. IV line was taken in unaffected limb and IV injection Ringer Lactate was started. Under all aseptic precautions vertical infraclavicular block was performed with arm adducted, the point of entry was immediately below the midpoint of the clavicle, between the sternal notch and ventral acromion, using a nerve locator connected to a 22 gauge, 50 mm long stimulating needle (Stimuplex, Braun, Germany). On distal motor response with <0.5 mA, drug was injected in increments of 5 ml after negative aspiration for blood.

Sensory block was assessed by the pin prick method every 3 minute after completion of drug injection (T<sub>0</sub>) in the dermatomal areas corresponding to median nerve, radial nerve, ulnar nerve and musculocutaneous nerve till complete sensory blockade. Sensory onset was considered when there was a dull sensation to pin prick.

Sensory block was graded as-

Grade 0: Sharp pin felt

Grade 1: Analgesia, dull sensation felt

Grade 2: Anaesthesia, no sensation felt

Assessment of motor block was carried out by the same observer at every 3 minute till complete motor blockade after drug injection. Onset of motor blockade was considered when Grade 1 motor blockade was achieved. Motor block was determined according to a modified Bromage scale for upper extremities on a 3-point scale.

Grade 0: Normal motor function with full flexion and extension of elbow, wrist and fingers

Grade 1: Decreased motor strength with ability to move the fingers only

Grade 2: Complete motor block with inability to move the fingers

### Timings recorded in mins

T<sub>0</sub>- Time at completion of drug injection

T<sub>1</sub>- Time at achievement Of Grade 1 sensory Block

T<sub>2</sub>- Time at achievement Of Grade 2 sensory Block

T<sub>3</sub>- Time when Sensory Block reverts back to Grade 0

T<sub>os</sub>- Time of onset of sensory block (T<sub>os</sub> = T<sub>1</sub>-T<sub>0</sub>)

T<sub>ds</sub>- Duration of sensory Block(T<sub>ds</sub>= T<sub>3</sub>-T<sub>1</sub>)

T<sub>4</sub>- Time at achievement Of Grade 1 motor Block

T<sub>5</sub>- Time at achievement Of Grade 2 motor Block

T<sub>6</sub>- Time when motor Block reverts back to Grade 0

T<sub>om</sub>- Time of onset of motor block (T<sub>om</sub> = T<sub>4</sub>-T<sub>0</sub>)

T<sub>dm</sub>- Duration of motor Block(T<sub>dm</sub>= T<sub>6</sub>-T<sub>4</sub>)

T<sub>7</sub>- Time at which VAS<sub>≥</sub>4 and first rescue analgesic was given to the patient

T<sub>av</sub>- Time to requirement of first rescue analgesic (T<sub>av</sub> = T<sub>7</sub>- T<sub>0</sub>)

The block was considered incomplete when any of the segments supplied by median, radial, ulnar and musculocutaneous nerve did not have analgesia even after 30 min of drug injection. These patients were

supplemented with intravenous fentanyl (1µg/kg) and midazolam (0.02 mg/kg). When more than one nerve remained unaffected, it was considered a failed block. In this case, general anaesthesia was given. Patients were monitored for hemodynamic variables such as heart rate, blood pressure and oxygen saturation every 30 min after the block, intraoperatively and post-operatively. At the end of the procedure, quality of operative condition was assessed according to the following numeric scale:

Grade 3: (Excellent) No complaint from patient

Grade 2: (Good) Minor complaint with no need for the supplemental analgesics

Grade 1: (Moderate) Complaint that required supplemental analgesia

The patients were observed intraoperatively as well as postoperatively for the side effects of any drug or any other complications pertaining to the block performed and if found any, then they were accordingly dealt with and managed.

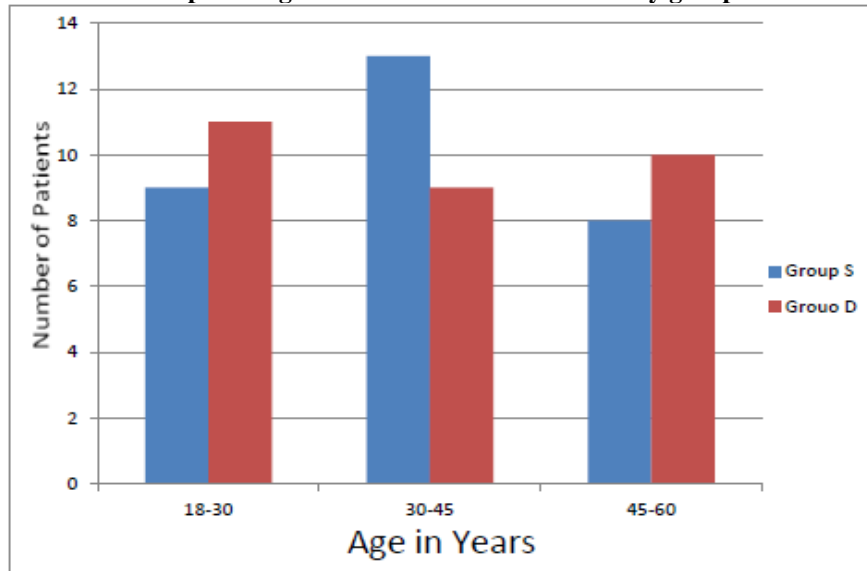
**Statistical Analysis:** Both the groups of patients were compared by independent sample 't' test, chi square test.

### Results

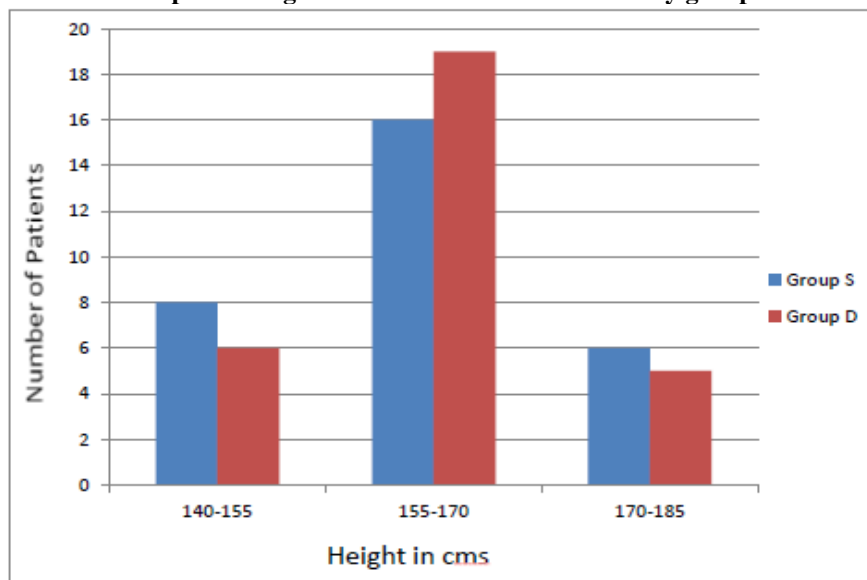
We studied total 60 patients between the age of 18 to 60 years, 30 patients per group (**S and D**). There were also 7 failed blocks which were excluded from the study and were not taken into account in the analysis.

The demographic data like age, height, weight, sex, ASA physical status were comparable in the two groups (Graphs 1 to 5).

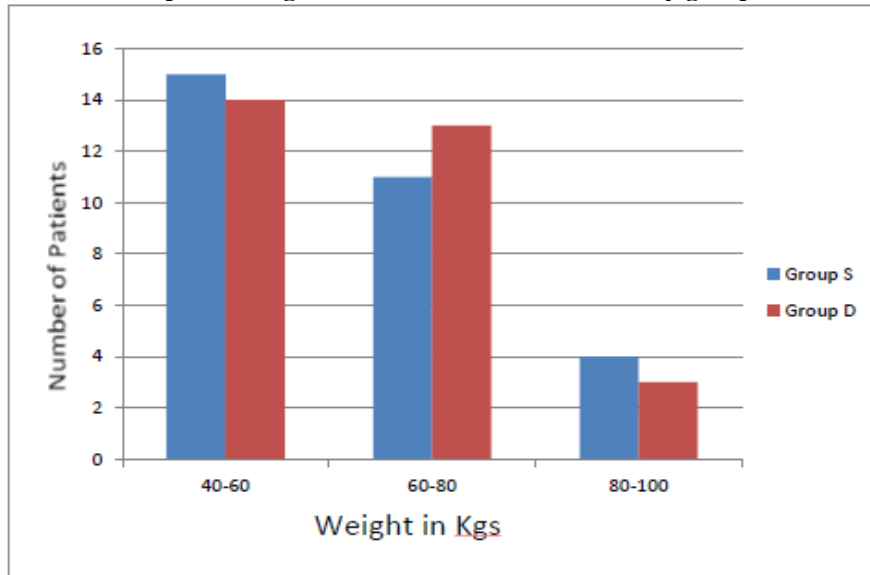
**Graph 1: Age distribution between two study groups**



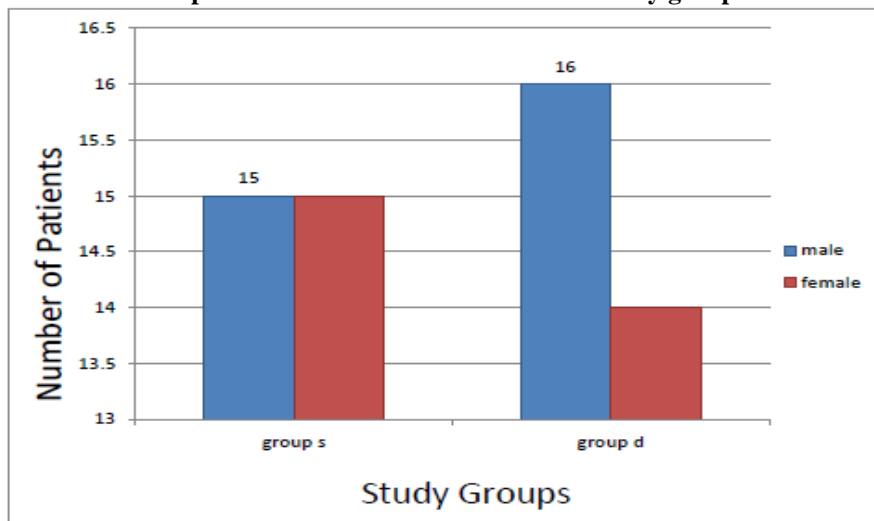
**Graph 2: Height distribution between two study groups**



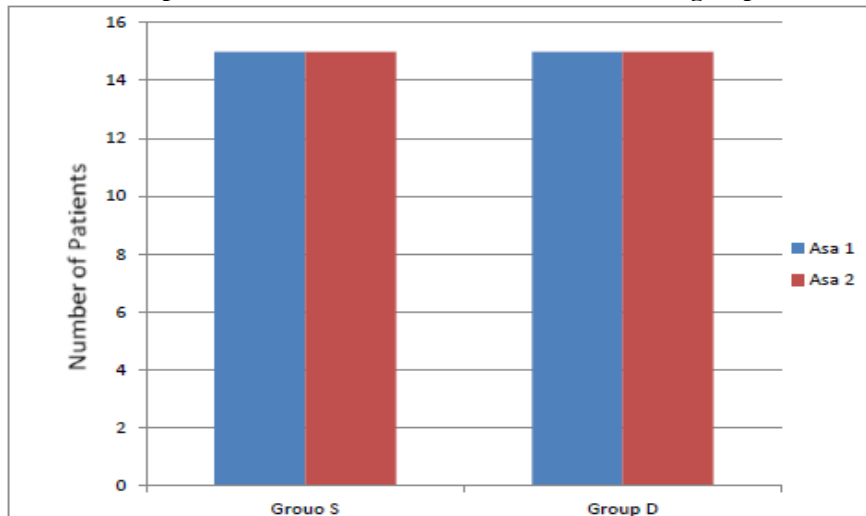
**Graph 3: Weight distribution between two study groups**



**Graph 4: Sex distribution between two study groups**



**Graph 5: Distribution of ASA status between two groups**



The onset of sensory block and motor block were earlier in Group D than Group S, and they were statistically significant ( $p < 0.001$ ). The duration of sensory and motor block was greater in Group D than Group S and was statistically significant ( $p < 0.001$ ). (Table 1 & 2)

**Table 1: Depiction of sensory characteristics of the two study groups**

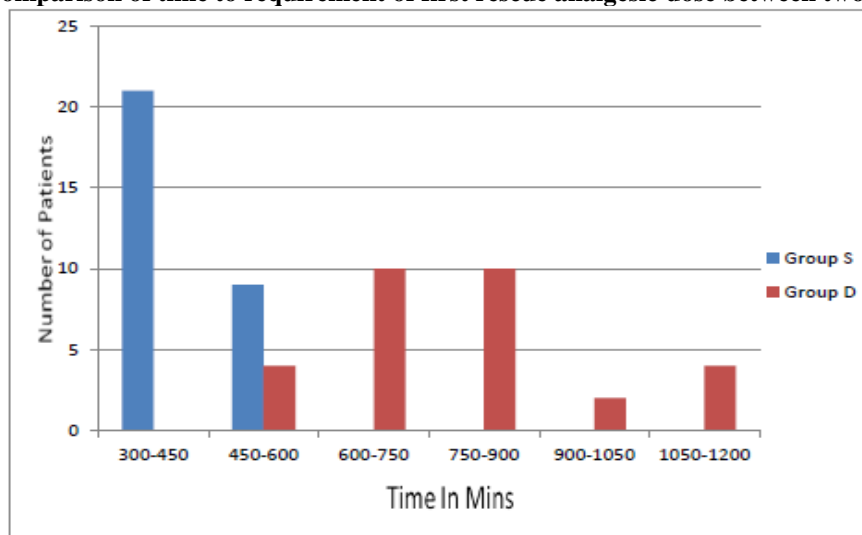
	Group S			Group D		
	Minimum	Maximum	Mean+SD	Minimum	Maximum	Mean+SD
Onset of sensory block	14 mins	26 mins	19.17±2.925 mins	11 mins	22 mins	15.63±2.906 mins
Duration of sensory block	200 mins	480 mins	353.33±75.71 mins	450 mins	780 mins	588.8±89.76 mins

**Table 2: Depiction of motor characteristics of the two study groups**

	Group S			Group D		
	Minimum	Maximum	Mean+SD	Minimum	Maximum	Mean+SD
Onset of motor block	18 mins	29 mins	22.87±2.92 mins	12 mins	24 mins	17.43±3.43 mins
Duration of motor block	240 mins	400 mins	304.83±37.97 mins	420 mins	660 mins	548.33±68.08 mins

The mean time to requirement of first rescue analgesic (VAS >4) in Group D was 793.33±173.31 min., and in Group S was 411.67±69.18 min. This difference was highly significant ( $p < 0.001$ ) both clinically and statistically. (Graph 6)

**Graph 6: Comparison of time to requirement of first rescue analgesic dose between two study groups**



The quality of block was better in Group D compared to Group S which was statistically significant ( $p < 0.005$ ) as evident from the Table 3.

**Table 3: Depiction of Quality of Block as assessed by patients**

	Group S	Percentage	Group D	Percentage
Excellent	20	66.66%	25	83.33%
Good	10	33.33%	5	16.67%
Moderate	0	0%	0	0%

In both the groups patients were hemodynamically stable, only one patient in Group D required intraoperative administration of Inj. Glycopyrolate 0.2 mg IV. There was no incidence of pneumothorax, nausea, vomiting, respiratory depression, pruritus and local anaesthetic drug toxicity in any of the group. In absence of supplemental IV sedation, 5 patients out of 30 in Group D were sedated, scoring  $\geq 3$  on Ramsay sedation scale, while none of the patients in Group S was sedated (Table 4).

**Table 4: Incidence of intraoperative sedation between the two study groups**

Parameter	Group S	Group S (%)	Group D	Group D (%)
Sedation	0	0	5	16.67
No Sedation	30	100	25	83.33

### Discussion

The patients posted for upper extremity surgeries are preferably managed under brachial plexus block (BPB). To avoid supplementary general anesthesia and to have good quality of BPB, the approach, onset and duration should be optimal for patient's satisfaction. In our study, for below elbow surgeries we had preferred vertical infraclavicular block for several reasons:-

1. Ability to perform block with patients head and arm in any position.
2. Avoidance of neurovascular structures of the neck.
3. Minimal risk of pneumothorax.
4. It is ideal for continuous catheter placement and fixation as it is an area with little movement and therefore less chances of being displaced.

Dexmedetomidine, as an adjuvant to local anesthetics has been used in neuraxial anesthesia and also in peripheral nerve block. Several hypothesized mechanisms of action have been suggested to explain the analgesic effect of dexmedetomidine. Some of these include vasoconstriction around the injection site<sup>(6,7)</sup>, direct suppression of impulse propagation through neurons as a result of a complex interaction with axonal ion channels or receptors<sup>(6,7,8)</sup>, local release of enkephalin like substances<sup>(9,10)</sup>, a decrease in localised inflammatory mediators<sup>(11)</sup> and an increase in anti-inflammatory cytokines through an  $\alpha_2$  adrenoceptor mediated mechanism.

**Abdallah et al**<sup>(12)</sup> did a quantitative review on all randomised control trials comparing the effects of dexmedetomidine as an adjuvant to local anesthetic on neuraxial and peripheral nerve blocks and concluded that dexmedetomidine prolongs the duration of analgesia compared with local anesthetics alone.

**Rachna Gandhi et al**<sup>(13)</sup> studied the effect of adding dexmedetomidine to bupivacaine in supraclavicular brachial plexus block. It was observed that in control group onset of motor and sensory blockade was faster, whereas dexmedetomidine group have better hemodynamic stability and greater post-operative analgesia.

**Esmaoglu et al**<sup>(14)</sup> mixed dexmedetomidine with levobupivacaine during placement of axillary brachial plexus blockade that resulted in shortening of block onset time and longer block duration resulting in improved post-operative analgesia.

Our prospective, randomised controlled study was conducted in two groups. After obtaining informed consent, patients were assigned to one of the following groups based on the computer generated randomization table.

Group S: Bupivacaine 0.375% (18 cc) + lignocaine 1.5% 20 cc + 2cc NS

Group D: Bupivacaine 0.375% (18 cc) + lignocaine 1.5% 20cc +

Dexmedetomidine 1  $\mu$ g/kg (2ml volume)

Vertical Infraclavicular brachial plexus block was performed by using a peripheral nerve stimulator (PNS).

The aims and objectives were to study the onset and duration of sensory and motor block, quality of block, time to first analgesic request and to analyse side effects if any. In our study, the demographic variables did not show any significant difference, both groups were comparable with respect to age, weight, height and sex distribution. The mean onset time of sensory block in Group S was 19.17 $\pm$ 2.92 mins while in group D was 15.63 $\pm$ 2.9 mins ( $p < 0.001$ ). Mean duration of sensory block in Group S was 353.33 $\pm$ 75.72 mins and that in group D was 588.80 $\pm$ 89.76 mins ( $p < 0.001$ ). The mean onset time of motor blockade in Group S was 22.87 $\pm$  2.92 mins while in Group D was 17.43  $\pm$  3.43 mins ( $p < 0.001$ ). The mean duration of motor block in Group S was 304.83 $\pm$ 37.97 mins while that in group D was 548.33 $\pm$ 68.08 mins ( $p < 0.001$ ). The mean time to requirement of first rescue analgesic (VAS $>$ 4) in Group S was 411.67 $\pm$ 69.18 mins while that in group D was 793.33 $\pm$ 173.31 mins( $p < 0.001$ ).

Two similar studies done on infraclavicular block (ICB) with local anesthetic and dexmedetomidine are:

1. A study conducted by **Mirkhesti et al**<sup>(15)</sup> in 2014, ICB was administered using USG. 111 patients were divided into three groups and a comparative study between 1.5% of 25 ml lidocaine with dexmedetomidine 100  $\mu$ g or ketorolac 5 ml or NS 5 ml was done. There was no significant difference in sensory block onset between the three groups. Sensory block duration in dexmedetomidine group was significantly longer than ketorolac and placebo groups. Motor block was significantly faster in dexmedetomidine compared to ketorolac and placebo groups. Also motor block duration with dexmedetomidine was significantly longer. Time to first analgesic request after the procedures was longest in ketorolac compared to dexmedetomidine and placebo group.
2. Another study conducted by **Ammy Ammar et al**<sup>(16)</sup> in 2012, ICB was given USG guided with 0.33% (30cc) bupivacaine alone or combined with 0.75  $\mu$ g/kg of dexmedetomidine. They found that adding dexmedetomidine to bupivacaine provides enhancement of onset of sensory and motor

blockade, prolonged duration of analgesia, increased duration of sensory and motor blockade, lower pain scores and reduced supplemental opioid requirement.

Thus the findings that there was shorter time of onset, and longer duration of sensory and motor block on adding dexmedetomidine to the LA of our study were consistent with above two studies.

There were no significant side effects like hypotension, bradycardia, pneumothorax, nausea and vomiting, respiratory depression and pruritus.

**Strength of the study:** With 40 ml volume and combination of local anesthetic, dense block was achieved lasting for longer duration as compared to other studies.

**Limitations of the study:** As this study included only 60 patients, multicentric study with larger sample size, using different dosages of dexmedetomidine, different volumes with different types and concentrations of local anesthetic agents are required. Also studies on patients with ASA III and above physical status need to be done.

**Acknowledgement:** We are thankful to Dr. Hemlata Kamat for her support.

## References

1. Raj PP, Montgomery SJ, Nettles D, Jenkins MT. Infraclavicular brachial plexus block-a new approach. *Anesth Analg.* 1973;52:897-904.
2. Fitzgibbon DR, Debs AD, Erjavec MK. Selective musculocutaneous nerve block and infraclavicular brachial plexus anesthesia. Case Report. *Reg Anesth.* 1995; 20:239-41.
3. Elliott S, Eckersall S, Fliqelstone L. Does addition of clonidine affect duration of analgesia of Bupivacaine in inguinal hernia repair. *Br J Anaesth* 1997;79:446-9.
4. Singelyn FJ, Gouveineur J, Robert A. A minimum dose of clonidine added to mepivacaine prolongs duration analgesia after brachial plexus block. *Anesth Analg* 1996;83:1046-50.
5. Popping DM, Elia N, Marret E, Wenk M, Tramèr MR. Clonidine as an adjuvant to local anesthetic for peripheral nerve and plexus blocks: A meta-analysis of randomized trials. *Anesthesiology* 2009;111:406-15.
6. Fitzgibbon DR, Debs AD, Erjavec MK. Selective musculocutaneous nerve block and infraclavicular brachial plexus anesthesia. Case report. *Reg Anesth.* 1995;20:239-41.
7. Sandhu NS, Capan LM. Ultrasound-guided infraclavicular brachial plexus block. *Br J Anaesth.* 2002;89:254.
8. Ebert TJ, Hall JE, Barney JA, Uhrich TD, Colino MD. The effects of increasing plasma concentrations of dexmedetomidine in humans. *Anesthesiology.* 2000;93:382-94.
9. Yoshitomi T, Kohjitani A, Maeda S, Higuchi H, Shimada M, Miyawaki T. Dexmedetomidine enhances the local anesthetic action of lidocaine via an alpha-2A adrenoceptor. *Anesth Analg.*

- 2008;107:96-101.
10. Butterworth JF, Strichartz GR. The  $\alpha$ -2-adrenergic agonists' clonidine and guanfacine produce tonic and phasic block of conduction in rat sciatic nerve fibers. *Anesth Analg.* 1993;76:295-301.
11. Nakamura M, Ferreira SH. Peripheral analgesic action of clonidine: Mediation by release of endogenous enkephalin-like substances. *Eur J Pharmacol.* 1988;146:223-8.
12. Abdallah FW, Brull R. Facilitatory effects of perineural dexmedetomidine on neuraxial and peripheral nerve block: a systematic review and meta-analysis. *Br J Anaesth* 2013;110 (6):915-25
13. Gandhi R, Shah A, Patel I. Use of dexmedetomidine along with bupivacaine for brachial plexus block. *Natl J Med Res.* 2012;2 (1):67-9.
14. Esmaoglu A, Yegenoglu F, Akin A, Turk CY. Dexmedetomidine added to levobupivacaine prolongs axillary brachial plexus block. *Anesth Analg.* 2010;111(6):1548-51.
15. Mirkheshti A, Saadatniaki A, Salimi A. Effects of dexmedetomidine versus ketorolac as local anesthetic adjuvants on the onset and duration of infraclavicular brachial plexus block *Anesth Pain Med.* 2014; Aug 2;4(3):18-28.
16. Ammar AS, Mahmoud KM. Ultrasound-guided single injection infraclavicular brachial plexus block using bupivacaine alone or combined with dexmedetomidine for pain control in upper limb surgery: A prospective randomized controlled trial. *audi J Anaesth* 2012;6(2):109-14.