

## Detection of Ovary Cyst using Kirsch Template

Anju R.S

P.G Scholar, Dept of CSE, BMCE, Kollam, Kerala, India

*anjurs89@gmail.com*

Radhakrishnan B

Professor, Dept. of CSE, BMCE, Kollam, Kerala, India

*radhak77@rediffmail.com*

**Abstract:** Ultrasound imaging of ovary is used to determine infertility problems. Now a days it is quite common. For effective treatment, information like shape, position, size and presence of cyst are important. Today detection of cyst is done by medical experts in non automatic way. This method often results inaccurate and incorrect determination. In this paper, a new automatic detection of follicles in ultrasound images of ovary is proposed. Four stages are involved like preprocessing, segmentation, feature extraction and classification. In preprocessing stage gaussian low pass filter is used for removing speckle noise in ultrasound image of ovary. Proposed algorithm use kirsch template for segmentation. Features extracted from the segmented image is used to classify normal ovary or cystic ovary.

**Keywords:** Ovary, Ultrasound image, Follicle, gaussian low pass filter, Speckle Noise Kirsch template, Feature Extraction.

### 1. INTRODUCTION

The ovary is an ovum-producing reproductive organ, often found in pairs as part of the vertebrate female reproductive system[1]. The ovaries are the site of production and periodical release of egg cells, the female gametes. In the ovaries, the developing egg cell (or oocyte) grows within the environment provided by follicles. Follicles are composed of different types and number of cells according to the stage of their maturation, and their size is indicative of the stage of oocyte development[2].

An ovarian cyst is any fluid-filled sac within the ovary. Most ovarian cysts are related to ovulation being either follicular cysts or corpus luteum cysts. Other types include cysts due to endometriosis, dermoid cysts, and cystadenomas[3]. Many small cysts occur in both ovaries in polycystic ovarian syndrome. Pelvic inflammatory disease may also result in cysts. Rarely cysts may be a form of ovarian cancer. Diagnosis is undertaken by pelvic examination with an ultrasound or other testing used to gather further details[4].

Ultrasound is sound waves with frequencies which are higher than those audible to humans. Ultrasound images also known as sonograms are made by sending pulses of ultrasound into tissue using a probe. The sound echoes off the tissue; with different tissues reflecting varying degrees of sound. These echoes are recorded and displayed as an image to the operator[5]. By analyzing ultrasound image of ovary help the doctor to determine whether it is cystic or not. Sometimes cyst may lead to infertility problems. For proper treatment of infertility, information like shape size, position are important. Non automatic detection of cyst in ultrasound image can be very demanding and inaccurate. To overcome those problems an automatic method is desirable. In this paper, a new automatic detection of cyst is proposed.

The literature on computer assisted approaches for follicle detection is rare. Potocnik and Zazula segmented ultrasound image of ovary using optimal thresholding[6]. This method use edges for finding ovary boundaries and thresholding. But it does not give optimal results. Again they were use active contour method for segmentation. But it is difficult to determine the parameters for snakes automatically[7]. Cigale and Zazula use cellular neural network for follicle segmentation. It was not promising work. Main disadvantage in this method is difficult to find the parameters for determining follicles[8]. Hiremath and Tegnoor segmented ultrasound image of follicle using edge based segmentation. Gaussian low pass filter is used in the preprocessing stage for noise removal[9]. Ultrasound images have high amount of speckle noise. The speckle is most often considered a dominant source of multiplicative noise and should be filtered out without affecting important features of the image[10].

In this paper, a new and improved algorithm for follicle detection is proposed. Four stages involved like preprocessing, segmentation, feature extraction and classification. Here speckle noise in the ultrasound image is reduced by using gaussian low pass filter and kirsch template method is used for segmentation. Features are extracted from the segmented image is used for classification. Main objective of this paper is to classify normal ovary and cystic ovary.

The paper is organized as follows. In section 2 describes new and improved proposed method for follicle determination. In section 3 shows the experimental results and section 4 concludes the paper.

## 2. METHODOLOGY

Ovarian follicles are spherical fluid- filled structures [8]. They grow from 8 to 10 mm on an average. Only the dominant follicle can reach as much as 17 to 25 mm in diameter . The small follicles of 2 to 3 mm can also be perceived in the ultrasound images of ovaries. In the middle of the ovary, other structures can also be found, such as blood vessels, lymphatic glands.

The block diagram used for follicle detection in this proposed method is shown in fig.1[11].Ultrasound image is an input to the algorithm. Our aim is to locate cystic portion from the image. Within the study of female fertility it is essential to know what your ovarian reserve is. Currently is still counting ovarian follicles, the truest estimate of ovarian reserve in a given patient. Ultrasound also allows us to follow the evolution and growth of follicles both in spontaneous cycle as in a stimulated cycle fertility treatment[12]. Sample ultrasound image is shown in fig.2. By this proposed algorithm we can know about the status of ovary whether it will affect infertility.

In this method mainly four steps are involved. Ultrasound image is preprocessed by Contourlet transform. Speckle noise can be reduced by this denoising method compared to gaussian low pass filter. Kirsch template is used for segmenting cystic portion from remaining region. Then features are extracted from the segmented image like major axis and minor axis. These features are used for classification.

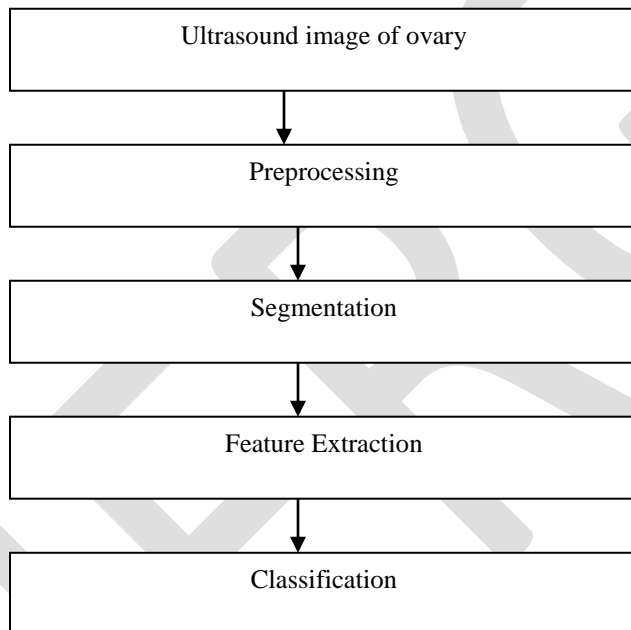


Fig.1 Block diagram of proposed algorithm

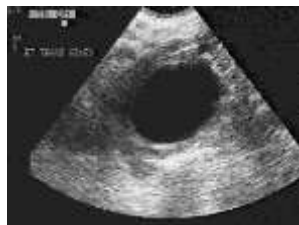

Fig.2 Sample ultrasound image of ovary

## A. Preprocessing

An efficient representation of visual information is one of the important tasks in image processing applications such as denoising. Ultrasound image is an input to this stage. Due to speckle noise in ultrasound image gives incorrect results. So this step is important. Gaussian low pass filter is used for noise reduction. This will yield better result compared to other noise removal methods.

## B. Segmentation

The image after noise removal will be the input for segmentation process. Kirsch template is used for segmentation. In this phase we compared with other methods, but kirsch template method yield better result. Correctly segment the cystic portion from remaining portion. Resulting image are broken due to noise. The broken edges are filled by using morphological dilation with appropriate structuring element like disc. Any unwanted edges are removed by using erosion operation.

## C. Feature Extraction

Feature extraction means extracting particular characteristics that can be used to classify images. Ovarian follicles are elliptical like structures. So we can consider as an ellipse and features can be extracted. Major axis, minor axis length of ellipse is extracted from the segmented image. By using these two measurement we can calculate the ratio of major axis and minor axis. Ratio is an important feature descriptor in this algorithm.

## D. Classification

### Training Phase

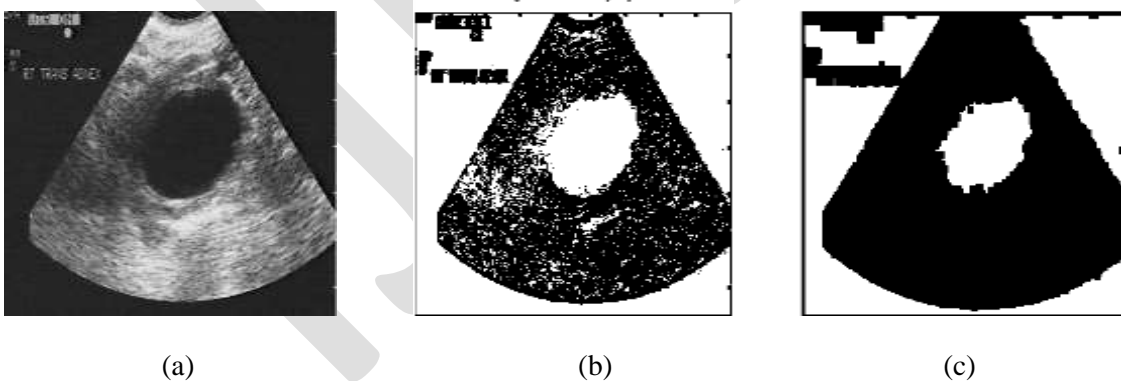
In this phase calculated ratio is an important information. Here we compute the ratio for regions known to be follicle in the segmented image. From our experimental study ratio for follicle region is 1.42 .

### Testing Phase

We can compute ratio of newly segmented image. By comparing ratio with our experimental value and classify whether it is cystic ovary or not.

## 3.EXPERIMENTAL RESULTS

Ultrasound image is an input to our proposed system. Images are collected from ultrasound gallery. The experimentation is done using 20 images, out of which 10 are used for testing phase and 10 for training phase. Typical results are shown in fig 3.






Fig.3 Results:a)Original image b)Segmented image c)dilated image d)eroded image e)detected cyst

#### 4.CONCLUSION

In this paper a new automated method for follicle detection is proposed. It helps significantly to improve the quality of diagnosis and treatment of patients. Ultrasound images are used as input. Gaussian low pass filter is used for noise removal in ultrasound image. Kirsch template is used for segmenting cyst portion. By extracting features from the segmented image is used for classification. The experimental results are in good agreement with the manual follicle detection by medical experts, and thus demonstrate efficiency of the method.

#### REFERENCES:

- [1] Daftary, Shirish; Chakravarti, Sudip (2011). Manual of Obstetrics, 3rd Edition. Elsevier. pp. 1-16. ISBN 9788131225561.
- [2] Salama S, Arbo E, Lamazou F, Levailant JM, Frydman R, Fanchin R (April 2010). "Reproducibility and reliability of automated volumetric measurement of single preovulatory follicles using SonoAVC". Fertil. Steril. 93 (6): 2069-73.
- [3] Qublan HS, Abdel-hadi J (2000). "Simple ovarian cysts: Frequency and outcome in girls aged 2-9 years". Clinical and experimental obstetrics & gynecology 27 (1):51-3. [PMID 10758801](#)
- [4] Caspi, B.; Zbar, AP.; Mavor, E.; Hagay, Z.; Appelman, Z. (Mar 2003). "The contribution of transvaginal ultrasound in the diagnosis of acute appendicitis: an observational study.". Ultrasound Obstet Gynecol 21.
- [5] Kollmann M, Martins WP, Raine-Fenning N (2014). "Terms and thresholds for the ultrasound evaluation of the ovaries in women with hyperandrogenic anovulation". Hum. Reprod. Update 20 (3): 463-4.
- [6] B.Potocnik, D.Zazula, The XUltra project-Automated Analysis of Ovarian ultrasound images, Proceedings of the 15th IEEE symposium on computer based medical systems (CBMS'02)
- [7] Cigale B and Zazula D, Segmentation of ovarian ultrasound images using cellular neural networks, Proc. 7th Inter. work. systems, signals and image processing (Maribor, Slovenia 2000) 33-36.
- [8] P.S.Hiremath and Jyothi R Tegnoor, Recognition of Follicles in Ultrasound Images of Ovaries using Geometric Features, Proc. 2nd IEEE International Conference on Biomedical and Pharmaceutical Engineering (ICBPE-09), 2-4 Dec. 2009, Singapore, ISBN 978-1-4244-4764-0/09
- [9] P.S.Hiremath and Jyothi R Tegnoor, Recognition of Follicles in Ultrasound Images of Ovaries using Geometric Features, Proc. 2nd IEEE International Conference on Biomedical and Pharmaceutical Engineering (ICBPE-09), 2-4 Dec. 2009, Singapore, ISBN 978-1-4244-4764-0/09
- [10] P.S.Hiremath and Prema Akkasaliger, Despeckling medical ultrasound images using the contourlet transform, 4th AMS Indian International Conference on Artificial Intelligence (IICAI-09), 16-18 Dec. 2009, Tumkur, India
- [11] P.S.Hiremath and Jyothi R Tegnoor, (2010), —Automatic Detection of Follicles in Ultrasound Images of Ovaries using Edge based Method, International Journal of Computer Applications (IJCA), Special issue on RTIPPR(2):No.3, Article 8, pp 120-125, ISSN 0975-8887.

[12] [12]M. J. Lawrence, R.A.Pierson, M.G.Eramian, E. Neufeld, "Computer assisted detection of polycystic ovary morphology in ultrasound images," In Proc. IEEE Fourth Canadian conference on computer and robot vision (CRV'07), pp. 105-112, 2007.

IJERGS