

## **THE EFFECT OF DENERVATION ON FRACTURE HEALING, AN EXPERIMENTAL STUDY ON RABBITS**

**Thamer A Hamdan<sup>\*</sup>, Mubder A Mohammed Saeed<sup>#</sup> & Abbas Salman Ismael<sup>@</sup>**

<sup>\*</sup>FRCS, FRCP, FICS, FACS, American Board (Ortho.), Professor of Orthopedic Surgery. <sup>#</sup>FICMS (Ortho.)Assistant Prof. of Orthopedic Surgery. College of Medicine, University of Basrah, Basrah, Iraq. <sup>@</sup>MB, CHB, Postgraduate Diploma (Ortho.)

### **Abstract**

Many studies suggested a relation between denervation and fracture healing either in positive or negative effect. This is a prospective experimental study on 20 rabbits carried out in the experimental animal's research laboratory of Basrah University, Medical College from April 2014 to November 2014 according to ethical rules of institution. They were housed under controlled conditions of temperature and lighting, same diet was given for all animals. The rabbits was divided into two groups; group A with sciatic denervation and fracture of the tibia while group B, with fracture tibia only. The state of fracture healing was studied radiologically after 4 weeks and histopathologically at 6 weeks.

The results showed significant difference between the two groups, the denervated group had poor fracture healing compared with non denervated group.

In conclusion, denervation affects fracture healing negatively in rabbits.

### **Introduction**

Peripheral denervation is claimed to delay healing of experimental fractures<sup>1,2</sup>, but opposing opinions have also been presented<sup>3,4</sup>. The effects of peripheral nerve lesions on callus formation at the fracture site are incompletely known.

In animal models, fibular fractures failed to unite after removal of proprioceptive receptors by periosteal stripping<sup>5</sup>. In human samples with delayed union or nonunion of diaphyseal fractures, the most remarkable finding was the insufficiency or total lack of peripheral innervation. Supporting these concepts are the observations that patients with neurologic disorders exhibit altered fracture healing and excessive callus formation. Dyck et al<sup>6</sup> showed that patients with neuropathic arthropathy due to subclinical sensory neuropathy also suffer from recurrent long bone fractures. Under conditions of altered nerve supply, Retief and Dreyer<sup>7</sup> observed that connective tissue proliferation from the

damaged bone is non-osteogenic and prevents healing of experimental cortical defects in the rat mandibulae. Other studies have shown that fracture calluses are bigger, less dense, and mechanically weaker compared with controls after sciatic section<sup>8</sup>. In addition, Becker<sup>9</sup> showed that the time of denervation in relation to the time of fracture is a critical factor in the influence of denervation on the rate of healing in the rat fibula. In paraplegic rats, the fracture callus showed delayed accumulation of calcium and incomplete maturation of woven new bone<sup>10</sup>. A number of experimental studies suggest direct neuronal influence on local bone metabolism. In sympathetically denervated rats, quantitative autoradiographic analysis using <sup>3</sup>H-proline showed reduced osteoblastic activity and morphometric analysis indicated an increased number of osteoclasts and increased resorption activity after sympathectomy<sup>11</sup>. Sensory denervation, on the other hand, was

associated with a decrease in the number of osteoclasts. The way that denervation influences bone metabolism is unclear. Some authors suggest that bone response after denervation is not only due to a local effect, but also to a systemic response. Accordingly, some authors have shown that after neurectomy there is an alteration in bone mass of the contralateral femur compared to the sham-operated limb<sup>12</sup>, This supports studies that have found increased callus formation, a greater and more rapid healing response with heterotopic ossification in patients with head injuries<sup>13</sup>.

### Material & Methods

This is a prospective study on rabbit animals, which was carried out in the experimental animal's research laboratory of Basrah University, Medical College from April 2014 to November 2014, according to ethical rules of institution. They were housed under controlled conditions of temperature and lighting, same diet was given for all animals. Included Rabbits were males, healthy, age between 6-8 weeks and weighted between 1-2kg. Exclusion was for rabbit which is not healthy, died during anesthesia or in the follow up and not matching the weight and age required. All rabbits were generally anaesthetized by intravenous injection of ketamine 10-15 mg/kg through external marginal auricular vein, the anesthesia was given to the rabbits by the researcher. Left

tibiae of all anaesthetized animals were fractured manually by the researcher. Fixation of fractured bone was made by Zimmer splint (which is used for splinting of fracture phalanx) with adhesive strapping.

Denervation procedure: under general anesthesia, preparation of the area (shaving the hair and the use of antiseptics) was done, the a 2 cm incision was made over posterior aspect of thigh with blunt dissection through gluteal muscles, identification of sciatic nerve and excision (1 cm) from the nerve, irrigation of the field with normal saline then closing the wound in one layer with nylon silk number zero and dressing. After that, tibia of the same side was manually fractured and fixed by Zimmer splint. The Twenty rabbits were divided into 2 groups equally. Group A: Subjected to sciatic denervation and fracture of left tibia then fixed with Zimmer splint. Group B: Subjected to fracture of left tibia then fixed with Zimmer splint. Two methods were chosen for evaluation of the process of fracture healing: Radiological and histopathological examinations.

Radiographs of the leg were done on the day of the procedure and then repeated after 4 weeks. Fracture healing evaluated blindly by radiologist according to a 5 point scale describing the degree of callus density (degree of mineralization) and the degree of fracture line visibility<sup>14</sup> as in Figures1-3, and table I.

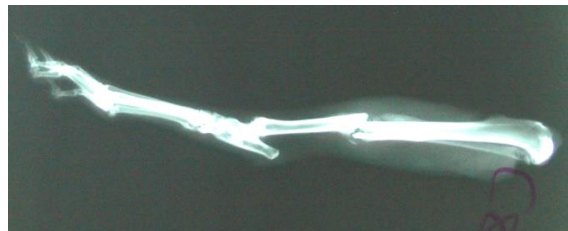

Fig. 1: Radiological findings of fracture healing (grade 1).

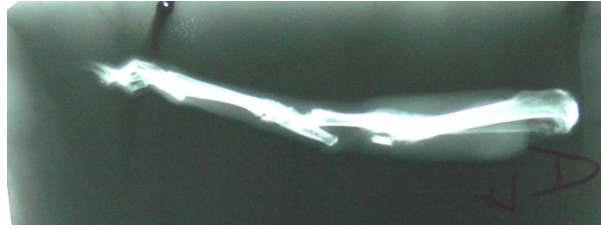

Fig. 2: Radiological findings of fracture healing (grade 2).

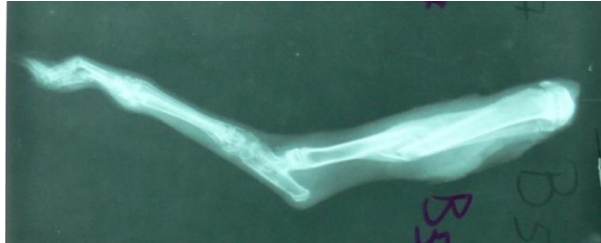

Fig. 3: Radiological findings of fracture healing (grade 3).

Table I: Radiological scores used for evaluation of fracture healing<sup>14</sup>

Grade	Radiological features of fracture healing
0	No callus with clearly visible fracture line
1	Low density callus with clearly visible fracture line
2	Moderate density callus with still visible fracture line
3	High density callus with hazy fracture line
4	Ossified callus with fracture line disappeared completely

After 6 weeks following fracture, 10 animals were studied, 5 animals from group A, 5 animals from group B all had odd number (1,3,5,7,9) had been sacrificed and the fractured tibiae were disarticulated and soft tissue was completely cleaned away. Kept in formalin for 5 days, Bone specimens were decalcified using (HCl 8% water 92%) for several days and then washed

for 24 hours in running tap water. Paraffin blocks were sectioned and the slides were stained by hematoxylin and eosin. The slides were examined by light microscopy. The fracture healing was evaluated blindly by a histopathologist; using the scoring system which consists of 5 points scale<sup>15</sup> as shown in Figures 4&5 and table II.

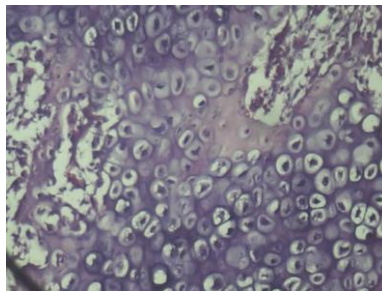


Fig.4: Histological picture of fracture healing, grade (3), shows chondrocytes .

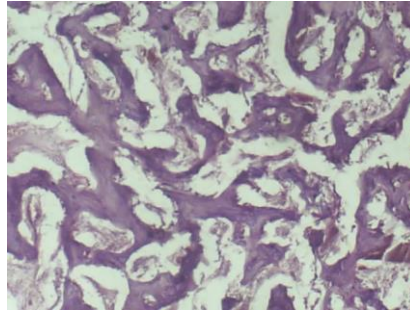


Fig.5: Histological picture of fracture healing shows mature bone trabeculae with osteoblastic rimming, grade (4).

Table II: Histological score used for evaluation of fracture healing<sup>15</sup>

Grade	Histological assessment of fracture healing
0	Non union
1	Incomplete cartilaginous union
2	Complete cartilaginous union
3	Incomplete bony union
4	Complete bony union

Data analysis was done using spss (statistical package for social sciences) program t-test was applied, p value<0.05 was considered to be significant.

**Results**

The results were studied statistically by means of radiological grade of healing and standard deviation of both groups. The radiological scores of experimental animal sample under study were as follows: FIRST: For the Group A (fractured animals with sacrificed nerve). Out of 10 rabbits, 8 animals shows poor results ( manifested in radiological score

equal to 1) and only 2 animals shows slightly improved score, equal to 2.

SECOND: For the group B which represents the fractured animal without sacrificed nerve represented in 7 animals out of 10 which shows a good prove of fracture healing and the remaining 3 animals with a radiological score of 2. as demonstrated in table III.

Table III: Radiological grading of rabbits, 28 days post fracture tibia for groups A, B.

Group	Animal number and radiological scoring										Mean Radiological grade	SD
	1	2	3	4	5	6	7	8	9	10		
Group A	1	1	2	1	1	1	1	2	1	1	1.2	0.42164
Group B	3	2	3	2	3	2	3	3	2	3	2.6	0.51640

P value <0.01 so there is highly significant correlation between denervation and fracture healing, the statistical analysis of the above results shows that the mean radiological grade for the group A was 1.2 and that for group B was 2.6, with an SD equal to (0.42164) and (0.51640) respectively.

The histopathological scores of experimental animal sample under study were as follows; FIRST: For the Group A

(fractured animals with sacrificed nerve). Out of 5 rabbits, 4 animals shows poor results ( manifested in histological score

equal to 3) and only 1 animal shows slightly improved score, equal to 4.

SECOND: For the group B which represents the fractured animal without

sacrificed nerve represented in 5 animals all shows a good prove of fracture healing (histological score equal to 4) as in table IV.

Table IV: Histological findings 6 weeks post fracture of rabbits in groups A and B.

Group	Animal number and histological scoring					Mean Histological grade	SD
	1	3	5	7	9		
Group A	3	4	3	3	3	3.6	0.44721
Group B	4	4	4	4	4	4	0

P value < 0.01 so there is highly significant correlations between denervation and fracture healing, the statistical analysis of the above results shows that the mean histological grade for the Group A was (3.6) and that for group B was (4), with a SD equal to (0.44721) and (0) respectively.

## Discussion

In the present study, rabbits were chosen because of similarities of rabbit and human skeleton. Male gender was selected to avoid pregnancy and period in females; also the sample size is in agreement with other studies<sup>16</sup>. To avoid effect on time of healing process as in Uthoff H K said<sup>17</sup>, the age and weight of the chosen animals was convergent. As mentioned in Orr-HE et al study, intravenous ketamine has been used for anesthesia because of its safety<sup>18</sup>. We used the posterior approach for exploration of sciatic nerve as mentioned in Brown MJ et al study<sup>19</sup>. Bone repair is a highly regulated process that can be separated into overlapping histological, chemical and biomechanical stages as mentioned in Robbins S L study<sup>20</sup>. The clinical assessment of fracture healing included subjective and the radiographic assessment of healing and have shown to be poor parameter, and there is also a lack of consensus as to what is a reliable definition of fracture healing in the orthopedic literature as stated by Corrales LA et al<sup>21</sup>. Bould M et al<sup>22</sup> said that it is

possible to identify an end point of healing by measuring the callus score and the time of occurrence of this end point will be different for different fracture treatment and the callus score can usually be measured from standard radiographs that are obtained during the routine follow up of most fractures. He used the digital image for evaluation of fracture healing which shown to be up to 20 times more accurate, so we depend on digital radiograph to measure the callus score. Another study by Gardner et al mentioned that fracture configurations are not amenable to callus measurement, only diaphyseal long bone fractures were used for callus measurement, as in current study we fractured tibial diaphysis. Another study done by K durak et al<sup>15</sup> explain that histology is a basic method for the evaluation of fracture healing and histological slides taken from bone blocks contain fracture site, were evaluated for complete and incomplete cartilaginous and bony union, so in the current study we depended on radiograph and histological assessment for evaluation of

process of fracture healing. The current study shows that there is statistically significant difference in fracture healing between the two groups of rabbits, rabbits group which had denervation and fracture and the other group which had fracture only. Denervated fractured group shows less grade callus score compared with non denervated fractured group, this is similar to the result obtained by Aro study on rats<sup>23</sup> which suggest that the nervous system interacts with fracture-healing. In regard to denervation that can influence the processes of fracture healing, it can affect the proliferation of early callus tissue, differentiation of chondrocytes, osteoblast activity, osteocytes, or blood flow to fracture.

It was observed that denervation had increase the number of the chondrocytes and osteoclasts significantly but decreased the number of fibroblasts and reduced osteoblastic activity. Another study by Wilson j<sup>24</sup>, who get the same results with the current study, he explain that denervation in rabbit lead to muscle and bone tissue atrophy on the paralyzed side, and the mechanism is by increased bone resorption followed by increased accretion until equilibrium is reached and the atrophy stops. Also muscle tone depends on an intact peripheral nerve supply so that, non denervated group (even when immobilized) the resting muscle tone apply load across the fracture which provide one of the mechanical factor to callus formation, while with denervation there will be loss of motor supply leads to loss of muscle tone and have negative effect on the process of fracture healing. The negative effect of denervation on fracture healing process

which obtained in current study also noticed by Takahashi et al study in rat, who explain denervation decrease vascular supply to bone which is important for fracture healing process<sup>25</sup>. Controversy to this study by Hukkanen et al<sup>26</sup> suggest changes in bone and callus blood flow in nerve-resected compared to normal tibiae have not been reported, but explain the negative effect of denervation that sensory innervation affect fracture angiogenesis, the delay in healing indicating defects in tissue composition or organization rendered by the nerve injury so the nerve resection group changed the pattern of the healing fracture. So the results suggest that intact innervation is essential for normal fracture healing, because nerve induced a large, mechanically sufficient, fracture callus and the process of healing go normally until complete union occur. Controversial to this suggestion Eichenholt<sup>27</sup> said that the fractures probably unite through bridging callus, which without innervation will occur regardless of the degree of stability, in humans this phenomena is probably reflected by excessive callus formation in paraplegic patients, but the fracture callus showed delayed accumulation of calcium and incomplete maturation of woven new bone, as number of experimental studies suggest direct neuronal influence on local bone metabolism.

Conclusion: The denervation affects fracture healing negatively in rabbits so this obviously indicates that nerve injury in association with fracture should be considered and managed as soon as possible.

## References

- 1-Smith, W. S. & Dunsford, E. R. Jr. Healing of fractures in denervated limbs in rats. *Surg. Forum* (1955) 6, 559-562.
- 2-Reyes-Cunningham, A., Marquez-Monter, H., Guerrero, L. M. B. D., Flores-Martinez, A., Lopez-Nosthe, F. & Mejia, S. E. Estudio del callo óseo en extremidades denervadas. *Trabajo*
- 3-Frymoyer, J. W. & Pope, M. H. Fracture healing in the sciatically denervated rat. *J. Z'ruumu* (1977) 17, 355-361.
- 4-Aro, H., Eerola, E., Aho, A. J. & Penttinen, R. Healing of experimental fractures in the denervated limbs of the rat. *Clin. Orthop.* (1981) 155, 211-217.
- 5-Aro H. Developmental of non-union in rat fibula. *Chin Orthop Rel Res.* 1985; 292-299
- 6-Dyck et al. Neuropathy and recurring fracture with subclinical inherited neuropathy. *Neurology* 1983; 33-357.
- 7-Retief and Dreyer. Effect of neural damage on the repair of bony defect in rat. *Arch. Oral Biol* 1967; 12-1035
- 8-Nordsletten L, et al. The neuronal regulation of fracture healing. Effects of sciatic nerve resection in rat tibia. *Acta Orthop Scand.* 1994; 65:299-304.
- 9-Becker R.O. The significance of bioelectric potentials. *Bioelectrochem. Bioenerg.* 1974; 1:187-199
- 10-Aro, H., Eerola, E. & Aho, A. J. Fracture healing in paraplegic rat. *Acta orthopaedica Scand.* 1985, 56, 288- 232.
- 11-Herskovites ms et al. Effect of guanethidine-induced sympathectomy on osteoblastic activity in rat femur evaluated by H-proline autoradiography. *Acta anat.* 1984; 120; 151-155.
- 12-Madsen JE, et al. Neural involvement in post-traumatic osteopenia: an experimental study in the rat. *J Bone Miner Res.* 1996; 11:411-416.
- 13-Spencer RF. The effect of head injury on fracture healing, a quantitative assessment. *J Bone Joint Surg. (B)* 1987; 69:525-528.
- 14-Haarman HJ, Manoliu RA. The reliability of plain radiography in experimental fracture healing. *Skeletal Radiol.* 2001 Mar; 30(3):151-6
- 15-Kurak, G. Sonmez, B. Sarisozen et al. Histological assessment of alpha-tocopherol on fracture healing in rabbits. *International Medical Research.* 2003; 31:26-30.
- 16-Jaykaran Charan et al. How to calculate sample size in animal studies. *J Pharmacol Pharmacother.* 2013 Oct-Dec; 4(4): 303-306
- 17-Uthoff HK. Fracture healing. In Gustilo RB, Kyle RF, Templeman DC: *Fracture and dislocation.* St Louis, Mosby 1993.
- 18-Orr-HE et al. Assessment of ketamine anesthesia in the domestic rabbit. *Vet Anaesth Analg.* 2005 Sep; 32(5):271-9
- 19-Brown MJ, et al. Guidelines for animal surgery in research and teaching. *Am. J. Vet. Res.* 1993; 54:1544-1559.
- 20-Robbins S. L. *Pathological basis of disease,* Elsevier Inc. 7th edition, 2005, p 1288 - 1298.
- 21-Corrales LA, et al. Variability in the assessment of fracture-healing in orthopaedic trauma studies. *J Bone Joint Surg Am.* 2008; 90:1862-1868.
- 22-Bould M, et al. Digital image analysis: Improving accuracy and reproducibility of radiographic measurement. *Clin Biomech.* 1999; 14:434-437.
- 23-Aro H. et al. Effect of nerve injury on fracture healing. Callus formation studied in the rat. *Acta Orthop Scand* 1985; 56(3):233-7.
- 24-Wilson J W. Vascular supply to normal bone and healing fractures. *Seminars. Vet. Med. Surg (Small Animal)* 1991 Feb; 6 (I): 26-38.
- 25-Takashahi H. et al. Bone blood flow after spinal paralysis in the rat. *Orthopaedic surgery unrelated research.* 1990 8(31): 393-400.
- 26-Hukkanen M. et al. Rapid proliferation of calcitonin gene-related peptide-immunoreactive nerves during healing of rat tibial fracture suggests neural involvement in bone growth and remodeling. *Neuroscience* 1993; 54 (4): 069-70.
- 27-Eichenholtz. S N. Management of long-bone fractures in paraplegic patients. *J Bone Joint Surg (Am)* 1963; 45(2):299-310.