

Received: 24 February 2014 • Accepted: 09 March 2014



# A rare Case of Uterine Leiomyosarcoma in a Virgin Woman: a case report

Anisodowleh Nankali<sup>1</sup>, Farahnaz Keshavarzi<sup>2\*</sup>, Mina Ataee<sup>3</sup>

<sup>1</sup> Assistant professor, Obs&Gyn Department, Maternity Research Center, Imam Reza Hospital, Kermanshah University of Medical Sciences, Kermanshah, Iran

<sup>2</sup> Associate professor, Obs&Gyn Department, Maternity Research Center, Imam Reza Hospital, Kermanshah University of Medical Sciences, Kermanshah, Iran

<sup>3</sup> Senior resident of Obs&Gyn Department, Imam Reza Hospital, Kermanshah University of Medical Sciences, Kermanshah, Iran

\*correspondence should be addressed to Farahnaz Keshavarzi, Associate professor, Obs&Gyn Department, Maternity Research Center, Imam Reza Hospital, Kermanshah University of Medical Sciences, Kermanshah, Iran; Maternity Research Center, Kermanshah University of Medical Sciences, Imam Reza Kermanshah, Iran Hospital, Parastar Blvd, sorkhehLyjeh; Tell: +988314276309; Fax: +98; Email: [fkeshavarzi@yahoo.com](mailto:fkeshavarzi@yahoo.com).

## ABSTRACT

Leiomyosarcoma (LMS) compared to other types of uterine cancers is rare uterine malignancy with a very aggressive course and poor prognosis. We report confirmed histopathologically uterine leiomyosarcoma by IHC study in virgin woman. Case A: 58-year-old woman was admitted with a history of abdominal enlargement with 4-5 month duration of lower abdominal lump. Tumor marker CA-125 was raised. She underwent hysterectomy, bilateral salpingo-oophorectomy and resection of degenerated leiomyoma's. Conclusion: The gold standard of uterine leiomyosarcoma treatment is surgery. The prognosis of uterine leiomyosarcoma depends on the extent of disease at the time of diagnosis and the mitotic index in women.

**Key words:** Leiomyosarcoma, uterine, Virgin Woman

Copyright © 2014 Anisodowleh Nankali et al. This is an open access article distributed under the [Creative Commons Attribution License](https://creativecommons.org/licenses/by/4.0/).

## 1. INTRODUCTION

Uterine leiomyosarcoma (LMS) is an uncommon malignancy. The incidence is 0.67 per 100,000 in above 20 years old (1, 2), it represents 1-1.3% of all uterine malignancies (1-4) and about 5% of uterine sarcomas (1, 5, 6). LMS arises from the smooth muscle cells within the myometrium. Clinically, it is aggressive smooth muscle malignancy. 2% - 6% of uterine malignancies have poor prognosis and annual incidence is 1.7 per women (3). Uterine LMS can be usually seen during the fifth or sixth decades of life (7). Incidence of uterine LMS in surgical cases is less than 0.5 %. This risk is increased with age, so that in women older than 60 years is 1.7% (8). The most common clinical presentations in uterine LMS include uterine bleeding, pelvic pain and or pelvic mass (1-3, 9). Preoperatively, diagnose of uterine LMS is very difficult, even if diagnostic imaging and endometrial sample have been performed preoperatively. Frozen section is not always decisive intra operatively (1, 8). First, the diagnosis of LMS is established by a pathologist or after surgical removal of a presumed benign uterine mass (8, 10). Poorly known responsible factors for the initial neoplastic myometrial transformation, it is

assumed that each leiomyoma arises from a single cell in the myometrium (3, 11). LMS cases that are metastases, particularly to the lungs have been widely described. We report a case of LMS confirmed by biopsy in 58 years virgin woman. This patient did not have any history of uterine bleeding which is the usual in uterine sarcoma. This case was considered due to the rarity of the disease, and so this woman has ever married and its age is high.

## 2. The Case

A 58 years old postmenopausal virgin woman with a history of abdominal enlargement and 4-5 month duration of lower abdominal lump had referred to gynecology department of Imam Reza Hospital in kermanshah. She was deaf and not married. So, the history of disease was taken from her brother's wife. Symptoms include nausea, vomiting, constipation and satiety and pressure sensation in urinary tract. She weighed 5-6 Kg loss two month ago. She had no history of vaginal bleeding or abdominal pain. Abdominal examination showed an abdominal mass, As much as 26 weeks of gestational age. Her general physical examination was unremarkable. There was no hepato-

splenomegaly. The mass was tough. Ultra sonogram showed a large heterogeneous calcified well defined mass measuring 20\*16 cm in size in the right region of pelvis. We watched malignant tumor in right ovarian (Figure 1).

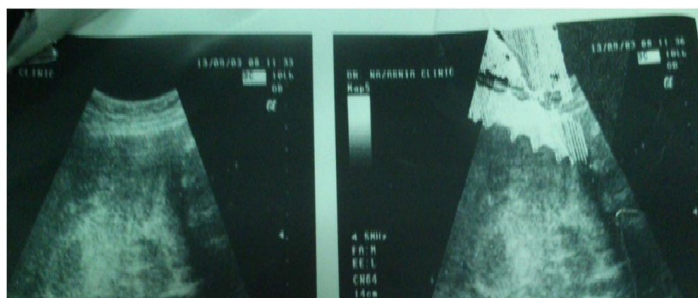

Figure 1. Trans abdominal sonogram of a pelvis revealing a large heterogeneous calcified well defined mass in the right region of pelvis

Other organs such as liver, spleen, and kidney were normal in sonography. Ascites was not found. CA-125 was 43ng/ml (0-35 ngr/ml). Other laboratory findings were normal. Clinical diagnosis was made for ovarian neoplasm and she was advised exploratory laparotomy (total abdominal hysterectomy and bilateral salpingo-oophorectomy (TAH+BSO). Bronchovascular marking was prominent in chest x ray. Total abdominal hysterectomy with BSO was performed by general anesthesia. Abdomen was opened by vertical midline incision. After opening the abdomen a hemorrhagic mass measuring 14cm in diameter attached to left posterior aspect of uterine fundus with a 4cm pedicle was found. Extending to the right side of abdomen was observed. Both ovaries and the fallopian tubes were normal. The degenerated subserosalmyoma was resected. In another intramural huge myoma (9cm) in diameter in the anterior body of uterus was also resected (figure2- 5).

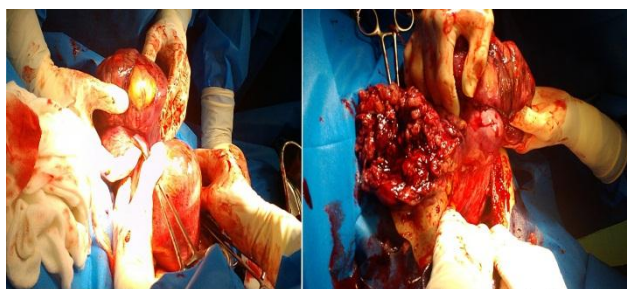


Figure2. Uterus pedunculated

Figure3. Lobulated mass arise from the

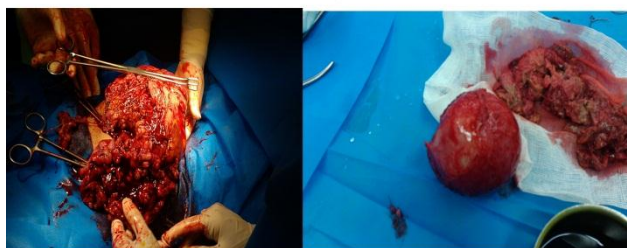

Figure4. Resection of myoma.

Figure5. Gross specimen of intramural myoma.

Both resected myoma sent for immediate pathological study. A total abdominal hysterectomy with bilateral salpingo-oophorectomy was performed by successive clamping. On the omentum did not show any tumor deposit. No suspected Para-

aortic lymph-node was palpated. The patient hospitalized for a week without any immediate post-operative complication .ten days after operation consequent results were shown; IHD study confirmed the diagnosis (Fig 6-9).

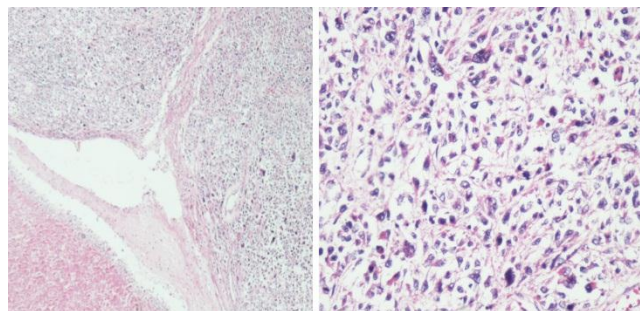


Figure6. LMS showing hypercellularity , Figure7. Hyper cellularity, pleomorphism and necrosis (X100)

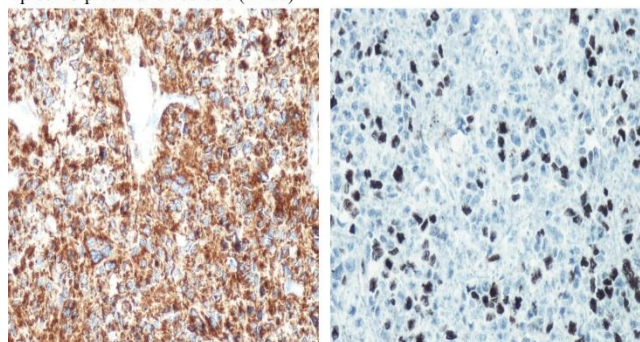


Figure8. SMA immunostaining showing positive staining in tumoral

Figure9. Ki-67 immunostaining showing positive nuclear staining in

### 3. DISCUSSION

Uterine (LMS) compared to other types of uterine cancers is rare uterine malignancy. LMS is an aggressive tumor associated with a high risk of recurrence and death, regardless of a stage at presentation (3, 12). In most cases the diagnosis of uterine (LMS) is made following hysterectomy (13, 14). In our case, after hysterectomy by permanent section was diagnosed. In rare cases it is diagnosed with endometrial sampling preoperatively or with frozen section. Frozen section did not suggest in the present case. Prognostic factor include tumor size > 5cm and a high mitotic index. These tumors are highly aggressive, with mitotic count of less than 2 per mm<sup>2</sup>. The most common mode of spread is hemotogenous, and lymphatic spread is rare. Recurrence is reported up to 70% in stage 1 and 2. Commonly, place of recurrence is lungs or upper abdomen (12, 15, 16). Liver, Abdomen, Pelvis and Pelvic or Para- aortic lymph nodes are other site of metastases (13, 17). Total hysterectomy is done for patient with LMS that in confined to the uterus at time of surgery (18, 19). Often, bilateral salpingo-oophorectomy (BSO) is performing at the time of total hysterectomy particularly for menopausal or premenopausal women. In women with confined disease to pelvis (stage 2) or the abdomen (stage 3), surgical cytoreduction is also performed. An optimal cytoreduction is associated with improved overall survival (14, 19). In women with metastatic disease extending beyond the peritoneal cavity there is no benefit to surgery (20). Pelvic lymphadenectomy is performed in women with enlarged pelvic nodes and extra uter-

ine disease (17, 21). In the present case palpable pelvic nodes were not found and omentum was free of tumor. Therefore, pelvic lymphadenectomy and omentectomy were not performed. Adjuvant radiation therapy has no impact on survival outcomes for woman with early stage LMS (22). In stage 3 or distant metastases (stage 4) that have undergone complete resection of disease; there is high risk of disease progression following surgery. Therefore adjuvant chemotherapy is offered by docetaxel and gemcitabine on a GOG trial (23). Due to the high risk of relapse, regardless of stage, for all women with early diagnosed LMS, surveillance examinations and imaging is required. Survival rates are dependent on the stage of disease at diagnosis (12, 24). Five-year survival rate is 50-55% for stage 1 year is 8-12% for stage 2-4 (15). The present case left the hospital after 1 week with no immediate post-operative complication.

#### 4. CONCLUSION

Uterine (LMS) compared to other types of uterine cancers is rare and aggressive uterine malignancy. Total hysterectomy and BSO is recommended for women with confined disease to the uterus pelvic. Lymphadectomy is limited to women with enlarged pelvic nodes. Prognosis for women with uterine (LMS) primarily depends on the extent of disease at the time of diagnosis and the mitotic index. Non randomized studies have reported improved survival after adjuvant chemotherapy. The value of pelvic radiation therapy has not been established.

#### REFERENCES

1. Schwartz LB, Diamond MP, Schwartz PE. Leiomyosarcomas: clinical presentation. American journal of obstetrics and gynecology. 1993;168(1 Pt 1):180-3.
2. Ola'h K, Kingston R. Uterine sarcoma. Progress in obstet gynecol Edinburg: Churchill Livingstone. 1994:427-49.
3. D'Angelo E, Prat J. Uterine sarcomas: a review. Gynecologic oncology. 2010;116(1):131-9.
4. Bennani O, Himmi A, Laghzaoui M, Aderdour M. [Uterine sarcoma. Apropos of 25 cases]. Revue francaise de gynecologie et d'obstetrique. 1995;90(1):12-6.
5. Friedrich M, Villena-Heinsen C, Mink D, Hell K, Schmidt W. Leiomyosarcomas of the female genital tract: a clinical and histopathological study. European journal of gynaecological oncology. 1997;19(5):470-5.
6. Scott JR, Gibbs RS, Karlan BY. Danforth's Obstetrics and Gynecology. 2005.
7. Tinelli A, Malvasi A, Hudelist G, Cavallotti C, Tsin DA, Schollmeyer T, et al. Laparoscopic intracapsular myomectomy: comparison of single versus multiple fibroids removal. An institutional experience. Journal of Laparoendoscopic & Advanced Surgical Techniques. 2010;20(8):705-11.
8. Leibsohn S, d'Ablaing G, Mishell Jr DR, Schlaerth JB. Leiomyosarcoma in a series of hysterectomies performed for presumed uterine leiomyomas. American journal of obstetrics and gynecology. 1990;162(4):968-76.

#### ACKNOWLEDGMENT

We would like to thank Dr. S.H. Madani, professor and head of department of pathology and Dr. H. Yarahmadi resident of pathology for providing histopathology slides of uterine liomyosarcoma.

#### AUTHORS CONTRIBUTION

This work was carried out in collaboration between all authors.

#### CONFLICT OF INTEREST

The authors declared no potential conflicts of interests with respect to the authorship and/or publication of this article.

9. Burkman RT. Management of the fibroid uterus (Reprinted from Advances in Obstetrics and Gynecology, vol 3, pg 103-27, 1996). MOSBY-YEAR BOOK INC 11830 WESTLINE INDUSTRIAL DR, ST LOUIS, MO 63146-3318 USA; 1998. p. 31-46.
10. Prayson RA, Hart WR. Pathologic considerations of uterine smooth muscle tumors. Obstetrics and gynecology clinics of North America. 1995;22(4):637-57.
11. Seddon BM, Davda R. Uterine sarcomas—recent progress and future challenges. European journal of radiology. 2011;78(1):30-40.
12. Denschlag D, Masoud I, Stanimir G, Gilbert L. Prognostic factors and outcome in women with uterine sarcoma. European Journal of Surgical Oncology (EJSO). 2007;33(1):91-5.
13. Giuntoli II RL, Metzinger DS, DiMarco CS, Cha SS, Sloan JA, Keeney GL, et al. Retrospective review of 208 patients with leiomyosarcoma of the uterus: prognostic indicators, surgical management, and adjuvant therapy☆. Gynecologic oncology. 2003;89(3):460-9.
14. Sagae S, Yamashita K, Ishioka S, Nishioka Y, Terasawa K, Mori M, et al. Preoperative diagnosis and treatment results in 106 patients with uterine sarcoma in Hokkaido, Japan. Oncology. 2004;67(1):33-9.
15. Salazar OM, Dunne ME. The role of radiation therapy in the management of uterine sarcomas. International Journal of Radiation Oncology\* Biology\* Physics. 1980;6(7):899-902.
16. Gadducci A, Sartori E, Landoni F, Zola P, Maggino T, Co-



- sio S, et al. The prognostic relevance of histological type in uterine sarcomas: a Cooperation Task Force (CTF) multivariate analysis of 249 cases. *European journal of gynaecological oncology*. 2001;23(4):295-9.
17. Leitao MM, Sonoda Y, Brennan MF, Barakat RR, Chi DS. Incidence of lymph node and ovarian metastases in leiomyosarcoma of the uterus. *Gynecologic oncology*. 2003;91(1):209-12.
18. Nassar O, Abdul MS, Khalil e-S, El-Taher M, El Najjar M. Outcome and prognostic factors of uterine sarcoma in 59 patients: single institutional results. *Journal of the Egyptian National Cancer Institute*. 2010;22(2):113-22.
19. Dinh TA, Oliva EA, Fuller Jr AF, Lee H, Goodman A. The treatment of uterine leiomyosarcoma. Results from a 10-year experience (1990–1999) at the Massachusetts General Hospital. *Gynecologic oncology*. 2004;92(2):648-52.
20. Park J-Y, Kim D-Y, Suh D-S, Kim J-H, Kim Y-M, Kim Y-T, et al. Prognostic factors and treatment outcomes of patients with uterine sarcoma: analysis of 127 patients at a single institution, 1989–2007. *Journal of cancer research and clinical oncology*. 2008;134(12):1277-87.
21. Goff BA, Rice LW, Flerschhacker D, Muntz HG, Falkenberry SS, Nikrui N, et al. Uterine leiomyosarcoma and endometrial stromal sarcoma: lymph node metastases and sites of recurrence. *Gynecologic oncology*. 1993;50(1):105-9.
22. Reed N, Mangioni C, Malmström H, Scarfone G, Poveda A, Pecorelli S, et al. Phase III randomised study to evaluate the role of adjuvant pelvic radiotherapy in the treatment of uterine sarcomas stages I and II: an European Organisation for Research and Treatment of Cancer Gynaecological Cancer Group Study (protocol 55874). *European Journal of Cancer*. 2008;44(6):808-18.
23. Hensley ML, Ishill N, Soslow R, Larkin J, Abu-Rustum N, Sabbatini P, et al. Adjuvant gemcitabine plus docetaxel for completely resected stages I–IV high grade uterine leiomyosarcoma: results of a prospective study. *Gynecologic oncology*. 2009;112(3):563-7.
24. Major FJ, Blessing JA, Silverberg SG, Morrow CP, Creasman WT, Currie JL, et al. Prognostic factors in early-stage uterine sarcoma: A gynecologic oncology group study. *Cancer*. 1993;71(S4):1702-9.