

---

**MAMMARY GLAND LYMPHOMA IN A 7-YEAR OLD GERMAN SHEPHERD BITCH**

---

**AJANI, Olumide Samuel, AGBUGBA, Linda Chinyere, BOLAJI-OLUTUNJI, Aanuoluwa Faith, HAMZAT, Abdulafees Ademola and AJALA, Oluwatoyin Oluwasola**

Department of Theriogenology, Faculty of Veterinary Medicine, University of Ibadan, Ibadan, Oyo State, Nigeria.

**Corresponding Author:** Ajani, O. S. Department of Theriogenology, Faculty of Veterinary Medicine, University of Ibadan, Ibadan, Oyo State, Nigeria. **Email:** [drqoforth09@yahoo.com](mailto:drqoforth09@yahoo.com) **Phone:** +234 803 808 7625

*Received May 08, 2023; Revised December 29, 2023; Accepted January 01, 2024*

---

**ABSTRACT**

*Mammary gland tumors are commonly observed in older, intact female dogs, while male dogs are rarely affected. The incidence of mammary gland tumors in dogs is significantly higher than in other domestic species, accounting for about 50% of tumor cases in dogs. A 7-year-old intact German Shepherd bitch was presented at the Veterinary Teaching Hospital, University of Ibadan, with swollen mammary glands and a history of conception failure, despite a successful mating a few months prior. Samples were collected using the fine needle aspirate technique from the swollen inguinal mammary glands and popliteal lymph nodes for cytological examination, which revealed confirmatory evidence suggestive of lymphoma. This article describes the mammary gland tumor in an adult intact bitch and her subsequent euthanasia due to tumor metastasis.*

**Keywords:** Mammary gland, Tumor, Lymphoma, Fine needle aspirate technique

---

**INTRODUCTION**

Lymphoma is a type of cancer that arises from lymphocytes, which are a type of white blood cell involved in the immune system's response. This group of blood and lymph tumors is commonly referred to as lymphoma, and it includes both non-malignant and malignant tumors. However, the term is typically used to describe only the cancerous versions of these tumors (Dorland, 2000). Breast tumors, on the other hand, result from abnormal cell growth in breast tissue, and they can be benign or cancerous. Mammary gland tumors are the most common neoplasia in female dogs, and their prevalence increases with age (Sorenmo, 2011). The development of mammary tumors in dogs is a complex process influenced by various factors, including hormonal exposure, aging and heredity.

Malignant breast tumors in dogs are typically detected by palpating one or more masses under the skin of the abdomen. These

masses may be found along the mammary chain adjacent to or inside the teat and vary in size and shape, but they are often hard and nodular (Vail and MacEwen, 2000). In rare cases, the skin over the mass may become infected, bleed and feel warm to the touch, and the affected area may also become painful. A discharge from the mammary gland may also occur (Lee *et al.*, 2008). It is essential to identify these clinical signs early to initiate prompt treatment and improve the outcome. Diagnostic techniques such as ultrasound and biopsy can aid in the early detection and diagnosis of malignant breast tumors (Gharekhanloo *et al.*, 2018).

Malignant breast tumors in dogs come in various forms, with carcinomas being the most prevalent. These tumors can arise from epithelial cells in the skin, mammary gland tubules, or other cells in the mammary chain (Akram *et al.*, 2017). Mammary gland lymphoma, a rare neoplasm, is a type of breast cancer that

develops in lymphocytes present in the mammary gland (Yoneyama *et al.*, 2021).

A case of mammary gland lymphoma in a dog presented to the Veterinary Teaching Hospital, University of Ibadan, Nigeria is presented in this study. Furthermore, the importance of early detection, diagnosis and appropriate treatment of mammary gland lymphoma in dogs is highlighted. Understanding the diverse forms of malignant breast tumors can help veterinary practitioners develop effective treatment plans and improve patient outcomes.

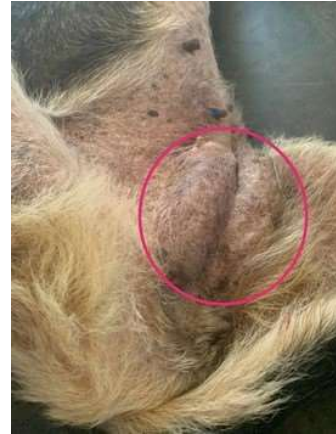### CASE DESCRIPTION

**Signalment and History:** On 12th December 2022, a 7-year-old German Shepherd weighing 21 kg was presented to the Veterinary Teaching Hospital (VTH) at the University of Ibadan, Oyo State, Nigeria. The owner complained of a swollen mammary gland a few months after a failed expected whelping. According to the owner's account, there had been no successful whelping since the last mating, despite it seeming to be successful. The patient's mammary gland had kept swelling, and the bitch had successfully whelped twice prior to the failed whelping (Figure 1). The owner also reported previous use of antibiotics.

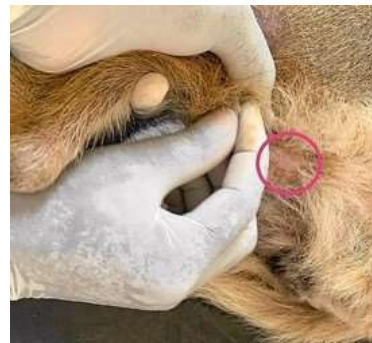

**Figure 1: A 7-year-old German Shepherd bitch as presented to the Veterinary Teaching Hospital**

**Physical Examination:** The patient exhibited dullness, anorexia and moderate cachexia. The bilateral inguinal mammary glands were markedly swollen, firm and warm to the touch (Figure 2). Additionally, the bilateral popliteal lymph nodes were swollen, with a consistency similar to that of the mammary gland (Figure 3).



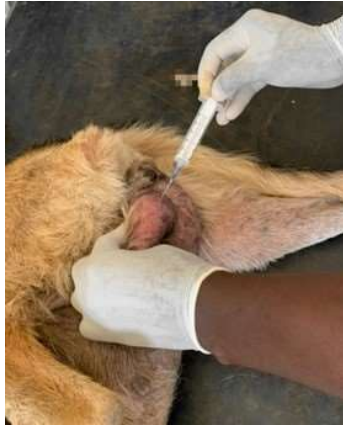**Figure 2: Swollen inguinal mammary gland of a 7-year-old German Shepherd bitch**



**Figure 3: Swollen Popliteal Lymph Node of a 7-year-old German Shepherd bitch**

The patient's body condition score was evaluated and scored 2/5. The mucous membrane appeared normal (pink) and the rectal temperature was 40°C. The heart and respiratory rates were within the normal range for the species, at 70 beats per minute (bpm) and 28 breaths per minute, respectively. A tentative diagnosis of mastitis and tumor was made and samples were collected for further laboratory investigation.

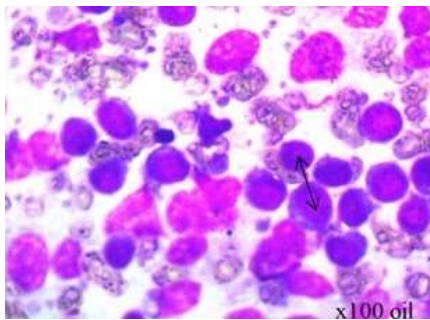
**Diagnostic Procedure:** Fine Needle Aspiration (FNA) technique was adopted to collect aspirates (Figure 4) from the swollen mammary gland and popliteal lymph node for cytology, microbial (bacterial) culture, and antibiotic sensitivity testing. This was done by cleaning the site of collection properly. Then a 25-gauge needle attached to 10 ml syringe was introduced into the gland for aspiration of the cells. Smears were made, fixed and stained. The slides were examined by the pathologists microscopically.



**Figure 4:** Fine needle aspiration of the inguinal mammary gland of a 7-year-old German Shepherd bitch

## RESULTS

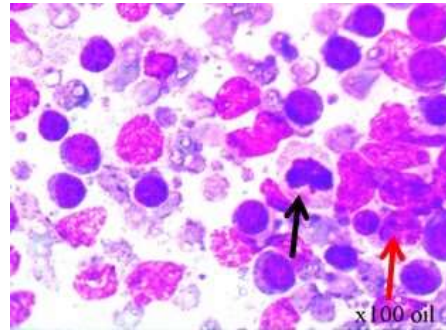
**Cytology Report:** The FNA smear from the mammary gland revealed numerous round cells with anisocytosis and cellular pleomorphism. The cells were typical of lymphoblasts, exhibiting mitosis, nuclear pleomorphism, and a high nuclear-cytoplasmic ratio, with a thin rim of bluish cytoplasm (Figure 5). Additionally, there were epithelial cells with hyperplastic features (Figure 6).



**Figure 5:** Micrograph of mammary gland aspirate smear. Round cells showing anisocytosis (double-head arrow) with thin basophilic cytoplasm

**Microbial Sensitivity:** The aspirate yielded no bacterial growth after 48 hours of incubation at 37°C.

**Lymphoma:** A confirmatory diagnosis indicated that the bitch had mammary gland lymphoma due to the metastasis of the tumour to the two popliteal lymph nodes.



**Figure 6:** Micrograph of mammary gland aspirate smear. Epithelial cells showing hyperplastic features (black arrow) and lymphocytes showing mitosis (red arrow)

## DISCUSSION

The incidence of mammary gland tumors in bitches is estimated to be 50% of all neoplasms, with about 40% of cases being malignant and 60% benign (Varma *et al.*, 2021). Although mammary benign mixed tumors occur frequently in dogs and are most often associated with a good prognosis, the risk of a bitch developing mammary tumors increases after each estrous cycle (Kumar *et al.*, 2021). The influence of pregnancy hormones, estrogen and progesterone, are essential in the physiological growth and tumorigenesis of the mammary gland, as they result in mammary gland development and hypertrophy (Sorenmo *et al.*, 2011). Spayed dogs are less likely to develop mammary cancers. An estimated 0.5% chance exists that a dog which has been spayed (ovariectomy or ovariectomy) before her first heat cycle may develop a mammary tumor. The likelihood of developing a mammary tumor would increase to 8% if the same dog was spayed after her first heat cycle. The likelihood of a mammary tumor forming in the same dog after two or more heat cycles is roughly 26% (Dobson, 2013). This fact may be attributed to the predisposition of the bitch presented in this report.

The average age predisposition is 7 to 12 years (Salas *et al.*, 2015). Depending on the breed, the tumor risk rises gradually each year and peaks between the ages of 11 and 13. Different breeds have been linked to an increased risk of breast cancer, but generally speaking, smaller breed dogs are more likely to be afflicted.

The larger breeds that are continuously overrepresented are the German Shepherd, English Springer Spaniel, Brittany Spaniel and English Setter. The fact that some breeds are more likely than others to develop mammary gland cancers suggests a hereditary element. However, a typical genetic mutation has not been reported (Sorenmo, 2011).

This case involves a 7-year-old bitch with multiple successful whelpings and no history of dystocia and prolonged pregnancy with a mammary gland tumor at the inguinal mammary gland pairs. Higher incidences of tumors at the inguinal mammary pairs have been recorded (Patel *et al.*, 2019), and these results have been corroborated with the higher gland volume and abundance of secretions at that region during lactation (Colleluori *et al.*, 2021).

Most dogs on presentation appear clinically healthy, and earlier studies showed that bitches with shorter durations of clinical signs have more aggressive tumors and a worse prognosis than dogs with longer clinical histories therapies (Gundim *et al.*, 2016; Edmunds *et al.*, 2023). The tumor type, size, involvement of local lymph nodes (lymph glands), presence or absence of distant metastases, completeness of resection, local behavior, vascular or lymphatic invasion and tumor differentiation all affect a dog's prognosis for malignant mammary tumors (Chang *et al.*, 2005). Treatment options including lumpectomy, ovariectomy, mastectomy have been recommended based on the study of Fossum *et al.* (2013), but in another study, the tumor was seen to reoccur and metastasize in one-third of all mammary tumor cases (Zappulli *et al.*, 2016; Vail *et al.*, 2019).

Breeder bitches are seven times more at risk of developing mammary cancers (Dobson, 2013). The increase incidence of mammary gland tumors will have serious economic implications for local dog breeders in Nigeria as bitches from age seven and above are predisposed to mammary tumors. Awareness needs to be raised amongst dog breeders and bitches approaching the ages of seven or eight should be dissuaded from been used for breeding.

The mammary gland tumor shares common features with humans, making dogs an excellent model for human breast cancer studies

in relation to cure and prognosis. Hence a further study on the dogs' mammary tumors should be done.

**Conclusion:** The cytology findings showed evidence of significant presence of atypical lymphoblasts in the mammary gland, characterized by marked anisocytosis, cellular pleomorphism, and high nuclear-cytoplasmic ratio. Additionally, hyperplastic epithelial cells were observed. The absence of bacterial growth in the microbial culture further supports the lymphomatous nature of the tumor. The confirmatory diagnosis establishes that the bitch was afflicted with mammary gland lymphoma, with metastasis to the popliteal lymph nodes, confirming the advanced stage of the disease. It is recommended that breeding of dogs in aged bitches should be discouraged. There is a need for increased awareness and education among pet owners and breeders regarding the predisposing factors of bitches to this condition. To mitigate the risks associated with breeding in aged bitches, it is advisable to encourage breeding in the early years after attaining sexual maturity.

## ACKNOWLEDGEMENTS

The authors appreciate the owner of the 7-year-old German Shepherd bitch for presenting the dog for diagnosis and treatment, and technical staff of the Veterinary Teaching Hospital (VTH), University of Ibadan, Oyo State, Nigeria, for their various contributions towards the success of this study.

## REFERENCES

- AKRAM, M., IQBAL, M., DANİYAL, M. and KHAN, A. U. (2017). Awareness and current knowledge of breast cancer. *Biological Research*, 50: 33. <https://doi.org/10.1186/s40659-017-0140-9>
- CHANG, S. C. CHANG, C. C. CHANG, T. J. and WONG, M. L. (2005). Prognostic factors associated with survival two years after surgery in dogs with malignant mammary tumors: 79 cases (1998–2002). *Journal of the American*

- Veterinary Medical Association*, 227(10): 1625 – 1629.
- COLLELUORI, G. PERUGINI, J. BARBATELLI, G. and CINTI, S. (2021). Mammary gland adipocytes in lactation cycle, obesity and breast cancer. *Reviews in Endocrine and Metabolic Disorders*, 22(2): 241 – 255.
- DOBSON, J. M. (2013). Breed-predispositions to cancer in pedigree dogs. *International Scholarly Research Notices Veterinary Science*, 2013: 941275. <http://dx.doi.org/10.1155/2013/941275>
- DORLAND, N. W. (2000). *Dorland's Illustrated Medical Dictionary*. 29<sup>th</sup> Edition, W. B. Saunders, Philadelphia, USA.
- EDMUNDS, G., BECK, S., KALE, K. U., SPASIC, I., O'NEILL, D., BRODBELT, D. and SMALLEY, M. J. (2023). Associations between dog breed and clinical features of mammary epithelial neoplasia in bitches: an epidemiological study of submissions to a single diagnostic pathology centre between 2008–2021. *Journal of Mammary Gland Biology and Neoplasia*, 28(1): 6. <https://doi.org/10.1007%2Fs10911-023-09531-3>
- FOSSUM, T. W., DUPREY, L. P. and HUFF, T. G. (2013). Surgery of reproductive and genital systems. In: FOSSUM, T. W. (Ed.). *Small Animal Surgery*. 5<sup>th</sup> Edition, St. Louis, Mosby, Maryland Heights, Missouri, USA.
- GHAREKHANLOO, F., HASELI, M. M. and TORABIAN, S. (2018). Value of ultrasound in the detection of benign and malignant breast diseases: a diagnostic accuracy study. *Oman Medical Journal*, 33(5): 380 – 386.
- GUNDIM, L. F., DE ARAUJO, C. P., BLANCA, W. T., GUIMARÃES, E. C. and MEDEIROS, A. A. (2016). Clinical staging in bitches with mammary tumors: Influence of type and histological grade. *Canadian Journal of Veterinary Research*, 80(4): 318 – 322.
- KUMAR, S. PUNIA, S. KUMAR, R. and KUMAR, P. (2021). Surgical management of mammary tumor in a she-dog. *The Pharma Innovation Journal*, SP-10(11): 2205 – 2207.
- LEE, Y. K., SUH, G. H. and LEE, C. Y. (2008). Inflammatory mammary carcinoma in a dog. *Journal of Veterinary Clinics*, 25(5): 405 – 407.
- PATEL, M. P. GHODASARA, D. J. RAVAL, S. H. and JOSHI, B. P. (2019). Incidence, gross morphology, histopathology and immunohistochemistry of canine mammary tumors. *Indian Journal of Veterinary Sciences and Biotechnology*, 14(4): 40 – 44.
- SALAS, Y. MÁRQUEZ, A. DIAZ, D. and ROMERO, L. (2015). Epidemiological study of mammary tumors in female dogs diagnosed during the period 2002-2012: a growing animal health problem. *PloS One*, 10(5): e0127381. <https://doi.org/10.1371/journal.pone.0127381>
- SORENMO, K. U. (2011). *Canine Mammary Tumors: Clinical Features, Diagnostics and Staging*. World Small Animal Veterinary Association (WSAVA), World Congress Proceedings 2011. <https://www.vin.com/apputil/content/defaultadv1.aspx?pId=11343&catId=34576&id=5124313>
- SORENMO, K. U. RASOTTO, R. ZAPPULLI, V. and GOLDSCHMIDT, M. H. (2011). Development, anatomy, histology, lymphatic drainage, clinical features, and cell differentiation markers of canine mammary gland neoplasms. *Veterinary Pathology*, 48(1): 85 – 97.
- VAIL, D. M. and MACEWEN, E. G. (2000). Spontaneously occurring tumors of companion animals as models for human cancer. *Cancer Investigation*, 18(8): 781 – 792.
- VAIL, D. M., THAMM, D. H. and LIPTAK, J. M. (2019). Hematopoietic tumors. In: VAIL, D. M., THAMM, D. H. and LIPTAK, J. M. (Eds.). *Withrow and MacEwen's Small Animal Clinical Oncology*. 6<sup>th</sup> Edition, W. B. Saunders, Philadelphia, USA.
- VARMA, C. G. TEJA, A. and LAVANYA, K. (2021). Assessment of risk factors for incidence of canine mammary tumors. *The Pharma Innovation Journal*, 10(5): 554 – 556.
- YONEYAMA, K., NAKAGAWA, M. and HARA, A. (2021). Primary lymphoma of the breast: A case report and review of the

literature. *Radiology Case Reports*,  
16(1): 55 – 61.  
ZAPPULLI, V., RASOTTO, R., CALIARI, D.,  
MAINENTI, M. and PEÑA, L. (2016).

Clinical and pathological prognostic  
factors in canine mammary tumors: a  
review. *Veterinary Pathology*, 53(5):  
1020 – 1034.



This article and articles in *Animal Research International* are Freely Distributed Online and Licensed under a [Creative Commons Attribution 4.0 International License \(CC-BY 4.0\)](https://creativecommons.org/licenses/by/4.0/) <https://creativecommons.org/licenses/by/4.0/>