



Diagnostic Accuracy of the Liver Imaging Reporting and Data System (LI-RADS 2018) in Diagnostic of Hepatocellular Carcinoma in Cirrhosis Patients, Chronic Hepatitis B Carrier Patient, Prior Hepatocellular Carcinoma Patient and Treated Hepatocellular Carcinoma Patient Compared with Histopathological Report

Monthanee Puengphong MD¹

Krongkan Kanchanarat MD^{1*}

¹ Department of Radiology, Faculty of Medicine Vajira Hospital, Navamindradhiraj University, Bangkok, Thailand

* Corresponding author, e-mail address: krongkan@nmu.ac.th

Vajira Med J. 2022; 66(2): 103-14

<http://dx.doi.org/10.14456/vmj.2022.11>

Abstract

Objective: To evaluate the accuracy of the Liver Imaging Reporting and Data System (LI-RADS) version 2018 category 5 in magnetic resonance imaging (MRI) for the diagnosis of hepatocellular carcinoma

Methods: This retrospective study included patients who underwent liver MRI and had proven pathological lesion. From 2012 to 2021, 45 patients (52 observations including 29 HCCs) met the inclusion criteria. Two radiologists independently reviewed hepatic observation and assessed the LI-RADS version 2018 category. The diagnosis performances of LI-RADS 3, LI-RADS 4, and LI-RADS 5 were calculated using the generalized estimating equation method.

Results: A total of 45 patients (mean age, 59.8) with 52 lesions, including 26 men and 19 women met the inclusion criteria. Most lesions were HCC, 29 (55.8%). The highest sensitivity of the major feature for HCC diagnosis was non-rim arterial enhancement (93%). The highest specificity of the major feature for HCC diagnosis was capsule appearance (100%). The highest accuracy of the major feature for diagnosis was non-rim peripheral washout (86.6%). The inter-observer agreement between the two readers in the classification of lesions was perfect for the Liver Imaging Reporting and Data System (LI-RADS) classification ($k = 0.868$) and almost perfect for LI-RADS with AF classification ($k = 0.872$). The LI-RADS 5 sensitivities were 82.8% and 79.3% (as R1, R2) with the same value when combined with ancillary findings. The accuracy of L5 of LI-RADS 2018 was 87.5% (same value with ancillary findings) and 83.3% (same value with ancillary findings) in R1 and R2, respectively.

Conclusion: The LI-RADS version 2018 category 5 has high sensitivity, specificity, and accuracy in the diagnosis of HCC.

Keywords: LIRAD, LIRAD version 2018, HCC



ความถูกต้องในการใช้ liver imaging reporting and data system ฉบับ 2018 (LI-RADS version 2018) ในการวินิจฉัยมะเร็งตับ ในผู้ป่วยที่มีภาวะตับแข็ง, ผู้ป่วยที่มีภาวะพาหะตับอักเสบเรื้อรัง, ผู้ป่วยที่เคยเป็นมะเร็งตับมาก่อนและรักษาแล้ว จากภาพเอกซเรย์ สนามแม่เหล็กไฟฟ้า เปรียบเทียบกับผลชิ้นเนื้อ

มณฑิณี พึ่งพงษ์ พ.บ.¹

กรองกาญจน์ กาญจนรัตน์ พ.บ.^{1*}

¹ ภาควิชารังสีวิทยา คณะแพทยศาสตร์วชิรพยาบาล มหาวิทยาลัยนวมินทราธิราช กรุงเทพมหานคร ประเทศไทย

* ผู้ติดต่อ, อีเมล: krongkan@nmu.ac.th

Vajira Med J. 2022; 66(2): 103-14

<http://dx.doi.org/10.14456/vmj.2022.11>

บทคัดย่อ

วัตถุประสงค์: ประเมินความแม่นยำของ LI-RADS ฉบับ 2018 ระดับ 5 ในภาพคลื่นสนามแม่เหล็กไฟฟ้าในการวินิจฉัย มะเร็งตับ

วิธีดำเนินการวิจัย: เป็นการศึกษาย้อนหลัง ผู้ป่วยที่ได้รับการตรวจภาพรังสีวินิจฉัยสนามแม่เหล็กไฟฟ้าของตับ และมีรอยโรคทางพยาธิวิทยาที่พิสูจน์แล้วตั้งแต่ปี ค.ศ. 2012 to 2021 จำนวน 45 คน (52 รอยโรค, มะเร็งตับ 29 รอยโรค) รังสีแพทย์ 2 คนประเมินระดับของ LI-RADS ฉบับ 2018 ในแต่ละรอยโรค ผลวินิจฉัย LI-RADS ระดับ 3 ถึง 5 คำนวณโดยใช้ generalized estimating equation method.

ผลการวิจัย: ผู้ป่วย 45 คน (อายุเฉลี่ย 59.8 ปี) 52 รอยโรค ชาย 26 คน, หญิง 19 คน ส่วนใหญ่ของรอยโรคเป็นมะเร็งตับ, 29 (ร้อยละ 58.8) Major feature ที่มีความไวสุดในการวินิจฉัยมะเร็งตับ คือ non-rim arterial enhancement (ร้อยละ 93) Major feature ที่มีความจำเพาะสุดในการวินิจฉัยมะเร็งตับคือการมี capsule (ร้อยละ 100) Major feature ที่มีความแม่นยำสุดในการวินิจฉัยมะเร็งตับ คือ non-rim peripheral washout (ร้อยละ 86.6). Inter-observer agreement ของรังสีแพทย์ 2 คนในการจำแนกรอยโรคโดยใช้ LI-RADS ฉบับ 2018 มีความสมบูรณ์แบบ (k = 0.868) และเกือบจะสมบูรณ์แบบเมื่อร่วมกับ ancillary findings (k = 0.872) ความไวของ LI-RADS ฉบับ 2018 ระดับ 5 ในการวินิจฉัย HCC เท่ากับ ร้อยละ 82.8 และ ร้อยละ 79.3 (รังสีแพทย์คนที่ 1, 2) โดยมีค่าเดียวกันเมื่อใช้ร่วมกับ ancillary findings ความแม่นยำของ LI-RADS ฉบับ 2018 ระดับ 5 ในการวินิจฉัยมะเร็งตับเท่ากับ ร้อยละ 87.5 และ ร้อยละ 83.3 (รังสีแพทย์คนที่ 1, 2) โดยมีค่าเดียวกันเมื่อใช้ร่วมกับ ancillary findings

สรุป: LI-RADS ฉบับ 2018 ระดับ 5 มีความไวและความแม่นยำสูงในการวินิจฉัยมะเร็งตับ

คำสำคัญ: LIRAD, LI-RADS ฉบับ 2018, มะเร็งตับ

Introduction

In 2020, liver cancer was the sixth leading cause of death globally (30160 individuals), in which the most common cause was lung cancer (135,720 individuals)¹. The most frequent primary malignant tumor of the liver is hepatocellular carcinoma (HCC), which is the second leading cause of cancer-related death globally². Hepatitis B and C viruses (HBV and HCV) are the important risk factors for HCC development and account more than 80% of HCC cases worldwide³. In a cancer institute in Thailand, in 2013–2015, the incidence of liver cancer was 33.9% in men and 12.9% in women. In 2018, liver cancer was noted in 18.2% of all cancers in men, which was the second most common cancer after colonic cancer (19.7%). In women, liver cancer was noted in 4.4% which was the sixth most common cancer in women⁴. Liver cancer is divided into three types: 1. Hepatocellular carcinoma (HCC), which is caused by the liver cell and is the most common, more than 80% of all liver cancers 2. Intrahepatic bile duct cancer, which is the most common liver cancer in northeast Thailand and caused by liver fluke and 3. other liver cancer types, such as lymphoma, angiosarcoma, and metastatic liver cancer.

To date, imaging, particularly multiphasic contrast-enhanced CT and MRI, is critical in the diagnosis of HCC. In high-risk patients, hepatocellular carcinoma (HCC) is the only primary malignancy that can be identified with imaging alone, without the need for pathologic confirmation. As a result, acceptable imaging criteria for noninvasive HCC diagnosis are critical.

The LI-RADS is a classification system for liver lesion that is used in patients with liver cirrhosis and hepatitis B carriers because these patients are at higher risk of HCC. The LI-RADS category indicates the probability of HCC which is based on typical CT and MRI findings. However the LI-RADS is not used in

patients aged less than 18 years or those with cirrhosis due to congenital fibrosis or vascular disorder because these groups of patients have low risk of developing HCC. The LI-RADS was introduced in 2011 and has been upgraded four times since then: 2013, 2014, 2017, and 2018. In our study, we used LI-RADS version 2018, which has two revised points: 1. Threshold growth definition was simplified to greater than or equal to 50% increase in the size of a mass in less than or equal to 6 months, in which the rationale is simply to achieve concordance with the definition advocated by the American Association for the Study of Liver Diseases (AASLD) and Organ Procurement and Transplantation Network (OPTN). Now, AASLD, OPTN, and LI-RADS have the same definition for threshold growth. 2. LI-RADS 2018 category 5 (LR5) criteria were revised to match those advocated by the AASLD. The -g and -us designations were eliminated for simplicity.

The rationale is simple. It has closer concordance with AASLD and OPTN criteria. Presently, LI-RADS and AASLD have the same criteria for definite HCC, and LI-RADS and OPTN have almost identical criteria for HCC with one exception: 10–19 mm + arterial phase hyperenhancement (APHE) + non peripheral washout = LR5 but does not meet OPTN class 5 criteria⁵.

A study of 70 patients from China (2020) by Shuo et al. found that the use of LR5 had 94% sensitivity for HCC⁶. A systematic review by Lee et al. from Korea (2020), with a total of 14 studies and 1841 HCC lesions, using LR5 showed 70% sensitivity for HCC (95% CI, 61–78), LR4 had 64% sensitivity for HCC (95% CI, 47–80), and LR3 had 31% sensitivity for HCC (95% CI, 12–50)⁷. The used of LI-RADS version 2018 criteria, which were referenced from two studies from China and Korea, revealed the difference in sensitivity. Moreover, the faculty of Medicine Vajira Hospital had performed MRI of a patient with suspected liver cancer since 2010.

Until now, hepatobiliary specific contrast agent for increased MRI detection of focal liver lesion and LI-RADS had never been used in the diagnosis of liver cancer in these patients. Therefore, we aimed to evaluate the accuracy of LR5 in the diagnosis of HCC compared with histopathological report.

Methods

Study population

This retrospective study was approved by the institutional review board of our institution and performed at a tertiary academic medical center. Informed consent was waived due to the retrospective nature of medical records and imaging. We searched the electronic medical record of our institution from 2012 to 2021. We found 84 patients with cirrhosis, chronic hepatitis B carrier, prior hepatocellular carcinoma and treated hepatocellular carcinoma underwent MRI study. Finally we identified 45 patients who met the inclusion criteria. The inclusion criteria were as follows: 1) The population underwent MRI with hepatobiliary specific contrast agent for suspected liver lesion. 2) The patient who had cirrhosis, chronic hepatitis B, previous HCC, and treated HCC underwent MRI. 3) All patients had tissue pathological report. 4) All patients underwent AFP blood test. The exclusion criterion was that the patient did not receive surgery.

Definition

The LI-RADS categories were as follows: LI-RADS 1, definitely benign; LI-RADS 2, probably benign; LI-RADS 3, intermediate probability; LI-RADS 4, probably HCC; LI-RADS 5, definitely HCC, LI-RADS TIV, and LI-RADS M. Five major features are typically observed in HCC in patients with liver cirrhosis and chronic HBV infection: 1. arterial phase hyperenhancement (APHE), 2. nonperipheral washout, 3. capsule, 4. size, 5. threshold growth. There are also ancillary features that are helpful

in the detection, improvement, and increased confidence in the diagnosis of HCC. Ancillary features that favor HCC are non-enhancing capsule, nodule within nodule, mosaic structure, blood product in mass, and fat in mass. Ancillary features that favor malignancy (not HCC) are restriction diffusion, mild-moderate T2 hyperintensity, coronal enhancement, fat sparing in solid mass, iron sparing in solid mass, transitional phase hypointensity, and hepatobiliary phase hypointensity. Ancillary features that favor benignity are parallel blood pool, undistorted vessels, higher iron level in the mass than in the liver, marked T2 hyperintensity, and hepatobiliary phase isointensity⁵.

MRI

Dynamic contrast-enhanced MRI of the liver was performed with 1.5 or 3.0 Tesla using 0.1 mL/kg or 10 mL of gadoxetate disodium (Primovist). The injection rate was 1 mL/s, followed by 10–20 mL of NSS. MRI technique are T1-weighted imaging (in phased and opposed phase), T2-weighted imaging, diffusion weighted imaging (DWI), and apparent diffusion coefficient imaging. Dynamic imaging was performed at 25, 75, and 120 s. Hepatobiliary phase was applied at 3,5,10, and 20 min.

Imaging review

The MR images were reviewed on Picture Archiving and Communication System (PACS) by two radiologists with 10 years' and 8 years' experience. The two radiologists were blinded to the histopathological report, but they aware of the purpose of the study. The patient's age, sex, AFP level, and histopathological report were collected by one radiologist and shared with the other. They reviewed the presence of major and ancillary features of the observation.

The major features were as follows: 1) arterial phase hyperenhancement, which were categorized as < 10 mm, 10–19 mm, and \geq 20 mm, 2) nonperipheral washout area, 3) presence of capsule, and 4) threshold growth. The threshold growth was not accessed in our study because only one review was evaluated per patient. If the observation enhancement was not arterial phase hyperenhancement, they were arterial phase hypoenhancement or isoenhancement, which were categorized as <20 mm and \geq 20 mm, respectively. The ancillary findings favored HCC, malignancy (not HCC), and benignity. 1) Findings that favored HCC are nonenhancing capsule, nodule within nodule, mosaic structure, blood product in the mass, and fat in mass. 2) Findings that favored malignancy (not HCC) are restriction diffusion, mild–moderate T2 hyperintensity, coronal enhancement, fat sparing in solid mass, iron sparing in solid mass, transitional phase hypointensity, and hepatobiliary phase hypointensity. 3) Findings that favored benignity are parallel blood pool, undistorted vessels, higher iron level in the mass than in the liver, marked T2 hyperintensity, and hepatobiliary phase isointensity. The LI-RADS category was assessed using CT/MRI diagnostic table⁵. The ancillary findings were applied as follows:⁵ If ancillary findings favored malignancy, upgrade by 1 category to LR4; however, absence of these ancillary findings should not be used to downgrade. If ancillary findings favored benignity, downgrade by 1 category; however absence of these ancillary findings should not be used to upgrade. If ancillary findings favored malignancy and ancillary findings favored benignity, do not adjust category. Moreover, the ancillary findings features cannot be used to upgrade to LR5.

Statistical analysis

The patients and lesion characteristic data were summarized using descriptive statistics. Continuous data are presented as mean \pm standard deviation or median range, and categorical data are presented as frequency and percentage. Diagnostic performance values were reported as sensitivity, specificity, positive predictive value, negative predictive value, and accuracy. The chi-square test was used to analyze the association between AFP and HCC. Inter-observer agreement between the two readers was evaluated using Cohen's kappa with 95% confidence intervals. Agreement level was interpreted as slight (kappa = 0.01–0.20), fair (kappa= 0.21–0.40), moderate (kappa = 0.41–0.60), substantial (kappa = 0.61–0.80), or almost perfect or perfect (kappa = 0.81–1.00). A P-value < 0.05 was considered statistically significant. Analyses were performed using PASW Statistics (SPSS) 18.0 (SPSS Inc., Chicago, IL, USA). To interpret the Cohen's kappa results, refer to the following guidelines (see Landis, JR & Koch, GG (1977). The measurement of observer agreement for categorical data. *Biometrics*, 33, 159-174).

Results

A total of 45 patients (mean age, 59.8 \pm 13.7 years; range, 30–90 years) with 52 lesions, including 26 (57.8%) men and 19 (42.2%) women, were selected for the analysis. The median AFP level of the lesion was 5.8 ng/mL (range, 1–12, 174 ng/mL). Most of the 52 lesions were HCCs (55.8%). The other lesions were cholangiocarcinoma (1, 1.9%), focal nodular hyperplasia (3, 5.8%), fibrosis (1, 1.9%), hemangioma (3, 5.8%), hepatitis (3, 5.8%), metastases (1, 1.9%), and others (11, 21.2%). The other lesions were fatty liver(2), cirrhosis, granuloma(2), hepatic adenoma(2), hepatic lymphoma(2), EBV infection, cirrhotic nodule. Regarding the association between AFP and HCC, the proportion of HCC was 93.3% in

patients with AFP level > 10 ng/mL and 38.5% in patients with AFP level ≤ 10 ng/mL. Thus, there was a statistically significant association between AFP level and HCC (P = 0.001). Regarding the frequencies of HCC and non-HCC by LI-RADS classification and LI-RADS with AF classification in the two readers, when major features were reviewed by reader 1, HCC was diagnosed in 1 of 8 (12.5%) LR3 lesions, 4 of 15 (26.7%) LR4, and 24 of 25 (96%) of LR5. Moreover, when the major features and AF were combined, HCC was diagnosed in 0 of 4 (0.0%) LR3 lesions, 5 of 19 (26.2%) of LR4, and 24 of 25 (96%) of LR5. The percentage of HCC in reader 2 for categories LR3, LR4, and LR5 were 22.2%, 28.6%, and 92%, respectively, for LI-RADS classification and 0%, 31.6%, and 92% for LI-RADS with AF classification. Regarding diagnostic performance for each major feature finding, sensitivity of major feature for diagnosis of HCC ranged from 7.1% to 93.3% and was highest for non-rim arterial enhancement. The specificity of major feature ranged from 17.4% to 100.0% and was highest for capsule appearance. Positive predictive value ranged from 18.2% to 100.0% and was highest for capsule appearance. Negative predictive value ranged from 29.7% to 100.0% and was highest for enhancement. Accuracy ranged from 27.1% to 86.6% and was highest for non-rim peripheral washout. The two readers' agreement in major finding ranged from substantial to perfect agreement (Kappa = 0.78 to 1.00). The percentage of diagnosis of HCC in the ancillary feature favored HCC was 100% HCC in both readers 1 and 2, which was highest for non-enhancing capsule (90% in Reader 1 and 77.8% in Reader 2). The percentages of diagnosis of HCC in the ancillary feature in favor of malignancy (not HCC) were 59.2% in reader 1 and 62.2% in reader 2, while other malignancies were 4% and 4.4% in reader 1 and reader 2. No LR M and LR TIV were categorized in our study as one metastasis was categorized as LR5 and another one

of cholangiocarcinoma was categorized as LR4. As a study of 70 patients from China (2020) by Shuo et al. found that LI-RADS 2018 category 5 (LR5) had 94% sensitivity for HCC⁶ and a systematic review by Lee et al from Korea (2020)⁷ in which the LR5 had 70% sensitivity in the diagnosis of HCC (95%, 61–78), LR4 had 64% sensitivity (95% CI, 47–80), LR3 had 31% sensitivity (95%CI, 12–50).

Our study revealed that, in LI-RADS 2018, LR5 had sensitivity of 82.8% and 79.3% in diagnosis of HCC (as R1, R2) with the same sensitivity when combined with ancillary findings (82.8%, 79.3%) and specificity 94.7% and 89.5% in diagnosis of HCC (as R1, R2) and the same specificity when combined with ancillary findings as 94.7% and 89.5%, respectively (Table 1).

In our result study, in LI-RADS 2018, LR5 sensitivity was 82.8% and 79.3% (as R1, R2) and the same value when combined with ancillary findings. This value was between the sensitivity of 70% of a systematic review by Lee et al.⁷ and sensitivity of 94% of Shao et al⁶. The accuracy of L5 of LI-RADS 2018 was 87.5% (same value with ancillary findings) and 83.3% (same value with ancillary findings) in R1 and R2, respectively.

LR4 had sensitivity of 13.8% (17.2% with AF), 13.8% (20.7% with AFs) in R1 and R2 and had specificity of 42.1% (26.3% with AFs) and 47.4% (31.6% with AF) in R1 and R2, respectively. The accuracies of LR4 in diagnosis HCC were 25% (20.8% with AF) and 27.1% (25% with AF) in R1 and R2 (Table 2). LR3 had sensitivity of 3.4% (0% with AF) and 6.9% (0% with AF) and had specificity 63.2% (79% with AF) and 63.2% (79% with AF) in R1 and R2, respectively. The accuracy of LR3 was 27.1% (31.3% with AF) and 29.3% (31.3% with AF) in R1 and R2 (Table 3). The inter-observer agreement between the two readers in the categorical classification of lesions was perfect for the LI-RADS classification (kappa = 0.868; 95% CI, 0.735–1.000) and almost perfect for LI-RADS with AF classification (kappa = 0.872; 95%CI, 0.747–0.997).

Table 1:

Diagnostic performance of LI-RADS5 and LI-RADS5 with AF

Parameter	Reader1		Reader2	
	LI-RADS5	LI-RADS5 with AF	LI-RADS5	LI-RADS5 with AF
True positive	24	24	23	23
False negative	5	5	6	6
False positive	1	1	2	2
True negative	18	18	17	17
Sensitivity, % (95% CI)	82.8% (64.2%, 94.2%)	82.8% (64.2%, 94.2%)	79.3% (60.3%, 92.0%)	79.3% (60.3%, 92.0%)
Specificity, % (95% CI)	94.7% (74.0%, 99.9%)	94.7% (74.0%, 99.9%)	89.5% (66.9%, 98.7%)	89.5% (66.9%, 98.7%)
Positive predictive value, % (95% CI)	96.0% (78.0%, 99.4%)	96.0% (78.0%, 99.4%)	92.0% (75.4%, 97.7%)	92.0% (75.4%, 97.7%)
Negative predictive value, % (95% CI)	78.3% (61.7%, 89.0%)	78.3% (61.7%, 89.0%)	73.9% (57.8%, 85.5%)	73.9% (57.8%, 85.5%)
Accuracy, % (95% CI)	87.5% (74.8%, 95.3%)	87.5% (74.8%, 95.3%)	83.3% (69.8%, 92.5%)	83.3% (69.8%, 92.5%)

Table 2:

Diagnostic performance of LI-RAD4 and LI-RAD4 with AF

Parameter	Reader1		Reader2	
	LI-RAD4	LI-RAD4 with AF	LI-RAD4	LI-RAD4 with AF
True positive	4	5	4	6
False negative	25	24	25	23
False positive	11	14	10	13
True negative	8	5	9	6
Sensitivity, % (95% CI)	13.8% (3.9%, 31.7%)	17.2% (5.9%, 35.8%)	13.8% (3.9%, 31.7%)	20.7% (8.0%, 39.7%)
Specificity, % (95% CI)	42.1% (20.3%, 66.5%)	26.3% (9.2%, 51.2%)	47.4% (24.5%, 71.1%)	31.6% (12.6%, 56.6%)
Positive predictive value, % (95% CI)	26.7% (11.9%, 49.4%)	26.3% (13.3%, 45.3%)	28.6% (12.8%, 52.2%)	31.6% (17.5%, 50.1%)
Negative predictive value, % (95% CI)	24.2% (15.6%, 35.6%)	17.2% (8.8%, 31.0%)	26.5% (18.0%, 37.2%)	20.7% (11.6%, 34.2%)
Accuracy, % (95% CI)	25.0% (13.6%, 39.6%)	20.8% (10.5%, 35.0%)	27.1% (15.3%, 41.9%)	25.0% (13.6%, 39.6%)

Table 3:

Diagnostic performance of LI-RADS3 and LI-RADS3 with AF

Parameter	Reader1		Reader2	
	LI-RADS3	LI-RADS3 with AF	LI-RADS3	LI-RADS3 with AF
True positive	1	0	2	0
False negative	28	29	27	29
False positive	7	4	7	4
True negative	12	15	12	15
Sensitivity, % (95% CI)	3.4% (0.1%, 17.8%)	0.0% (0.0%, 11.9%)	6.9% (0.9%, 22.8%)	0.0% (0.0%, 11.9%)
Specificity, % (95% CI)	63.2% (38.4%, 83.7%)	79.0% (54.4%, 94.0%)	63.2% (38.4%, 83.7%)	79.0% (54.4%, 94.0%)
Positive predictive value, % (95% CI)	12.5% (1.9%, 51.7%)	0.0% (0.0%, 60.2%)	22.2% (6.2%, 55.2%)	0.0% (0.0%, 60.2%)
Negative predictive value, % (95% CI)	30.0% (23.2%, 37.8%)	34.1% (29.1%, 39.5%)	30.8% (23.7%, 38.9%)	34.1% (29.1%, 39.5%)
Accuracy, % (95% CI)	27.1% (15.3%, 41.9%)	31.3% (18.7%, 46.3%)	29.2% (17.0%, 44.1%)	31.3% (18.7%, 46.3%)

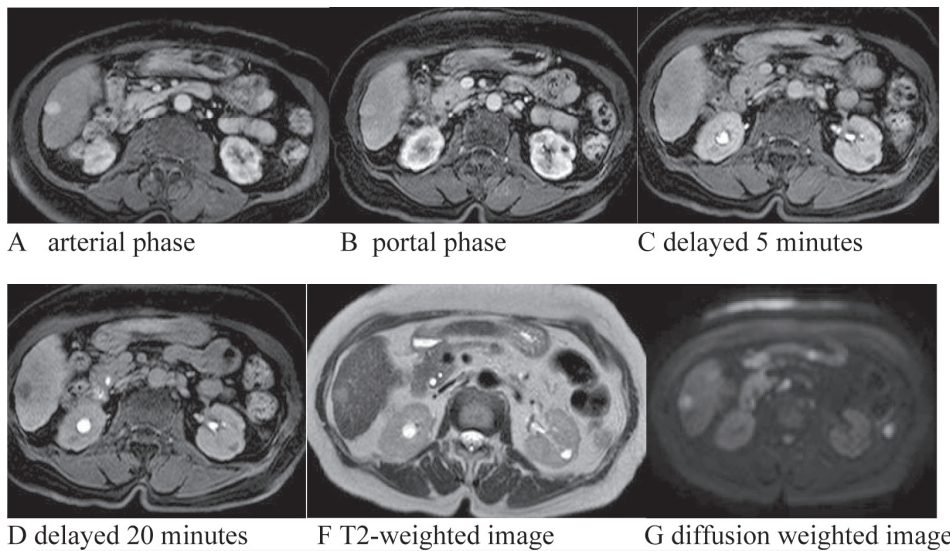


Figure 1: Axial imaged of gadoxedate -enhancement MRI in a 71- year-old woman with hepatitis B and hepatocellular carcinoma at segment 6. The liver mass at segment 6 measuring 1.5×1.4 cm in size showed hypersignal intensity on T2 weight (E), arterial phase (A) hyperenhancement, washout on portal phase (B) with enhancing capsule. The mass showed restriction (F) on DWI, hyposignal intensity on transitional phase (C) and delayed 20 minutes image (D). This hepatic observation was categorized as LR 5 according to LIRAD version 2018. HCC was confirmed with pathological report.

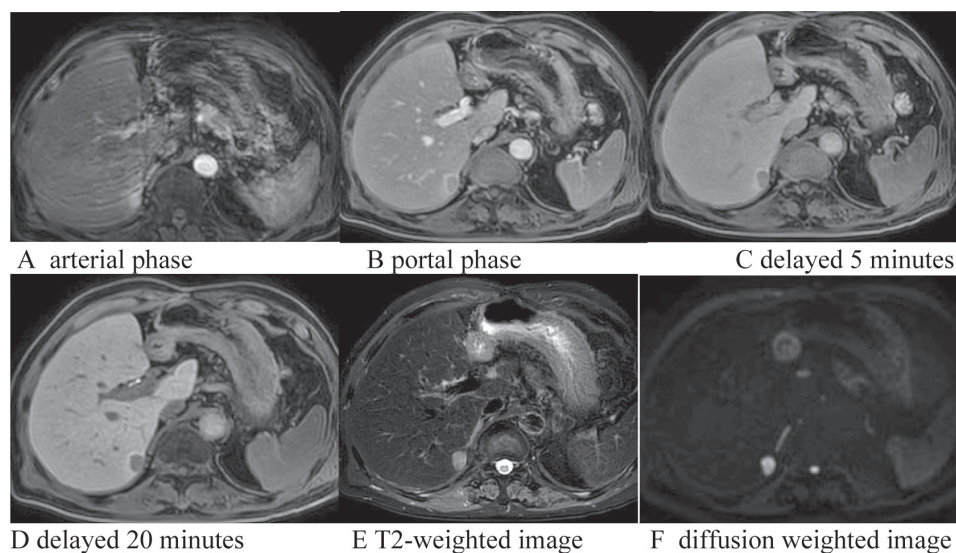


Figure 2: Axial imaged of gadoxedate -enhancement MRI in a 90 - year-old man with chronic hepatitis B and hepatocellular carcinoma (HCC) at segment 6. The liver mass at segment 6 of liver measuring 1.3x1.3 cm in size showed hypersignal intensity on T2 weight (E), arterial phase (A) hyperenhancement, washout on portal phase (B) with visible enhancing capsule. The mass showed restriction (F) on DWI, hyposignal intensity on transitional phase (C) and delayed 20 minutes image (D). This hepatic observation was categorized as LR 5 according to LIRAD version 2018. HCC was confirmed with pathological report. Also noted motion artifact on arterial phase image (A).

Discussion

Our study showed sensitivity of 82.8% (same value with AF) and specificity of 94.7% for HCC diagnosis in LR5 category (Table 1) in reader 1, 79.3% (same value with AF) sensitivity, and 89.5% (same value with AF) specificity in reader 2. This showed high sensitivity and high specificity of LR5 in diagnosis of HCC (Table 1).

The same sensitivity and specificity of LR5 and LR5 with AF in readers 1 and 2 were because there was no upgrade or downgrade of LR5. The LR5 showed more percentage of HCC than LR4 (96% LR5 and 26.7% LR4 as reader 1 without AF). Our study revealed that, in LI-RADS 2018, LR5 had sensitivity of 82.8% and 79.3% in diagnosis of HCC (as R1, R2) with the same sensitivity when combined with ancillary findings (82.8%, 79.3%) and specificity 94.7% and 89.5% in diagnosis of HCC (as R1, R2) and the same specificity when combined with ancillary findings

as 94.7% and 89.5%, respectively (Table 1). The value was between the sensitivity of 70% of a systematic review by Lee et al.¹⁶ and sensitivity of 94% of Shao et al.⁶.

The LR4 showed more percentage of HCC than LR3 (26.7% LR4 and 12.5% LR3 as reader 1 without AF). Thus, higher LI-RADS showed high percentage of HCC (i.e., 12.5% of LR3, 26.7% of LR4, and 96% of LR5 in reader 1).

LR5 showed higher accuracy than LR4 and LR3 (87.5%, 25%, and 27% as LR5, LR4, and LR3 without AF of reader 1) (83.3%, 27.1%, and 31.3% without AF of reader 2).

In our study, the accuracies of LI-RADS 3 and 4 version 2018 in diagnosis of HCC were 27.1% (31.3% with AF) and 25% (20.8% with AF) (reader 1) and 29.2% (31.3% with AF) and 27.1% (25% with AF) (reader 2). This showed that the accuracy of LR3 and LR4 in the diagnosis of HCC were almost the

same, which could be from a small number of patients. However, the LR5 showed the high accuracy in diagnosis of HCC (87.5%, 25%, and 27% as LR5, LR4, and LR3 without AF of reader 1 and 83.3%, 27.1%, and 31.3% without AF of reader 2). In our study, no LR1 and LR2 were found because, when the criteria met LR1 or LR2 category, the patient did not undergo the procedure to obtain the pathological report. No LR M and LR TIV were categorized in our study. One metastasis was categorized as LR5 and another one of cholangiocarcinoma was categorized as LR4. These could be from small number of patients.

About the major features, the non-rim arterial enhancement (arterial phase hyperenhancement) was more sensitive (93.1%) than other major features for the diagnosis of HCC but the specificity of non-rim arterial enhancement was 52.2%. The non-rim arterial hyperenhancement was noted in 27 HCCs but also observed in 12 non-HCC lesions. The highest specificity of major features was noted in the presence of capsule (100% specificity of R1 and R2), in which its sensitivity was 51.7% in R1 and 55.2% in R2. The capsule was noted in 15 HCC lesions and 0 of non-HCC lesion in R1.

The highest accuracy of major features was noted in non-rim peripheral washout (86.6% R1, 80.7% R2) and its sensitivity was 82.8% in R1 and 79.3% in R2. The non-rim peripheral washout was noted in 24 HCCs and two non-HCC lesion (R1). Regarding the ancillary features in favor of HCC, when we concluded finding favored HCC, the histopathological report was HCC totally in both R1 and R2. Moreover, when the conclusion favored malignancy (not HCC), in R1, 29 (59.2%) cases were HCC and 20 (40.8%) were non-HCC, and in R2, 28 (62.2%) cases were HCC, and 17 (37.8%) cases were non-HCC. Moreover, when we concluded finding favored benignity, no HCC was found in both R1 and R2.

Lee et al.⁸ and Granata et al.⁹ reported a sensitivity of 81%–84% and specificity of 73%–100% for hypersignal intensity of DWI. In our study, the highest accuracy of ancillary findings in diagnosis of HCC was noted in non-enhancing capsule (R1 sensitivity 34.5%, specificity 95.7%, and R2 sensitivity, 24.1%, specificity, 91.3%). The highest sensitivity of ancillary findings was noted in hepatobiliary phase hyposignal intensity as 73.9% but the specificity was 6.9%, and the accuracy was 36.5% in R1 (R2 had 65.2% sensitivity, 3.4% specificity, and 30.8% accuracy). The previous studies of LI-RADS version 2014 assessed the application of ancillary features have shown that they modified the final category in 15%–35% of observations with about 63% of LR4 observations being upgraded from LR3¹⁰⁻¹². In our study, which used the LI-RADS version 2018, the ancillary findings have shown that they modify the final LR category in 36.5% of total observation with 62.5% of LR4 upgraded from LR3 and no LR4 upgrade to LR5 (in reader 1). Moreover, in reader 2, the ancillary findings shown modification of the final LR category in 36.5% of total observation with 66.7% of LR4 upgrade from LR3 and no LR4 upgrade to LR5. The percentage of the upgraded observation was 36.5% as in reader 1 and reader 2 (which was the value about 15%–35% as the previous study¹⁰⁻¹² and the percent upgrade from LR3 to LR4 were 62.5% and 66.7% of readers 1 and 2, respectively, which was about 63% from previous study¹⁰⁻¹²).

The limitations of our study were as follows: 1. The retrospective study in one center and more than half of our patients were excluded because they did not met the inclusion criteria. 2. We did not consider the ancillary features in LR TIV and LRM 3. The threshold growth that is one of the major features was not accessed because only one scan was evaluated per patient. 4. The two radiologists were blinded to histopathological report but

they were aware of the purpose of the study. The excluded patients who underwent MRI outside the center with no contrast administration or inadequate quality for evaluation may lead to a selection bias; however, it was necessary for maintenance.

Conclusion

The LI-RADS version 2018 category 5 has high sensitivity (82.8% in R1, 79.3% in R2), specificity (94.7% in R1, 89.5% in R2), and accuracy (87.5% and 83.3% in R1 and R2, respectively) for diagnosis HCC.

Abbreviation

LI-RADS - Liver Imaging Reporting and Data System, TIV -Tumour in vein M - Malignant, HCC - Hepatocellular Carcinoma, AF - Ancillary finding, APHE - Arterial phase hyperenhancement, R1 -Reader 1, R2 -Reader 2.

Acknowledgement

This study was supported by Navamindrahiraj University Research Fund.

References

1. American cancer society. Cancer Facts& Figures 2020 [Internet]. 2021 [cited 2021 Oct 2]. Available from: Cancerstatisticscenter. cancer.org
2. Mittal S, Serag El. Epidemiology of hepatocellular carcinoma. *J Clin Gastroenterol* 2013;47: S2-6.
3. Bosch FX, Ribes J, Cléries R, Díaz M. Epidemiology of hepatocellular carcinoma. *Clinics in liver disease* 2005;9(2):191-211.
4. Imsamran W, Pattatag A, Supaattagorn P, Chiawiriyabunya I, Namthaison K, Wongsena M, et.al. Cancer in Thailand Volume IX 2013-2015. Bangkok : Cancer Registry Unit, National Cancer Institute, 2015.
5. Chernyak V, Fowler KJ, Kamaya A, Kielar AZ, Elsayes KM, Bashir MR, et al. Liver Imaging Reporting and Data System (LI-RADS) version 2018: imaging of hepatocellular carcinoma in at-risk patients. *Radiology* 2018;289(3): 816-30.
6. Shuo S, Liang Y, Kuang S, Chen J, Shan Q, Yang H, et al. Diagnostic performance of LI-RADS version 2018 in differentiating hepatocellular carcinoma from other hepatic malignancies in patients with hepatitis B virus infection. *Bosnian journal of basic medical sciences* 2020;20(3): 401-10.
7. Lee S, Kim YY, Shin J, Hwang SH, Roh YH, Chung YE, et al. CT and MRI liver imaging reporting and data system version 2018 for hepatocellular carcinoma: A systematic review with meta-analysis. *Journal of the American College of Radiology* 2020;17(10): 1199-206.
8. Lee MH, Kim SH, Park MJ, Park CK, Rhim H. Gadoteric acid-enhanced hepatobiliary phase MRI and high-b-value diffusion-weighted imaging to distinguish well-differentiated hepatocellular carcinomas from benign nodules in patients with chronic liver disease. *AJR Am J Roentgenol* 2011;197(5): W868-75.
9. Granata V, Fusco R, Avallone A, Filice F, Tatangelo F, Piccirillo M, et al. Critical analysis of the major and ancillary imaging features of LI-RADS on 127 proven HCCs evaluated with functional and morphological MRI: Lights and shadows. *Oncotarget* 2017;8(31): 51224-37.
10. Cerny M, Bergeron C, Billiard JS, Murphy-Lavallée J, Olivie D, Bérubé J, et al. LI-RADS for MR Imaging Diagnosis of Hepatocellular Carcinoma: Performance of Major and Ancillary Features. *Radiology* 2018;288:118-28.

11. Joo I, Lee JM, Lee DH, Ahn SJ, Lee ES, Han JK. Liver imaging reporting and data system v2014 categorization of hepatocellular carcinoma on gadoteric acid-enhanced MRI: Comparison with multiphasic multidetector computed tomography. *Journal of Magnetic Resonance Imaging* 2017;45(3):731-40.
12. Choi SH, Byun JH, Kim SY, Lee SJ, Won HJ, Shin YM, et al. Liver Imaging Reporting and Data System v2014 with gadoterate disodium-enhanced magnetic resonance imaging: validation of LI-RADS category 4 and 5 criteria. *Investigative radiology* 2016;51(8):483-90.