

# Squamous cell carcinoma on the eyelid of Nigerian albino horse

Garba, U. M.<sup>1\*</sup> Nwokike, E. C.<sup>1</sup>, Mbuk, E. U.<sup>1</sup>, Ali, A.<sup>1</sup>, Zamdayu, J. M.<sup>2</sup>,  
Yunusa, H. G.<sup>2</sup>, Amaje, J.<sup>1</sup> and Auwal, U.<sup>1</sup>

<sup>1</sup>Veterinary Clinic, Equitation Dept, Nigerian Defence Academy, Kaduna, Nigeria.

<sup>2</sup>Nigerian Army Medical corps, Veterinary Unit, Kaduna, Nigeria.

\*Corresponding author. Email: garbaum@yahoo.com; +2348034524912.

Copyright © 2019 Garba et al. This article remains permanently open access under the terms of the [Creative Commons Attribution License 4.0](https://creativecommons.org/licenses/by/4.0/), which permits unrestricted use, distribution, and reproduction in any medium, provided the original work is properly cited.

Received 16th March, 2019; Accepted 16th April, 2019

**ABSTRACT:** Squamous cell carcinoma is the most common neoplasia of the skin in horses. An adult albino stallion of Nigerian indigenous (*Arewa*) breed used for military ceremonial parade was presented with the chief complaints of growth on left side lower eyelid and unilateral epiphora. Tentatively diagnosis of eyelid squamous cell carcinoma was made and managed successfully. Restraint was achieved using chlorpromazine as tranquilizer and physical method with the animal on right lateral recumbency for the surgery. Lidocaine-adrenaline 2% was used for local anaesthesia. The growth was debulked only once and chemotherapeutically treated using vincristine 1 mg for local infiltration once and 2 mg intravenously twice at 3 weeks apart. Tissue sample was preserved in formaldehyde-10% and processed for histopathological examination. Haematological findings pre-treatment were neutropenia, 32% (52 to 70%) and hyperproteinemia, 10.2 g/d L (6.0 to 8.5g/dL) which became neutrophilic leucocytosis 16.1 x 10<sup>9</sup>/L (5.6-12.1 x 10<sup>9</sup>/L) post-treatment. Histopathological findings were focal areas of keratin pearls surrounded by a concentric aggregation of cornified squamous epithelial cells. Massive undifferentiated tumour cells and inflammatory cells at different stages of mitosis were also observed. It was concluded that surgical excision of lesion and vincristine therapy twice at 3 weeks apart only was effective to cure the eyelid squamous cell carcinoma in the horse. It was recommended that surgical excision of growths and vincristine therapy given by intravenous and local infiltration routes should be used in management of eyelid squamous cell carcinoma in albino horses.

**Keywords:** Albino, carcinoma, eyelid, horse, Nigerian, squamous cell.

## INTRODUCTION

Traditionally, albino horses are the main choice for ceremonial parade amongst the military and the police force in Nigeria because of their bright, attractive and outstanding colour on parade ground which adds to beautification of the parade proceedings. Incidentally, albino horses are the most predisposed to squamous cell carcinoma, SCC (Clode et al., 2018). Squamous cell carcinoma is neoplasia of squamous epithelial cells characterized by abnormal growth found at location(s) where it did not previously exist (Saror, 2011) and is usually superficial affecting limbus, conjunctiva and eyelid in horses and cattle (Dreyfus et al., 2011). Ocular lesions of squamous cell carcinoma may appear thick, rough

surfaced, pinkish to red in colour, ulcerated and commonly observed on the skin of eyelid and palpebral conjunctiva in older animals (Conceicao et al., 2010). The SCC of eye is the most common ocular tissue neoplasia with increasing incidence with age, decreased skin pigmentation, light coloured coats and increased exposure to ultraviolet light. Success of treatment depends upon the location and extent of tumor while the prognosis is relatively good depending upon the speed of detection, extent and anatomic position of the lesion(s) (Clode et al., 2018). Over 80% of tumours in horses occur on the skin and subcutaneous tissue and early detection, appropriate removal and treatment are important to prevent more

severe and costly problems (CEH, 2008). The essence of reporting this case is to bring to the knowledge of veterinary practitioners and horse owners the health challenge posed by SCC especially in albino horses in Nigeria so that appropriate treatment measures can be instituted when horses are diagnosed of SCC.

## CASE HISTORY, CLINICAL EXAMINATION AND MANAGEMENT

An albino stallion of Nigerian indigenous (*Arewa*) breed used for military ceremonial parade was presented to the Veterinary Clinic, Nigerian Defence Academy, Kaduna on the 15th June, 2017. The chief complaints were growth on left side lower eyelid and unilateral epiphora. The horse weighed 305.2 Kg using electronic digital scale (Model: PS3000, Breaknell, China) with age estimate of 5 years as described by Wayne and Melvin (2000). History showed that the growth increased in size despite earlier treatments with Gentamycin eye-drops before presentation. Body condition of the horse was scored to be 6 using the 9 points chart of KER (2011).

Clinical examination of animal revealed that the growth was on mucocutaneous junction of lower left eyelid that was spreading to the fornix of bulbo-palpebral conjunctiva. The growth was curly flower-like. Animal continuously had mucopurulent ocular discharge from the affected left eye. Respiration was 10 circle/minute; pulse, 32 beats/minute and rectal temperature, 38.2°C/minute. These were also within normal ranges (Wood, 2013). Mucous membrane of the affected eye was slightly congested.

### Management of the horse

The horse was in the same institutional stable housing 53 horses in 6 stable blocks. Each stable block is partitioned into loose boxes (measuring 12 x 12 ft) for individual horse, terrazzo-floored, sufficient drainage system and ventilation vents and doors that are fitted with fly-proof nets. Fresh coarse hay was provided as bedding material and changed as soon as it was getting bad. The stables were cleaned daily.

Feeding at the period of presentation of these cases comprised of hay, water and salt lick provided *ad libitum*. Whole grains mixture in equal quantities of sorghum/millet totaling 1.1 kg, wheat bran (0.75 kg)/ maize bran (1kg) mixture and concentrate feed supplement (groundnut cake, vitamins, fat and oil) of about 28.5 g were served per animal per day in two divided rations for morning (10.00 am) and evening (5.00 pm).

### Samples collection

About 5 ml of jugular vein blood was collected in EDTA bottle for haemogram analysis. Surgery was planned for

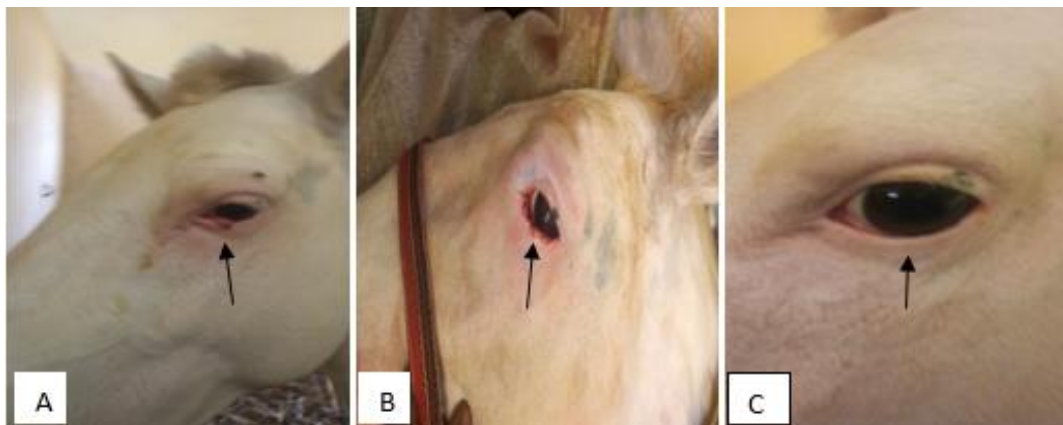
the next day during which excised tissue was sampled into 10% formalin and prepared for histopathological examination.

### Surgical procedure

The horse head was washed with tap water and shampoo with the animal in standing position. Towel was used to mop up water with particular attention to the left side of face bearing the lesion. Restraint was achieved using chlorpromazine 6 mg total dose, slow IV, via the jugular vein as tranquilizer (Aliu, 2007) and casted on right lateral recumbency on a thick collection of hay as bedding material using Double Half-hitch method (Wosu, 2002). The horse head was restrained on polyethylene sheet spread over bedding material in head region while an assistant maintained the head in position by holding onto the halter fitted to the head. The left eye lashes were trimmed while the field was covered using cotton wool soaked in 0.9% normal saline and swabbed carefully to remove hair particles and prevent falling into the eyes. The eyelids were locally infiltrated with 5 mL of 2% lidocaine-adrenaline as local anaesthetic using 5 ml syringe and 23G needle. The surgeon re-gloved his hands, evaginated the eyelids with forceps and carefully but sufficiently excised the lesion on the palpebral conjunctiva. An area that was erythemic on upper eyelid and in contact with the lesion on lower eyelid was also scrapped. Single stitch of horizontal mattress pattern (Kumar, 2003) was applied to stitch the conjunctiva and skin edge of lower eyelid together using size 3/0 chromic catgut with the knot on the skin (outside). Cotton wool soaked in 0.9% normal saline solution and squeezed to drain excess solution was used to cover the eye ball, dab off bleeders and together with a finger of the surgeon, provided guard for the eyeball during the procedure. During the procedure, the surgical team was very attentive to guard against unwanted body movement of the animal. The excised tissues were separately preserved in sample bottles containing formaldehyde 10%, labeled and submitted for histopathological study at the Department of Veterinary Pathology, Faculty of Veterinary Medicine, Ahmadu Bello University, Zaria, Nigeria. The horse was hospitalized in the clinic unit of the Equitation Department, Nigerian Defence Academy, Kaduna.

### Post-surgical care and chemotherapy

Immediately before the horse rose from recumbent surgical position, Vincristine 1 mg was infiltrated at the surgical sites on the eyelid while covering the eyeball with cotton wool swab (soaked in normal saline and drained) to prevent direct contact of drug with eyeball. In addition, vincristine 2 mg, IV was administered and this route injection was repeated 3 weeks later. The affected eye was carefully cleaned of discharges for three days with cotton wool soaked in 0.9% normal saline and gentamycin eye



**Plate I.** Growth on mucocutaneous junction of leftside lower eyelid (A), post-surgicalexcision of growth on day 0 (B) and healed eyelid on day 180 postsurgical (C).

**Table 1.** Evaluation of haematological parametres of horse pre-treatment and post-treatment.

Haematological parameters	Observed Values	
	Pre-treatment (on day before)	Post-treatment (day 180)
Haemoglobin (10.1-16.1g/dL)	11.6g/dL	13.6g/dL
Packed cell volume (27-43%)	35%	41%
White blood cells (5.6-12.1x10 <sup>9</sup> /L)	9.5x10 <sup>9</sup> /L	16.1x10 <sup>9</sup> /L
Bands (0-1%)	02%	04%
Neutrophils (52-70%)	32%	80%
Lymphocytes (21-42%)	60%	16%
Monocytes (0-6%)	06%	00%
Eosinophils (0-7%)	0%	00%
Basophils (0-2%)	0%	00%
Total protein (6.0-8.5g/dL)	10.2 g/dL	8.2 g/dL
General Comments	Neutropenia/Lymphocytosis/Hyperproteinemia	Neutrophilic leukocytosis

**Key:** Values in parenthesis are normal reference ranges for horses as reported by Susan (2018) in *MSD Veterinary Manual*, Online Version.

drop was instilled after every cleaning daily for the first 3 days. However, when swelling was observed, Betamethasone-Neomycin eye drop was used as substitute and by day 5 post-surgical, the frequency of administration was reduced to x2 daily until wound was observed to have healed on day 10 post-surgical. During the period, facial fly-guard was fitted to the head to aid in keeping flies away until healed.

## RESULTS

### Postsurgical observation of the animals

The eyelid surgical wound healed steadily without re-growth within 14 days. Further observations on days 180 and 450 postsurgical, the stallion did not show any sign of re-growth of lesion (Plate I: A, B, C) and the horse was

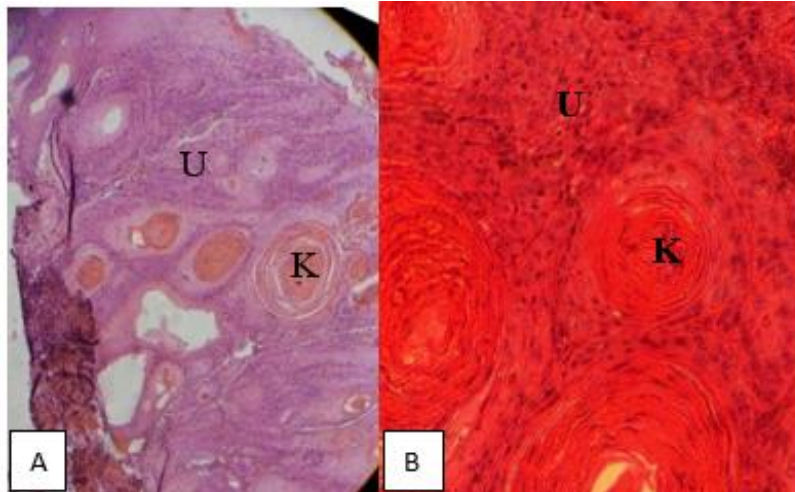
apparently healthy and in active training/exercise without further complaint.

### Haematological findings

Significant pretreatment parameters observed were neutropenia, lymphocytosis and hyperproteinemia while post-treatment, neutrophilic leukocytosis was observed (Table 1).

### Histopathological findings

Histopathological examination revealed, focal areas of keratin pearls surrounded by a concentric aggregation of cornified squamous epithelial cells (horn pearl), undifferentiated tumour cells at different stages of mitosis and inflammatory cells (Plate II).



**Plate II.** Sections of tissue sample from eyelid. Focal areas of keratin pearls (horn pearl) (K) and undifferentiated tumour cells at different stages of mitosis and inflammatory cells (U). H-E stain, X200 (A). H-E Stain, X400 (B).

## DISCUSSION

In the present case, the gross curly flower-like appearance of the growth on the mucocutaneous junction of the eye of the albino horse strongly suggested SCC as reported by Dreyfus et al. (2011) and Saror (2011). The presence of focal areas of keratin (keratin pearls) surrounded by concentric aggregation of cornified squamous epithelial cells (horn pearl) and massive undifferentiated tumour cells at different stages of mitosis (anisocytosis and anisokaryosis) and inflammatory cells typifies metastatic tumour of squamous cells in horses as described for preputial sheath SCC case in mixed breed dog in Iran by Manesh et al. (2014). These earlier reports support the present diagnosis of SCC of the eyelid.

The level of healing achieved without re-growth of lesion as at day 180 after surgical excision and chemotherapy may partly be due to small size and early presentation of this case. This also agreed with the reports by Conceicao et al. (2010) and Clode et al. (2018) that success in recovery is partly dependent on combined effects of early presentation and severity of lesion. In this case study, the listed factors combined with surgical excision and vincristine therapy (which included intravenous and local infiltration at surgical site) might have significantly contributed to success achieved in treatment.

The haematological parameters showed neutropenia/lymphocytosis and hyperproteinemia pre-surgical/chemotherapy in this case report, suggesting that the condition was getting beyond the control of cell mediated immune response while it is mobilizing the humoral system resulting in immune complexes build up seen as elevated total protein in cancer (Sow et al., 2014). However, after first surgical intervention, the horse exhibited neutrophilic leukocytosis only, suggestive of

reversal from the pre-treatment haemogramme and possible an ongoing acute bacterial infection (Allison, 2012). The haemogramme and absence of re-growth several months later jointly indicate healed SCC in this case study.

## Conclusion

The haematological changes associated with SCC in albino horses include; neutropenia, lymphocytosis and hyperproteinemia while the histopathological changes observed were aggregates of keratin pearls, undifferentiated mitotic tumour cells and inflammatory cells. These changes are resolved post-treatment.

A combination of surgical excision of lesions and vincristine therapy administered by local infiltration, 1 mg once and intravenous injection of 2 mg twice at 3 weeks apart only, was effective cure in management of SCC in albino horses. Early treatment intervention, when lesions are limited in size and spread, increases success chances and reduces duration of treatment.

## Recommendations

Surgical excision of growths and chemotherapy using vincristine intravenously and locally infiltrated at surgical sites especially in early stage should be used in management of SCC in Albino horses. Surgeons should be patient in management to ensure complete cure. Thorough check of the animals' body should be conducted regularly to identify cases in early stage for prompt management. This will prevent complications and enhance success rate of treatment.

## CONFLICT OF INTEREST

The authors declare that they have no conflict of interest.

## ACKNOWLEDGEMENT

The contributions of late Mr Bitrus, Mallam Yunusa and Prof Mohammed Bisalla all in the Department of Pathology, Faculty of Veterinary Medicine, Ahmadu Bello University, Zaria, Nigeria for the preparation of tissue sample, haemogramme analysis and histopathology slides examination respectively are highly appreciated.

## REFERENCES

- Aliu, Y. O. (2007). Nigerian veterinary formulary; Handbook of essential veterinary drugs, biologics and pesticide chemicals. First edition, Veterinary Council of Nigeria, p. 67.
- Allison, R. W. (2012). Laboratory evaluation of the liver/Laboratory evaluation of plasma and serum proteins, In: Thrall, M. A., Weiser, G., Allison R. W., & Campbell, T. W. (Eds). *Veterinary Hematology and Clinical Chemistry*. Second Edition, Wiley-Blackwell, U.K., Pp. 401-424 & 460-479.
- Centre for Equine Health (CEH) (2008). Understanding cancer in horses. Some common tumors and what to expect. A publication of the Centre for Equine Health, UC Davis School of Veterinary Medicine, University of California, 26(2), 1-16.
- Clode, A., Knottenbelt, D., Miller, P. E., Munroe, G., & Hollis, A. (2018). Eye: Squamous cell carcinoma. Vetstream, Definitive Veterinary Intelligence. Available at <https://www.vetstream.com/treat/equis/diseases/eye-squamous-cell-carcinoma>. Accessed 24th March, 2018.
- Conceição, L. F. D., Ribeiro, A. P., Piso, D. Y. T., & Laus, J. L. (2010). Considerations about ocular neoplasia of dogs and cats. *Ciência Rural*, 40(10), 2235-2242.
- Dreyfus, J., Schobert, C. S., & Dubielzig, R. R. (2011). Superficial corneal squamous cell carcinoma occurring in dogs with chronic keratitis. *Veterinary Ophthalmology*, 14(3), 161-168.
- Kentucky Equine Research (KER) (2011). Body condition score chart. Published by Kentucky Equine Research, 3910 Delaney Ferry Rd., Versailles. Available at <https://ker.com/published/body-condition-score-chart/>. Accessed 13th March, 2018.
- Kumar, A. (2003). *Veterinary Surgical Technique*. Second Reprint, Vikas Publishing House PVT Ltd, Lndia. Pp. 59-73.
- Manesh, J. Y. Y., Shafiee, R., Bahrami, A. M., Mehdi, P., Pourzaer, M., Pedram, B., Javanbakht, J., Mokarizadeh, A., & Khadivar, F. (2014). RETRACTED ARTICLE: Cyto-histopathological and outcome features of the prepuce squamous cell carcinoma of a mixed breed dog. *Diagnostic Pathology*, 9, 110.
- Saror, D. I. (2011). *General Veterinary Pathology*. 2nd edition, Onaivi Printing and publishing Co. Ltd, Makurdi, Nigeria. Pp. 85-100.
- Sow, A., Sidibé, I., Kalandi, M., Bathily, A., Ndiaye, N. P., Ouédraogo, M., Mouiche, M. M. M., & Sawadogo, G. J. (2014). Biochemical changes induced by natural infection of trypanosomosis in Burkinabese local donkey breeds. *Comparative Clinical Pathology*, 23(1), 103-109.
- Susan, E. F. (2018). Hematologic Reference Ranges. *MSD Veterinary Manual*. Online version, Merck Sharp and Dohme Corp., U.S.A. Available at <https://www.msddvetmanual.com/appendixes/reference-guides/hematologic-reference-ranges>. Accessed 29th March, 2018.
- Wayne, L., & Melvin, B. (2011). Determining age of horses by their teeth, Extension and Agricultural Information, 1-98 Agriculture Building, Columbia, MO 65211; XPLOR website.
- Wood, C. (2013). Temperature, pulse and respiration in a horse. An extension service publication funded by United States Department of Agriculture (USDA) and National Institute of Food and Agriculture (NIFA). Available at <https://articles.extension.org/pages/27755/temperature-pulse-and-respiration-in-a-horse>. Accessed on 10th March, 2018.
- Wosu, L. O. (2002). *The veterinarian's handbook*. First edition, Mike social press, Nsukka, Nigeria, 268p.