

Case Report

Asian Pacific Journal of Tropical Medicine

apjtm.org



doi:10.4103/1995–7645.338433

5-Years Impact Factor: 2.285

Furuncular myiasis by *Wohlfahrtia magnifica* (Diptera: Sarcophagidae) in a healthy childMajed Hamdi Wakid^{1,2✉}, Angham Ahmed Almakki³, Nouf Saleh Alsahaf⁴, Mohammed Ali Almatrafi^{5,6}¹King Abdulaziz University, Faculty of Applied Medical Sciences, Department of Medical Laboratory Technology, Jeddah, Saudi Arabia²Special Infectious Agent Unit, King Fahd Medical Research Center, King Abdulaziz University, Jeddah, Saudi Arabia³Department of Laboratory and Blood Bank, Security Forces Hospital, Makkah, Saudi Arabia⁴Medical College, Umm Al Qura University, Makkah, Saudi Arabia⁵Department of Pediatrics, Umm Al Qura University, Makkah, Saudi Arabia⁶Department of Pediatrics, Security Forces Hospital, Makkah, Saudi Arabia

ABSTRACT

Rationale: Human myiasis is the invasion of tissue or organs by fly larvae. This could be obligatory, facultative, or accidental.

Patient concerns: A 4-year-old Saudi boy complained of fever over the past three days with multiple inflamed painful dermal furuncles and worms-like discharge.

Diagnosis: Furuncular obligatory myiasis caused by *Wohlfahrtia magnifica*.

Interventions: Maggots were removed for identification. The wounds were cleaned with antiseptic dressings. Topical and oral antibiotics were applied.

Outcomes: Seven days later, the wounds completely healed.

Lessons: Although several reports correlated human myiasis with old age, low health status, mental retardation, and low socioeconomic status, but the patient in our case was a healthy child from a family with good socioeconomic status, good hygiene, no history of diseases or mental disability, but traveled to a village where the climate is suitable for fly breeding.

KEYWORDS: Furuncule; Myiasis; *Wohlfahrtia magnifica*; Maggots; Saudi Arabia

1. Introduction

Invasion of dipterous maggots to vertebrate host tissues or organs is called myiasis, which derived from ancient Greek word "myia" meaning fly. Several fly species belonging to Calliphoridae and

Sarcophagidae families are well known to cause myiasis worldwide, especially in rural tropical and subtropical regions. Myiasis can be classified according to the etiological behavior of the fly's invasion into obligatory (specific) myiasis that only infest living tissues; facultative (opportunistic or semi specific) myiasis that infest both decomposing and living tissue or as free living; and accidental myiasis (pseudomyiasis) where host is not essential for fly's development and the transmission is accidental by eggs or larvae deposition on the accessible organ and tissue or by ingestion. Obligatory myiasis is true parasitism and usually the most serious type, as the maggots lead to severe destruction in the infested living tissues or organs. Clinically, myiasis can be classified according to the affected organ or tissues, such as cutaneous, intestinal, ophthalmic, urogenital, nasopharyngeal, and oral. The symptoms severity depends on the affected part of the body, the species and number of the parasitizing maggots.

Here we present a child case with furuncular obligatory myiasis caused by *Wohlfahrtia (W.) magnifica*. Signed informed consent was obtained from the patient's mother for publication of this case report and related images.

✉To whom correspondence may be addressed. E-mail: mwakid@kau.edu.sa

This is an open access journal, and articles are distributed under the terms of the Creative Commons Attribution-Non Commercial-ShareAlike 4.0 License, which allows others to remix, tweak, and build upon the work non-commercially, as long as appropriate credit is given and the new creations are licensed under the identical terms.

For reprints contact: reprints@medknow.com

©2022 Asian Pacific Journal of Tropical Medicine Produced by Wolters Kluwer-Medknow. All rights reserved.

How to cite this article: Wakid MH, Almakki AA, Alsahaf NS, Almatrafi MA. Furuncular myiasis by *Wohlfahrtia magnifica* (Diptera: Sarcophagidae) in a healthy child. Asian Pac J Trop Med 2022; 15(2): 87–89.

Article history: Received 17 October 2021
Accepted 18 February 2022

Revision 4 February 2022
Available online 28 February 2022

2. Case history

In August 2021, a 4-year-old Saudi boy presented to the Emergency Department at the Security Forces Hospital in Makkah, complaining of fever for the last three days and several painful itchy furuncles and worms-like discharge. The Emergency Department doctor noticed multiple furuncles that spread from the head, the back of the ear to the trunk and extremities. Each dermal furuncle was inflamed with an opening, through which the larva gets air (Figure 1A). The boy had a history of traveling with his family to AshShifa village. After playing shirtless on a rainy day, he complained to his mother about insects' attack and later she noticed the development of inflamed dermal boils. On admission, the patient looked conscious and alert; his vital signs were stable and standard, with no snoring or stridor on his airway and no chest pain. There was no evidence of lymphadenopathy, meningitis, or an increase in intracranial pressure. Vomiting, gastrointestinal distress, and decreased activity or oral intake were all denied by his mother. The child's immunization was up to date, and his weight and height were 17.3 kg and 110 cm, respectively. Testings for COVID-19 and bacterial blood culture were negative. The complete blood count (CBC) revealed slight leukocytosis, $13.18 \times 10^3/\mu\text{L}$ (normal reference value 5×10^3 - $11 \times 10^3/\mu\text{L}$), eosinophils represented 1.30% (normal range 1%-5%), normal hemoglobin of 13.9 g/dL (normal reference value 11-15 g/dL), and $331 \times 10^3/\mu\text{L}$ platelet count (normal reference value 150×10^3 - $450 \times 10^3/\mu\text{L}$). The inflammatory marker C-reactive protein (CRP) was 13.5 mg/L, which is slightly high (reference value 0.02-10 mg/L).

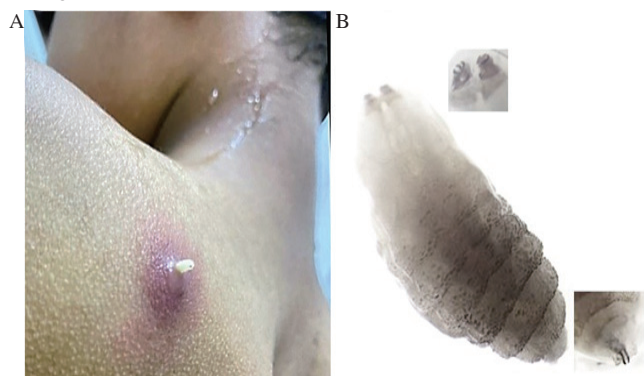


Figure 1. (A) The gross view of one of the lesions in the 4-year-old Saudi boy, showing the emerged larva. (B) Microscopic appearance of the third instar larva at different focuses showing posterior spiracles with three peritremal slits, oral pair of teeth (cephalopharyngeal skeleton).

The patient was admitted to the contacting isolation room with suspicions of myiasis and planned for pediatric consultation. Eleven larvae protruded after petroleum jelly was applied to the punctum of skin lesions to suffocate the organisms. The extracted larvae were then collected in a sterile container, and sent to the microbiology laboratory in the hospital, where they were confirmed as maggots. All affected areas were cleaned with antiseptic dressings and a local antibiotic was applied. For further conclusive species identification, four maggots were sent to the diagnostic parasitology laboratory at

the Special Infections Agents Unit, King Fahd Medical Research Center in Jeddah. The received larvae were covered with pus and traces of blood. Three larvae were alive, and one was dead. The size of the maggots ranged in length from 9 to 13 mm and in width from 1 to 2 mm and the entomological examination under the stereomicroscope revealed spines covering the whole body. Presence of two peritremal slits in the posterior spiracles of the dead larva determined that this stage is clearly a second larval instar. Moreover, the remaining three larvae were distinctly third larval instars as they demonstrated posterior spiracles with three peritremal slits, oral pair of teeth (cephalopharyngeal skeleton) and anterior spiracles with five branches (Figure 1B). All general features confirmed the identity of *W. magnifica* larval stages. In order to confirm fly identity depending on pupae and adult flies, the three alive maggots were cultured and continued feeding from the surrounding pus and blood. In addition, a small quantity of sputum was added to provide a more food source. Larvae size increased overtime and dark pupae formed on day 7 (Figure 2A). On day 14, one *W. magnifica* adult fly emerged (Figure 2B), while the remaining two pupal stages died and collapsed.




Figure 2. *Wohlfahrtia magnifica* (A) Pupa and (B) Adult fly.

The patient was discharged with an oral amoxicillin-clavulanic acid antibiotic for seven days for secondary bacterial infection and follow-up with the pediatric clinic. After one week, the mother revealed that her son had no complaints and the affected skin completely healed.

3. Discussion

The World Health Organization classifies human myiasis among the serious medical conditions that require urgent treatment[1]. Human myiasis is mainly distributed in tropical and subtropical countries; however, cases have been already reported in Europe, Asiatic Russia, Manchuria, China and other areas around the world[2]. Cutaneous myiasis is mainly classified into furuncular, dermal and wound (traumatic) myiasis.

W. magnifica belongs to the family Sarcophagidae and is classified among the obligatory myiasis flies that primarily infest animals. In recent years, *W. magnifica* has been reported as the cause of several types of myiasis. In Saudi Arabia, a case of *W. magnifica* myiasis was documented in a 4-year-old girl with inflamed scalp ulcer. The child was from a very low socioeconomic status family and surgical operations were essential to extract a large number of larvae before treatment[3]. A case of an 8-year-old Turkish boy with hypereosinophilia who presented a furuncular myiasis under his right armpit. The clinical and hematological manifestations returned

to normal a few days after the removal of the larvae[4]. An unusual cutaneous myiasis case localized in and subcutaneous tissues in an 87-year-old man with head-neck cancerous wound was documented but with no details about the treatment[5]. Aural myiasis (otomyiasis) was seen in a 4-month-old female infant from a rural community with a history of irritability and right otorrhea. A few days after the removal of maggots and treatments with topical and oral antibiotics, the patient's symptoms were completely relieved[6]. Similar observation and treatment were applied on another child of a 4-year-old living in a socioeconomically poor family from a rural area. Surgery and otoscopic examination were essential for extraction of the maggots before treatment[7]. Urogenital myiasis caused by *W. magnifica* is rare in humans. A case of such myiasis was reported in 2010 in an 86-year-old rural man with a painful black necrotic penile ulcer. The patient was hospitalized for removal of the larvae and antibiotic therapy[8]. Oral (gingival) myiasis is another uncommon condition caused by *W. magnifica* among patients with poor oral hygiene. After the removal of the larvae, the patients recover with no subsequent complications and no further treatment is need. The recent two gingival myiasis cases were reported in Iran and Turkey, in a 4-year-old mental retarded boy with anorexia and a 43-year-old male patient with chronic periodontitis, respectively[9,10].

Here we report a case of furuncular myiasis caused by *W. magnifica* in Saudi Arabia, and for the first time identified depending on larva, pupa, and adult fly morphology.

We anticipated that myiasis cases are much more than reported and often misdiagnosed. Many physicians are stymied regarding identification of myiasis cases, mainly because humans are occasional hosts and the symptoms are not specific. If so, further awareness about myiasis should be raised among workers in medical specialties. Several human reports correlated flies infestation with age, low health status, mental retardation, low socioeconomic status, low education level, poor hygiene, travel to endemic areas, and other predisposing factors. In our case, the child is from a family with good socioeconomic status, no history of diseases or mental disability, but traveled this August to AshShifa village where the climate is suitable for flies breeding. It should be noted that AshShifa is a mountainous village in Makkah region in Saudi Arabia, where the climate is moderate, and the temperature in August usually touches the threshold of 30 °C.

The accompanied pain with the current case may be caused by larvae deep burrowing in tissues and feeding using mouth hooks. It is also possible that this process gradually destroys tissues, which results in the development of skin inflammation and secondary bacterial infection.

Effective treatment for any type of myiasis, including the present furuncular myiasis, is achieved mainly by the physical removal of all maggots. We also used local disinfectants and an oral antibiotic to prevent secondary infection or complications. These procedures relieved the patient's pain with effective response to the treatment. The awareness of the team about myiasis and related clinical aspects improved the expediency and success of treatment of the present case.

In order to prevent such myiasis cases, children playing outdoors should be warned about avoiding contact with flies and animals surrounded by insects.

In conclusion, the current case has shown that human furuncular myiasis may occur in healthy (physically and mentally) children with good socioeconomic status but exposed to the flies in rural areas.

Conflict of interest statement

The authors declare that there are no conflicts of interest.

Authors' contributions

MAA and NSA performed the clinical diagnosis and treatments of the patient. AAA obtained informed consent. MHW and AAA supervised the laboratory analysis and interpretation. MHW performed the identification of the maggots and the speciation of the fly. MAA, NSA and AAA collected data and drafted the manuscript. MHW revised critically and prepared the final version of the manuscript. MHW, AAA, NSA and MAA read and approved the manuscript for publication. MHW supervised the whole project.

References

- [1] World Health Organization (WHO). *International classification of diseases*. 11th Revision (ICD-11). [Online]. Available from: <https://icd.who.int/en>. [Accessed on 10 September 2021].
- [2] Yildirim I, Ceyhan M, Cengiz AB, Saki CE, Ozer E, Beken S, et al. What's eating you? Cutaneous myiasis (*Wohlfahrtia magnifica*). *Cutis* 2008; **82**(6): 396-398.
- [3] Al Badri R, Al Harbi T, Tonnsi A, Almatary A, Hassanein R. Cutaneous myiasis in a child scalp caused by *Wohlfahrtia magnifica* (Diptera: sarcophagidae): A case report. *MOJ Clin Med Case Rep* 2016; **4**(3): 76-78.
- [4] Tuygun N, Özkan AT, Tanır G, Mumcuoğlu KY. Furuncular myiasis in a child caused by *Wohlfahrtia magnifica* (Diptera: Sarcophagidae) associated with eosinophilia. *Turk J Pediatr* 2009; **51**(3): 279-281.
- [5] Çevik C, Kaya OA, Akbay E, Ozkan M, Kahraman A, Uçak M. An unusual *Wohlfahrtia magnifica* myiasis case localized in cutaneous and subcutaneous tissues in a patient with head-neck cancer. *Turkiye Parazitol Derg* 2014; **38**(2): 135-137.
- [6] Ata N, Güzelkara F. Aural myiasis in an infant. *J Craniofac Surg* 2017; **28**(1): e89-e90. doi: 10.1097/SCS.0000000000003272.
- [7] Beyhan YE, Yılmaz H, Taş-Cengiz Z, Ayrıl A. A case of aural myiasis caused by *Wohlfahrtia magnifica* in a child in Turkey. *Turk Bull Hyg Exp Biol* 2017; **74**(4): 347-350.
- [8] Salimi M, Goodarzi D, Karimfar MH, Edalat H. Human urogenital myiasis caused by *Lucilia sericata* (Diptera: Calliphoridae) and *Wohlfahrtia magnifica* (Diptera: Sarcophagidae) in Markazi Province of Iran. *J Arthropod-Borne Dis* 2010; **4**(1): 72-76.
- [9] Mohammadzadeh T, Hadadzadeh R, Esfandiari F, Sadjjadi S. A case of gingival myiasis caused by *Wohlfahrtia magnifica*. *J Arthropod Borne Dis* 2008; **2**(1): 53-56.
- [10] Çetin Özdemir E, Ekşi F, Şenyurt SZ, Üstün K, Karaoğlu İ, Erciys K. A case of gingival myiasis caused by *Wohlfahrtia magnifica*. *Mikrobiyol Bul* 2014; **48**(3): 512-517.