

REVIEW

The benefits of antimicrobial photodynamic therapy with RLP068 in the management of diabetic foot ulcers

Nicolò Martinelli MD¹, Vincenzo Curci MD², Antonella Quarantiello MD², Gennaro Saldalamacchia MD³

¹IRCCS Istituto Ortopedico Galeazzi, Via Riccardo Galeazzi, 4, 20161 Milan, Italy; ²Dipartimento Interdivisione di Cura del Piede Diabetico, Istituto Clinico Città Studi di Milano, Via Jommelli 17, 20131, Milan, Italy; ³Dipartimento di Medicina Interna, UOS "Piede Diabetico", UOC di Diabetologia, Azienda Ospedaliera Universitaria Policlinico "Federico II", Via Pansini 5, 80100 Napoli, Italy

Abstract

This article is the first part of a literature review concerning diabetic foot ulcers and the use of antimicrobial photodynamic therapy (PDT). Diabetic foot ulcers are associated with high morbidity, mortality, and healthcare costs. Natural healing is often delayed by microbial infection or colonisation, which might lead to serious complications, such as amputation. Furthermore, antibiotic treatment could have limited success because of the development of bacterial resistance and severely limited drug delivery to the ulcer due to vascular damage. PDT has antimicrobial effects and has been used to reduce the total and pathogenic microbial load in diabetic ulcers without inducing bacterial resistance. It is safe and can be used to

improve outcomes. A clinical trial demonstrated that PDT with RLP068 reduced the microbial load of diabetic ulcers in 62 patients. This article reports previously published evidence and presents four, unpublished, clinical cases treated in the real-life setting.

Keywords: diabetic foot ulcer, ulcer therapy, photodynamic therapy, PDT.

Citation

Martinelli N, Curci V, Quarantiello A, Saldalamacchia G. The benefits of antimicrobial photodynamic therapy with RLP068 in the management of diabetic foot ulcers. *Drugs in Context* 2019; 8: 212610. <https://doi.org/10.7573/dic.212610>

Background

Diabetic foot ulcers (DFUs) are one of the main complications in type 1 and 2 diabetes mellitus, are associated with high morbidity and mortality amongst patients and represent a significant burden on healthcare systems. Patients with diabetes are at risk of developing DFUs in 25% of cases,¹ which correspond to 9.1–26.1 million patients/year, according to the International Diabetes Federation.² Furthermore, the risk of death in the United Kingdom (UK) is estimated to be 5% in the first 12 months and 42% within 5 years, and patients with DFUs were shown to have a 2.5-fold increased risk of death as compared to those without DFUs.³ Additionally, patients with DFUs experienced high morbidity, poorer health-related quality of life (HRQoL), and psychosocial complications.⁴ Lastly, some researchers found that DFUs accounted for almost one-third of the expenditures for diabetes care in healthcare systems.^{5,6}

Treatment of DFUs is often challenging. Bacterial colonisation of ulcers is commonly involved in healing delay, and infection is associated with high risk of treatment failure.⁷ Moreover, DFU relapse occurs in approximately 40% of patients

within 1 year from remission.^{2,8} These challenges result in unhealed DFUs in around 20% of patients within 1 year of treatment. Well-established DFU managing options, such as surgical debridement, dressings, wound offloading, vascular assessment, active infection management, and glycaemic control, are available; however, a wide spectrum of novel interventions is being developed continuously to improve wound healing.

In this review, we discuss the rationale for the current standard of DFU care. We also present evidence for a therapeutic approach aimed at meeting the unmet needs and improving DFU wound healing outcomes, by using antimicrobial photodynamic therapy with RLP068.

Methods

A narrative review of the literature was performed by retrieving relevant articles in PubMed; the following keywords were used for searches: diabetic ulcer, diabetes, antimicrobial photodynamic therapy, and RLP068. In addition, the authors report four exemplary cases recently treated following the

reported evidence and obtaining good results, as expected. These case reports are presented to the reader as tutorial examples.

Underlying mechanisms

Patients suffering from diabetic ulcers usually develop pathophysiologic complications, such as atherosclerosis, diabetic peripheral neuropathy, and metabolic imbalances.

Atherosclerosis leads to decreased blood flow in large- and medium-size vessels, due to increased thickness of capillary basement membrane, reduced elasticity, and lipid deposits in vessel walls. Small vessel ischaemia occurs in later stages of the disease. Peripheral neuropathy affects the sensory, motor, and autonomic nervous systems. There are several causes of neuropathy, including vascular disease occluding the vasa nervorum, endothelial dysfunction, chronic hyperosmolarity, and increased intake of sorbitol and fructose.⁹

Peripheral sensory neuropathy is the cause of most DFUs because of minor traumas or thermal injury. These traumas and injuries are not usually perceived by the patient and therefore remain untreated unless a routine evaluation is performed.⁹

Peripheral motor neuropathy may induce abnormal foot anatomy and biomechanics, including clawing of toes, acquiring high arch and subluxed metatarsophalangeal joints, evolving of excess pressure on the foot area involved, formation of callus, and developing ulcers. Peripheral autonomic neuropathy is a cause of deficient sweating leading to dry and cracking skin. Tissue viability and healing capability are reduced in the presence of vascular insufficiency. Moreover, diabetes metabolic imbalances lead to impaired neutrophil function and therefore slow wound healing.⁹

Diagnosis of colonisation and infection

Diagnosing infections in DFUs is a crucial step for choosing an appropriate therapy. If left untreated, infections of the DFUs can lead to lower extremity amputation and occasionally infection-related death.⁷ Although an often-forgotten principle, only infected foot wounds require systemic antimicrobial therapy, whilst colonised lesions should receive topical treatment. Nevertheless, diagnosing an infection can sometimes be a difficult task because of continuous colonisation and peripheral neuropathy, vascular disease and inflammation. Continuous infection and colonisation lead to inconclusive diagnosis whereas peripheral neuropathy and vascular disease mask the inflammation, which is a diagnosis marker for DFUs in soft tissues or bones.

Diagnosis starts with reviewing the patient history and performing a physical examination followed by serological tests. Erythrocyte sedimentation rate in osteomyelitis may

be especially helpful although some of the available tests, including bone biomarkers and procalcitonin, are not very specific. Accurately obtained soft tissue culture and bone specimens can diagnose and define the pathogens accountable for diabetic foot infections. A standard X-ray test is the first imaging approach; however, when this is inadequate or more details of bone or soft tissue abnormalities are needed, magnetic resonance imaging (MRI) can be used.¹⁰

Diagnosis of diabetic foot-related osteomyelitis is particularly challenging. Usually, recurrent infected soft tissue wounds lead to bone involvement and diabetic foot osteomyelitis. Moreover, bone infections can sometimes result from apparently clinically uninfected ulcers. 'Sausage toe', a red, swollen, and warm digit, is a diagnostic feature of diabetic foot osteomyelitis. The only pathognomonic clinical symptom for osteomyelitis is the presence of bone fragments in the wound, dressing, or debridement.¹⁰

Standard of care

Surgical debridement, dressings, wound offloading, vascular assessment, active infection management, and glycaemic control are the essential standard of care for DFUs and may be used with a multidisciplinary approach combined with a patient education program.^{7,9,11,12}

A review of the literature suggested that tight glycaemic control is an effective tool for prevention or delay in neuropathy development in patients with type 1 diabetes or neuropathy progression reduction in some patients with type 2 diabetes.¹³

The removal of necrotic and hyperkeratotic tissue promotes ulcer healing. A strong debridement with surgery is recommended for ulcer wounds, especially for those with bone and soft tissue involvement.¹⁴ An analysis of a standardised wound care protocol supported by a combined multidisciplinary team during a 10-year period showed a reduction in amputation rates in diabetic foot patients, due to efficient on-time debridement.¹⁵

Dressings represent a defence from external contaminants and promote absorption of ulcer exudate. A wide variety of foot dressings are available along with increasingly advanced methods of promoting wound healing; however, the efficiency of new foot dressings in wound healing compared with past models is very limited.¹⁴

Offloading pressure to the ulcer area can decrease repeated injury, improve vascularisation, and promote repair. It can be obtained with crutches, wheelchairs, and castings. Cast walkers over the diabetic foot were found to improve ulcers in a randomised controlled trial, and the 'total contact cast' was the most effective offloading device.¹⁶

Antiplatelet drugs are the primary therapy for vascular defect; however, surgical bypass may be needed in some patients. In addition, revascularisation of ischaemic legs results in improved

reperfusion, which is associated with a decreased frequency of foot amputations in patients with DFUs.¹⁴

Infected DFUs require appropriate systemic antibacterial therapy, usually based on antibiotics chosen by tissue and bone cultures, although broad-spectrum drugs are often used. Gram-positive bacteria account for a significant percentage of infections with an increasing occurrence of the methicillin-resistant *Staphylococcus aureus* (MRSA), in recent years. Osteomyelitis in patients with diabetes necessitates aggressive surgical intervention, in addition to antibiotic treatment. Treatment duration varies from 2 to 6 weeks, depending on the severity of infection and surgical debridement.¹⁷

Uninfected ulcers are nonetheless colonised, and the presence of microorganisms delays ulcer healing. Local treatment is usually based on topical antibiotics.

Unmet needs and photodynamic therapy

In a minority of patients, DFUs would not heal with standard treatment, or healing would be associated with a very high social burden, such as long-lasting care and high costs, and pose medical issues due to the low efficacy of interventions.¹⁶ Widespread and increasing bacterial antibiotic resistance, in addition to fungal infections, has provided the necessary impetus to find alternative drugs and/or therapies. Additionally, several therapeutic interventions have been developed based on the principles of photomedicine to overcome the issue of poor drug circulation in infected areas (exacerbated by concomitant ischaemia), with the aim of killing microbial agents whilst leaving the surrounding host mammalian cells quite unharmed. Such techniques use absorption of photons by specific chromophores. For example, photodynamic therapy (PDT) is a relatively novel strategy.^{18,19} This technique employs a photosensitizer, a dye that is activated by light of appropriate wavelength. Once activated, the dye acts as an intermediate to generate reactive oxygen species (ROS), which initiate further oxidative responses locally with components of the bacterial cell wall, cell membranes, enzymes, or nucleic acids. However, one of the challenges in employing PDT as an antibacterial strategy is to look for appropriate photosensitizers that would kill the bacteria without affecting the neighbouring host cells.²⁰

Phenothiazinium and its derivatives, which include methylene blue, Rose Bengal, and toluidine blue O, are a class of first-generation photosensitizers (PSs) that were initially investigated for PDT of solid cancers. These PSs are commonly employed in antimicrobial photodynamic therapy (APDT) because of their high binding affinity for both Gram-positive and Gram-negative bacteria. Methylene blue derivatives have been developed to increase efficacy.²¹

Antimicrobial PDT can be performed with cationic PSs in both Gram-positive and Gram-negative species. Cationic

phenothiazinium-, phthalocyanine-, and porphyrin derivatives have been shown to significantly enhance phototoxicity in both Gram-positive and Gram-negative species.²¹ Phthalocyanines are heterocyclic macrocycle aromatic compounds, with maximum excitation at longer wavelengths (typically >660 nm).²¹

When irradiated with visible light, phthalocyanines photosensitize a variety of microbial pathogens, including Gram-positive and Gram-negative bacteria, independent of the antibiotic sensitivity of the treated pathogens.^{22,23} *In vitro* studies found a high selectivity of *S. aureus* photoinactivation without binding to important constituents of potential host tissues, such as human fibroblasts and keratinocytes.²³

PDT with RLP068

RLP068 is a cationic zinc phthalocyanine derivative, activated by exposure to red light. It was developed as a topical treatment for superficial bacterial and fungal infections. Following photoactivation of RLP068, singlet oxygen and other ROS are produced, resulting in a rapid, broad range, bactericidal, and fungicidal effect.²⁴ Furthermore, due to the large number of cellular targets and the rapidity of action, the chance of developing treatment resistance by pathogens is very low. RLP068 was effective and safe in experimental studies on animal models of infected skin ulcers.²⁵

A randomised, double-blind, parallel series, and placebo-controlled phase II trial published in 2014 demonstrated the efficacy of PDT with RLP068 on total and pathogen microbial load of diabetic ulcers.¹⁸ In that study, three concentrations of RLP068 (0.10%, 0.30%, and 0.50%) were used as add-ons to systemic treatment with amoxicillin and clavulanic acid. Total and pathogenic microbial loads on days 1, 3, 8, and 15 were measured after photoactivation with 689 nm red light. In total, 62 patients aged ≥18 years, with type 1 or type 2 diabetes and infected foot ulcers, with an area of 2–15 cm² and a maximum diameter of ≤4.6 cm took part in the trial. One session of PDT with RLP068 determined a dose-dependent reduction in total and pathogenic microbial loads. It was significant for a gel concentration of 0.30%. The effect of the drug was at its maximum immediately following illumination, vanished over time, and was only borderline significant after 3 days. This seems compatible with administration every other day or three times a week. No safety issues emerged from the analysis of adverse events, and systemic absorption of RLP068 was negligible. This study could not demonstrate an overall clinical improvement due to its design. Moreover, a single administration of an antimicrobial agent cannot be expected to determine relevant clinical outcomes in diabetic ulcers. Interestingly, there was a trend towards a reduction in perfusion, extent, depth, infection, and sensation scores in patients treated with the higher concentrations (0.30% and 0.50%) of RLP068, although the sample size was too small to perform a formal statistical analysis.¹⁸

Extensive clinical studies are expected to evaluate the effect of repeated administration of photodynamic therapy with RLP068 on outcomes.

Case reports

Based on available evidence, the authors of this article treated some patients with DFUs; four exemplary cases are reported here, showing results in agreement with the clinical study, obtained in the real-life setting.

In this experience with four patients affected by DFU, PDT was performed with the photosensitiser, RLP068 (VULNOFAST plus; Molteni Therapeutics S.R.L., Italy) twice a week according to the manufacturer's instructions. A single dose of RLP068 was applied using a sterile syringe on the wound, which was covered with a Tegaderm™ patch and a nontransparent bandage. Thirty minutes after the application, the ulcer was illuminated for 8 minutes by a portable LED light device (VULNOLIGHT, Molteni Therapeutics S.R.L., Italy) with a red light at 630 nm wavelength, providing a total energy of 60 J/cm². The ulcer was then washed with saline solution to remove the residues of the photosensitiser and covered with an absorbent foam dressing.

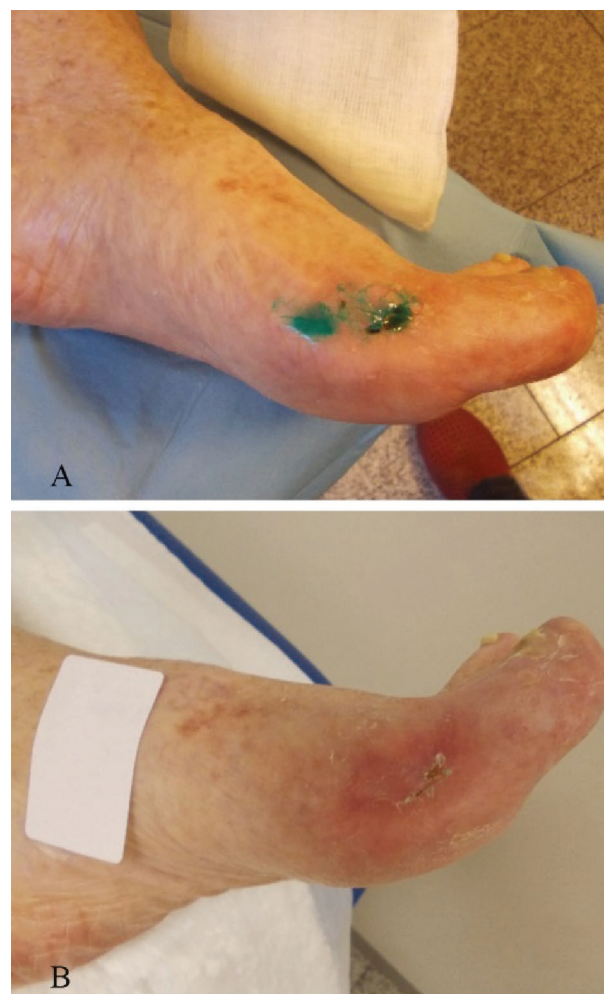
Patients were chosen based on clinical evaluation, as eligible to gain benefit from the treatment. In accordance with the World Medical Association Declaration of Helsinki, all the data referring to the patients are published in anonymous way, without any details allowing re-identifying the patient.

Case report 1

A 77-year-old female with a history of diabetes and peripheral vascular disease was referred by her local physician for treatment of a non-healing ischaemic foot ulcer over a period of 2 months. The patient suffered from essential thrombocythaemia and was treated with hydroxyurea. Medical history also included hypertension, which was diagnosed 10 years before first visit. A Doppler ultrasound of the lower limb revealed critical ischaemia of the superficial femoral artery without blood flow at the anterior and posterior tibial arteries. The transcutaneous oxygen pressure (TcPO₂) around the ulcer was 31 mmHg, suggesting that the blood supply to the ulcer was significantly decreased. X-ray examination and MRI did not show abnormality in the foot and ankle. The physical examination revealed an ischaemic ulcer of 1×1 cm at the apex of the great toe with exudate and an ischaemic dry ulcer of 2×2.5 cm at the medial aspect of the first metatarsus-phalangeal (MTP) joint of the right foot. The patient reported severe pain.

The patient underwent revascularisation with angioplasty. Three days later, surgical debridement was performed, and hyaluronic acid-based matrix (i.e. Hyalomatrix®) was applied. Two months later, the ulcers were covered with fresh granulation tissue and therefore received a skin graft. During follow-up visits, the ulcer of the toe completely healed, and the ulcer at the first MTP joint improved but did not heal completely (Figure 1A). Pain was still present with a score of

Figure 1. A 77-year-old female with an ischaemic ulcer of the medial aspect of the first metatarsus-phalangeal joint, at baseline (A) and 10 days after photodynamic therapy with RLP068 (B).



7 on a visual analogue scale (VAS). Tissue culture obtained from the ulcer revealed the presence of MRSA infection. Although arterial revascularisation and skin substitute had improved the lesion, an antimicrobial treatment was necessary to obtain complete cure. Because of advanced age and of concomitant treatment with several drugs, it was decided to use photodynamic therapy, instead of systemic antibiotics.

PDT with RLP068 was then performed. The ulcer completely healed after eight applications of PDT, and the patient reported a decrease of pain from 7 to 0 on the VAS scale (Figure 1B). At 3 months of follow-up, the patient was able to ambulate with no gait abnormalities and was pain free.

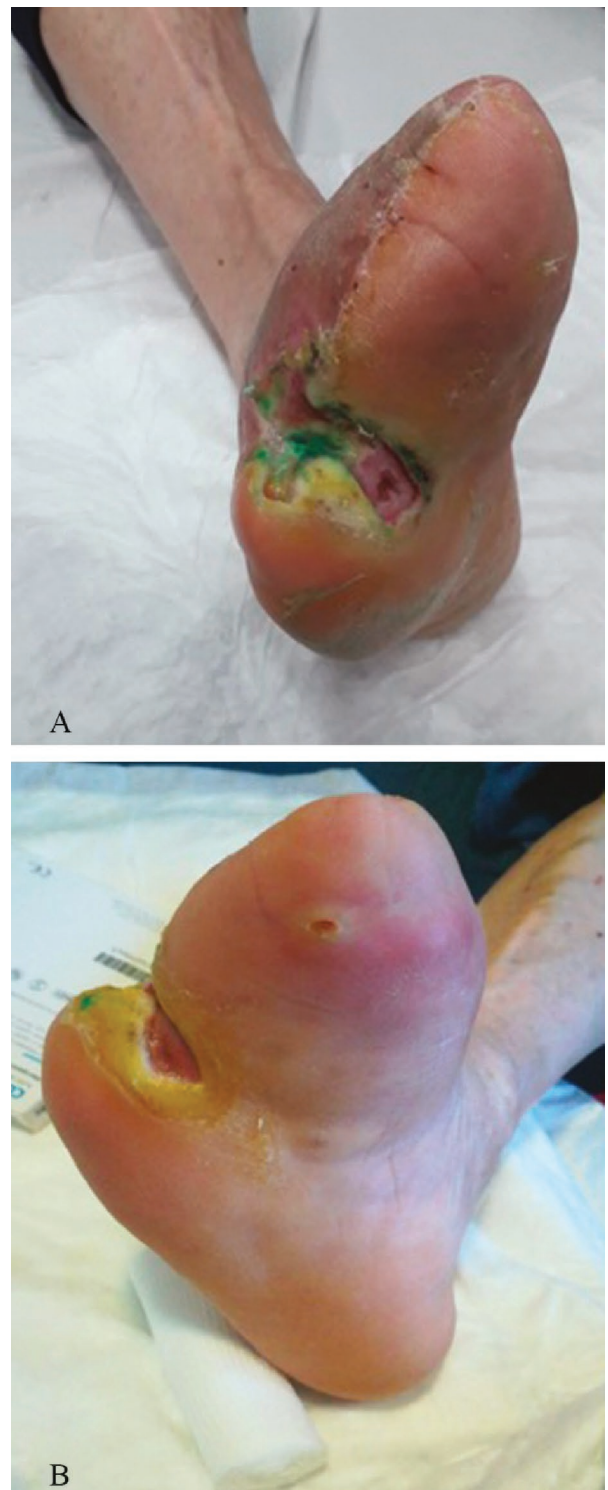
Case report 2

A 67-year-old man presented in an outpatient department with a history of chronic medial malleolus venous ulcer.

Figure 2. A 67-year-old man with a medial malleolus venous ulcer. (A) The ulcer after surgery and before photodynamic therapy with RLP068. (B) The ulcer after surgery and after eight sessions of photodynamic therapy with RLP068.

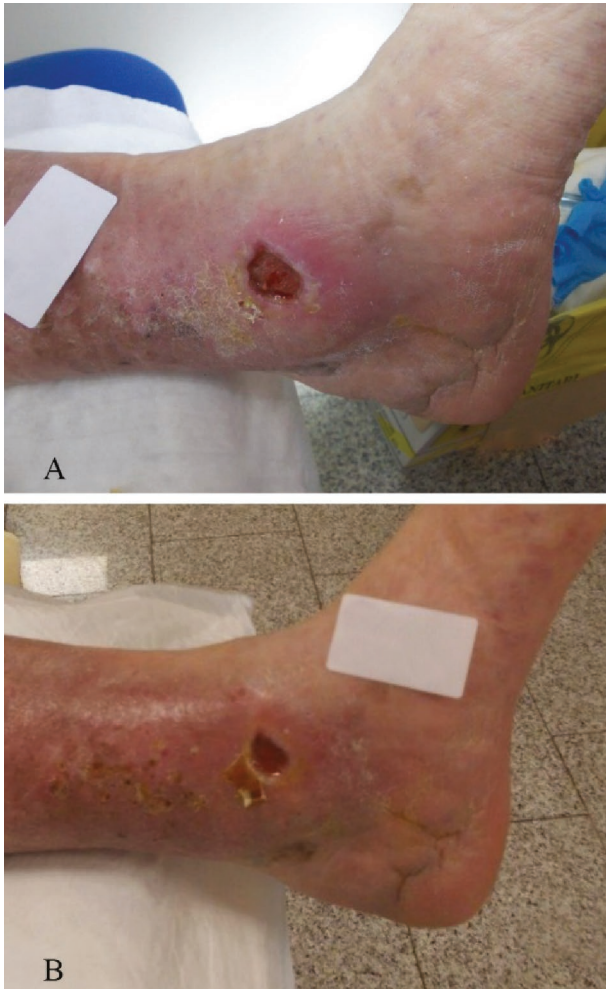

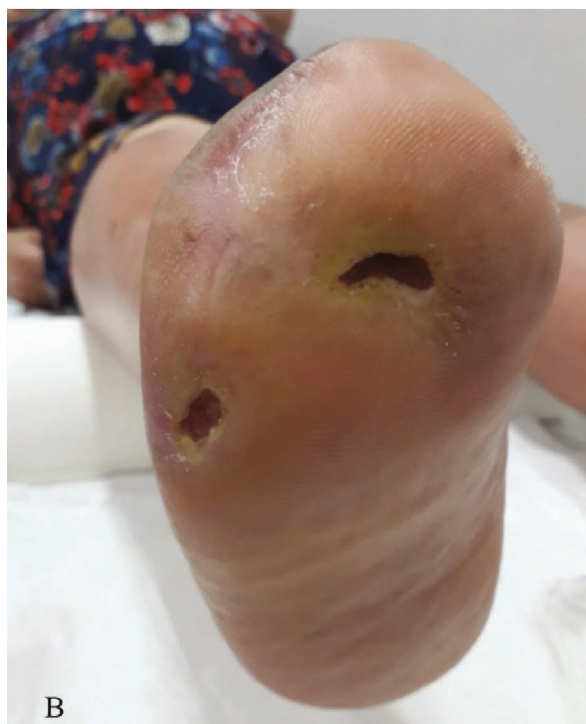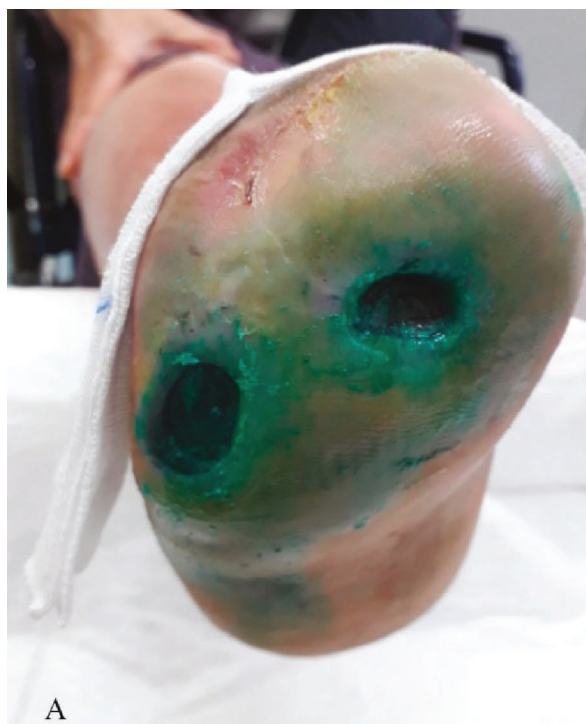
Figure 3. A 61-year-old man with an amputated toe. The painful ulcer of the stump (A) was reduced in size and pain levels after photodynamic therapy with RLP068 (B).



Comorbidities included diabetes, hypertension, and hepatic cirrhosis. Three years before presentation, the patient underwent femoral-popliteal bypass for arterial insufficiency. Peripheral pulses were normal, and Doppler ultrasonographic examination of the lower limb revealed normal arterial blood flow. The ulcer had a mild malodorous wound covering and the surrounding skin was erythematous and xerotic. Pain was scored as 9 on the VAS scale. Based on the clinical findings, surgical debridement was performed, and the wound was covered with hyaluronic acid-based matrix (i.e. Hyalomatrix®). Intraoperative cultures revealed multibacterial infection with antibiotic-resistant *S. aureus* and *Pseudomonas aeruginosa*. Antibiotic therapy with a fluoroquinolone (i.e. levofloxacin) was given for 3 weeks. Three months after surgery the ulcer was still present, but it was smaller (Figure 2A) and pain was scored as 7 on the VAS scale. Tissue culture from the ulcer revealed the

presence of MRSA infection but with multidrug resistance (i.e. to fluoroquinolones and trimethoprim/sulfamethoxazole). To overcome the problem of drug resistance, further antimicrobial treatment employed PDT.

Figure 4. A 50-year-old woman with two ulcers of the stump in right foot. The infected ulcer (A) was clear with reduced size after photodynamic therapy with RLP068 (B).



Case report 3

A 61-year-old man was referred to a diabetes clinic in Naples, Italy, in November 2018, because of a painful plantar ulcer of the right foot. His toes had been amputated some years before, and remnants of the first toe were present. The patient had been diagnosed with type 2 diabetes in 2000 and had been treated with oral antidiabetic agents for 4 years and later with insulin. He was affected with blood hypertension, ischaemic heart disease, dyslipidaemia, and hyperuricaemia. Since 2005, he had neuropathy and had received gabapentin. At presentation, the patient reported persisting paraesthesia, and patellar reflex was absent. The X-ray of the foot showed arthrosis and bone demineralisation. Clinical observations revealed that the ulcer was infected at presentation. An antimicrobial treatment was necessary, but the patient desired to avoid systemic antibiotics because he was receiving several other drugs for diabetes, hypertension, heart disease, and hyperuricaemia. It was decided to perform antimicrobial PDT.

In November 2018, the ulcer size was 4×1 cm, and PDT with RLP068 was initiated (Figure 3A). After 10 days, signs of infection had disappeared, and the ulcer size was reduced to 3×0.5 cm (60% reduction). Diameter reduction progressed during the following weeks. In January 2019, no infection was present, and the ulcer size was 2×0.5 cm (Figure 3B).

Case report 4

A 50-year-old woman was visited in November 2018 after complaining about two painful ulcers of the right foot. The patient was affected with type 2 diabetes (since 2002), blood hypertension, ischaemic heart disease, peripheral arterial disease, obesity, and proliferative retinopathy. The toes of the right foot were amputated in 2016. The skin of the residual limb was erythematous and dyschromic, and the ulcers on the stump were infected. Peripheral pulses of the lower limbs were present. A computerised tomography scan of the right foot did not show signs of destructive bone defects. The patient reported paraesthesia of the residual foot. The size of ulcers was 2×1.5 cm and 2×1.2 cm (Figure 4A). In this serious case, with risk of further amputation, PDT was added to previous therapies because healing was necessary in a short time. Five months after PDT, the infection was resolved, and dyschromia was reduced. Ulcer size was also reduced by 20%, although the lesion was not completely cured (Figure 4B).

Conclusions

Diabetic ulcer healing is often delayed by microbial infection or colonisation. Failure to heal ulcers in patients with diabetes may have serious outcomes, such as amputation. Widespread use of systemic antibiotics for ulcer treatment leads to frequent occurrence of bacterial resistance and has often little effect

After eight sessions of PDT with RLP068, the ulcer size was considerably reduced, and the patient was pain free (Figure 2B). At the last follow-up, the patient was very satisfied with the clinical outcome and could ambulate with no aids. The ulcer was covered with a simple dressing.

because of vascular damage-induced reduction in drug delivery in the ulcers. PDT was demonstrated to reduce the total and pathogenic microbial loads in diabetic ulcers. This article described effective treatment of both mild (limited novel ulcers) and severe cases (old ulcers in amputated limbs) of DFUs in the real-life setting. PDT with RLP068 facilitated ulcer healing and reduced the infection load. It was well tolerated, in

agreement with previously published evidence. The use of PDT was valuable for the antimicrobial treatment of patients already receiving several drugs, with ulcers infected by drug-resistant bacteria, or in addition to other therapies in serious cases. Clinical studies are expected to confirm the efficacy of PDT with RLP068 on wider samples, and to define the best procedure for each type of patient.

Contributions: All named authors meet the International Committee of Medical Journal Editors (ICMJE) criteria for authorship for this article, take responsibility for the integrity of the work as a whole, and have given their approval for this version to be published.

Disclosure and potential conflicts of interest: The authors declare that they have no conflicts of interest. The International Committee of Medical Journal Editors (ICMJE) Potential Conflicts of Interests form for the authors is available for download at <http://www.drugsincontext.com/wp-content/uploads/2019/08/dic.212610-COI.pdf>

Acknowledgments: Content Ed Net provided editorial assistance, with the helpful support of Laura Brogelli, PhD, in the drafting of the manuscript and of Mr Bilal Bham and Hussein Hijazi in the final reading of the manuscript for English language improvement. The authors thank Molteni Farmaceutici for unrestricted support.

Funding declaration: Editorial assistance was funded by Molteni Farmaceutici, Scandicci FI, Italy.

Copyright: Copyright © 2019 Martinelli N, Curci V, Quarantiello A, Saldamacchia G. <https://doi.org/10.7573/dic.212610>. Published by Drugs in Context under Creative Commons License Deed CC BY NC ND 4.0 which allows anyone to copy, distribute, and transmit the article provided it is properly attributed in the manner specified below. No commercial use without permission.

Correct attribution: Copyright © 2019 Martinelli N, Curci V, Quarantiello A, Saldamacchia G. Published by Drugs in Context under Creative Commons License Deed CC BY NC ND 4.0.

Article URL: <https://www.drugsincontext.com/the-benefits-of-antimicrobial-photodynamic-therapy-with-rlp068-in-the-management-of-diabetic-foot-ulcers/>

Correspondence: Nicolò Martinelli, IRCCS Istituto Ortopedico Galeazzi, Via Riccardo Galeazzi, 4, 20161 Milan, Italy. N.Martinelli@unicampus.it

Provenance: submitted; externally peer reviewed.

Submitted: 15 July 2019; **Peer review comments to author:** 25 July 2019; **Revised manuscript received:** 30 July 2019; **Accepted:** 31 July 2019; **Publication date:** 20 August 2019.

Drugs in Context is published by BioExcel Publishing Ltd. Registered office: Plaza Building, Lee High Road, London, England, SE13 5PT.

BioExcel Publishing Limited is registered in England Number 10038393. VAT GB 252 7720 07.

For all manuscript and submissions enquiries, contact the Editor-in-Chief gordon.mallarkey@bioexcelpublishing.com

For all permissions, rights and reprints, contact David Hughes david.hughes@bioexcelpublishing.com

References

1. Boulton AJ, Armstrong DG, Albert SF, et al. Comprehensive foot examination and risk assessment. A report of the Task Force of the Foot Care Interest Group of the American Diabetes Association, with endorsement by the American Association of Clinical Endocrinologists. *Phys Ther*. 2008;88:1436–1443.
2. Armstrong DG, Andrew JM, Boulton AJ. Diabetic foot ulcers and their recurrence. *New Engl J Med*. 2017;376:2367–2375. <http://dx.doi.org/10.1056/NEJMr1615439>
3. Walsh JW, Hoffstad OJ, Sullivan MO, Margolis DJ. Association of diabetic foot ulcer and death in a population-based cohort from the United Kingdom. *Diabet Med*. 2016;33:1493–1498. <http://dx.doi.org/10.1111/dme.13054>
4. Goodridge D, Trepman E, Embil JM. Health-related quality of life in diabetic patients with foot ulcers: literature review. *J Wound Ostomy Continence Nurs*. 2005;32:368–377. <http://dx.doi.org/10.1097/00152192-200511000-00007>
5. Skrepnek GH, Mills JL Sr, Lavery LA, Armstrong DG. Health care service and outcomes among an estimated 6.7 million ambulatory care diabetic foot cases in the U.S. *Diabetes Care*. 2017;40(7):936–942. <http://dx.doi.org/10.2337/dc16-2189>
6. Driver VR, Fabbri M, Lavery LA, Gibbons G. The costs of diabetic foot: the economic case for the limb salvage team. *J Vasc Surg*. 2010;52:17s–22s. <http://dx.doi.org/10.1016/j.jvs.2010.06.003>
7. Lipsky BA, Berendt AR, Cornia PB, et al. 2012 Infectious Diseases Society of America clinical practice guideline for the diagnosis and treatment of diabetic foot infections. *Clin Infect Dis*. 2012;54:e132–173. <http://dx.doi.org/10.1093/cid/cis346>

8. Prompers L, Schaper N, Apelqvist J, et al. Prediction of outcome in individuals with diabetic foot ulcers: focus on the differences between individuals with and without peripheral arterial disease. The EURODIALE study. *Diabetologia*. 2008;51:747–755. <http://dx.doi.org/10.1007/s00125-008-0940-0>
9. Packer CF, Manna B. Diabetic ulcer. StatPearls. Accessed July 2019. <https://www.ncbi.nlm.nih.gov/books/NBK499887/>
10. Glaudemans AW, Uçkay I, Lipsky B. Challenges in diagnosing infection in the diabetic foot. *Diabet Med*. 2015;32:748–759. <http://dx.doi.org/10.1111/dme.12750>
11. Lavery LA, Davis KE, Berriman SJ, et al. WHS guidelines update: diabetic foot ulcer treatment guidelines. *Wound Repair Regen*. 2016;24:112–126. <http://dx.doi.org/10.1111/wrr.12391>
12. Everet E, Mathioudakis N. Update on management of diabetic foot ulcers. *Ann N Y Acad Sci*. 2018;1411(1):153–165. <http://dx.doi.org/10.1111/nyas.13569>
13. Ang L. Glucose control and diabetic neuropathy: lessons from recent large clinical trials. *Curr Diabetes Rep*. 2014;14:528. <http://dx.doi.org/10.1007/s11892-014-0528-7>
14. Lim JZ, Ng NS, Thomas C. Prevention and treatment of diabetic foot ulcers. *J R Soc Med*. 2017;110(3):104–109. <http://dx.doi.org/10.1177/0141076816688346>
15. Hsu CR, Chang CC, Chen YT, Lin WN, Chen MY. Organization of wound healing services: the impact on lowering the diabetes foot amputation rate in a ten-year review and the importance of early debridement. *Diabetes Res Clin Pract*. 2015;109:77–84. <http://dx.doi.org/10.1016/j.diabres.2015.04.026>
16. Armstrong DG, Lavery LA, Wu S, Boulton AJ. Evaluation of removable and irremovable cast walkers in the healing of diabetic foot wounds: a randomised controlled trial. *Diabetes Care*. 2005;28:551–554. <http://dx.doi.org/10.2337/diacare.28.3.551>
17. Rao N. Anti-infective therapy for foot ulcers in patients with diabetes. *Clin Orthop Relat Res*. 2005;439:87–90. <http://dx.doi.org/10.1097/01.blo.0000181497.42117.fa>
18. Mannucci E, Genovese S, Monami M, et al. Photodynamic topical antimicrobial therapy for infected foot ulcers in patients with diabetes: a randomized, double-blind, placebo-controlled study-the D.A.N.T.E (Diabetic ulcer Antimicrobial New Topical treatment Evaluation) study. *Acta Diabetol*. 2014;51:435–440. <http://dx.doi.org/10.1007/s00592-013-0533-3>
19. Raymakers JT, Houben AJ, van der Heyden JJ, Tordoir JH, Kitslaar PJ, Schaper NC. The effect of diabetes and severe ischaemia on the penetration of ceftazidime into tissues of the limb. *Diabet Med*. 2001;18:229–234. <http://dx.doi.org/10.1046/j.1464-5491.2001.00460.x>
20. Agrawal T, Avci P, Gupta GK, et al. Harnessing the power of light to treat staphylococcal infections focusing on MRSA. *Curr Pharm Des*. 2015;21:2109–2121. <http://dx.doi.org/10.2174/1381612821666150310102318>
21. Liu Y, Qin R, Zaat SAJ, Breukink E, Heger M. Antibacterial photodynamic therapy: overview of a promising approach to fight antibiotic-resistant bacterial infections. *J Clin Transl Res*. 2015;1(3):140–167. <http://dx.doi.org/10.18053/jctres.201503.002>
22. Merchat M, Bertoloni G, Giacomoni P, Villanueva A, Jori G. Meso-substituted cationic porphyrins as efficient photosensitizers of Gram-positive and Gram-negative bacteria. *J Photochem Photobiol B*. 1996;32:153–157. [http://dx.doi.org/10.1016/1011-1344\(95\)07147-4](http://dx.doi.org/10.1016/1011-1344(95)07147-4)
23. Soncin M, Fabris C, Busetti A, et al. Approaches to selectivity in the Zn(II)-phthalocyanine-photosensitized inactivation of wild-type and antibiotic-resistant *Staphylococcus aureus*. *Photochem Photobiol Sci*. 2002;1(10):815–819. <http://dx.doi.org/10.1039/B206554A>
24. Zeina B, Greenman J, Purcell WM, Das B. Killing of cutaneous microbial species by photodynamic therapy. *Br J Dermatol*. 2001;144:274–278. <http://dx.doi.org/10.1046/j.1365-2133.2001.04013.x>
25. Simonetti O, Cirioni O, Orlando F, et al. Effectiveness of antimicrobial photodynamic therapy with a single treatment of RLP068/Cl in an experimental model of *Staphylococcus aureus* wound infection. *Br J Dermatol*. 2011;164:987–995. <http://dx.doi.org/10.1111/j.1365-2133.2011.10232.x>