



Endosalpingiosis of the pediatric ileum- a surgical surprise and a therapeutic adventure: A case report

Ram Mohan B¹, Aureen Ruby D'cunha¹, Tarun John K Jacob¹, A. J Joseph², Mayur Suryavamshi³

Departments of Pediatric Surgery¹, Gastroenterology² and Pathology³ Christian Medical College Vellore, India

ABSTRACT

A diagnosis of endosalpingiosis in the pediatric population is extremely rare - in some cases it may coexist with or mimic endometriosis, and hence is missed. On the other hand, its close relationship with the development of serous tumors is an issue that needs attention. Histopathology confirms the diagnosis. Surgery is the mainstay of management and medical therapy is for symptom relief. We present a case of endosalpingiosis presenting in an unusual age group, in a new location, and describe the benefit of using off-label colchicine for adjuvant therapy.

Key Words: Endosalpingiosis, fallopian tubal epithelium, colchicine, mullerian anomalies, child.

✉ *Dr. Tarun John K Jacob*

*Associate Professor, Department of Pediatric Surgery,
Christian Medical College Vellore, India*

E-mail: tarunjki@cmcvellore.ac.in

Received: 2020-10-10 / Revisions: 2020-11-17

Accepted: 2020-12-26 / Publication Date: 2021-03-01

Introduction

Endosalpingiosis is defined as ectopic presence of ciliated cells, secretory cells and intercalated cells otherwise found in normal fallopian tubal epithelium [1,2]. It has also been described as one of a triad of non-neoplastic mullerian disorders along with endometriosis and endocervicosis [3]. Endosalpingiosis typically develops after menarche and tends to atrophy postmenopause [3]. Most commonly, however, it is encountered in the third to the fifth decade [2,4,5]. Our patient on the contrary presented early on in adolescence, which is rather unusual [6]. The words of D.H. Lawrence,

“What the eye doesn't see and the mind doesn't know, doesn't exist” very aptly applies to endosalpingiosis. Being rare and not often discussed, endosalpingiosis is often missed, as diagnosing it requires a combination of a high index of suspicion along with a good histopathological examination.

This case was intriguing in several ways as the age of presentation was younger than previously reported, the site of bowel involvement has not been reported before and a novel drug was used for adjuvant management.

Case report

A 14-year old girl was referred by pediatricians with complaints of recurrent, intermittent, spasmodic abdominal pain of 4 years duration associated with non-bilious vomiting. She did not have any history of fever, jaundice, abdominal distension, any urinary or bowel

complaints. However, as she reported a 5-kilogram weight loss during this period, she was evaluated elsewhere and empirically started on anti-tuberculous therapy with no positive results. She had attained menarche but her menstrual cycles were irregular. She did not have any dysmenorrhea or menorrhagia. There were no symptoms of any eating disorder or symptoms suggestive of any connective tissue disorder. She did not have a family history of any malignancy or exposure to tuberculosis. On clinical examination she was hemodynamically stable but thin built and poorly nourished with a soft, non-tender, scaphoid abdomen.

Her baseline blood investigations were normal. Specific tests were done to rule out a connective tissue disorder because of persistently positive antinuclear antibodies, and included a C-reactive protein (< 3.03mg/L, reference range <3.0mg/L), erythrocyte sedimentation rate (15mm/hr, reference range 0-2- mm/hr), 8 am cortisol (10 microgram/dL, reference range 10-20 micrograms/dL), albumin (5.2g/dL, reference range 3.4-5.4g/dL), indirect coombs test (negative), C3 and C4 levels (94.2 & 15.4mg/dL, reference range 80-160mg/dL and 15-45mg/dL respectively). The work up for tuberculosis was negative. Faecal calprotectin was positive, pointing to an intestinal inflammatory pathology.

Except for a non-visualized right ovary, the ultrasound imaging was unremarkable. A computerized tomography scan done demonstrated dilated small bowel loops with multiple air fluid levels with a possible transition point at the terminal ileum. In lieu of these obstructive radiological findings she was taken up for surgery.

A differential diagnosis of a terminal ileal obstructing band, tuberculosis and

inflammatory bowel disease were considered because of her chronic obstructive symptoms and imaging findings consistent with mechanical bowel obstruction.

At diagnostic laparoscopy there were multiple dense inter loop small bowel adhesions forming a fibrous cocoon leading to poor visualization and limited working space necessitating a conversion to a laparotomy. In addition to confirming the laparoscopy findings, the distal jejunal and ileal loops had multiple serosal out-pouchings (Fig. 1). There was minimal gelatinous free fluid with no peritoneal or omental deposits. The uterus, ovaries and tubes appeared normal. After complete adhesiolysis and release of the entrapped bowel from the cocoon, it was noted that there was no residual mechanical obstruction and enteric content could be milked freely into the colon. An incidentally noted Meckel's diverticulum was excised and the wall of the cocoon was sent for histopathological examination.

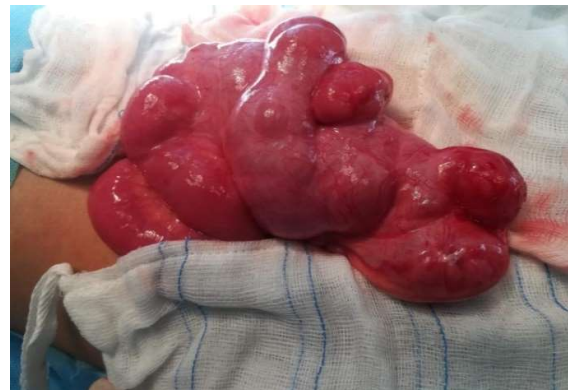

Fig. 1. Intraoperative photograph showing the ileal loops entrapped in a fibrous cocoon with scattered serial outpouchings.

She made an uneventful post-operative recovery with resumption of oral feeds from day 3. She developed an ileus a week later, which resolved with gut rest. She was pain free and on a normal diet at the time of discharge.

The histopathology on the cocoon wall had congestion, fibrosis and occasional scattered glands lined by ciliated columnar epithelium (Fig. 2) with no mitosis, atypia or endometrial strongman cells or ‘hemosiderophages’. There were no granulomas, and no evidence of malignancy or inflammatory bowel disease and the lymph nodes were reactive. A diagnosis of endosalpingiosis was made based on these findings.

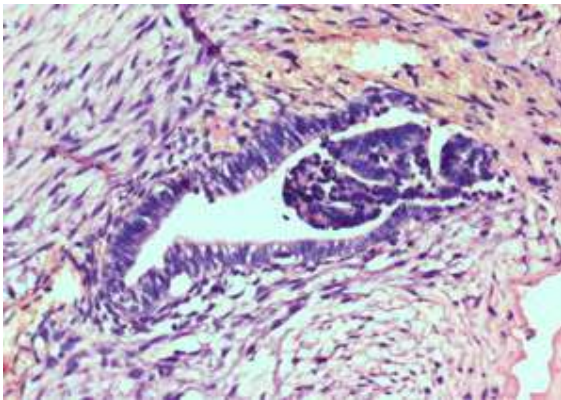


Fig. 2. Histopathological image of the cocoon wall with congestion, fibrosis and occasional scattered glands lined by ciliated columnar epithelium (Arrowheads).

In consultation with the gastroenterologists, the child was started on oral colchicine therapy because of its anti-fibrotic properties. An initial dose of 0.25mg was later hiked up to 0.5mg once daily and was continued after educating the family about possible adverse effects. At the time of discharge the child was tolerating medication well and able to have a normal oral diet. On follow up after 8 months she continued to have menstrual irregularities, but had gained 1 kilogram in weight and was symptom free. She was advised to gradually taper and stop the colchicine.

Discussion

Peritoneal mullerian inclusions were initially identified by Ries [3] in 1897, and

“endosalpingiosis” was discovered by Sampson in 1930 [1,3,4] following examination of tubal surgery specimens. As several cases are asymptomatic and the diagnosis is incidentally picked up, there is insufficient data on this condition, and establishing a prevalence remains challenging [2,4].

Literature describes several sites for endosalpingiosis, common locations including visceral pelvic peritoneum covering the uterus, fallopian tubes, ovaries and cul-de-sac [1,3,7]. The pelvic parietal peritoneum, omentum, bladder, colon and appendix, [7] periaortic area, axillary nodes, [8] spleen [9] and skin are infrequent but reported sites of occurrence. To the best of our knowledge this is the first case of small bowel endosalpingiosis to be described.

Various theories on the pathogenesis and natural history have been suggested, often overlapping with those of endometriosis [3]. Two popularly accepted ones however, are metaplasia and ectopic transport [1, 2]. PAX-8 and calretinin are useful immunohistochemical markers that can determine the cell origin of the inclusions [1]. Mural involvement has been described suggesting that invasion of the muscular coat of hollow pelvic viscera is possible, thereby justifying bowel involvement [7,10]. As figure 1 demonstrates, endosalpingiosis may also appear as small, cystic blebs on the peritoneum and on pelvic and abdominal surfaces that are clear to white in color [2].

More often than not, the diagnosis of endosalpingiosis is arrived at incidentally during surgery for other gynecological problems, especially ovarian serous neoplasms [1, 2]. Since it is not obvious to the naked eye and often coexists with endometriosis, [5] the diagnosis comes as a postoperative

histopathological surprise as in our patient. There has been limited data to guide the management of this condition. Unless surgical excision is complete, recurrences can occur [2]. However since the diagnosis is often made in retrospect, the possibility of complete resection remains a formidable challenge. Medical management for endosalpingiosis is directed at symptom management [2, 3] and includes the use of oral contraceptives, danazol and gonadotropin releasing hormone analogues [3]. Bladder lesions are predominantly surgically managed, [3] and when associated with malignancy, treatment is directed at the malignancy. Note has been made about the concurrence with serous ovarian neoplasms [1,3] and infertility, and our patient was detailed about the same and instructed to be on close follow up.

Colchicine, a plant alkaloid and an anti-mitotic drug is most commonly known for its use in gout and Familial Mediterranean Fever [11]. Colchicine inhibits mRNA expression of transforming growth factor β , thereby producing anti-inflammatory action. In addition to having strong anti-fibrogenic effects [12], it has a low side effect profile and cost. There have been no clinical trials for its use in endosalpingiosis, however, it has been used successfully in anecdotal experience at our institution. Though not without adverse effects, [11] a multi-disciplinary team of treating physicians considered it safe for use as the dose was small and the intended duration was limited. The use of colchicine is also considered when surgical resection is incomplete and hormonal treatment is ineffective [12].

Conclusion

- Endosalpingiosis owing to its rarity, and often being an incidental surgical finding,

requires a high index of suspicion for diagnosis teamed with a detailed histopathological examination.

- The management of such infrequently encountered and complex cases warrants a multidisciplinary team involvement with sound interdepartmental collaboration and systematic follow up.
- Colchicine, pending further studies, could become a promising modality of treatment of symptomatic endosalpingiosis.

Compliance with ethical statements

Conflicts of Interest: None.

Financial disclosure: None.

Consent: Patient confidentiality has been maintained and written consent has been obtained from the patient's parents for the publication of patient information and clinical pictures and can be provided as required.

Open Access Statement

This is an open access journal which means that all content is freely available without charge to the user or his/her institution under the terms of the Creative Commons Attribution Non-Commercial License (<http://creativecommons.org/licenses/by-nc/4.0>). Users are allowed to read, download, copy, distribute, print, search, or link to the full texts of the articles, without asking prior permission from the publisher or the author.

ORCID iD of the author (s)

Ram Mohan B / 0000-0003-1551-5720

Aureen Ruby D'cunha / 0000-0001-7808-2091

Tarun John K Jacob / 0000-0003-4451-5623

References

- [1]Prentice L, Stewart A, Mohiuddin S, et al. What is endosalpingiosis? *Fertil Steril.* 2012;98(4):942-47.

- [2] Ong NCS, Maher PJ, Pyman JM, et al. Endosalpingiosis, an unrecognized condition: report and literature review. *Gynecol Surg.* 2004;1:11-14.
- [3] <https://www.uptodate.com/contents/endosalpingiosis> (Access date: April 2019).
- [4] Min Hou, Lipai Chen, Jingping Yun. Facts about Endosalpingiosis. *Open J Obstet Gynecol.* 2015;5(10):523-27.
- [5] Zangmo R, Singh N, Kumar S, et al. Second Look of Endosalpingiosis: A Rare Entity. *J Obstet Gynaecol India.* 2017;67(4):299–301.
- [6] Heerema AE, Laufer MR, Barbieri RL. Endosalpingiosis: Description of presentation and follow up. *J Pediatr Adolesc Gynecol.* 1996;9(3):150.
- [7] McCluggage WG, Clements WD. Endosalpingiosis of the colon and appendix. *Histopathology.* 2001;39(6):645-46.
- [8] Stolnicu S, Preda O, Kinga S, et al. Florid, papillary endosalpingiosis of the axillary lymph nodes. *Breast J.* 2011;17(3):268-72.
- [9] Tanahashi J, Kashima K, Daa T, et al. Florid cystic endosalpingiosis of the spleen. *APMIS.* 2006;114(5):393-98.
- [10] Cajigas A, Axiotis CA. Endosalpingiosis of the vermiform appendix. *Int J Gynecol Pathol.* 1990;9(3):291-95.
- [11] Leung YY, Yao Hui LL, Kraus VB. Colchicine--Update on mechanisms of action and therapeutic uses. *Semin Arthritis Rheum.* 2015;45(3):341–50.
- [12] Solak A, Solak İ. Abdominal cocoon syndrome: preoperative diagnostic criteria, good clinical outcome with medical treatment and review of the literature. *Turk J Gastroenterol.* 2012;23(6):776-9.