



Influence of Freezing on Muscles of Rainbow Trout (*Oncorhynchus mykiss*): A Histological and Microbiological Study

M. Strateva¹, G. Penchev¹, D. Stratev^{2*} 

1. Department of Veterinary Anatomy, Histology and Embryology, Faculty of Veterinary Medicine, Trakia University, 6000 Stara Zagora, Bulgaria

2. Department of Food Hygiene and Control, Veterinary Legislation and Management, Faculty of Veterinary Medicine, Trakia University, 6000 Stara Zagora, Bulgaria

HIGHLIGHTS

- After freezing twice, deformities were observed resulting in completely destructured muscle fibers.
- Muscles were damaged to a greater extent after freezing twice and thawing.
- Microbiological indicators did not change significantly after freezing.

Article type

Original article

Keywords

Oncorhynchus mykiss
Muscles
Freezing
Histology
Food Microbiology

Article history

Received: 4 Oct 2020
Revised: 11 Dec 2020
Accepted: 23 Dec 2020

Acronyms and abbreviations

CFU=Colony Forming Unit

ABSTRACT

Background: Freezing is a common and ancient method for preservation of foods which is applicable both under household and industrial conditions. The objective of the study was to establish histological and microbiological changes in dorsal and abdominal muscles of rainbow trout (*Oncorhynchus mykiss*) after freezing once and twice.

Methods: Forty-five fresh rainbow trout specimens were distributed into three groups of 15 fish each. The first group was subjected to histological and microbiological analysis immediately after delivery at the laboratory. The second fish group was frozen at -18 °C for 15 days, while the third group of fish was frozen at -18 °C for 15 days, thawed and frozen again at -18 °C for 15 days. Data were analyzed using GraphPad InStat 3 software.

Results: After freezing once, muscle fibers with intracellular void spaces were observed and retained stable peripheral boundary. In some muscle fibers, the endomysium boundaries were visible and with retained integrity. After freezing twice, damages and deformities were observed resulting in completely destructured muscle fibers. Large void spaces among the muscle fibers and bundles were greatly the result of shrinking and grouping of fibers and the laceration of endomysium and perimysium internum. Total microbial count and Enterobacteriaceae count had no significant differences ($p>0.05$) between fresh, frozen once, and frozen twice trout.

Conclusion: Muscles of rainbow trout (*O. mykiss*) are histologically damaged to a greater extent after freezing twice and thawing. However, microbiological indicators had no change significantly after freezing once and twice.

© 2021, Shahid Sadoughi University of Medical Sciences. This is an open access article under the Creative Commons Attribution 4.0 International License.

Introduction

Freezing is a common method for preservation of foods which is applicable both under household and industrial

conditions (Jiang et al., 2019; Okuda et al., 2020). After the onset of death, fish muscles start to lose their fresh-

* Corresponding author (D. Stratev)

✉ E-mail: deyan.stratev@trakia-uni.bg

ORCID ID: <https://orcid.org/0000-0003-4907-1590>

To cite: Strateva M., Penchev G., Stratev D. (2021). Influence of freezing on muscles of rainbow trout (*Oncorhynchus mykiss*): a histological and microbiological study. *Journal of Food Quality and Hazards Control*. 8: 2-12.

ness quickly (Shi et al., 2020). Freezing may retain within optimal borders nutrients in the frozen fish (Akter et al., 2020). Deterioration of the quality of frozen meat may be due to various factors of physiological nature (Jiang et al., 2019). Freezing is a preferred method since the present ice crystals inhibit microbial growth and chemical reactions (Hafezparast-Moadab et al., 2018). That effect is achieved quickly with no need to use any additional methods that could affect the final quality (Luan et al., 2018). It is worth noting that the state of meat prior to freezing, the freezing and storage technology are directly related to the final state of meat (Jiang et al., 2019).

Under the influence of low temperatures, water in the muscle tissue begins to freeze and leads to the formation of ice mass (Shi et al., 2020). Ice crystals are different in size depending on the freezing speed. Numerous and small in size are the crystals when freezing at great speed (Dalvi-Isfahan et al., 2019). Large crystals cause large scale damages of tissues as a result of the slow speed of freezing compared to the small ice crystals. The mechanical effect of the presence of ice crystals is responsible for the occurrence of a change in meat quality (Dalvi-Isfahan et al., 2019; Jiang et al., 2019; Kaale and Eikevik, 2013). Ice crystals can deform muscle fibers and thus contribute to a change in the cell area and distribution, as well as the structural organization of the various fiber components. Altered osmotic pressure and contracted muscle fibers as a result of freezing are also induced by the extracellular ice crystals (Shi et al., 2020). The damages and deformities in the muscles can be determined using morphological methods (Latorre et al., 2015).

Muscles of healthy alive fish are reckoned to be sterile (Stratev et al., 2015), but when processed after the fishing, meat quality may deteriorate considerably under the effect of various microorganisms. The most frequent paths for the invasion of microorganisms are related to the fishing method and the subsequent processing as well as fish storage. The human factor has a key role for fish contamination with bacteria during processing (Chakma et al., 2020).

Although there is a study on the histological and microbiological changes in rainbow trout after freezing (Popelka et al., 2014), there is no information about the morphometric changes occurring in this type of fish after freezing once and twice. Hence, the objective of this study was to establish in-depth the histological as well as microbiological changes in dorsal and abdominal muscles of rainbow trout (*Oncorhynchus mykiss*) after freezing once and twice.

Materials and methods

The samples

Forty-five fresh rainbow trout (*O. mykiss*) fish of an average weight of 400 g were purchased from the stores and transported in cooler bags to the laboratory for analysis. The fish were divided into three groups of 15 fish. The first group were analyzed immediately upon arrival at the laboratory. The second group was frozen at -18 °C for 15 days; while the third group was frozen at -18 °C for 15 days, thawed at 4 °C for 24 h and re-frozen at -18 °C for 15 days. Dorsal and abdominal muscles were taken from all fish in three groups for histological analysis, and dorsal muscles were taken to determine total microbial count and Enterobacteriaceae count.

Histological analysis

After skinning, a sample of 1×1×0.5 cm³ from the dorsal and abdominal muscles was taken from each fish. Histological analysis was performed on 24 samples of fresh fish, 24 samples of once frozen fish and 24 samples of twice frozen fish.

The material was fixed immediately in 10% buffered formalin (pH 7.4) and Carnoy's fixative as anhydrous fixative containing 60 parts absolute alcohol, 30 parts chloroform, and 10 parts glacial acetic acid. The material from samples fixed in 10% buffered formalin (pH 7.4) was washed under running water, dehydrated in ascending alcohol series (50, 70, 80, 90, 96, and 100%), clarified twice in xylol, and embedded in paraffin. The material from samples fixed in a Carnoy's fixative was washed and dehydrated in 100% alcohol, clarified twice in xylol, and embedded in paraffin. Then, 6 µm thick sections were obtained on a rotary microtome (YD-335A, China) and they were stained by the hematoxylin/eosin (H&E) and Van-Gieson methods. The histological assessment was performed on a microscope N-200 M (Hangzhou Sumer Instrument Co., Ltd, China). Photo documenting was performed using an OptikaMB5 Digital Camera (OPTIKA Microscopes, Italy) and PROVIEW software (Optika Srl, Ponteranica, Italy).

Morphometric analysis

The muscle fiber diameter, the perimysium internum width and empty spaces among muscle fibers of fresh, frozen once and frozen twice trouts were measured by means of microscope N-200M (Hangzhou Sumer Instrument Co., Ltd, China) and an ocular micrometer.

Total microbial count

Ten g of tissue with skin were taken aseptically and weighed in a stomacher homogenizer bag. A 90 ml of Maximum Recovery Diluent sample diluent (Merck, Germany) was added, after which the samples were homogenized for 1 min. Ten-fold dilutions were made in 9 ml tubes with the sample diluent Maximum Recovery Diluent (HiMedia, India) and 0.1 ml of each dilution inoculated on two petri dishes containing Plate Count Agar (HiMedia, India). The inoculated petri dishes were incubated at 30 °C for 72 h. The colony count was determined by a colony counter, and the results are presented as log Colony Forming Unit (CFU)/g (Stratev et al., 2015).

Determining Enterobacteriaceae count

Ten-fold dilutions were made in 9 ml tubes with the sample diluent Maximum Recovery Diluent (HiMedia, India). From each dilution, 1 ml was transferred into two sterile empty dishes and poured with molten and cooled Violet Red Bile Glucose agar (HiMedia, India). After solidification of the agar, the plates were incubated at 37 °C for 24 h. From petri dishes with 15 to 300 colonies (pink to violet 0.5 mm in size), 5 colonies were taken, inoculated on Caso agar (HiMedia, India), and incubated at 37 °C for 24 h. The colonies were confirmed as Enterobacteriaceae by oxidase test and glucose fermentation using Oxidation/Fermentation Medium (O/F; HiMedia, India).

The Enterobacteriaceae count was determined by the following equation:

$$x = \frac{A}{B} \times C$$

whereas A is the number of confirmed colonies (oxidase-negative and glucose-fermentation), B is the number of colonies tested, and C is the number of all presumptive Enterobacteriaceae colonies on the petri dish. The result was presented in CFU/g as an average value of the number of colonies on two petri dishes multiplied by the degree of dilution (Paulsen et al., 2008).

Statistical analysis

The results of the morphometric and microbiological analyses were statistically processed using the GraphPad InStat 3 software (GraphPad Software, San Diego, CA) and presented as mean values with standard deviation. One-way ANOVA and Tukey's post hoc test were performed to compare the significance of the differences between the individual experimental groups. Statistical significance was determined at $p < 0.05$.

Results

Histological assessment of dorsal muscles (fresh)

In the conducted survey of skeletal muscle tissue obtained from the dorsal area in fresh rainbow trout (*O. mykiss*), no structural changes were found in longitudinal and cross slices. The structural organization of the muscle component in fresh rainbow trout was well maintained as a whole. A thin layer of loose connective tissue known as endomysium surrounded each muscle fiber. Fibers from the dorsal area were attached to each other in bundles and had the typical polygonal shape. Skeletal muscle fibers were seen as groups of fibers separated from each other by a loose connective tissue (perimysium internum). Individual muscle fibers, bundles of muscle fibers, as well as the global spatial structure were clearly discernible. Oval and basophil tained nuclei were observed predominantly in the periphery, under the sarcolemma. It was established from the studied dorsal muscles of fresh rainbow trout that muscle fibers had preserved integrity and no significant difference ($p > 0.05$) concerning shape, size, and distribution (Figure 1: A, B; Figure 3: A).

Histological assessment of dorsal muscles (frozen once)

During the freezing once and thawing of the dorsal muscles from rainbow trout, changes in the structure of the muscle fibers were observed. Irregular and large void spaces occupied a significant part of the analyzed areas of the dorsal muscles. Most likely, they were related to the more pronounced shrinking of the fibers. Their damage was observed to a greater extent, with the presence of torn muscle fibers and vacuoles (intracellular). Muscle fibers with intracellular void spaces and retained intact peripheral boundary were established. Areas with enlarged cleft (empty) spaces were found throughout the entire muscle tissue. In some muscle fibers, the boundaries of the endomysium were visible and intact. In the one-time freezing cycle at -18 °C, released cellular content (interstitial protein material) was observed between the muscle fibers, the structure of which was of granular nature. The structure of dorsal muscles was deformed due to the presence of extracellular large ice crystals (Figure 1: C, D; Figure 3: B).

Histological assessment of dorsal muscles (frozen twice)

The muscle fibers of the dorsal muscles of rainbow trout (*O. mykiss*) frozen twice and thawed at -18 °C had a significantly reduced quantitative distribution. The irregular void space was greatly increased. The areas with such spaces occupied large parts of the studied areas. A solid amount of extracellular ice macro crystals and

combined muscle fibers were found due to endomysium rupture. Interstitial protein material was also observed in the space between the muscle fibers. The tissue looked badly damaged. It was difficult to determine the contours of muscle fibers and bundles due to the rupture of endomysium and perimysium internum. Lesions were much stronger compared to freezing once and thawing under the same conditions. Muscle fibers had a completely destroyed structure and interfibrillar void spaces were wider. Highly fragmented and deformed fibers were observed. After freezing twice and thawing at $-18\text{ }^{\circ}\text{C}$, large-scale muscle degradation was noted. Skeletal muscle tissue was irreversibly damaged to the greatest extent (Figure 1: E, F; Figure 3: C).

Histological assessment of abdominal muscles (fresh)

When applying the histological method for examination of the abdominal muscles in fresh rainbow trout (*O. mykiss*), no structural changes were found in the muscle fibers. The polygonal appearance typical of fibers was noted in cross slice. The structure of abdominal muscles of fresh rainbow trout included two parts. One corresponded to the skeletal muscle tissue formed by skeletal muscle fibers. The other corresponded to the void spaces used to denote the sites taken by extracellular fluid. The compact muscle tissue was in the largest volume, and the rest (void space) was defined as normally wider for this anatomical area and with smooth edges. When describing the histostructure of the skeletal muscle fibers, the outlines and location of muscle fibers were confirmed, as well as the basophilic nuclei (peripherally positioned in oval cross slices; rod-shaped in longitudinal slices). Muscle bundles created by the grouping of muscle fibers were separated by loose connective tissue (perimysium internum). Endomysium (loose connective tissue) enveloping each muscle fiber was also preserved. No changes in the structure of the perimysium internum and endomysium of the skeletal muscle bundles and fibers were observed (Figure 2: A, B; Figure 3: D).

Histological assessment of abdominal muscles (frozen once)

In a microstructural analysis performed on abdominal muscles frozen once and thawed, it was found that the skeletal muscle tissue spread in two parts (muscle fibers and void spaces). When analyzing this distribution, it was confirmed that irregular void space was far greater in amount. Modifications such as shrunken and dehydrated muscle fibers have been reported. Areas with incorporated fragmented central portion in fibers were noted, but nevertheless muscle fibers retained their original shape as their outer portion was intact. Enlarged cleft-like (void) spaces were found in large quantities. Fields of vision

with blurred ends of muscle fibers were also evident. Fully destructured fibers also turned out to be a find. The loose connective tissue forming the endomysium of fibers was not affected. The structure of skeletal muscle tissue was damaged due to sublimation of macrocrystals. Their situation was determined as extracellular. Damaged fibers were a consequence of the pressure generated by the formation of ice crystals. Excessive void spaces were seen between the bundles of muscle fibers. In the cycle of freezing once at $-18\text{ }^{\circ}\text{C}$, both basophilic, granular protein material and presence of non-homogeneously distributed vacuoles were recognized (Figure 2: C, D; Figure 3: E).

Histological assessment of abdominal muscles (frozen twice)

The studied material of abdominal muscles from rainbow trout (*O. mykiss*) frozen twice and thawed at $-18\text{ }^{\circ}\text{C}$ was also systematized in two parts. The decrease in the amount of skeletal muscle tissue was at the expense of an even more noticeable increase in irregular empty space. Skeletal muscle tissue organization was categorized as dehydrated and degenerated. Due to the presence of many and bulky extracellular ice macrocrystals, the tissue was permanently deformed, which led to the fusion of muscle fibers. No clear contours of muscle fibers and bundles were observed. Ice crystals had caused massive structural damage. The distribution of defects was ubiquitous throughout the tissue. Microscopically visible changes were pronounced. Muscle fibers were torn; interfibrillar void spaces occupied a large volume. More severe structural damage to muscle fibers associated with more extensive muscle degradation was found. The skeletal muscle tissue was severely affected and irreversibly damaged to the greatest extent. Large void spaces between muscle fibers and bundles were encountered due to shrinking and grouping of the fibers, as well as due to rupture of the endomysium and perimysium internum. A large amount of interstitial protein material was observed in the space between the fibers (Figure 2: E, F; Figure 3: F).

Morphometric analysis

The results from morphometric analysis of dorsal and abdominal muscles are presented in Table 1. Statistically significant differences were established between the dimensions of muscle fibers and empty spaces in the dorsal and abdominal muscles of fresh trout and trout frozen once, whereas perimysium internum showed differences in fresh trout only. After freezing twice, no significant differences ($p>0.05$) were found between the dimensions of muscle fibers, empty spaces, and perimysium internum of dorsal and abdominal muscles.

Table 2 presents the morphometric changes of dorsal and abdominal muscles after freezing once and twice. The dimensions of muscle fibers, empty spaces, and perimysium internum revealed statistically significant differences ($p < 0.001$) after freezing once and twice.

Total microbial and Enterobacteriaceae count

The microbiological indicators were not affected considerably after freezing. The total microbial count had no significant differences ($p > 0.05$) between fresh (4.53 log CFU/g), frozen once (4.58 log CFU/g) and frozen twice (4.69 log CFU/g) rainbow trout. Enterobacteriaceae count had no significant differences either ($p > 0.05$) between fresh (1.51 log CFU/g), frozen once (1.37 log CFU/g) and frozen twice (1.11 log CFU/g) rainbow trout.

Discussion

Fraudulent practices in fish trade are mainly related to the replacement of fish offered for sale. In commercial aspect, there are cases in which frozen and thawed fish is offered as fresh (Ottavian et al., 2013). Fraudulent practices aim greater profits, since the market price of frozen and thawed fish is much lower than that of fresh fish (Popelka et al., 2014). Fish is a perishable raw material, which makes its freshness a key factor in the supply of fish in the stores (Chakma et al., 2020).

Popelka et al. (2014) proved histological and microbiological changes in rainbow trout after freezing. In contrast to that study, we established the changes in muscle fiber diameter, the perimysium internum width and empty spaces among muscle fibers of rainbow trout after freezing once and twice. In the present study, unfrozen trout showed muscle fibers with preserved integrity, which were evenly distributed. This study is in accordance with findings of Shi et al. (2020) who stated that intact and compact muscle fibers are found in unfrozen channel catfish muscles. With the dehydrated and shrunken muscle fibers found and the increasing size of void spaces after freezing, we confirm the opinion of Shi et al. (2020) that after freezing, muscle cells shrink and change their shape, extracellular space increases, and intracellular vacuoles appear, resulting in fiber breakdown. According to Bahuaud et al. (2008), the position of ice crystals is influenced by the freezing method and its velocity. It is a known fact that ice crystals can appear both in intracellular and extracellular spaces. Intracellular crystals are located within fiber boundaries, while extracellular ice crystals affect endomysium. In our study on rainbow trout frozen by convection freezers at a slow rate, the presence of large extracellular crystals affecting the endomysium of muscle cells was found. Based on the results of the present study, it can be assumed that the

cause of muscle fiber destruction is the mechanical impact of extracellular ice crystals.

Tinacci et al. (2018, 2020) indicated histological parameters to distinguish fresh from frozen fish and octopus meat, which aim to assess the overall organization of muscle tissue, the presence or absence of void spaces in the areas, and the presence of protein material in the intercellular space. Our study showed characteristics for histological evaluation by Tinacci et al. (2018). Kaale and Eikevik (2013) believe that the ice mass formed is responsible for the damaged muscle fibers. Popelka et al. (2014) found that significant myofibre damage was observed in rainbow trout that had undergone freezing twice. Our results are similar to those of Popelka et al. (2014), who also point out that freezing twice damages fibers to a high degree and leads to irreversible consequences. Bahuaud et al. (2008) revealed that dehydration of muscle fibers results from the action of ice crystals on them. This leads to a change in the tissue concentration of salts as it increases and concentrates. The described consequences of the occurrence of dehydration are mainly related to membrane damage and denaturation of proteins. Lu et al. (2020) also support the view that muscle damage during slow freezing is significant and the effects are irreversible due to the destructive effect of large and extracellular ice masses.

The results from our study do not correspond to the findings by Díaz-Tenorio et al. (2007), who did not find any structural changes in the connective tissue in white leg shrimp (*Litopenaeus vannamei*) frozen by cryogenic and forced convection and thawed at 4 °C and 25 °C. We established affected connective tissue in rainbow trout muscles after freezing. Possible reasons for the difference in results are the different freezing methods as well as the different time of storage in frozen state. Jasra et al. (2001) also proved changes in the muscle structure of carp (*Labeo rohita*) stored at -8 °C and -20 °C for up to 6 months. The histochemical, biochemical, and electrophoretic methods reveal degenerative changes in myosin and α -actinin, whereas other high molecule protein structures fragment to low molecule proteins. In frozen (-20 °C for 24 h) and thawed (4 °C for 12-16 h) sea bass (*Dicentrarchus labrax*), Ayala et al. (2005) found spaces filled with liquid in the interstitial spaces and inside the muscle fibers. The arrangement of contractible filaments is compromised and the majority of sarcolemmas are broken and the interfibrillar spaces are significantly enlarged. Makri (2009) stored vacuum packaged gilthead sea bream (*Sparus aurata*) fillets at -22 °C for up to 340 days and observed compromised muscle structure and denaturation of muscle proteins. Pavlov et al. (2008) studied the histological changes in carp (*Cyprinus carpio*) after freezing at -18 °C for 14 days. The structural changes found consisted of destruction of the central part of the

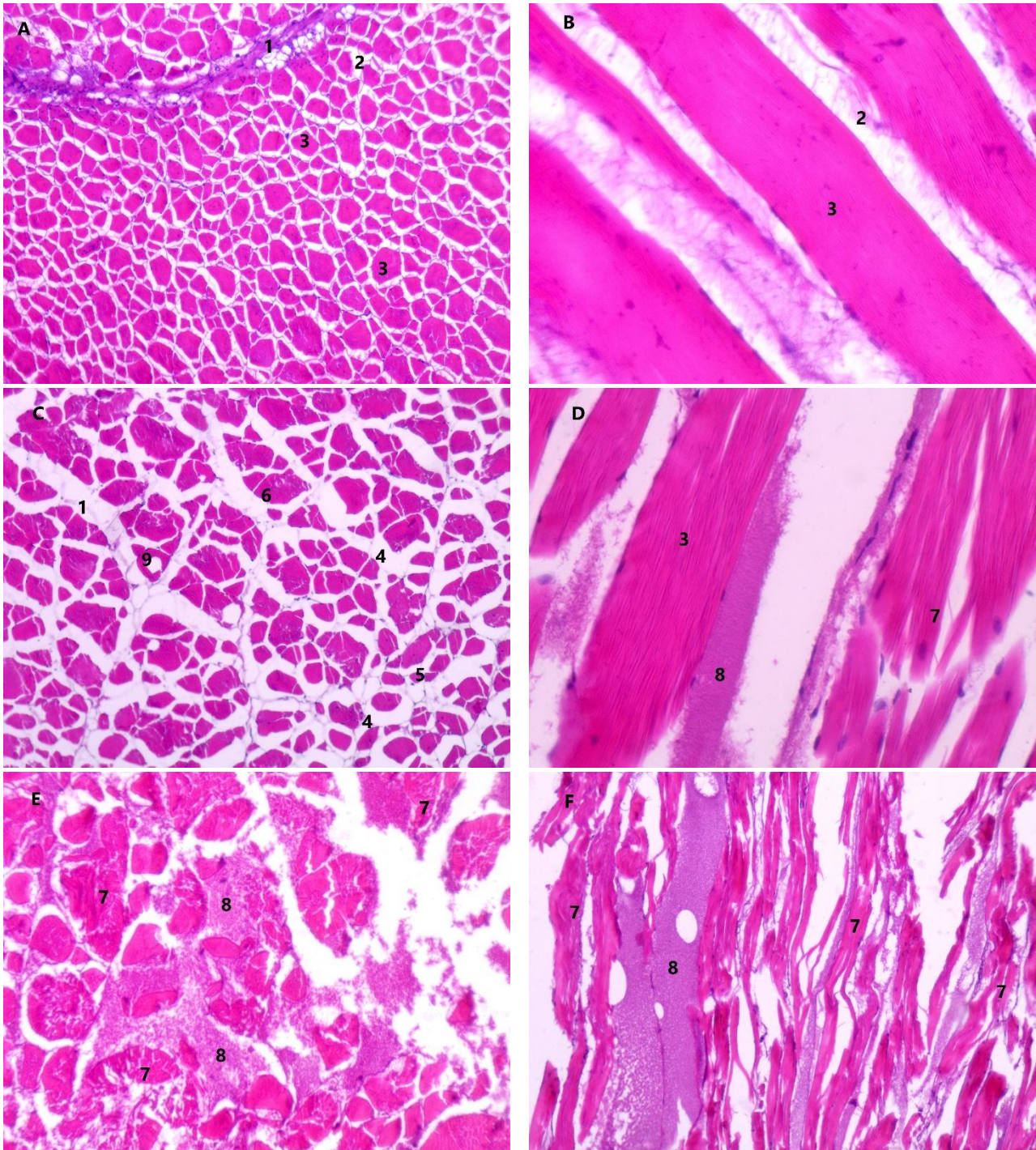


Figure 1: Cross and longitudinal slices of dorsal muscles of rainbow trout (*Oncorhynchus mykiss*) (H&E): A: cross slice of skeletal muscle fibers of fresh rainbow trout (10x, scale bar=100 μ m); B: longitudinal slice of skeletal muscle fibers of fresh rainbow trout (40x, scale bar=25 μ m); C: cross slice of skeletal muscle fibers of rainbow trout frozen once at -18 $^{\circ}$ C (10x, scale bar=100 μ m); D: longitudinal slice of skeletal muscle fibers of rainbow trout frozen once at -18 $^{\circ}$ C (40x, scale bar=25 μ m); E: cross slice of skeletal muscle fibers of rainbow trout frozen twice at -18 $^{\circ}$ C (20x, scale bar=50 μ m); F: longitudinal slice of skeletal muscle fibers of rainbow trout frozen twice at -18 $^{\circ}$ C (10x, scale bar=100 μ m).

Key: 1: perimysium internum; 2: endomysium; 3: skeletal muscle fibers with normal histostructure; 4: enlarged cleft spaces; 5: shrunken skeletal muscle fibers; 6: skeletal muscle fibers with broken central and retained peripheral part; 7: completely destructed skeletal muscle fibers; 8: interstitial protein material; 9: vacuoles

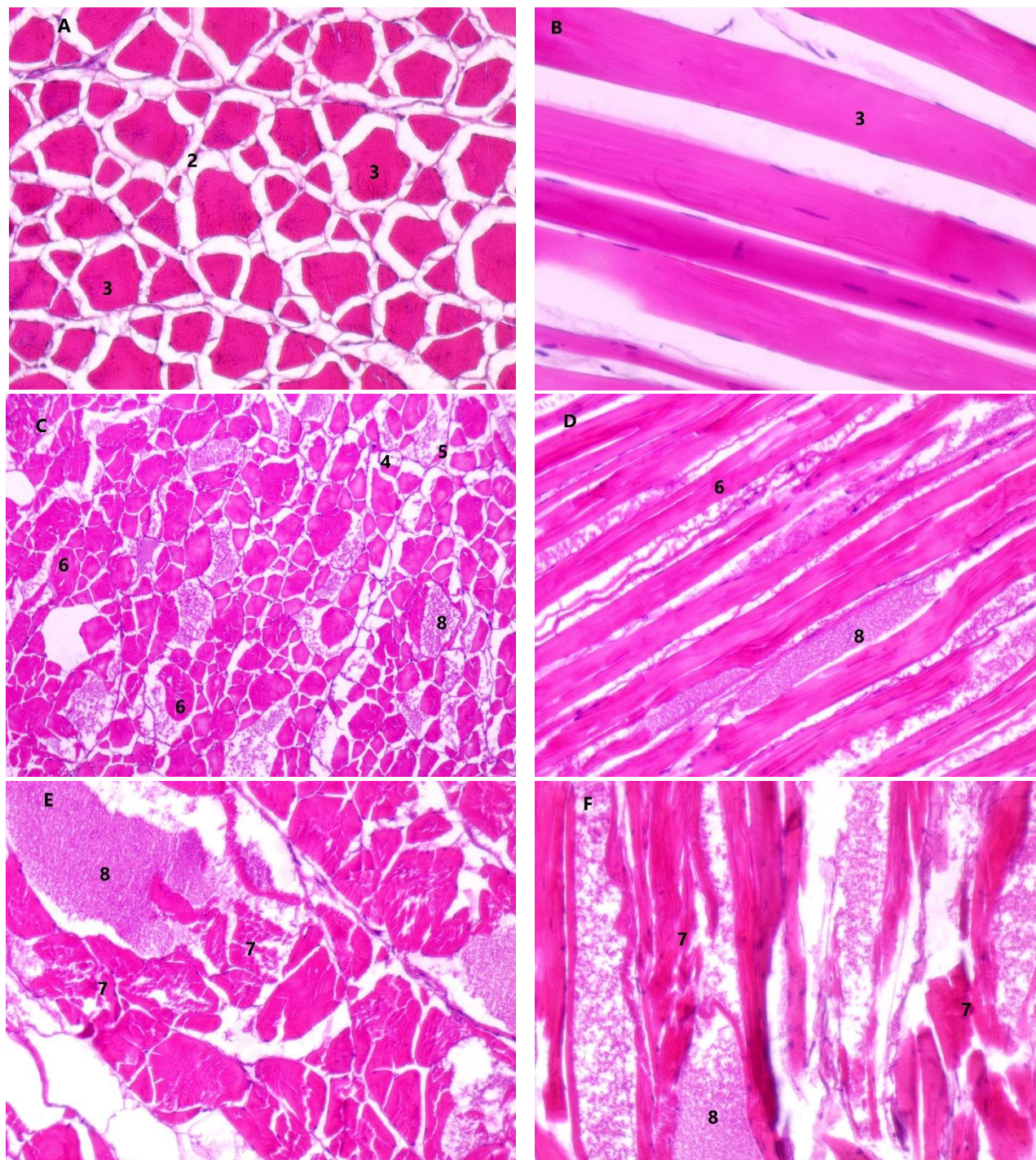


Figure 2: Cross and longitudinal slices of abdominal muscles of rainbow trout (*Oncorhynchus mykiss*) (H&E): A: cross slice of skeletal muscle fibers of fresh rainbow trout (20x, scale bar=50 μ m); B: longitudinal slice of skeletal muscle fibers of fresh rainbow trout (20x, scale bar=50 μ m); C: cross slice of skeletal muscle fibers of rainbow trout frozen once at -18 $^{\circ}$ C (10x, scale bar=100 μ m); D: longitudinal slice of skeletal muscle fibers of rainbow trout frozen once at -18 $^{\circ}$ C (20x, scale bar=50 μ m); E: cross slice of skeletal muscle fibers of rainbow trout frozen twice at -18 $^{\circ}$ C (20x, scale bar=50 μ m); F: longitudinal slice of skeletal muscle fibers of rainbow trout frozen twice at -18 $^{\circ}$ C (20x, scale bar=50 μ m).
 Key: 1: perimysium internum; 2: endomysium; 3: skeletal muscle fibers with normal histostructure; 4: enlarged cleft spaces; 5: shrunken skeletal muscle fibers; 6: skeletal muscle fibers with broken central and retained peripheral part; 7: completely destructed skeletal muscle fibers; 8: interstitial protein material; 9: vacuoles

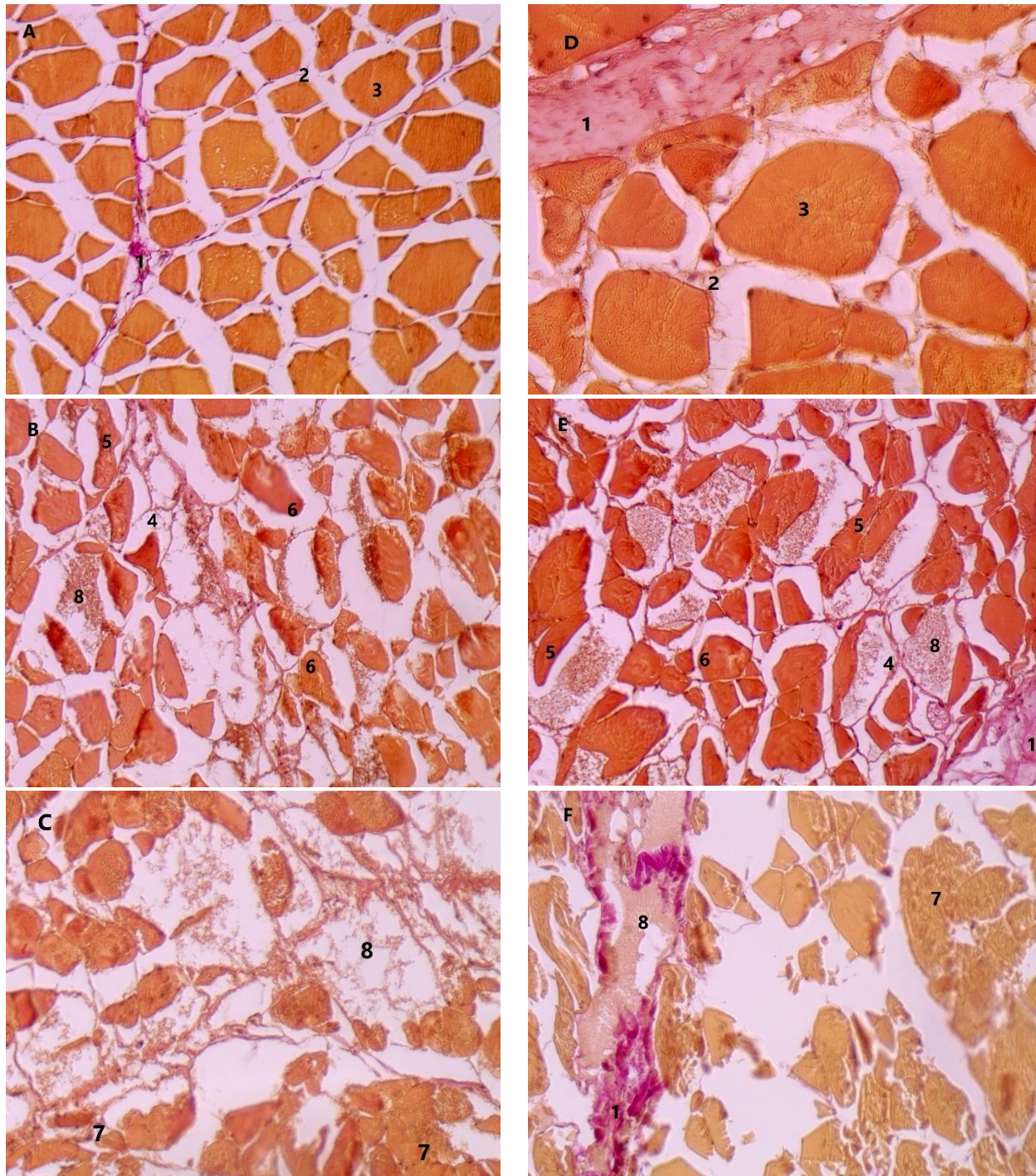


Figure 3: Cross slices of dorsal and abdominal muscles of rainbow trout (*Oncorhynchus mykiss*) stained by Van-Gieson method: A: cross slice of skeletal muscle fibers from dorsal muscles of fresh rainbow trout (20x, scale bar=50 μ m); B: cross slice of skeletal muscle fibers from dorsal muscles of rainbow trout frozen once at -18° C (20x, scale bar=50 μ m); C: cross slice of skeletal muscle fibers from dorsal muscles of rainbow trout frozen twice at -18° C (20x, scale bar=50 μ m); D: cross slice of skeletal muscle fibers from abdominal muscles of fresh rainbow trout (40x, scale bar=25 μ m); E: cross slice of skeletal muscle fibers from abdominal muscles of rainbow trout frozen once at -18° C (20x, scale bar=50 μ m); F: cross slice of skeletal muscle fibers from abdominal muscles of rainbow trout frozen twice at -18° C (20x, scale bar=50 μ m).

Key: 1: perimysium internum; 2: endomysium; 3: skeletal muscle fibers with normal histostructure; 4: enlarged cleft spaces; 5: shrunken skeletal muscle fibers; 6: skeletal muscle fibers with broken central and retained peripheral part; 7: completely destructed skeletal muscle fibers; 8: interstitial protein material; 9: vacuoles

Table 1: Comparison of the morphometric indicators of dorsal and abdominal muscles of rainbow trout (*Oncorhynchus mykiss*)

Indicator	State of fish	Dorsal muscles (μm)	Abdominal muscles (μm)	Significance (p)
Muscle fibres	fresh	80.08 \pm 18.98	87.36 \pm 16.63	*
	frozen once	51.80 \pm 12.41	60.20 \pm 15.56	**
	frozen twice	39.48 \pm 10.08	40.04 \pm 11.67	NS
Empty spaces	fresh	29.68 \pm 8.78	38.36 \pm 9.30	***
	frozen once	96.60 \pm 26.27	111.44 \pm 33.82	*
	frozen twice	225.12 \pm 126.11	197.64 \pm 85.75	NS
Perimysium internum	fresh	43.96 \pm 15.23	65.54 \pm 24.87	***
	frozen once	136.92 \pm 63.20	148.68 \pm 63.05	NS
	frozen twice	250.88 \pm 119.86	229.32 \pm 70.48	NS

NSD :Non-Significant Difference ($p>0.05$); * $p<0.05$; ** $p<0.01$; *** $p<0.001$ **Table 2:** Comparison of the morphometric indicators of dorsal and abdominal muscles in different states of rainbow trout (*Oncorhynchus mykiss*)

Indicator	Muscles	Fresh trout (μm)	Trout frozen once (μm)	Trout frozen twice (μm)	Significance (p)
Muscle fibres	Dorsal muscles	80.08 \pm 18.98 ^a	51.80 \pm 12.41 ^b	39.48 \pm 10.08 ^c	***
	Abdominal muscles	87.36 \pm 16.63 ^a	60.20 \pm 15.56 ^b	40.04 \pm 11.67 ^c	***
Empty spaces	Dorsal muscles	29.68 \pm 8.78 ^a	96.60 \pm 26.27 ^b	225.12 \pm 126.11 ^c	***
	Abdominal muscles	38.36 \pm 9.30 ^a	111.44 \pm 33.82 ^b	197.64 \pm 85.75 ^c	***
Perimysium internum	Dorsal muscles	43.96 \pm 15.23 ^a	136.92 \pm 63.20 ^b	250.88 \pm 119.86 ^c	***
	Abdominal muscles	65.54 \pm 24.87 ^a	148.68 \pm 63.05 ^b	229.32 \pm 70.48 ^c	***

*** $p<0.001$; values with different indications show significant differences ($p<0.05$)

muscle cells with retained peripheral part. The sarcoplasm of these cells is not in the fibrillar structure. Similar to Pavlov et al. (2008), we observed changes in the muscle fibers related to certain parts of their structure. The fibers were in a non-affected peripheral border and destructive changes in their central part. More of these fibers were found after freezing rainbow trout once. The results from our study convincingly showed differences in the structure of muscle fibers and intercellular space between fresh and frozen rainbow trout. In support of that, Sigurgisladdottir et al. (2000) found shrunken shape of muscle fibers in Atlantic salmon (*Salmo salar*) after freezing at -20 °C for 1 month. The established enlarged void spaces after freezing in our study corresponds to the findings by Sigurgisladdottir et al. (2000), who proved enlarged intercellular space in Atlantic salmon (*Salmo salar*) after freezing.

Microorganisms are one of the main factors responsible for the poor quality and spoilage of fish (Chakma et al., 2020). Freezing and frozen storage can affect the microbial population by reducing it by inhibiting their growth (Venugopal, 2005). This is possible because microorganisms need water, but when frozen it turns into an ice mass (Kolbe and Kramer, 2007). The results for the total number of microorganisms and

Enterobacteriaceae in frozen and thawed foods vary in different ranges. Their quantity depends on certain factors such as water quality, method and conditions of freezing and thawing, and fish processing (Angane et al., 2020; Chakma et al., 2020). The results of the microbiological analysis in the current work are opposite to those of Popelka et al. (2014) who found that both total microbial and Enterobacteriaceae counts are highest in trout frozen twice. In the present study, the microorganism count is below the maximum permissible value of 7 log CFU/g proposed by the International Commission on Microbiological Specification for Foods (ICMSF, 1986). Liu et al. (2014) found that by increasing storage time for common carp (*C. carpio*) at -18 °C, microbial count increases from 4.4 log CFU/g on day 1 to 5.5 log CFU/g on day 35. Our study also proved an increase in the total microbial count in trout stored at -18 °C for 30 days, although results revealed no significant differences. However, in trout stored at temperature lower than -18 °C a reduction of the total microbial count is noticed. Taşkaya et al. (2003) froze fillets from rainbow trout (*Oncorhynchus mykiss*) at -35 °C and stored them at -24 °C for 3 months. The total microbial count in fresh fish is 7.48 log CFU/g, while in frozen and thawed fish it reduces to 5.58 log CFU/g.

Conclusion

The histological assessment of the muscles of rainbow trout (*Oncorhynchus mykiss*) after freezing once for 15 days and twice for a total of 30 days found broken structure of muscle fibers and the tissue organization. Muscles are histologically damaged to a greater extent after freezing twice and thawing. However, microbiological indicators do not change significantly after freezing once and twice for the relevant periods.

Author contributions

All authors contributed equally to study designing, experimental work, data analysis, and also manuscript writing. All authors read and approved the final manuscript.

Conflicts of interest

There is no conflict of interest to declare.

Acknowledgements

This study was funded by Faculty of Veterinary Medicine, Trakia University, Bulgaria (Grant number 3/19).

References

- Akter N., Linkon K.M.R., Rahman M., Hossain S. (2020). A comparative study on the determination of biochemical changes of different species of fish during frozen storage. *Letters in Applied NanoBioScience*. 9: 1444-1450. [DOI: 10.33263/LIANBS93.14441450]
- Angane M., Gupta S., Fletcher G.C., Summers G., Hedderley D.I., Quek S.Y. (2020). Effect of air blast freezing and frozen storage on *Escherichia coli* survival, n-3 polyunsaturated fatty acid concentration and microstructure of Greenshell™ mussels. *Food Control*. 115: 107284. [DOI: 10.1016/j.foodcont.2020.107284]
- Ayala M.D., Albors O.L., Blanco A., Alcázar A.G., Abellán E., Zarzosa G.R., Gil F. (2005). Structural and ultrastructural changes on muscle tissue of sea bass, *Dicentrarchus labrax* L., after cooking and freezing. *Aquaculture*. 250: 215-231. [DOI: 10.1016/j.aquaculture.2005.04.057]
- Bahuaud D., Mørkøre T., Langsrud Ø., Sinnes K., Veiseth E., Ofstad R., Thomassen M.S. (2008). Effects of -1.5 °C superchilling on quality of Atlantic salmon (*Salmo salar*) pre-rigor fillets: cathepsin activity, muscle histology, texture and liquid leakage. *Food Chemistry*. 111: 329-339. [DOI: 10.1016/j.foodchem.2008.03.075]
- Chakma S., Saha S., Hossain N., Rahman A., Akter M., Hoque S., Ullah R., Mali S.K., Al Shahriar. (2020). Effect of frozen storage on the biochemical, microbial and sensory attributes of Skipjack Tuna (*Katsuwonus pelamis*) fish loins. *Journal of Applied Biology and Biotechnology*. 8: 58-64. [DOI: 10.7324/JABB.2020.80409]
- Dalvi-Isfahan M., Jha P.K., Tavakoli J., Daraei-Garmakhany A., Xanthakis E., Le-Bail A. (2019). Review on identification, underlying mechanisms and evaluation of freezing damage. *Journal of Food Engineering*. 255: 50-60. [DOI: 10.1016/j.jfoodeng.2019.03.011]
- Díaz-Tenorio L.M., García-Carreño F.L., Pacheco-Aguilar R. (2007). Comparison of freezing and thawing treatments on muscle properties of whiteleg shrimp (*Litopenaeus vannamei*). *Journal of Food Biochemistry*. 31: 563-576. [DOI: 10.1111/j.1745-4514.2007.00130.x]
- Hafezparast-Moadab N., Hamdami N., Dalvi-Isfahan M., Farahnaky A. (2018). Effects of radiofrequency-assisted freezing on microstructure and quality of rainbow trout (*Oncorhynchus mykiss*) fillet. *Innovative Food Science and Emerging Technologies*. 47: 81-87. [DOI: 10.1016/j.ifset.2017.12.012]
- ICMSF (International Commission on Microbiological Specification for Foods). (1986). Microorganisms in foods. 2. Sampling for microbiological analysis: principles and specific applications. 2nd edition. Buffalo, NY: University of Toronto Press.
- Jasra S.K., Jasra P.K., Talesara C.L. (2001). Myofibrillar protein degradation of carp (*Labeo rohita* (Hamilton)) muscle after post-mortem unfrozen and frozen storage. *Journal of the Science of Food and Agriculture*. 81: 519-524. [DOI: 10.1002/jsfa.841]
- Jiang Q., Nakazawa N., Hu Y., Osako K., Okazaki E. (2019). Changes in quality properties and tissue histology of lightly salted tuna meat subjected to multiple freeze-thaw cycles. *Food Chemistry*. 293: 178-186. [DOI: 10.1016/j.foodchem.2019.04.091]
- Kaale L.D., Eikevik T.M. (2013). A histological study of the microstructure sizes of the red and white muscles of Atlantic salmon (*Salmo salar*) fillets during superchilling process and storage. *Journal of Food Engineering*. 114: 242-248. [DOI: 10.1016/j.jfoodeng.2012.08.003]
- Kolbe E., Kramer D. (2007). Planning for seafood freezing. Fairbanks, Alaska: Alaska Sea Grant College Program, University of Alaska Fairbanks.
- Latorre R., Sadeghinezhad J., Hajimohammadi B., Izadi F., Sheibani M.T. (2015). Application of morphological method for detection of unauthorized tissues in processed meat products. *Journal of Food Quality and Hazards Control*. 2: 71-74.
- Liu Q., Kong B., Han J., Chen Q., He X. (2014). Effects of superchilling and cryoprotectants on the quality of common carp (*Cyprinus carpio*) surimi: microbial growth, oxidation, and physicochemical properties. *LWT-Food Science and Technology*. 57: 165-171. [DOI: 10.1016/j.lwt.2014.01.008]
- Lu X., Zhang Y., Xu B., Zhu L., Luo X. (2020). Protein degradation and structure changes of beef muscle during superchilled storage. *Meat Science*. 168: 108180. [DOI: 10.1016/j.meatsci.2020.108180]
- Luan L., Wang L., Wu T., Chen S., Ding T., Hu Y. (2018). A study of ice crystal development in hairtail samples during different freezing processes by cryosectioning versus cryosubstitution method. *International Journal of Refrigeration*. 87: 39-46. [DOI: 10.1016/j.ijrefrig.2017.10.014]
- Makri M. (2009). Biochemical and textural properties of frozen stored (-22 °C) gilthead seabream (*Sparus aurata*) fillets. *African Journal of Biotechnology*. 8: 1287-1299.
- Okuda K., Kawauchi A., Yomogida K. (2020). Quality improvements to mackerel (*Scomber japonicus*) muscle tissue frozen using a rapid freezer with the weak oscillating magnetic fields. *Cryobiology*. 95: 130-137. [DOI: 10.1016/j.cryobiol.2020.05.005]
- Ottavian M., Fasolato L., Facco P., Barolo M. (2013). Foodstuff authentication from spectral data: toward a species-independent discrimination between fresh and frozen-thawed fish samples. *Journal of Food Engineering*. 119: 765-775. [DOI: 10.1016/j.jfoodeng.2013.07.005]
- Paulsen P., Borgetti C., Schopf E., Smulders F.J.M. (2008). Enumeration of Enterobacteriaceae in various foods with a new automated most-probable-number method compared with petrifilm and international organization for standardization procedures. *Journal of Food Protection*. 71: 376-379. [DOI: 10.4315/0362-028X-71.2.376]

- Pavlov A., Dimitrov D., Penchev G., Georgiev L. (2008). Structural changes in common carp (*Cyprinus carpio* L.) fish meat during freezing. *Bulgarian Journal of Veterinary Medicine*. 11: 131-136.
- Popelka P., Nagy J., Pipová M., Marcinčák S., Lenhardt E. (2014). Comparison of chemical, microbiological and histological changes in fresh, frozen and double frozen rainbow trout (*Oncorhynchus mykiss*). *Acta Veterinaria Brno*. 83: 157-161. [DOI: 10.2754/avb201483020157]
- Shi L., Yin T., Xiong G., Ding A., Li X., Wu W., Qiao Y., Liao L., Wang J., Wang L. (2020). Microstructure and physico-chemical properties: effect of pre-chilling and storage time on the quality of Channel catfish during frozen storage. *LWT*. 130: 109606. [DOI: 10.1016/j.lwt.2020.109606]
- Sigurgísladóttir S., Ingvarsdóttir H., Torrissen O.J., Cardinal M., Hafsteinsson H. (2000). Effects of freezing/thawing on the microstructure and the texture of smoked Atlantic salmon (*Salmo salar*). *Food Research International*. 33: 857-865. [DOI: 10.1016/S0963-9969(00)00105-8]
- Stratev D., Vashin I., Daskalov H. (2015). Microbiological status of fish products on retail markets in the Republic of Bulgaria. *International Food Research Journal*. 22: 64-69.
- Taşkaya L., Çaklı S., Kışla D., Kılınç B. (2003). Quality changes of fish burger from rainbow trout during refrigerated storage. *Journal of Fisheries and Aquatic Sciences*. 20: 147-154.
- Tinacci L., Armani A., Guidi A., Nucera D., Shvartzman D., Miragliotta V., Coli A., Giannesi E., Stornelli M.R., Fronte B., Di Iacovo F., Abramo F. (2018). Histological discrimination of fresh and frozen/thawed fish meat: European hake (*Merluccius merluccius*) as a possible model for white meat fish species. *Food Control*. 92: 154-161. [DOI: 10.1016/j.foodcont.2018.04.056]
- Tinacci L., Armani A., Scardino G., Guidi A., Nucera D., Miragliotta V., Abramo F. (2020). Selection of histological parameters for the development of an analytical method for discriminating fresh and frozen/thawed common octopus (*Octopus vulgaris*) and preventing frauds along the seafood chain. *Food Analytical Methods*. 13: 2111-2127. [DOI: 10.1007/s12161-020-01825-0]
- Venugopal V. (2005). Seafood processing: adding value through quick freezing, retortable packaging, and cook-chilling. CRC press, Taylor & Francis Group.