

CD-1a immunoexpression in oral lichen planus and oral lichenoid reaction

Azadeh Majidian¹, Maryam Seyedmajidi², Hamid Abbaszadeh^{3✉}, Majid Sharbatdaran⁴,
Sina Jafari⁵, Hemmat Gholinia⁶

1.Dental Student, Student Research Committee, Babol University of Medical Sciences, Babol,IR Iran.**ORCID** (0000-0001-7096-2297)

2.Professor, Dental Materials Research Center, Health Research Institute, Babol University of Medical Sciences, Babol, IR Iran.

3.Associate Professor, Department of Oral and Maxillofacial Pathology, Faculty of Dentistry, Birjand University of Medical Sciences, Birjand, IR Iran .

4.Assistant Professor, Cellular and Molecular Biology Research Center, Health Research Institute, Babol University of Medical Sciences, Babol, IR Iran .

5.Postgraduate Student, Department of Prosthodontics, Faculty of Dentistry, Shahed University Tehran,Tehran, IR Iran.

6.Msc in Statistics, Health Research Institute, Babol University of Medical Sciences, Babol, IR Iran.

✉**Corresponding Author:** Hamid Abbaszadeh, Faculty of Dentistry, Birjand University of Medical Sciences, Birjand, IR Iran.

Email: hamidabbaszade@yahoo.com

Tel: +985632381703

ORCID (0000-0002-7443-0607)

Received: 20 Oct 2019

Accepted: 29 Jul 2020

Abstract

Introduction: Oral lichen planus (OLP) is an immunologically mediated mucocutaneous diseases. Langerhans cells (LCs) are antigen presenting cells resident within oral mucosa which, together with intraepithelial lymphocytes, play a role in mucosal defense. The aim of present study was to determine the immunohistochemical expression of LC in Oral Lichenoid reaction (OLR) and OLP compared with normal oral mucosa (NOM).

Materials & Methods: In this cross-sectional study, 61 oral mucosal specimens diagnosed histopathologically as OLP (n=31) and OLR (n=30) and 11 NOM were used to study the immunohistochemical expression of CD1a. The CD1a positive LCs in three regions (basal, suprabasal, and connective tissue) were counted in six randomly selected fields. Data were analyzed using the SPSS 24, T-test, ANOVA, LSD, Games-Howell tests. $P<.05$ was considered significant.

Results: CD1a expression in OLP and OLR was significantly higher compared to NOM ($P<.001$). CD1a expression in OLP was also significantly higher than OLR ($P=0.009$). There was a statistically significant difference between the three groups in basal, suprabasal and connective tissue regions ($P<.001$). The mean of CD1a positive cells in the basal, suprabasal and connective tissue regions was significantly higher in the OLP group than OLR and NOM. Also, in comparison between OLR and NOM, the OLR group had significantly more CD1a positive cells ($P<.05$).

Conclusion: Increasing the number of CD1a in OLP and OLR compared with the NOM indicates the role of LC in the pathogenesis of these diseases.

Keywords: Lichen planus, Lichenoid eruption, Langerhans cells, Immunohistochemistry

Citation for article: Majidian A, Seyedmajidi M, Abbaszadeh H, Sharbatdaran M, Jafari S, Gholinia H. CD-1a immunoexpression in oral lichen planus and oral lichenoid reaction. *Caspian J Dent Res* 2020; 9:26-34.

بیان ایمنو هیستوشیمیایی CD-1a در لیکن پلان و واکنش لیکنوئید دهانی

آزاده مجیدیان^۱، مریم سیدمجیدی^۲، حمید عباس زاده^{۳*}، مجید شربتداران^۴، سینا جعفری^۵، همت قلی نیا^۶

۱. دانشجوی دندانپزشکی، کمیته تحقیقات دانشجویی، دانشگاه علوم پزشکی بابل، بابل، ایران.

۲. استاد، مرکز تحقیقات مواد دندان، پژوهشکده سلامت، دانشگاه علوم پزشکی بابل، بابل، ایران.

۳. دانشیار، گروه پاتولوژی دهان، فک و صورت، دانشکده دندانپزشکی، دانشگاه علوم پزشکی بیرجند، بیرجند، ایران.

۴. استادیار، مرکز تحقیقات بیولوژی سلولی و مولکولی، پژوهشکده سلامت، دانشگاه علوم پزشکی بابل، بابل، ایران.

۵. دانشجوی دستپاری، گروه پروتئین‌های دندان، دانشکده دندانپزشکی، دانشگاه شاهدتهران، تهران، ایران.

۶. کارشناسی ارشد آمار، پژوهشکده سلامت، دانشگاه علوم پزشکی بابل، بابل، ایران.

*نویسنده مسئول: حمید عباس زاده، دانشکده دندانپزشکی، دانشگاه علوم پزشکی بیرجند، بیرجند، ایران.

پست الکترونیکی: hamidabbaszade@yahoo.com تلفن: +۹۸۵۶۳۳۸۱۷۰۳

چکیده

مقدمه: لیکن پلان دهانی یک بیماری با واسطه ایمنی پوستی-مخاطی است. مطالعات از پایه با واسطه ایمنولوژیک برای این بیماری حمایت می کنند. سلولهای لانگرهانس، سلولهای ایمنی مقیم در مخاط دهان هستند که همراه با لنفوسیت‌های داخل اپی تلیالی در دفاع مخاطی نقش دارند. هدف از مطالعه حاضر بررسی بیان ایمنو هیستوشیمیایی سلولهای لانگرهانس در لیکن پلان دهانی و ضایعات لیکنوئید دهانی در مقایسه با مخاط نرمال دهان بود.

مواد و روش ها: در این مطالعه مقطعی ۶۱ نمونه مخاطی با تشخیص هیستوپاتولوژیکی لیکن پلان دهانی (۳۱ مورد)، واکنش لیکنوئید دهانی (۳۰ مورد) و ۱۱ نمونه مخاط نرمال دهانی برای بیان ایمنو هیستوشیمیایی CD-1a استفاده شدند. سلولهای لانگرهانس CD-1a در سه منطقه شامل لایه بازال و سوپرا بازال اپیتلیوم و بافت همبندی در ۶ فیلد به طور تصادفی شمارش شدند. داده ها با استفاده از آزمون های آماری SPSS 24, T-test, ANOVA, LSD, Games-Howell tests تحلیل شد. $P < 0.05$ به عنوان سطح معناداری در نظر گرفته شد.

یافته ها: بیان CD-1a در OLP و OLR در مقایسه با مخاط نرمال بسیار بالاتر بود. ($P < 0.001$) در CD-1a در OLP نیز به طور معنی داری بیشتر از OLR بود ($P = 0.009$) اختلاف آماری معنی داری بین سه گروه در بازال، سوپرا بازال و بافت همبند وجود داشت ($P < 0.001$) میانگین سلولهای بیان کننده CD-1a در لایه های بازال، سوپرا بازال و بافت همبند در گروه OLP به طور معنی داری بیشتر از OLR و مخاط نرمال بود. همچنین، در مقایسه با OLR و مخاط نرمال، در گروه OLR سلولهای بیان کننده CD-1a به میزان قابل توجهی بیشتر بود ($P < 0.05$).

نتیجه گیری: افزایش تعداد CD-1a در OLP و OLR در مقایسه با مخاط نرمال نشان دهنده نقش سلولهای لانگرهانس در پاتوژنز این بیماریها است.

واژگان کلیدی: لیکن پلان، واکنش لیکنوئید، سلولهای لانگرهانس، ایمنو هیستوشیمی

Introduction

Oral lichenoid reaction (OLR) is clinically and histopathologically similar to oral lichen planus (OLP); [1-9] Pathogenesis of OLP and OLR is unclear. Most studies support an immunologically-mediated etiopathogenesis [1,3,5,7,10,11] Attention has been paid to epithelial antigen presenting cells and mast cells and

induction of lymphocytic response in the underlying connective tissue by these cells. [1,5,7,10-15] Langerhans cells (LC) are dendritic cells of the skin and present in all layers of the epidermis and are most prominent in the stratum spinosum. They are also present in oral epithelium. [9, 16-19] Langerhans cells (LCs) appear to play

an important role in OLP pathogenesis through presenting of antigens to T lymphocytes.^[11,15] Some studies suggest a change in the number of Langerhans cells in OLP^[9,19-23] which can confirm the role of LCs in the etiopathogenesis of the OLP.^[9,18,24,25]

The similar clinical picture of the OLP and OLR probably indicates similarities in immune responses between the two diseases and it is hypothesized that the pathogenesis of these two conditions should be somewhat similar.^[11] CD1a is a membrane surface glycoprotein that has good specificity for Langerhans cells.^[23,26-28] Its expression in OLP and OLR has been studied in some researches which has been associated with contradictory results.^[9,19-21,23,26,28-33] Therefore, present study was aimed to determine the immunohistochemical expression of CD1a (for detection of LCs) in OLP and OLR and their subtypes (atrophic-erosive and reticular subtypes) and to compare it with normal oral mucosa (NOM).

Materials & Methods

Samples: This cross-sectional analytical study was approved by ethical committee of Babol University of Medical sciences (Code of ethics: IR.MUBABOL.REC.1397.010). Thirty one formalin-fixed paraffin-embedded (FFPE) tissue blocks of OLP samples (16 cases of atrophic –erosive subtype and 15 cases of reticular subtype) and 30 FFPE OLR samples were retrieved from archive of oral and maxillofacial pathology department of Babol dental school. Also, 11 NOM samples (as control group) were included in the study (these consisted of gingival tissues with minimal clinical and histopathological inflammation belong to patients undergoing surgical extraction of impacted third molar tooth or dental implants surgery). The criteria for diagnosis of OLP and OLR was based on world health organization (WHO) defining criteria. Hematoxylin and eosin stained slides were re-evaluated to confirm the diagnosis; Samples which had been misdiagnosed were excluded from the study. Also cases with inadequate epithelium were excluded.

Table 1. Age and gender distribution in the studied groups

Group	Number		Age(Mean±SD)		Pvalue
	Male	Female	Male	Female	
Oral lichen planus	19	12	44.67±14.00	49.53±12.12	0.314
Oral lichenoid reaction	13	17	67.23±18.95	47.00±10.26	0.03
Normal oral mucosa	4	7	45.00±13.44	49.71±14.98	0.616
Total	72		51.08±15.50		0.128

Immunohistochemicalstaining:

Immunohistochemistry (IHC) was performed using a standard streptavidin-biotin protocol.^[23]

Sections were incubated with primary antibodies (clone 010, 1:80 dilution; Dako, Glostrup, Denmark) for 1 hour at room temperature. The slides were incubated with secondary antibodies conjugated with horseradish peroxidase (HRP) (LSAB[®]+ system- HRP, Mouse/Rabbit; Dako, Glostrup, Denmark) for 30 minutes at 37°C. Human skin was used as positive control. Negative controls were used by omitting primary antibody. Histopathologic examinations were performed using Olympus BX41 light microscope (Olympus, Tokyo, Japan). langerhans cells stained brown and had a nucleus with clear boundaries and well-formed dendrites. The CD1a⁺ Langerhans cells were counted manually at six randomly selected high power fields (HPFs). The number of CD1a⁺ LCs in each sample was calculated as the mean number of positive cells per HPF.^[23] In three studied groups, CD1a⁺ cells were counted in three regions: basal, suprabasal, and connective tissue. Data were analyzed using the SPSS version 24 software (SPSS Inc., Chicago, USA) and T-test, ANOVA, LSD, Games-Howell statistical tests. P-value <0.05 was considered significant.

Results

In this research, study sample consisted of 72 tissue samples including 31 OLP samples (16 reticular forms and 15 atrophic-erosive forms), 30 OLR samples, and 11 NOM samples (as control group) (Table 1). Significant difference were found between CD1a⁺ cells in three studied groups (P<0.001). (Figure 1). According to Post hoc Games-Howell test, the number of CD1a⁺ cells in OLP was significantly higher than control and OLR (P<0.001 and P=0.009, respectively). There was also a statistically significant difference in the mean CD1a⁺ cells between OLR and control group (P<0.001) (Table 2). Table 3 shows mean number of CD-1a⁺ cells of basal, suprabasal and connective tissue regions in three studied groups.

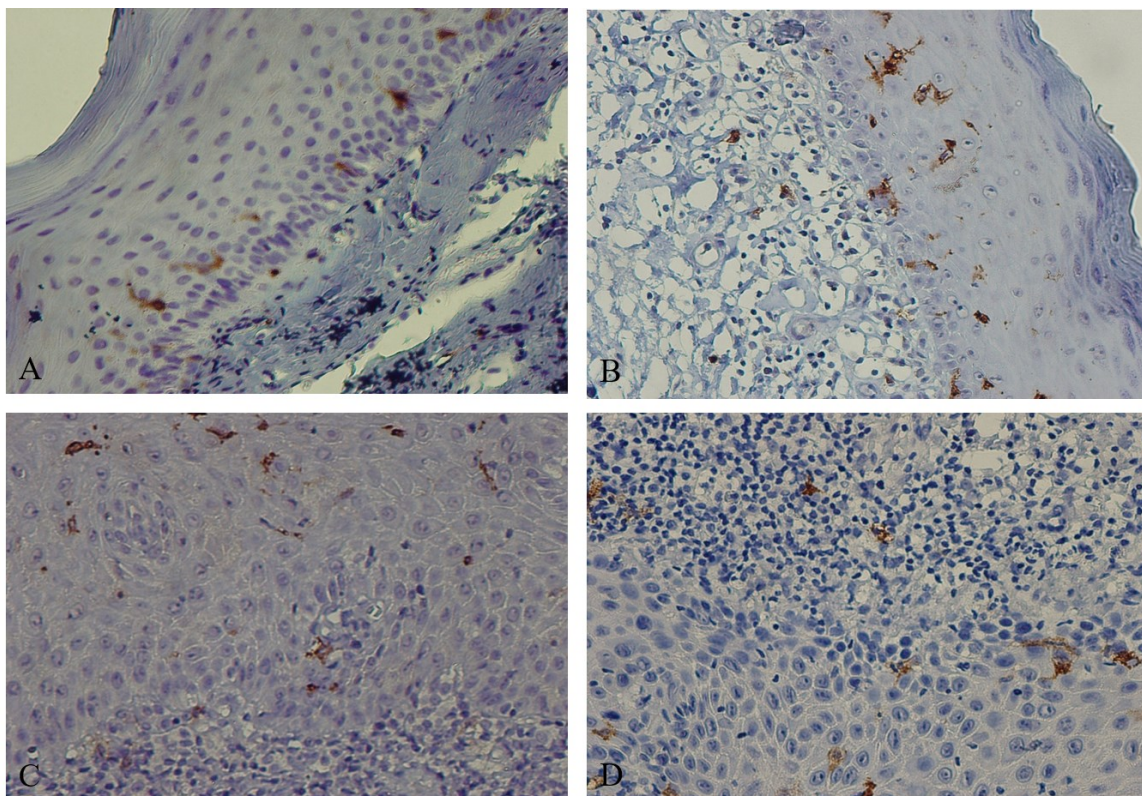


Figure 1. Immunohistochemical expression of CD1a. A) Normal oral mucosa, B) Erosive Oral lichen planus, C) Reticular Oral lichen planus, and D) Oral lichenoid reaction

Table 2. Comparison of the mean number of CD-1a⁺ cells in three studied groups

Groups	N	Mean	Standard deviation	Minimum	Maximum
OLP	31	6.375	4.769	0.4	35.00
OLR	30	4.484	3.745	0.0	24.10
NOM	11	1.160	1.390	0.0	5.8

OLP, Oral lichen planus; OLR, Oral lichenoid reaction; NOM, Normal Oral Mucosa; n, Number

Table 3. Comparison of the mean number of CD-1a⁺ cells of basal, suprabasal and connective tissue regions in three studied groups

Groups	OLP	OLR	NOM	P-Value
Region	Mean (±Standard Error)	Mean (±Standard Error)	Mean (±Standard Error)	
Basal Region	5.887(±0.585)*¥	4.100(±0.503)§	1.227(±0.348)	<0.001
Suprabasal Region	9.358(±1.106)**¥	6.696(±0.824)£	1.963(±0.529)	<0.001
Connective Tissue	3.880(±0.413)***¥	2.656(±0.462)¥	0.290(±0.142)	<0.001
P-Value	<0.001	<0.001	0.013	

OLP, Oral lichen planus; OLR, Oral lichenoid reaction; NOM, Normal Oral Mucosa

*There was a statistically significant difference (P = 0.016) between OLP and OLR groups in the basal region.

**There was a statistically significant difference (P = 0.043) between OLP and OLR groups in the suprabasal region.

*** There was a statistically significant difference (P = 0.037) between OLP and OLR groups in the connective tissue region.

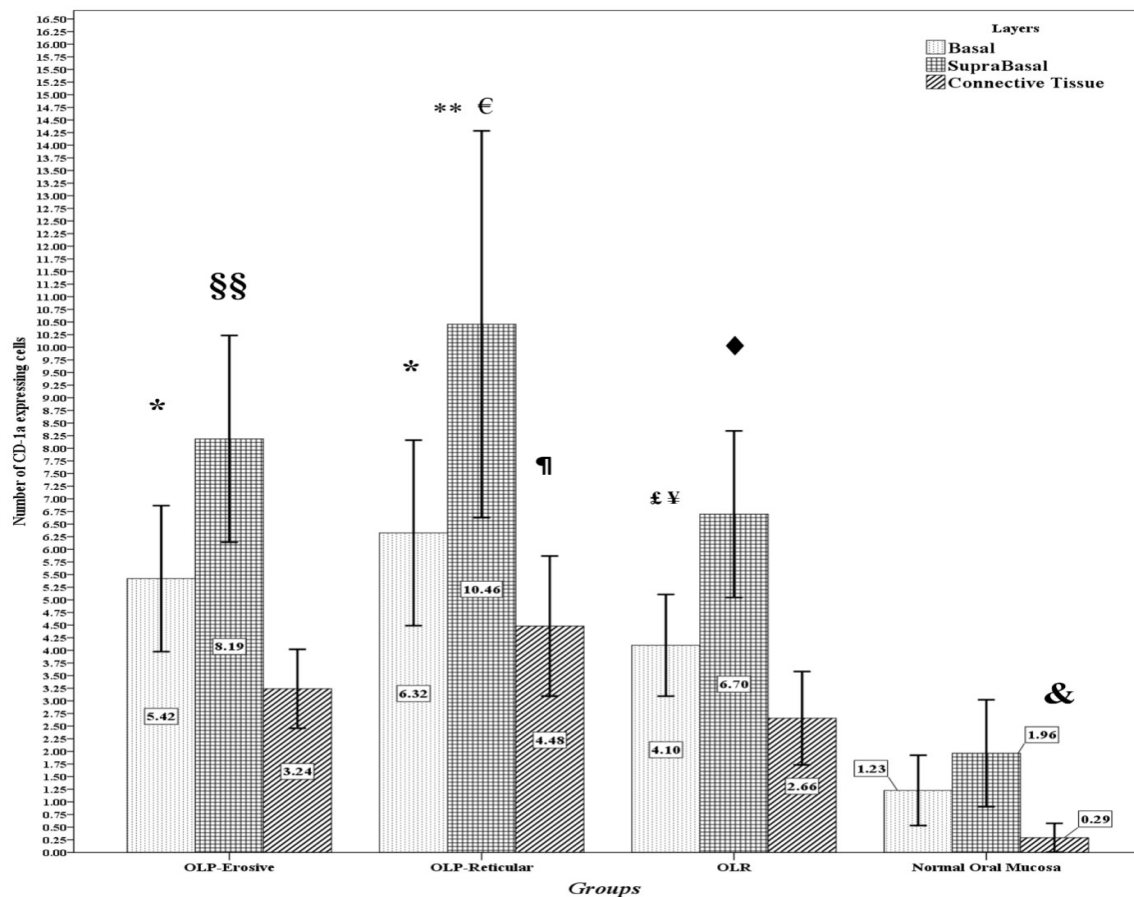
¥There was a statistically significant difference (P <0.001) between OLP and NOM in basal, suprabasal and connective tissue regions, and between OLR and NOM in the connective tissue region.

§There was a statistically significant difference (P = 0.005) between OLR and NOM in the basal region.

£There was a statistically significant difference (P = 0.010) between OLR and NOM in the suprabasal region.

There was a statistically significant difference between the three studied groups in basal, suprabasal and connective tissue regions. The highest mean of CD1a⁺ cells was found in the suprabasal region of the OLP group and the lowest in connective tissue region of NOM. Graph 1 shows comparison of the mean number

of CD1a⁺ cells between reticular subtype of OLP, atrophic-erosive subtype of OLP, OLR and NOM groups. Significant differences were observed in three regions of the four above-mentioned groups. P-values were <0.001 in basal and connective tissue regions, and 0.001 in suprabasal region, respectively (Graph 1).



Graph 1. Comparison of the number of CD-1a expressing cells between four groups in three regions

*There was a statistically significant difference (P = 0/001) between erosive subtype of OLP and reticular subtype of OLP compared to NOM in the basal region.

¥There was a statistically significant difference (P = 0.013) between reticular subtype of OLP and OLR in the basal region.

£There was a statistically significant difference (P = 0.005) between OLR and NOM in the basal region.

§§ There was a statistically significant difference between erosive subtype of OLP and NOM (P = 0.003) in the suprabasal region.

** There was a statistically significant difference between reticular subtype of OLP and OLR (P = 0.018) in the suprabasal region.

€ There was a statistically significant difference between reticular subtype of OLP and NOM (P <0.001) in the suprabasal region.

◆ There was a significant difference between OLR and NOM groups (P = 0.009) in the suprabasal region.

¶ There was a statistically significant difference (P = 0.1010) between reticular subtype of OLP and OLR in the connective tissue region.

& There was a statistically significant difference between erosive subtype of OLP, reticular subtype of OLP and OLR in comparison with NOM (P = 0.001, P <0.001, P = 0.004) in connective tissue region.

Discussion

We evaluated CD1a expression in OLP (reticular and atrophic-erosive subtypes), OLR and NOM. The mean number of CD1a⁺ cells in OLP was significantly higher than OLR and NOM. OLR also expressed a higher CD1a⁺ cells than NOM. In comparison between different regions of OLP and OLR, it was found that the suprabasal region had more CD1a⁺ cells than basal and connective tissue regions. Despite the higher number of CD1a⁺ cells in the basal region compared to the connective tissue region, the difference was not significant. There was a significant difference between the suprabasal region and the connective tissue in the NOM group.

It has been reported that epithelial region has more CD1a⁺ cells compared with the connective tissue region. [11,17,23,29,31,34-37] Some studies indicated that there was no significant difference between the number of CD1a⁺ cells in OLP compared to control group. [15, 18, 38] One study showed that CD1a⁺ cells in the epithelium of the OLP decreased compared to the control group. [30] The reason for this discrepancy in the results can be related to the location of lesions and different antigenic stimuli in patients admitted in various studies, including the type of food used in different geographical areas and stress and mechanical pressures within the oral environment. [16,21,39]

Souto et al. reported that the number of CD1a⁺ cells in the connective tissue region in the OLP group was significantly higher than the normal mucosa and amalgam lichenoid reaction (ALR). Despite the higher mean of CD1a⁺ cells in the epithelium of the OLP and ALR groups compared to the control group, this difference was not significant. [21] In our study, the mean number of CD1a⁺ cells in the connective tissue and epithelium of the OLP group was higher than OLR and NOM. Souto et al. reported that the morphology of LCs in the epithelium and connective tissue regions were different, so that LCs in the epithelium region had many dendrites, but in the connective tissue region, these cells had round shape. [21] In the present study, LCs had similar shapes to LCs in Souto et al. study.

Gueiros et al. showed that CD1a⁺ cells was significantly higher in lichenoid lesions (OLP and oral lichenoid lesions) than control group. [9] This is in accordance with the results of this study. In the study of Devi et al., mean number of CD1a⁺ cells in basal, suprabasal and connective tissue regions of the OLP group was significantly higher than the NOM group and

lichenoid mucositis (LM). [26] Also in McCartan and Lamey [19], Regezi et al. [32], and Laine et al. [33] studies, the number of LCs in OLP was significantly higher than NOM group, but there was not significant difference between the different regions. Devi et al. study showed that there was not significant difference between LM and control group in the basal layer. There was no significant difference in LM and control group in connective tissue region.

They also observed that the mean of CD1a⁺ cells in the connective tissue region was much higher than suprabasal and basal regions. [26] Their observations are in contradictory with the results of the present study and studies by Kulkarni et al. [23], Chou et al. [34], Pitigala-Arachi et al. [35], Haseus et al. [11], VillarroelDorrego et al. [29], Santoro et al. [31], Gustafson et al. [37], and Mitamura et al. [40] In this study, LCs was present in the NOM group, which was similar to other studies. [11,17,29,31,34-37,40] Eversole and Farthing et al showed that dendritic cells in OLP were present in the epithelium and connective tissue, and are probably involved in the antigen processing and antigen presenting to CD4⁺ T lymphocytes. [18,41]

Immature LCs in the NOM expresses CD1a molecules more than other CD1 isoforms. [23,42] Kulkarni et al. stated that the higher expression of LCs in the epithelium compared to connective tissue could be because of that langerhans cells are present in the epithelium as guardians of the immune system and are constantly processing antigens and presenting them to T lymphocytes. [23] In addition, Haseus et al. [11], and Gustafson et al. [37] suggested that the presence of langerhans cells in the normal mucosa can better trap antigens. This increase can be due to the presence of many unknown antigens in the OLP lesions. [23] In the present study, the number of LCs in OLP and OLR groups were significantly higher than NOM group in connective tissue region. The increase in the number of LCs in the connective tissue of the OLR and OLP indicates that LCs are recruited to site of antigen entry, mature, and migrate to the lymph nodes via the connective tissue. [11,37]

In this study, the results showed that reticular subtype of OLP had more LCs than erosive subtype of OLP, OLR and NOM in all 3 regions, but this difference was not significant except in the erosive subtype of OLP. In comparison between OLR with erosive subtype of OLP, although there was a significant increase in LCs in the erosive subtype of OLP, this difference was

significant only in the basal region. In addition, LCs of erosive subtype were significantly higher than the NOM group at all three regions. Various staining techniques and counting method for detection and calculating number of LCs have been used including mean number per mm of basal layer, mean number per mm of epithelial surface, mean number per mm² of epithelium and mean number per high power field. Direct count and count method using photomicrographs can be noted.^[19] Gondak et al. also stated that the number of LCs in a normal epithelium vary greatly.^[39]

In the epiderm, immature LCs have little capability for antigen presenting.^[25,43,44] After antigen uptake, immature LCs are matured. So, mature LCs are antigen presenting cells (APCs) that had important role in immune response.^[43,44] In T-cell mediated autoimmune diseases, autoantigens presented by dendritic cells to T lymphocytes cause activity of T lymphocytes and finally cause tissue damage.^[37] In addition to autoimmunity, deregulation of LCs may occur in receptors such as CCR2, CCR6^[45], and CCR7^[30,31] or chemokines such as CCL2, CCL20, and CCL19 that are involved in LCs movements.^[45] Tolerance of LCs in some areas of oral mucosa of OLP may be altered.^[46, 47] Souto et al.^[21] stated LCs play different role in pathogenesis of OLP and OLR. Gueiros et al.^[9] stated that there was increased presence of LCs in OLR compared to NOM probably because of regulating immune response in OLR. In OLR secondary to medication, the number of LCs of epithelium are lower than OLP because direct presenting of antigens in epithelium is unlikely.^[19,26]

Conclusion

The mean number of CD1a⁺ LC in OLP group was higher than OLR and NOM groups. In addition, the mean number of CD1a⁺ LC in basal, suprabasal and connective tissue regions of the reticular subtype of OLP was higher than the three regions of OLR and NOM. It seems that antigen presenting by LCs had different role in OLP compared to OLR and has more contribution to OLP pathogenesis.

Funding: This study was research project (Grant no: 9745719), supported and funded by Babol University of Medical Sciences.

Conflict of interest: We declare no conflict of interest

Authors' Contribution

The study was designed by Maryam Seyedmajidi, Hamid Abbaszadeh and Majid Sharbatdaran. The study data were collected by Azadeh Majidian and Sina Jafari. Analysis and interpretation of data were pre-formed by Hemmat Gholinia. Study supervision was performed by Maryam Seyedmajidi.

References

1. De Rossi SS, Ciarrocca K. Oral lichen planus and lichenoid mucositis. *Dent Clin North Am* 2014;58:299-313.
2. Hoseinpour Jajarm H, Asadi R, Bardideh E, Shafae H, Khazaei Y, Emadzadeh M. The effects of photodynamic and low-level laser therapy for treatment of oral lichen planus-A systematic review and meta-analysis. *Photodiagnosis Photodyn Ther* 2018;23:254-60.
3. Seyedmajidi M, Shafai Sh, Hejazi M, Haji Ahmadi M, Siadati S. Expression of P53 and P63 in oral lichen planus and oral lichenoid lesions. *J Babol Univ Med Sci* 2011; 13: 7-13.
4. Yamanaka Y, Yamashita M, Innocentini LMA, Macedo LD, Chahud F, Ribeiro-Silva A, et al. Direct immunofluorescence as a helpful tool for the differential diagnosis of oral lichen planus and oral lichenoid lesions. *Am J Dermatopathol* 2018;40:491-7.
5. Alrashdan MS, Cirillo N, McCullough M. Oral lichen planus: a literature review and update. *Arch Dermatol Res* 2016;308:539-51.
6. Tampa M, Caruntu C, Mitran M, Mitran C, Sarbu I, Rusu LC, et al. Markers of oral lichen planus malignant transformation. *Dis Markers* 2018;2018:1959506.
7. Seyedmajidi M, Motallebnejad M, Foroughi R, Aslani F. Clinical and histopathological findings in 26 patients with oral lichenoid lesions. *J Babol Univ Med Sci* 2010; 12 :72-8.
8. De Rossi SS, Ciarrocca KN. Lichen planus, lichenoid drug reactions, and lichenoid mucositis. *Dent Clin North Am* 2005;49:77-89, viii.
9. Gueiros LA, Gondak R, Jorge Júnior J, Coletta RD, Carvalho Ade A, Leão JC, et al. Increased number of Langerhans cells in oral lichen planus and oral lichenoid lesions. *Oral Surg Oral Med Oral Pathol Oral Radiol* 2012;113:661-6.

10. Chiang CP, Yu-Fong Chang J, Wang YP, Wu YH, Lu SY, Sun A. Oral lichen planus - Differential diagnoses, serum autoantibodies, hematinic deficiencies, and management. *J Formos Med Assoc* 2018;117:756-65.
11. Hasséus B, Jontell M, Brune M, Johansson P, Dahlgren UI. Langerhans cells and T cells in oral graft versus host disease and oral lichen planus. *Scand J Immunol* 2001;54:516-24.
12. Giannetti L, DelloDiago AM, Spinasi E. Oral Lichen planus. *J Biol Regul Homeost Agents* 2018;32:391-5.
13. Muller S. Oral lichenoid lesions: distinguishing the benign from the deadly. *Mod Pathol* 2017;30:S54-S67.
14. Sankar V, Noujeim M. Oral manifestations of autoimmune and connective tissue disorders. *Atlas Oral Maxillofac Surg Clin North Am* 2017;25:113-26.
15. Sloberg K, Jonsson R, Jontell M. Assessment of Langerhans' cells in oral lichen planus using monoclonal antibodies. *J Oral Pathol* 1984;13:516-24.
16. Upadhyay J, Upadhyay RB, Agrawal P, Jaitley S, Shekhar R. Langerhans cells and their role in oral mucosal diseases. *N Am J Med Sci* 2013;5:505-14.
17. Lombardi T, Hauser C, Budtz-Jørgensen E. Langerhans cells: structure, function and role in oral pathological conditions. *J Oral Pathol Med* 1993;22:193-202.
18. Farthing PM, Matear P, Cruchley AT. The activation of Langerhans cells in oral lichen planus. *J Oral Pathol Med* 1990;19:81-5.
19. McCartan BE, Lamey PJ. Expression of CD1 and HLA-DR by Langerhans cells (LC) in oral lichenoid drug eruptions (LDE) and idiopathic oral lichen planus (LP). *J Oral Pathol Med* 1997;26:176-80.
20. Maloth AK, Dorankula SP, Pasupula AP, Thokala MR, Muddana K, Ramavath R. A Comparative Immunohistochemical Analysis of Langerhans Cells in Oral Mucosa, Oral Lichen Planus and Oral Squamous Cell Carcinoma. *J Clin Diagn Res* 2015;9:ZC76-9.
21. Souto GR, Nunes LF, Tanure BB, Gomez RS, Mesquita RA. CD1a+ dendritic cells in oral lichen planus and amalgam lichenoid reaction. *Oral Surg Oral Med Oral Pathol Oral Radiol* 2016;121:651-6.
22. Deguchi M, Aiba S, Ohtani H, Nagura H, Tagami H. Comparison of the distribution and numbers of antigen-presenting cells among T-lymphocyte-mediated dermatoses: CD1a+, factor XIIIa+, and CD68+ cells in eczematous dermatitis, psoriasis, lichen planus and graft-versus-host disease. *Arch Dermatol Res* 2002;294:297-302.
23. Kulkarni G, Sakki EP, Kumar YV, Kolimi S, Perika R, Karthik KV, et al. Expression of CD1a by langerhans' cells in oral lichen planus - A retrospective analysis. *J Clin Diagn Res* 2016;10:ZC28-31.
24. Dhodapkar MV, Steinman RM, Sapp M, Desai H, Fossella C, Krasovsky J, et al. Rapid generation of broad T-cell immunity in humans after a single injection of mature dendritic cells. *J Clin Invest* 1999;104:173-80.
25. Banchereau J, Briere F, Caux C, Davoust J, Lebecque S, Liu YJ, et al. Immunobiology of dendritic cells. *Annu Rev Immunol* 2000;18:767-811.
26. Devi M, Saraswathi TR, Ranganathan K, Vijayalakshmi D, Sreeja C, Fathima SS. Langerhans cells in lichen planus and lichenoid mucositis an immunohistochemical study. *J Pharm Bioallied Sci* 2014;6(Suppl 1):S146-9.
27. Kim JH, Hu Y, Yongqing T, Kim J, Hughes VA, Le Nours J J, et al. CD1a on Langerhans cells controls inflammatory skin disease. *Nat Immunol* 2016;17:1159-66.
28. Scully C, Beyli M, Ferreira MC, Ficarra G, Gill Y, Griffiths M, et al. Update on oral lichen planus: etiopathogenesis and management. *Crit Rev Oral Biol Med* 1998;9:86-122.
29. Villarreal Dorrego M, Correnti M, Delgado R, Tapia FJ. Oral lichen planus: immunohistology of mucosal lesions. *J Oral Pathol Med* 2002;31:410-4.
30. Mukae S, Okazaki Y, Tsuda H, Nagai K, Matsumoto N, Ochiai T, et al. Detection of fascin and CCR-7 positive mature dendritic cells in oral lichen planus. *J Oral Pathol Med* 2009;38:334-42.
31. Santoro A, Majorana A, Roversi L, Gentili F, Marrelli S, Vermi W, et al. Recruitment of dendritic cells in oral lichen planus. *J Pathol* 2005;205:426-34.
32. Regezi JA, Stewart JC, Lloyd RV, Headington JT. Immunohistochemical staining of Langerhans cells and macrophages in oral lichen planus. *Oral Surg Oral Med Oral Pathol* 1985;60:396-402.
33. Laine J, Kontinen YT, Beliaev N, Happonen RP. Immunocompetent cells in amalgam-associated oral lichenoid contact lesions. *J Oral Pathol Med* 1999;28:117-21.

34. Chou LL, Epstein J, Cassol SA, West DM, He W, Firth JD. Oral mucosal Langerhans' cells as target, effector and vector in HIV infection. *J Oral Pathol Med* 2000;29:394-402.
35. Pitigala-Arachchi A, Crane IJ, Scully C, Prime SS. Epithelial dendritic cells in pathological human oral tissues. *J Oral Pathol Med* 1989;18:11-6.
36. van Loon LAJ, Krieg SR, Davidson CL, Bos JD. Quantification and distribution of lymphocyte subsets and Langerhans cells in normal human oral mucosa and skin. *J Oral Pathol Med* 1989;18:197-201.
37. Gustafson J, Eklund C, Wallstrom M, Zellin G, Magnusson B, Hasseus B. Langerin-expressing and CD83-expressing cells in oral lichen planus lesions. *Acta Odontol Scand* 2007;65:156-61.
38. Chou MJ, Daniels TE. Langerhans cells expressing HLA-DQ, HLA-DR and T6 antigens in normal oral mucosa and lichen planus. *J Oral Pathol Med* 1989;18:573-6.
39. Gondak RO, Alves DB, Silva LF, Mauad T, Vargas PA. Depletion of Langerhans cells in the tongue from patients with advanced-stage acquired immune deficiency syndrome: relation to opportunistic infections. *Histopathology* 2012;60:497-503.
40. Mitamura J, Onodera K, Ooya K. Histopathological and immunohistochemical study of oral lichen planus in the buccal mucosa: relationship between clinicopathological features and histometrical analysis. *Oral Med Pathol* 2008;13:1-6.
41. Eversole LR. Immunopathology of oral mucosal ulcerative, desquamative, and bullous diseases. Selective review of the literature. *Oral Surg Oral Med Oral Pathol* 1994;77:555-71.
42. Roopashree MR, Gondhalekar RV, Shashikanth MC, George J, Thippeswamy SH, Shukla A. Pathogenesis of oral lichen planus--a review. *J Oral Pathol Med* 2010;39:729-34.
43. Banchereau J, Steinman RM. Dendritic cells and the control of immunity. *Nature* 1998;392:245-52.
44. Steinman RM. The dendritic cell system and its role in immunogenicity. *Annu Rev Immunol* 1991;9:271-96.
45. Caux C, Ait-Yahia S, Chemin K, de Bouteiller O, Dieu-Nosjean MC, Homey B, et al. Dendritic cell biology and regulation of dendritic cell trafficking by chemokines. *Springer Semin Immunopathol* 2000;22:345-69.
46. Incorvaia C, Frati F, Sensi L, Riario-Sforza GG, Marcucci F. Allergic inflammation and the oral mucosa. *Recent Pat Inflamm Allergy Drug Discov* 2007;1:35-8.
47. Rattis FM, Peguet-Navarro J, Staquet MJ, Dezutter-Dambuyant C, Schmitt D, Courtellemont P, et al. Expression and function of B7-1 (CD80) and B7-2 (CD86) on human epidermal Langerhans cells. *Eur J Immunol* 1996;26:449-53.