

CASE REPORT

PINEAL GERMINOMA – HYPOGONADISM ISSUES

**Alexandra BOLOCAN^{1,2}, Bogdan SOCEA^{2,3}, Dan N. PADURARU^{1,2}, Oana BOTEZAN⁴,
Octavian ANDRONIC^{1,2}, Andra MORAR⁵, Cristina MOLDOVAN⁴, Alexandra ENE⁴,
Roxana TURTUREA⁴, Mara CARȘOTE^{6✉}, Ana VALEA^{3,7}**

¹ General Surgery Department and Emergency III, University Emergency Hospital of Bucharest, Romania

² „Carol Davila“ University of Medicine and Pharmacy, Bucharest, Romania

³ Clinical Emergency Hospital „Sf. Pantelimon“, Bucharest, Romania

⁴ County Clinical Hospital, Cluj-Napoca, Romania

⁵ Clinical Hospital of Infectious Diseases, Cluj-Napoca, Romania

⁶ „C.I. Parhon“ National Institute of Endocrinology, Bucharest, Romania

⁷ „I. Hatieganu“ University of Medicine and Pharmacy, County Clinical Hospital, Cluj-Napoca, Romania

Received 10 Oct 2019, Accepted 13 Nov 2019

<https://doi.org/10.31688/ABMU.2019.54.4.25>

ABSTRACT

Introduction. Pineal tumors are an inhomogeneous group of lesions with pineal origin, characterized by various degrees of hypothalamic-pituitary dysfunction.

Case presentation. We present the case of a patient with pineal germinoma and hypogonadotropic hypogonadism who was evaluated in several medical centers. A 31-year-old male patient with a history of primary hypothyroidism and pineal germinoma, for which he underwent surgery, radiation and chemotherapy, was admitted for frontal-temporal headache, nausea and moderate intensity asthenia. Clinical examination revealed normal weight, normal blood pressure, left eye strabismus, pale skin, diminished facial and body hair, bilateral gynecomastia. The endocrine profile showed adequate thyroid hormone replacement, low normal basal cortisol levels (5.88 µg/dL, normal 5-25 µg/dL), low IGF-1 (Insulin-like Growth Factor) (93.2 pg/mL, normal 115-307 pg/mL), low gonadotrophins, testosterone (0.57 ng/mL, normal 1.3-8.53 ng/mL) and estradiol (<10 pg/mL, normal 15-60 pg/mL). Breast ultrasound showed bilateral asymmetric gynecomastia,

RÉSUMÉ

Le séminome pinéal – aspects d’hypogonadisme

Introduction. Les tumeurs pinéales forment un groupe non homogène de lésions d’origine pinéale, caractérisées par divers degrés de dysfonctionnement hypothalamo-hypophysaire.

Présentation du cas. Nous présentons le cas d’un patient atteint de séminome pinéal et d’hypogonadisme hypo-gonadotrope évalué dans plusieurs centres médicaux. Un patient de 31 ans aux antécédents d’hypothyroïdie primitive et de séminome pinéal, pour lequel il a subi une intervention chirurgicale, une radiothérapie et une chimiothérapie, a été admis pour des maux de tête fronto-temporaux, des nausées et une asthénie d’intensité modérée. L’examen clinique a montré un poids normal, une tension artérielle normale, un strabisme de l’œil gauche, une peau pâle, une pilosité faciale et corporelle réduite, une gynécomastie bilatérale. Le profil endocrinien montrait un remplacement adéquat des hormones thyroïdiennes, des taux de cortisol basal normaux (5,88 µg / dL, normaux:

✉ Address for correspondence:

Mara CARȘOTE
„C.I. Parhon“ National Institute of Endocrinology, Bucharest, Romania
E-mail: carsote_m@hotmail.com; Phone +40 213 172 041

BIRADS-2. No tumors or surgery complications were found on MRI (Magnetic Resonance Imaging) exam. A diagnosis of hypogonadotropic hypogonadism was established and surgical cure of gynecomastias, as well as testosterone replacement therapy were recommended.

Conclusions. Pineal germinomas are rare tumors associated with increased risk of endocrine dysfunctions, including hypogonadotropic hypogonadism, as a consequence of germinoma-specific therapy. Frequent biochemical assessment as well as follow-up imaging are needed, in order to prevent tumor recurrence and long-term complications related to the germinoma itself or the chosen therapy.

Keywords: germinoma, hypogonadism, gynecomastia.

INTRODUCTION

Pineal tumors are an inhomogeneous group of benign or malignant lesions of pineal origin, characterized by various degrees of hypothalamic-pituitary dysfunction¹. Tumors of the pineal region account for 1% of intracranial tumors. The most common histological types are germinomas and teratomas. Germ cell tumors constitute approximately 35% of all pineal lesions. Tumors of pineal origin, pinealoblastomas and pineocytomas, are a rare occurrence. On imaging studies, they differentiate from other cell types by disseminated calcifications rather than the engulfment of the calcifications, as seen in germinomas².

The treatment course of these lesions is controversial. Before microsurgical techniques were developed, the preferred therapy involved avoidance of surgery, due to increased mortality (ranging from 30 to 70%) and morbidity (of 65%)². Therefore, the treatment of choice was cerebral ventricular shunting and fractionated radiotherapy, proven to have lower mortality rates (of 5%) and a higher survival rate (up to 70%)³. We present the case of a patient with pineal germinoma and hypogonadotropic hypogonadism, who was evaluated in several medical centers.

5-25 µg / dL), un facteur de croissance faible de IGF-1 (insuline-like like) (93,2pg / mL, normal: 115- 307pg / mL), des gonadotrophines basses, de la testostérone (0.57ng / mL, normal: 1.3-8.53ng / mL) et de l' estradiol (<10pg / mL, normal: 15-60pg / mL). L'échographie mammaire a révélé une gynécomastie asymétrique bilatérale, BIRADS-2. Aucune tumeur ni complication chirurgicale n'a été trouvée lors de l'examen IRM (Imagerie par résonance magnétique). Un diagnostic d'hypogonadisme hypo-gonadotrope a été établi et la guérison chirurgicale des gynécomasties ainsi qu'un traitement substitutif à la testostérone ont été recommandés.

Conclusions. Les séminomes pinéaux sont des tumeurs rares associées à un risque accru de dysfonctionnements du système endocrinien, notamment d'hypogonadisme hypo-gonadotrope, en conséquence d'un traitement spécifique du séminome. Une évaluation biochimique fréquente ainsi qu'une imagerie de suivi sont nécessaires pour éviter la récurrence de la tumeur et les complications à long terme liées au séminome ou à la thérapie choisie.

Mots-clés: séminome, hypogonadisme, gynécomastie.

CASE PRESENTATION

A 31-year-old male patient was admitted for frontal-temporal headache, nausea and moderate intensity asthenia. His past medical history mentioned a pineal germinoma diagnosed at age 15, for which he underwent surgery 4 months later, followed by chemotherapy and radiotherapy. One year after treatment, he developed intracranial hypertension due to obstructive hydrocephalus, for which a right ventriculoperitoneal shunt was placed. Five years later he was diagnosed with primary hypothyroidism and thyroid replacement therapy was prescribed.

At the current admission, clinical examination revealed height of 180 cm, weight of 77 kg, BMI (Body Mass Index) of 23.77 kg/m², normal blood pressure of 105/65 mmHg, heart rate of 72 bpm, left eye strabismus, pale skin, diminished facial and body hair and bilateral gynecomastia. The hormonal profile showed adequate thyroid hormone replacement, with negative anti-thyroid antibodies, low normal basal serum cortisol (of 5.88 µg/dL, normal: 5-25 µg/dL), low IGF-1 (of 93.2 pg/mL, normal: 115-307 pg/mL), low gonadotrophins, testosterone (of 0.57 ng/mL, normal: 1.3-8.53ng/mL), estradiol (of <10 pg/mL, normal: 15-60 pg/mL) and normal prolactin levels (Table 1). Biochemical workup showed normal renal and hepatic function, hypercholesterolemia and

Table 1. The postoperative endocrine and biochemical parameters of a 31-year-old man diagnosed with hypogonadotropic hypogonadism after radiation and chemotherapy for pineal germinoma

Parameter	Value	Normal limits	Units
Testosterone	0.57	1.3-8.53	ng/mL
FSH	3.70	0.7-11.5	U/L
LH	2.34	0.8-7.6	U/L
PRL	16.4	2.5-17	ng/mL
Estradiol	< 10	15-60	pg/mL
TSH	*2.91	0.4-4	μIU/mL
FT4	*1.02	0.89-1.76	ng/dL
Serum cortisol	5.88	5-25	μg/dL
IGF-1	93.2	115-307	ng/mL
AST	23	< 50	U/L
ALT	29	< 50	U/L
Iron	51	70-180	μg/dL
Cholesterol	282	< 200	mg/dL
Triglycerides	140	< 150	ng/dL
Glycemia	86	74-106	mg/dL
Hemoglobin	14.1	13-17	g/dL
Hematocrit	40.9	40-54	%

Legend. FSH= Follicle-Stimulating Hormone; LH= Luteinizing Hormone; PRL= prolactin; TSH= Thyroid Stimulating Hormone; FT4= Free Thyroxine; IGF-1= Insulin-like Growth Factor 1; ALT= Alanine Aminotransferase; AST= Aspartate Aminotransferase

* 25 μg/day Thyroxine therapy.

hypoferraemia with normal hematological index values (Table 1).

Thyroid ultrasound revealed normal volume and echogenicity, with a hypochoic nodule, measuring 4.5/2.3 mm, located on the anterior side of the right lobe. Breast ultrasound showed bilateral asymmetric gynecomastia, BIRADS-2. Contrast-enhanced brain MRI excluded tumor recurrence and showed the proper position of the cerebral ventricular shunt (Figure 1).

A diagnosis of hypogonadotropic hypogonadism was established and surgical cure for gynecomastia, as well as testosterone replacement therapy, were recommended, along with thyroid replacement therapy, hypolipidemic treatment and iron supplementation.

DISCUSSION

Pineal tumors account for 1% of brain tumors and up to 11% of the tumors discovered in children⁴. Previous studies have not come to an agreement concerning the optimal treatment of pineal tumors, but it has been emphasized that biopsy and hydrocephalus treatment are of an extreme importance⁵. Germinal tumors are rare, with an incidence of 0.4-3.4% and are commonly diagnosed between the ages of 10 and 20 years⁵. The main risk associated with germinomas concerns the normal development

of children⁶. Patients with pineal germinomas have hypothalamic-pituitary dysfunction at presentation. Other manifestations include: Parinaud's syndrome, which leads to upward gaze paralysis, impairment of pupillary photo-motor responses, accommodation reflexes or ocular convergence. These tumors can also lead to intracranial hypertension, due to obstructive

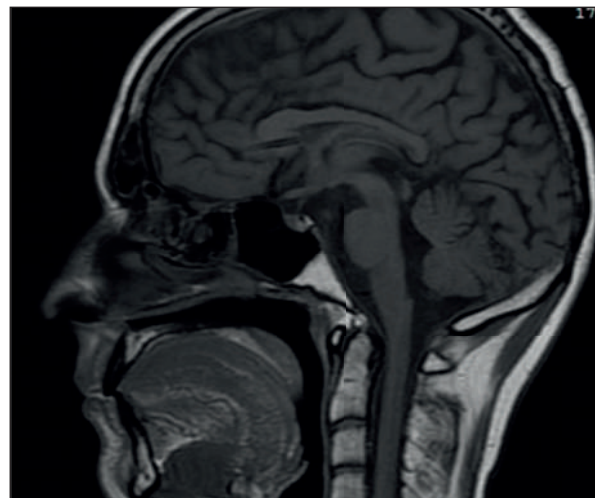


Figure 1. Postoperative contrast-enhanced brain MRI of a 31-year-old man: absence of pineal germinoma recurrence after surgery followed by radiation and chemotherapy. Sagittal plane.

hydrocephalus⁷. Endocrine manifestations include: diabetes insipidus (through suprasellar and 3rd ventricle involvement), gonadal dysfunction and precocious puberty⁸. They secrete hCG (human Chorionic Gonadotrophin), which stimulates Leydig cells, increasing testosterone production and leading to precocious puberty⁸.

The diagnosis can be established through imaging, usually CT (computed tomography) or MRI, but the main challenge consists in differentiating germinomas from gliomas or metastatic brain lesions. Another diagnostic tool is stereotactic biopsy of the tumor tissue, performed endoscopically⁹. Pure germinomas are inhomogeneous and small, with a maximum diameter of 2 mm, and there is a chance biopsy could not reach them⁹. The levels of hCG and AFP (alpha fetoprotein) can be measured in the CSF (cerebral spinal fluid) and high levels could indicate malignancy. CSF cytology helps establish tumor extension to the ventricular system and spinal subarachnoid region¹⁰. The treatment options involve radiotherapy, chemotherapy and radiosurgery. An important complication of pineal tumors is hydrocephalus, which can be treated either by placing a ventriculoperitoneal shunt in order to reduce intracranial pressure, with a risk of peritoneal dissemination or by using endoscopic third ventriculostomy, with lower risk of dissemination, but higher risk of infection¹¹⁻¹⁵.

This type of lesion needs to be differentiated from other more frequent tumors of pituitary – hypothalamic area which may cause hypogonadism, like incidentalomas or macroadenomas¹⁶⁻¹⁸ and clinical outcome from paraneoplastic syndromes^{19,20}.

In our case, the pineal lesion was treated by surgery and adjuvant radiation and chemotherapy. Due to the development of hydrocephalus, a ventriculoperitoneal shunt was placed a year after the radical therapy of the germinoma. The patient was closely monitored and there was no tumor recurrence, but he developed pituitary dysfunction in the form of hypogonadotropic hypogonadism and therefore hormone replacement therapy was recommended.

CONCLUSIONS

Pineal germinomas are rare tumors associated with increased risk of endocrine dysfunctions, including hypogonadotropic hypogonadism as a consequence of germinoma-specific therapy. Frequent biochemical assessment, as well as follow-up imaging are needed, in order to prevent tumor recurrence and long-term complications related to the germinoma itself or the chosen therapy.

Compliance with Ethics Requirements:

„The authors declare no conflict of interest regarding this article“

“The authors declare that all the procedures and experiments of this study respect the ethical standards in the Helsinki Declaration of 1975, as revised in 2008(5), as well as the national law. Informed consent was obtained from the patient included in the study“

„No funding for this study“

REFERENCES

1. Nagaishi M, Suzuki R, Tanaka Y, et al. Pure germinoma of the pineal gland with synchronous spinal dissemination. *Neurol Med Chir (Tokyo)* 2010; 50.
2. Dumrongpisutikul N, Intrapiromkul J, Yousem DM. Distinguishing between Germinomas and Pineal Cell Tumors on MR Imaging. *Am J Neuroradiol* 2012;33:550-55.
3. Yousem DM, Grossman RI. Neoplasms of the brain. In: Yousem DM, Grossman RI, eds. *Neuroradiology: The Requisites*, 3rd ed., Philadelphia: Mosby, 2010:94-98.
4. Dahiya S, Perry A. Pineal tumors. *Adv Anat Pathol* 2010;17:419-27.
5. Komakula S, Warmuth-Metz M, Hildenbrand P, et al. Pineal parenchymal tumor of intermediate differentiation: imaging spectrum of an unusual tumor in 11 cases. *Neuroradiology* 2010; 53: 577- 84.
6. Vaghela V, Radhakrishnan N, Radhakrishnan VV, et al. Advanced magnetic resonance imaging with histopathological correlation in papillary tumor of pineal region: report of a case and review of literature. *Neurol India* 2010;58:928-32.
7. Wang Y, Zou L, Gao B. Intracranial germinoma: clinical and MRI findings in 56 patients. *Childs Nerv Syst* 2010;26:1773-77.
8. Kubik MJ, Saremian J. Primary cerebrospinal fluid diagnosis of pineal germinoma. *Diagnostic Cytopathology* 2015;43(6):644-649.
9. Saito R, Kumabe T, Kanamori M, et al. Early response to chemotherapy as an indicator for the management of germinoma-like tumors of the pineal and/or suprasellar regions. *Journal of Clinical Neuroscience* 2014;21:124-130.
10. Kamoshima Y, Sawamura Y. Update on current standard treatments in central nervous system germ cell tumors. *Curr Opin Neurol* 2010;23:571-5.
11. Acharya S, DeWees T, Shinohara ET, Perkins SM. Long-term outcomes and late effects for childhood and young adulthood intracranial germinomas. *Neuro-Oncology* 2015; 17(5): 741-746.
12. Calaminus G, Kortmann R, Worch J, et al. SIOP CNS GCT 96: final report of outcome of a prospective, multinational nonrandomized trial for children and adults with intracranial germinoma, comparing craniospinal irradiation alone with chemotherapy followed by focal primary site irradiation for patients with localized disease. *Neuro Oncol* 2013; 15(6): 788-796.
13. Alapetite C, Brisse H, Patte C, et al. Pattern of relapse and outcome of non-metastatic germinoma patients treated with chemotherapy and limited field radiation: the SFOP experience. *Neuro Oncol* 2010; 12(12): 1318-1325.
14. Campen CJ, Kranick SM, Kasner J, et al. Cranial irradiation increases risk of stroke in pediatric brain tumor survivors. *Stroke* 2012; 43(11): 3035-3040.

15. Valea A, Dumitru N, Buruiana A, Carsote M, Petrova E, Ghemigian A. Confirmation of congenital hypogonadotropic hypogonadism during the third decade of life: frame of co-morbidities and complications. *Arch Balk Med Union* 2016; 51(4): 546-550.
16. Carsote M, Chirita C, Dumitrascu A, et al. Pituitary incidentalomas - how often is too often? *J Med Life* 2009; 2(1):92.
17. Gheorghiu M, Hortopan D, Dumitrascu A, et al. Age-related endocrine tumors: non-functioning adrenal tumors as compared to pituitary adenomas. *Acta Endocrinologica (Bucharest)* 2009; 5(3): 371-383.
18. Gheorghisan-Galateanu AA, Carsote M, Valea A. Incidentaloma: from general practice to specific endocrine frame. *JPMA* 2017; 67(6): 917-922.
19. Draghici T, Negreanu L, Bratu OG, Pantea Stoian A, et al. Paraneoplastic syndromes in digestive tumors: a review. *Romanian Biotechnological Letters* 2018; 23(6):1-10.
20. Diaconu CC, Arsene D, Paraschiv B, Balaceanu A, Bartos D. Hyponatremic encephalopathy as the initial sign of neuroendocrine small cell carcinoma - case report. *Acta Endocrinologica* 2013;IX(4): 637-642.