

PATHOGENETIC FEATURES OF LIPID AND PROTEIN PEROXIDE OXIDATION DUE TO EXPERIMENTAL ACUTE NECROTIZING PANCREATITIS

Vitaliy V. MAKSYMUYUK¹, Michael I. SHEREMET^{1✉}, Volodimir V. TARABANCHUK¹, Olexandr V. SHIDLOVSKYI², Sergey P. BRODOVSKYI¹, Igor V. ZHULKEVYCH³, Yan V. GYRLA¹, Nina P. TKACHUK¹, Oleksandr V. BILOOKYI¹, Michael M. GRESKO¹, Marina D. GRESKO⁴, Oksana I. HOLIAR⁵

¹ Surgery Department No 1, Bukovinian State Medical University, Ukraine

² Surgery Department, I.Y. Horbachevsky State Medical University, Ukraine

³ Department of Oncology, Radiology and Therapy and Radiation Medicine, "Ivan Horbachevsky" Ternopil State Medical University, Ukraine

⁴ Department of Obstetrics and Gynecology with the Course of Infantile and Adolescent Gynecology, Bukovinian State Medical University Ukraine

⁵ Department of internal medicine and infectious diseases, Bukovinian State Medical University, Ukraine

Received 10 Apr 2019, Accepted 29 May 2019

<https://doi.org/10.31688/ABMU.2019.54.2.03>

ABSTRACT

The objective of the study was to research the dynamics of changes in oxidative and reducing systems in the blood and tissues of the pancreas, lungs and liver during the development of acute necrotizing pancreatitis.

Material and methods. The experiment involved 63 sexually-mature rabbits «Gray giant». The degree of oxidative modification of plasma proteins was assessed by the method of I.F. Meshchyschen. The content of malonic aldehyde in the erythrocytes was determined by the method of I. D. Stalna and T.G. Gorishvili. The content of ceruloplasmin in the serum was studied by M.I. Revina method. The level of medium mass molecules was determined by the method of N.I. Gabrielyan. The oxidative modification of proteins in the tissues of the

RÉSUMÉ

Caractéristiques pathogénétiques du développement de l'oxydation au peroxyde de lipides et de protéines en raison de la pancréatite nécrotique expérimentale aiguë

L'objectif de l'étude était d'étudier la dynamique des modifications des systèmes oxydatifs et réducteurs dans le sang et les tissus du pancréas, des poumons et du foie au cours du développement de la pancréatite nécrotique aiguë.

Materiel et méthodes. L'expérience a impliqué 63 lapins sexuellement matures «Gris géant». Le degré de modification oxydative des protéines plasmatiques a été évalué par la méthode de I.F. Meshchyschen. Le teneur en aldéhyde malonique dans les érythrocytes a été déterminée par la méthode de I. D. Stalna et T.G.

✉ Address for correspondence:

Michael I. SHEREMET
Surgery Department, Bukovinian State Medical University, Ukraine
Address: Golovna str. 191/16, Chernivtsi, Ukraine, 58018
E-mail: mihayl71@gmail.com; Phone +380956064607

pancreas, liver and lungs was carried out using the histochemical method and original techniques.

Results. The development of acute necrotic pancreatitis in the experiment was characterized by an increase in the activity of lipids and proteins in the blood and the oxidative modification of proteins in pancreaticocytes, hepatocytes and alveocytes, which is one of the leading mechanisms for their lesion. The growth of the oxidative modification of proteins in the endothelial cells of the pancreas, liver and lungs in the development of acute pancreatitis contributes to the occurrence of endothelial dysfunction, which is the leading factor in the secondary lesions of these organs.

Conclusions. Considering the important role of lipoperoxidation and oxidative modification of proteins in the mechanisms of progression of acute necrotic pancreatitis, it is pathogenetically grounded to develop new effective methods of systemic and local antioxidant and anti-proteolytic effects.

Keywords: acute necrotizing pancreatitis, peroxide oxidation of lipids and proteins.

Abbreviations: MMM – medium mass molecules; MA – malonic aldehyde; POM – protein oxidative modification; ANP – acute necrotizing pancreatitis; LPO – lipid peroxidation; CP – ceruloplasmin.

INTRODUCTION

Disorders in the redox equilibria in acute pancreatitis are known to be accompanied by peroxide reactions, transforming them from adaptation to damaging ones¹⁻³. In this case, the free radicals of oxygen are not only a direct damaging factor for pancreatic cysts and blood vessels endothelium, but also signaling molecules⁴⁻⁶. They trigger the synthesis of cellular adhesion molecules, cytokines and proapoptotic compounds, and also can activate pancreatic enzymes⁷⁻¹². It is accompanied by a deepening of necrotic lesions of the pancreas tissues and an increase in endotoxemia^{3,5,8,13-18}. However, the mechanisms for the development of such harmful reactions, especially in the tissues of pancreas and distant organs, require a more thorough study.

THE OBJECTIVE OF THE STUDY was to research the dynamics of changes in oxidative and reducing systems in the blood and tissues of the pancreas, lungs and liver during the development of acute necrotizing pancreatitis (ANP).

Gorishvili. La teneur en céruloplasmine dans le sérum a été étudiée par M.I. Méthode Revina. Le niveau de molécules de masse moyenne a été déterminé par la méthode de N.I. Gabrielyan. La modification oxydative des protéines dans les tissus du pancréas, du foie et des poumons a été réalisée en utilisant la méthode histochimique et les techniques originales.

Résultats. Le développement de la pancréatite nécrotique aiguë au cours de l'expérience est caractérisé par une augmentation de l'activité des lipides et des protéines dans le sang et par la modification oxydante des protéines dans les pancréatocytes, les hépatocytes et les alvéocytes, qui est l'un des principaux mécanismes de leur lésion. La croissance de la modification oxydative des protéines dans les cellules endothéliales du pancréas, du foie et des poumons lors du développement d'une pancréatite aiguë contribue à l'apparition d'un dysfonctionnement endothélial, qui est le principal facteur des lésions secondaires de ces organes.

Conclusions. Considérant le rôle important des processus de lipoperoxydation et de modification oxydante des protéines dans les mécanismes de progression de la pancréatite nécrotique aiguë, le développement de nouvelles méthodes efficaces aux effets antioxydants et anti-protéolytiques systémiques et locaux est bien fondé du point de vue pathogène.

Mots-clés: pancréatite aiguë nécrotique, oxydation au peroxyde de lipides et de protéines.

MATERIAL AND METHODS

The experimental research involved 63 sexually-mature rabbits «Gray giant», weighing from 8 to 10 kg, in which ANP was simulated by ligating the main pancreatic duct, followed by an injection of bile solution with trypsin into the pancreas parenchyma (utility model patent number 66667).

The degree of oxidative modification of plasma proteins was assessed by the I.F. Meshchyschen method¹⁹. The content of malonic aldehyde in the erythrocytes was determined by the I. D. Stalna and T.G. Gorishvili method²⁰. The content of ceruloplasmin [KF 1.16.3.1] in the serum was studied by the M.I. Revin method²¹. The level of medium mass molecules (MMM) was determined by the N.I. Gabrielyan method²¹.

In order to study the processes of protein oxidative modification (POM) in the tissues of the pancreas, liver and lungs, histochemical research was carried out using the I.S. Davydenko original techniques²².

The ratio of the activity of antioxidant defense (AOD) and lipid peroxidation (LPO) of the blood was carried out by determining the integral index (coefficient K) by the E.V. Chuyanova method²².

Table 1. Primary values in the activity of pro- and antioxidant systems of the experimental animals' blood.

Values	M	m
Malonic aldehyde (μmol/L)	13.620	0.267
Protein oxidative modification (o.u.g/mL)	2.08	0.06
Ceruloplasmin (mg/L)	206.357	4.312
Medium mass molecules (s.u.)	0.195	0.003

In conducting the research, we followed the generally accepted world and national standards for carrying out research in the field of biology and medicine, namely: Vancouver Convention on Biomedical Research (1979,1994) and other legislative acts in force in Ukraine.

RESULTS AND DISCUSSION

The primary parameters of the activity of oxidative and reducing systems of blood are shown in Table 1, and the coefficient R/B in the tissues of the organs of experimental animals in Table 2.

After 24 hours, there was a marked increase in the concentration of malonic aldehyde (MA) (Fig. 1) and ceruloplasmin (CP) (Fig. 2), while the levels of POM (Fig. 3) and MMM (Fig. 4) decreased moderately. The above changes were accompanied by a significant increase in the integral index of activity of LPO and AOD (Fig. 5). At the same time, the POM in both functional cells and the endothelium of the blood vessels of the pancreas (Fig. 6), the liver (Figure 7) and the lungs (Figure 8) increased significantly.

The above data prove that the initiation of AP in animals was accompanied by a characteristic

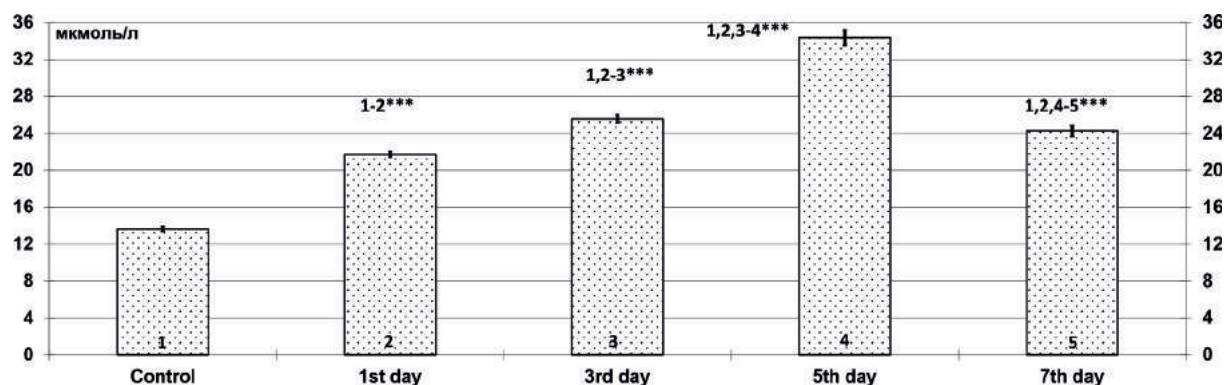
Table 2. Primary values of R/B index in the tissues of experimental animals.

Morphological substrate	M	m
Epithelial cells of the exocrine apparatus of the pancreas	0.98	0.012
Endothelial cells of the blood vessels of the pancreas	0.98	0.007
Hepatocytes	1.08	0.012
Endothelial cells of the blood vessels of the liver	0.99***	0.011
Epithelial cells of the respiratory system lung departments	0.94	0.007
Endothelial cells of the pulmonary blood vessels	0.97**	0.008

Note. ** – reliability index P between the functional and endothelial cells of the organs < 0.01, *** – < 0.001 (only statistically significant differences are given).

activation of LPO. The parallel growth of AOD activity is a logical process that prevents possible adverse effects of oxidative reactions. It is outlined by a significant increase in the K coefficient and a decrease in the POM activity and the level of MMM in the blood plasma, as well as the existence of a reverse significant correlation between the level of MA and CP (Table 3).

At the same time, the early growth of LPO, even alongside with a pronounced activation of AOD and domination of its integral value, stimulates intraacinar activation of pancreatic enzymes and the occurrence of local hypoxia. It is evidenced by a significant increase in the R/B ratio of epithelial cells of the exocrine apparatus (Figure 9) and endothelium of the blood vessels of the pancreas (Figure 6), as well as the existence of a close direct significant correlation between the increase in the level of MA and the activity of POM in pancreatic and endothelial cells of the pancreas (Table 3). Therefore, the intensification of

**Figure 1.** Dynamics of malonic aldehyde rate (μmol/L) in the blood plasma of experimental animals in the course of development of acute necrotizing pancreatitis

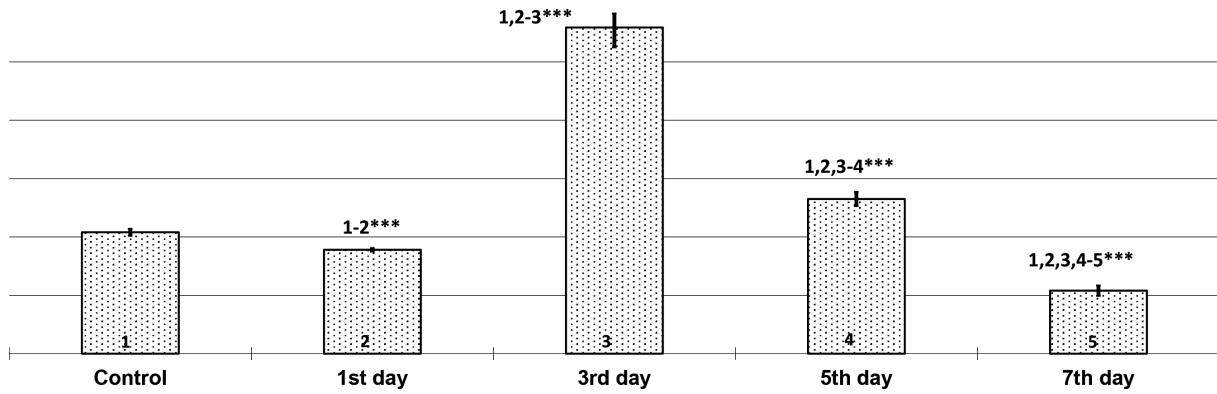


Figure 2. Dynamics of POM parameters (o.u. g/L) in the blood plasma of experimental animals in the course of development of acute necrotizing pancreatitis

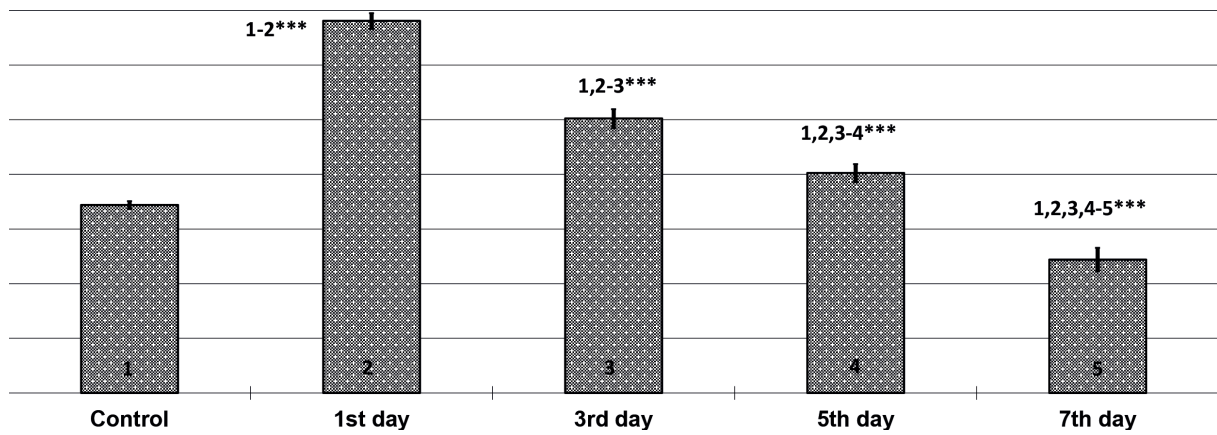


Figure 3. Dynamics of ceruloplasmin rate (mg/L) in the blood plasma of experimental animals in the course of the development of acute destructive pancreatitis

Note. *** – reliability index P between the indicated terms of observation < 0.001 (only statistically significant differences are shown).

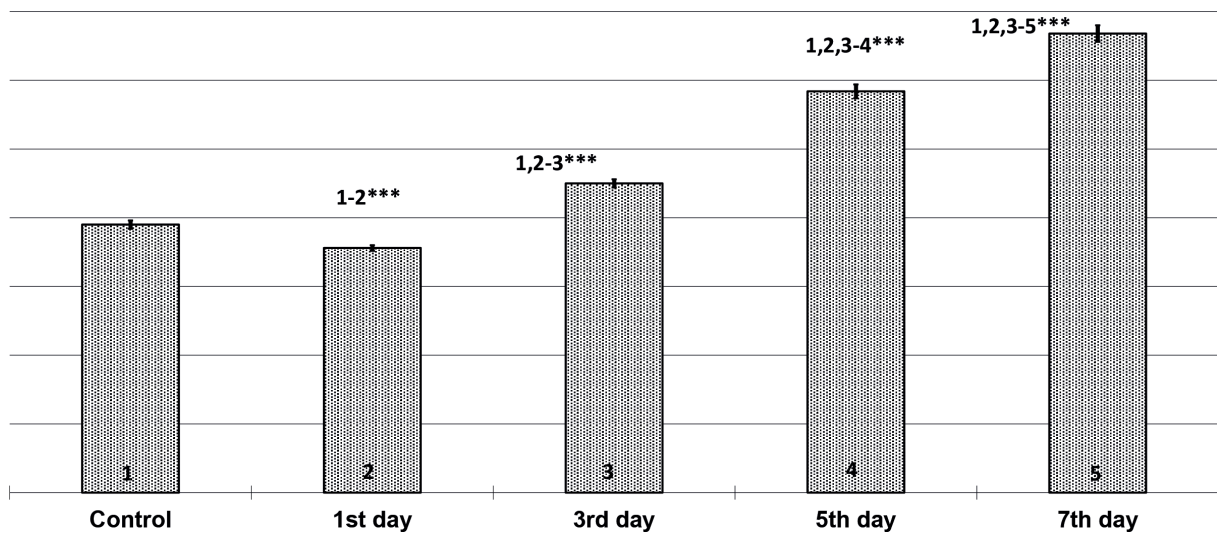


Figure 4. Dynamics of the medium mass molecules (s.u) rate in the blood plasma of experimental animals in the course of development of acute necrotizing pancreatitis

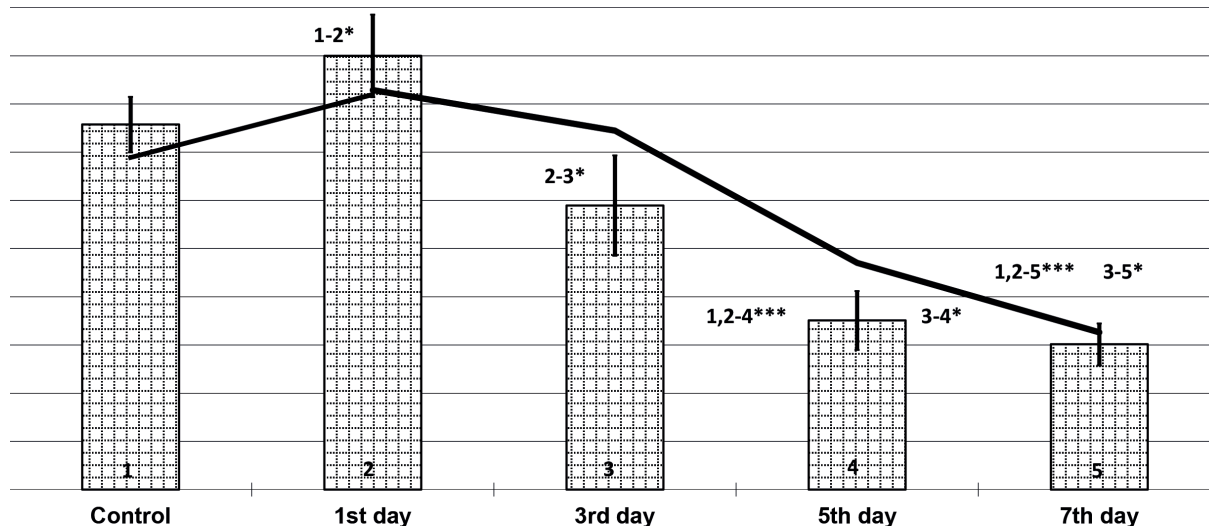


Figure 5. Dynamics of changes in the integral index of activity of lipid peroxidation systems and the blood antioxidant defense (K coefficient) in the development of acute necrotizing pancreatitis

Note. * – reliability index P between the indicated terms of observation < 0.05, *** – < 0.001 (only statistically significant differences are shown).

Table 3. Correlations of pro- and antioxidant systems of blood and tissues on the 1st, 3rd and 7th day of development of experimental acute necrotic pancreatitis.

Material under study	1 st day		3 rd day		7 th day		Material under study
	r	p	r	p	r	p	
MA	-0.48	<0.05	0.10	>0.05	0.21	>0.05	CP
MA	0.64	<0.05	0.50	<0.05	-0.13	>0.05	POM of pancreatocytes
MA	0.63	<0.05	0.10	>0.05	0.03	>0.05	POM of pancreatic endothelium
POM of the blood	0.58	<0.05	0.09	>0.05	0.52	<0.05	POM of pancreatocytes
MMM	0.64	<0.05	0.59	<0.05	0.70	<0.05	POM of pancreatocytes
POM of pancreatocytes	0.99	<0.01	0.87	<0.01	0.90	<0.01	POM of pancreatic endothelium
POM of pancreatocytes	0.57	<0.05	0.49	<0.05	0.33	>0.05	POM of hepatocytes
POM of pancreatocytes	0.86	<0.01	0.60	<0.05	0.59	<0.05	POM of alveocytes
POM of hepatocytes	0.52	<0.05	-0.02	>0.05	-0.48	<0.05	POM of alveocytes
POM of alveocytes	0.87	<0.01	0.12	>0.05	-0.02	>0.05	POM of pulmonary endothelium
POM of pancreatonecrosis areas	-	-	0.51	<0.05	0.49	<0.05	MMM
POM of pancreatonecrosis areas	-	-	0.73	<0.05	0.48	<0.05	POM of pancreatocytes
POM of pancreatonecrosis areas	-	-	0.63	<0.05	0.48	<0.05	POM of the pancreas endothelium
POM of pancreatonecrosis areas	-	-	0.55	<0.05	0.25	>0.05	POM of the liver endothelium
POM of pancreatonecrosis areas	-	-	0.61	<0.05	0.59	<0.05	POM of alveocytes
POM of pancreatonecrosis areas	-	-	0.43	>0.05	0.50	<0.05	POM of pulmonary endothelium

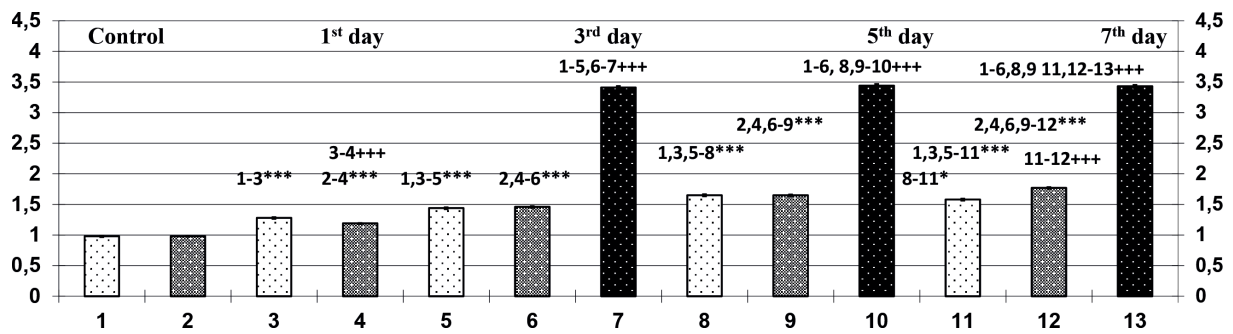


Figure 6. Dynamics of changes in the R/B ratio in the pancreatic tissues of experimental animals in the development of acute necrotizing pancreatitis

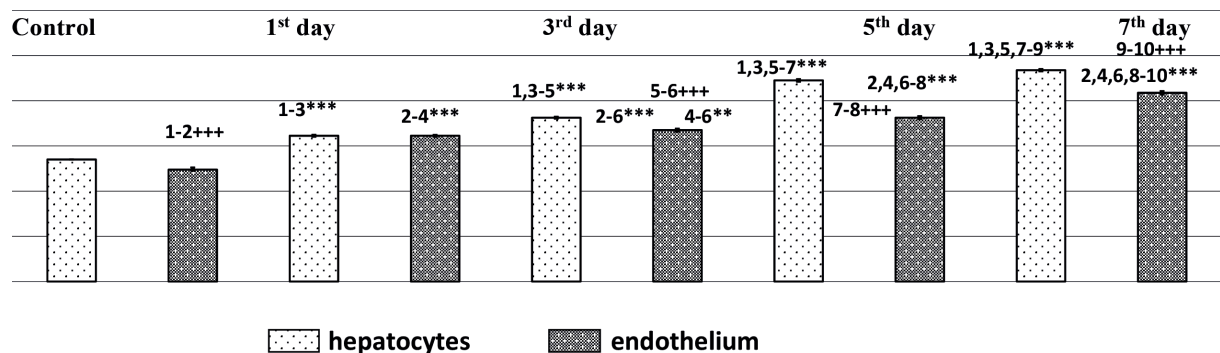


Figure 7. Dynamics of changes in R/B ratio in the liver tissues of experimental animals in the development of acute necrotizing pancreatitis

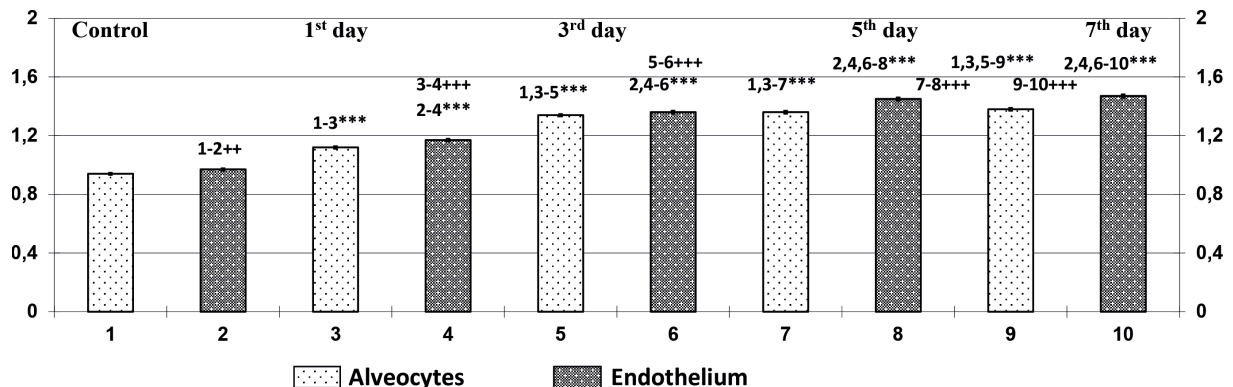


Figure 8. Dynamics of changes in R/B ratio in the lung tissues of experimental animals in the development of acute necrotizing pancreatitis

Note. * – reliability index P between the indicated terms of observation < 0.05; ** – < 0.01, *** – < 0.001; ++ – reliability index between the indicated tissues < 0.05; +++ – < 0.01; ++++ – < 0.001 (only statistically significant differences are shown).

LPO is not only a cause of changes in the lipid component of the membranes and contributing factor of the intraacinar activation of pancreatic enzymes, but also the leading trigger mechanism for activating POM, both in the blood and tissues^{10,23}. Oxidized proteins, in turn, are activators of numerous multicatalytic proteases, including the pancreatic ones^{11,24}. This allows us to consider the above-mentioned pathological mechanisms as factors contributing to the

progression of AP and affecting directly the nature of its further development.

It should be also noted that the increase in the activity of LPO in the plasma is accompanied by a significant elevation of POM hepatocytes (Fig. 10), alveocytes (Fig. 11), and endothelial cells of the liver (Figure 7) and lungs (Figure 8). In addition, all these changes are characterized by the presence of a number of direct significant correlation dependencies

(Table 3). It shows that the intensification of the LPO leads to the initiation of systemic reactions, which is based on the initiation of processes that are, factors in the development of hypoxia and dysfunction of distant organs, in particular the liver and the lungs.

From the 24th to 72nd hours of ANP development, there was a significant increase in the levels of MA, POM and MMM in the blood plasma, while the CP concentration was decreasing. At the same time, the reliable decrease of the integral index in the activity of the LPO processes showed the dominance of the prooxidant systems over the reserve capabilities of regenerative redox mechanisms. Besides, there was a progressive growth of the POM activity in pancreaticocytes (Figure 12), hepatocytes (Figure 14), alveocytes (Figure 15), as well as in endothelial cells of the pancreas (Fig. 6), liver (Fig. 7) and lungs (Fig. 8) vessels on the 3rd day. In addition, during histological examination in the tissues of the pancreas, there were reliable morphological signs of the formation of small centers of necrosis (Fig. 13), whose POM activity was significantly higher than in viable pancreaticocytes and endothelial cells of blood vessels (Fig. 6). At the same time, the changes in POM in tissues were interrelated, which was confirmed by the presence of many direct significant correlation dependencies (Table 3).

All of the above facts show that the maximum intensity of prooxidant reactions against the backdrop of the compensatory systems failure in case of ANP progression can be regarded as a manifestation of «oxygen explosion»²². A sharp activation of free radical transformation is associated with an increase in the content of reactive forms of oxygen, the main sources of which are stimulated phagocytes and endothelial cells^{10,25}. It is obvious that such uncontrolled excessive increase in the activity of prooxidant factors in blood and tissues leads to numerous negative consequences. Among them, along with changes in metabolism, circulation and immunity^{10,13}, it is worth noting the disturbance of the stability of cellular and subcellular membranes, which, besides the disorders of transmembrane transport, is one of the causes of necrotic lesions in the pancreatic parenchyma^{2,15}. The latter is reliably confirmed by the fact that the activity of POM in the centers of necrotic lesions in the pancreatic tissues on the 3rd day was 2.5 times more intense than in the viable pancreatic and endothelial cells, exceeding their initial indices by almost 3.5 times (see Fig. 3). In addition, these changes were characterized by close direct significant correlations (Table 3). All of the above make it possible to consider the sharp increase in POM activity in pancreatic parenchyma as one of the leading mechanisms of its necrotic lesion.

From the third to the seventh day of the development of ANP, there was a significant decrease in the

concentration of POM and CP in the blood plasma, below the baseline values, against the background of a pronounced tendency to decrease the level of MA, which, however, was higher than that of the control. At the same time, the level of MMM continued to grow progressively, and the integral index of pancreatic activity was characterized by an even more pronounced tendency to predominance of prooxidant factors. In addition, there was a significant increase in the activity of POM in functional and endothelial cells of all organs, which was accompanied by the appearance of a common necrotic lesions of pancreatic parenchyma (Fig. 16) and the development of degenerative processes in the liver (Fig. 17) and lungs (Fig. 18). In this case, there was a direct significant correlation between the growth of POM activity in the pancreatic functional and endothelial cells, those of the liver and lungs (Table 3).

Such changes indicate that, in addition to the growth of POM in pancreaticocytes, alveocytes and hepatocytes, the growth of POM in their endothelial cells is another mechanism of lesions in the pancreas, liver and lungs. The latter, in our opinion, contributes to the emergence of endothelial dysfunction, which is the leading factor in secondary lesions of the pancreas, liver and lungs.

It should be also emphasized that, despite the expressed suppression of redox-blood reactions, the activity of POM in the tissues of all organs was characterized by a continuously progressive growth. At the same time, such changes were accompanied by the appearance of reliable morphological manifestations of common pancreatic necrosis and the development of degenerative processes in the liver and lungs. This shows that the necrotic lesions of the pancreas and the development of dysfunction/ insufficiency of distant organs correlate with the activity of POM and the severity of endogenous intoxication syndrome. The reliability of the latter was further confirmed by a set of direct significant correlations between these changes (Table 3).

Particular attention should be also drawn to the fact that in the early stages of development of acute pancreatitis, the activity of LPO directly significantly correlates with POM in pancreaticocytes and endothelial cells of the pancreas, while such a connection can not be traced in case of the initial development of necrotic lesions of pancreatic parenchyma and its subsequent progression. The above is likely to indicate that the rapid growth of the activity of the PO processes initiates the processes of POM in the pancreatic tissues, which causes triggering the local alteration mechanism. Further development of the latter is potentiated by its own non-oxidant factors and is characterized by universality, which implies

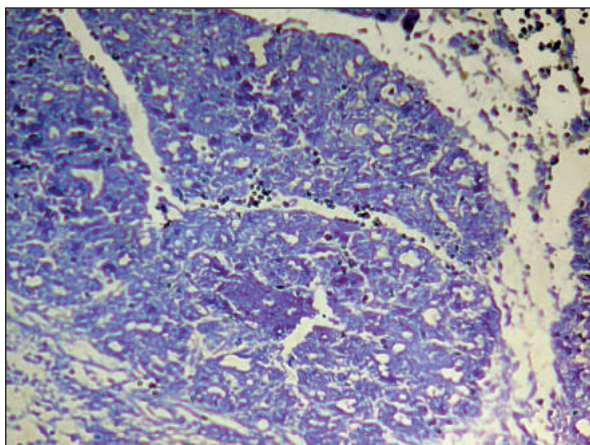


Figure 9. Microphotography of the pancreas area in a rabbit after 24 hours of simulating acute pancreatitis. Coefficient R/B: cells of the exocrine apparatus – 1.268, endothelium of blood vessels – 1.188. Coloring with bromophenol blue by Mikel Calvo. Ob. 40^x, Ok. 10^x.

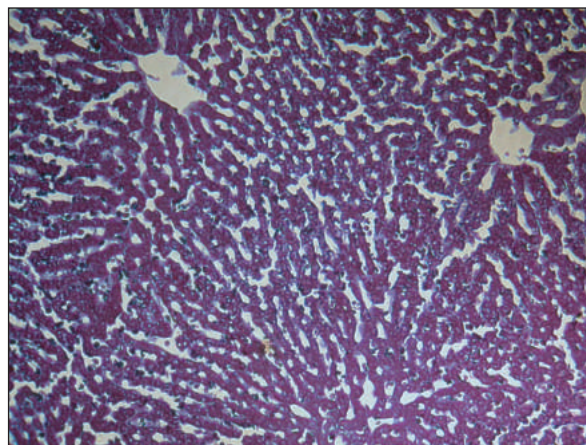


Figure 10. Microphotography of the liver area in a rabbit after 24 hours of simulating acute pancreatitis. Coefficient R/B: hepatocytes – 1.287, endothelium of blood vessels – 1.281. Coloring with bromophenol blue by Mikel Calvo. Ob. 40^x, Ok. 10^x.

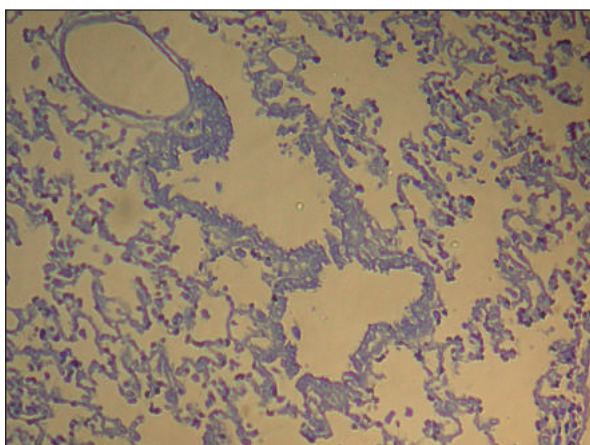


Figure 11. Microphotography of the lungs area in a rabbit after 24 hours of simulating acute pancreatitis. Coefficient R/B: epithelium of the respiratory parts of the lungs – 1.268, endothelium of blood vessels – 1.188. Coloring with bromophenol blue by Mikel Calvo. Ob. 40^x, Ok. 10^x.

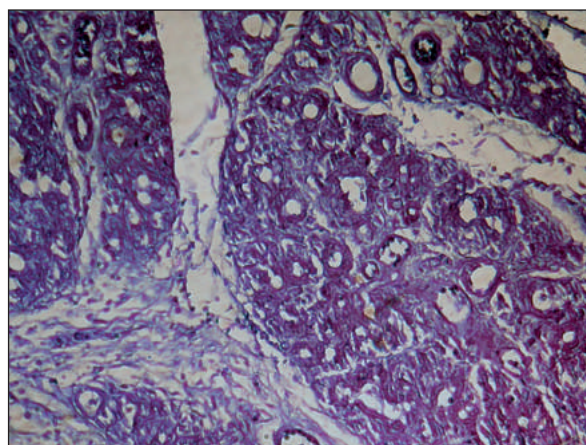


Figure 12. Microphotography of the pancreas area in a rabbit after 72 hours of simulating acute pancreatitis. Coefficient R/B: cells of the exocrine apparatus – 1.431, endothelium of blood vessels – 1.455. Coloring with bromophenol blue by Mikel Calvo. Ob. 40^x, Ok. 10^x.

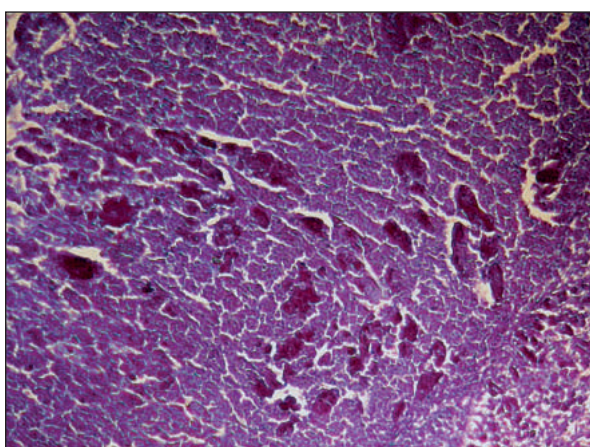


Figure 13. Microphotography of the pancreas area in a rabbit after 72 hours of simulating acute pancreatitis. Coefficient R/B of piecemeal necrosis areas – 3.428. Coloring with bromophenol blue by Mikel Calvo. Ob. 40^x, Ok. 10^x.

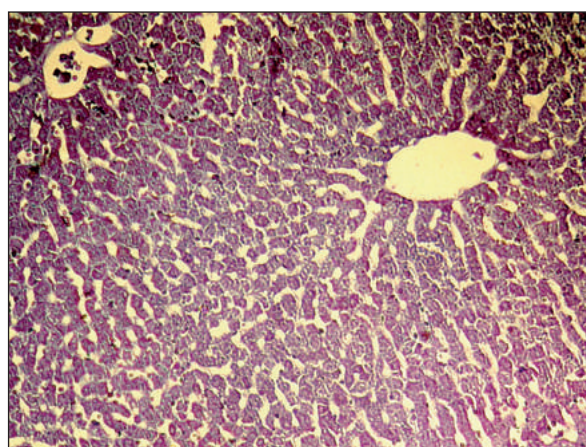


Figure 14. Microphotography of the liver area in a rabbit after 72 hours of simulating acute pancreatitis. Coefficient R/B: hepatocytes – 1.455, endothelium of blood vessels – 1.337. Coloring with bromophenol blue by Mikel Calvo. Ob. 40^x, Ok. 10^x.

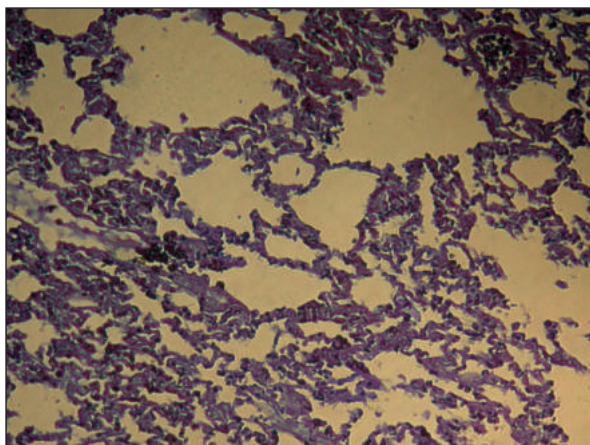


Figure 15. Microphotography of the lungs area in a rabbit after 72 hours of simulating acute pancreatitis. Coefficient R/B: epithelium of the respiratory parts of the lungs – 1.341, endothelium of blood vessels – 1.364. Coloring with bromophenol blue by Mikel Calvo. Ob. 40^x, Ok. 10^x.

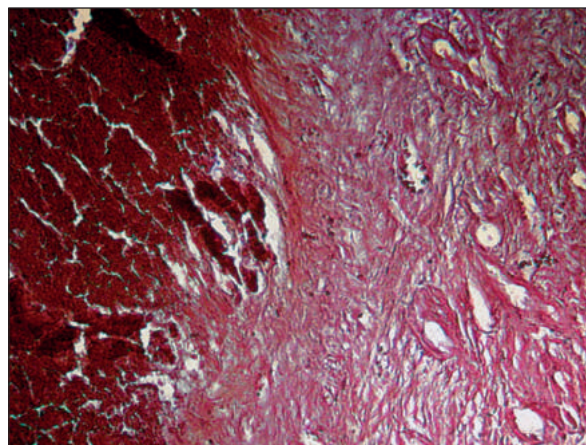


Figure 16. Microphotography of the pancreas area in a rabbit after 7 days of simulating acute pancreatitis. Coefficient R/B of diffuse necrosis area – 3.452. Coloring with bromophenol blue by Mikel Calvo. Ob. 40^x, Ok. 10^x.

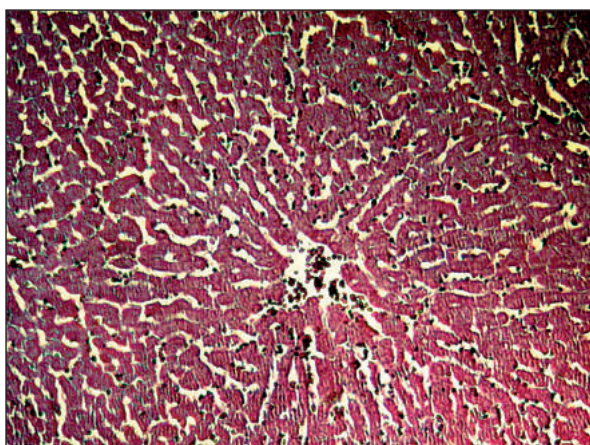


Figure 17. Microphotography of the liver area in a rabbit after 7 days of simulating acute pancreatitis. Coefficient R/B: hepatocytes – 1.883, endothelium of blood vessels – 1.679. Coloring with bromophenol blue by Mikel Calvo. Ob. 40^x, Ok. 10^x.

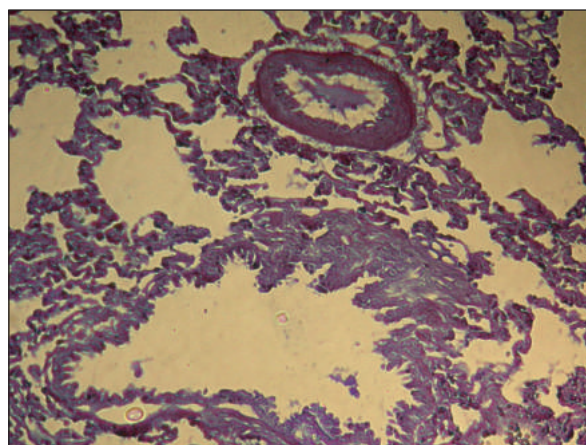


Figure 18. Microphotography of the lungs area in a rabbit after 7 days of simulating acute pancreatitis. Coefficient R/B: epithelium of the respiratory parts of the lungs – 1.385, endothelium of blood vessels – 1.481. Coloring with bromophenol blue by Mikel Calvo. Ob. 40^x, Ok. 10^x.

an accelerating effect on both the parenchyma of the pancreas and tissues of distant organs^{26,27}. The mechanism of alteration of the POM growth in tissues may mean that intracellular growth of POM is a possible indication of the activation of ubiquitin-dependent proteolysis, which may be non-protective (regulation of the rate of transcription and cell cycle, apoptosis, proliferation, differentiation and repair, the immune system) in nonphysiological conditions^{23,28,29}, but, on the contrary, it can be damaging^{22,30}.

CONCLUSIONS

The development of acute necrotizing pancreatitis in the experiment is characterized by an increase in the activity of processes of lipids and proteins in

the blood and oxidation modification of proteins in pancreaticocytes, hepatocytes and alveocytes, which is one of the leading mechanisms of their lesion. The growth of the oxidative modification of proteins in endothelial cells of the pancreas, liver and lungs during the development of acute pancreatitis contributes to the occurrence of endothelial dysfunction, which is the leading factor in the secondary lesions of these organs³¹. Considering the important role of processes of lipoperoxidation and oxidative modification of proteins in the mechanisms of the progression of acute necrotic pancreatitis, the development of new effective methods of systemic and local antioxidant and anti proteolytic effects is pathogenically grounded.

Compliance with Ethics Requirements:

„The authors declare no conflict of interest regarding this article“

„The authors declare that all the procedures and experiments of this study respect the ethical standards in the Helsinki Declaration of 1975, as revised in 2008(5), as well as the national law.“

„All institutional and national guidelines for the care and use of laboratory animals were followed“

„No funding for this study“

REFERENCES

1. Wang GJ, Gao CF, Wei D, Wang C, Ding SQ. Acute pancreatitis: etiology and common pathogenesis. *World J Gastroenterol* 2009;15(12):1427-1430.
2. Lowenfels AB, Maisonneuve P, Sullivan T. The changing character of acute pancreatitis: epidemiology, etiology, and prognosis. *Curr Gastroenterol Rep* 2009;11(2):97-103.
3. Kavutharapu S, Nagalla B, Abbagani V, et al. Role of proteases and antiprotease in the etiology of chronic pancreatitis. *Saudi J Gastroenterol*. 2012;18(6):364-8.
4. Mazzini GS, Jost DT, Ramos DB, et al. High phosphate serum levels correlate with the severity of experimental severe acute pancreatitis: insight into the purinergic system. *Pancreas*. 2015;44(4): 619-625.
5. Dawra R, Sah RP, Dudeja V, et al. Intra-acinar trypsinogen activation mediates early stages of pancreatic injury but not inflammation in mice with acute pancreatitis. *Gastroenterology*. 2011;141(6): 2210-2217.
6. Fong CS, Wu RM, Shieh JC, et al. Pesticide exposure on southwestern Taiwanese with MnSOD and NQO1 polymorphisms is associated with increased risk of Parkinson's disease. *Clin Chim Acta*. 2007;378(1-2):136-141.
7. Chen JM, Férec C. Genetics and pathogenesis of chronic pancreatitis: The 2012 update. *Clin Res Hepatol Gastroenterol* 2012;36(4):334-40.
8. Ji B, Gaiser S, Chen X, Ernst SA, Logsdon CD. Intracellular trypsin induces pancreatic acinar cell death but not NF- κ B activation. *J Biol Chem*. 2009;284(26):17488-17498.
9. Masami N, Rimeï N, Takashi S, et al. Genetic association of glutathione peroxidase-1 with coronary artery calcification in type 2 diabetes: a case control study with multi-slice computed tomography. *Cardiovascular Diabetology*. 2007;6:23.
10. Leopold JA, Loscalzo J. Oxidative risk for atherothrombotic cardiovascular disease. *Free Radic Biol Med*. 2009;47(12):1673-1706.
11. Arun KT, Prasad PF, Thelma BK, et al. Oxidative stress pathway genes and chronic renal insufficiency in Asian Indians with type 2 diabetes. *J Diabetes Complications*. 2009; 23:104.
12. Testoni PA. Acute recurrent pancreatitis: etiopathogenesis, diagnosis and treatment. *World J Gastroenterol*. 2014;20(45):16891-16901.
13. Akinosoglou K, Gogos C. Immune-modulating therapy in acute pancreatitis: fact or fiction. *World J Gastroenterol*. 2014;20(41):15200-15.
14. Singh, VK, Wu BU, Bollen TL, et al. A prospective evaluation of the bedside index for severity in acute pancreatitis score in assessing mortality and intermediate markers of severity in acute pancreatitis. *Am J Gastroenterol*. 2009;104(4):966-971.
15. Sabo A, Goussous N, Sardana N, et al. Necrotizing pancreatitis: a review of multi-disciplinary management. *JOP*. 2015;16(2):125-135.
16. Bonfrate L, Wang DQ, Garruti G, Portincasa P. Obesity and the risk and prognosis of gallstone disease and pancreatitis. *Best Pract Res Clin Gastroenterol*. 2014;28(4):623-635.
17. Gomatos IP, Xiaodong X, Ghaneh P, et al. Prognostic markers in acute pancreatitis. *Expert Rev Mol Diagn*. 2014;14(3):333-346.
18. Peng YS, Chen YC, Tian YC, et al. Serum levels of apolipoprotein A-I and high-density lipoprotein can predict organ failure in acute pancreatitis. *Critical Care*. 2015;19: 88.
19. Hyrla YV, Polyanskyi IYu, Sheremet MI. The parameters of the blood plasma optical density as criteria of diagnostics of thyrotoxicosis' severity grades. *Arch Balk Med Union*. 2013;48(3):68.
20. Greenchuk FV, Guminestskij SG. New method of diagnostics of abdominal acute surgical pathology. *Arta Medica*. 2007;4 (25):201.
21. Polianskiy IYu, Grynchuk FV. Particularities of the diagnostic and treatment of perforative gastroduodenal ulcers at patients with concomitant pathology. *Arta Medica*. 2007;4(25):199 - 200.
22. Maksymyuk V, Polyansky I, Tarabanchuk V, Hrynchuk F, Davidenko I. Specific changes of cytokine status throughout the processing of acute necrotic pancreatitis in experiment. *Bulletin of the Academy of Sciences of Moldova*. 2014;44(3):22-25.
23. Sheremet MI, Sydorchuk LP, Shidlovskiy VO, et al. Caspase-dependent mechanisms and antioxidant defense in the thyroid tissue of patients with nodular goiter with autoimmune thyroiditis and thyroid adenoma according to allelic status of BCL-2 (rs17759659), CTLA-4 (rs231775), APO-1/ FAS (rs2234767) genes. *Arch Balk Med Union*. 2017;52(3):254-62.
24. Maksymyuk VV, Ivanchuk MA, Sheremet MI, et al. Prognosis markers in acute pancreatitis. *Arch Balk Med Union*. 2017;52(3):263-271.
25. Maksymyuk VV, Polyansky IYu, Tarabanchuk VV. Assessment of changes in plasma optical density of venous blood in acute edematous pancreatitis. *Arch Balk Med Union*. 2012:101-103.
26. Diaconu C, Balaceanu A, Morosan E. Sepsis biomarkers: past, present and future. *Farmacologia* 2015;63(6):811-815.
27. Socea B, Nica AA, Bratu O, et al. Incidental finding of a sigmoid intussusception associated with rectal prolapse - a case report. *Arch Balk Med Union* 2018;53(1):143-146.
28. Tanaka K. The proteasome: overview of structure and functions. *Proc Jpn Acad Ser B Phys Biol Sci*. 2009;85:12-36.
29. Inobe T, Fishbain S, Prakash S, Matouschek A. Defining the geometry of the two-component proteasome degron. *Nature Chemical Biology*. 2011;7(3):161-167.
30. Uitte de Willige S, Miedzak M, Carter A, et al. Proteolytic and genetic variation of the alpha-2-antiplasmin C-terminus in myocardial infarction. *Blood*. 2011;117(24):6694-6701.
31. Draghici T, Negreanu L, Bratu O, et al. Liver abnormalities in patients with heart failure. *Arch Balk Med Union* 2018;53(1):76-81.