

Histochemical characterization of Mucosubstances in the intestine of Fish, *Channa gachua* (F. Hamilton) exposed to lethal concentration of Dichlorvos

Kadam PL* and Patil RN

P.G. Department of Zoology, Sadguru Gadage Maharaj College, Karad, MS. India. 415124.

*Corresponding author Email- gayatrikadam7@gmail.com

Manuscript details:

Available online on
<http://www.ijlsci.in>

ISSN: 2320-964X (Online)
ISSN: 2320-7817 (Print)

Editor: Dr. Arvind Chavhan

Cite this article as:

Kadam PL and Patil RN (2018) Histochemical characterization of Mucosubstances in the intestine of Fish, *Channa gachua* (F. Hamilton) exposed to lethal concentration of Dichlorvos, *Int. J. of Life Sciences*, Special Issue, A10: 153-158.

Copyright: © Author, This is an open access article under the terms of the Creative Commons Attribution-Non-Commercial - No Derives License, which permits use and distribution in any medium, provided the original work is properly cited, the use is non-commercial and no modifications or adaptations are made.

ABSTRACT

Direct discharge from agricultural runoff and industrial effluent in to river, ponds and lakes causing serious environmental pollution. These runoff and effluent contain toxicant which exerts their effect on aquatic animals particularly fish by interfering their physiological processes. Therefore, present work was aimed to study the histochemical characterization of mucosubstances in intestine of fresh water fish, *Channa gachua* after acute exposure to organophosphate pesticide dichlorvos. There was decrease in the secretion of neutral mucosubstances by the epithelial cells in exposed fishes. On the other hand secretion of neutral mucosubstances by G1- Goblet cells was decreased. In G2- goblet cells secretion of sulfomucins was enhanced but the secretion of neutral mucosubstances and sulfomucins was decreased in G3- Goblet cells. In submucosa, muscularis and serosa the neutral mucosubstances was decreased as well as the glycogen was also decreased in muscularis. From these results it is concluded that the pesticide exerts their effects in organ system of fish and decreases their food values.

Key words: mucosubstances, intestine, goblets cells, dichlorvos.

INTRODUCTION

Revolution in Agriculture, science and technology coupled with population explosion and progressive urbanization has been led to introducing numerous harmful chemicals in the environment. India is over populated country with high growth rate, the people mainly depend on agricultural products to overcome their basic need of food. But different types of insect pests reduce the agricultural production. So the farmers use biological weapon i.e. pesticides to control insect pests and for high crop yield. As the pesticides effects on insects pests they also exerts their effects on non-target organism in similar manner. These pesticides come in water resources through agricultural runoff, leaching and air. Among the various animal groups, fishes have been identified as very sensitive to pollutants and have been the most popular test organism because they are presumed to be the best understood organism in the aquatic environment.

Fishes are one of the most important members of the aquatic food chain, and through them some toxicants may reach human beings as well (Gopalkrishnan, 1990). Dichlorvos is highly potent organophosphate pesticide that used to control pests on vegetable crops, sugarcane, soyabean, groundnut, wheat, rice, etc. It is effective against mushroom flies, aphids, spider, mites, caterpillars, thrips and whiteflies in greenhouse, and vegetable crops. As the tremendous use of this pesticide the evidences of pollution may be increases and health of non-target organism at high risk.

Histochemical studies helps in assessing the location and quantity of biochemical constituents as well as molecular changes at cellular level (Pathan et al., 2009). The intensity of the staining might be used to compare the amount of mucosubstances and biochemical moieties like, glycogen, protein and lipid. An insight into the existing literature revealed that very scanty information is available on the nature of muco substances present in the various histological sites of the intestine. There are limited reports by some earlier researchers, who contributed little information about the nature of mucosubstances in the intestine of few fishes, Oliveira-Ribeiro and Fanta (2000) in *Trichomycterus brasiliensis*, Cinar and Senol (2006) in flower fish, *Pseudophoxinus antalyea*, Kozaric et al. (2007) in *Thunnusthyunnus*, Rajiand Norouzi (2010) in *Claris batrachus* and *Serrasalmus nattereri*, Senol (2014) in *Scardinius erythrophtholmus*, Santos et al. (2015) in *Trachelyopterus striatulus*. Therefore, present research work has been undertaken to augment the information regarding the histochemistry of muco substances in these histological sites in intestine of fish *C. gachua*.

METHODOLOGY

1) Selection of fish

In the present work the fresh water fish, *C.gachua* was selected keeping in mind their availability in local river Krishna around Karad city and its suitability for toxicity testing. Healthy specimens of size 15 ± 1 cms and weight 50 ± 5 gms. were collected from the river with the help of a fisherman. The collected fish were brought to the laboratory, they were treated with 0.1% KMnO₄ solution to prevent dermal infection and acclimatized to the laboratory condition for a period of 10 days. During this period, they were fed once a day on pelleted fish feed and were kept in aerated aquarium. After 10 days fish with normal behavioral activity and good health

condition were selected for further experimental purpose.

2) Pesticide

Commercially available organophosphorus pesticide, dichlorvos brought from local Agro-chemist shop was used for present research work.

Experimental set up- Under the experiment healthy fishes were divided in to three groups each group contained ten fishes. Group 1st was considered as control and group 2nd and 3rd as experimental groups. Fishes in the experimental groups were exposed to LC0 (5 ppm) and LC50 (12.5 ppm) conc. of pesticide for 96 hrs. in acute toxicity study.

Histochemical method:

Well established and recommended histochemical techniques for characterization of mucosubstances was used.

RESULTS

The histochemical reactivities of mucosubstances in the various histological sites such as mucosa (Epithelial cells and goblet cells), submucosa muscularis and serosa in the intestine of control fish are illustrated photomicrographically in Figs. 1-20.

A) Control fish:

Epithelial cells: These cells lining exhibited poor PAS reactivity (Figs. 1) which was completely blocked by prior phenylhydrazine treatment (Figs. 2) whereas the PAS reactivity was not altered after diastase digestion(Figs. 3) in these cells. These initial histochemical observations in these cells thus indicated the presence of only neutral mucosubstances but the absence of any acidic mucosubstances and glycogen. The absence of acidic mucosubstances was further confirmed by negative staining in these cells with AB pH 1.0 (Figs. 4), AB pH 2.5 (Figs. 5), C.I. and AF (Figs. 8). Thus, histochemical observations revealed the presence of only neutral mucosubstances (poor), but absence of any type of acidic mucosubstances and glycogen.

Goblet cells: These cells were found distributed in between the epithelial cells. On the basis of histochemical staining reactivities these cells divided into 3 types.

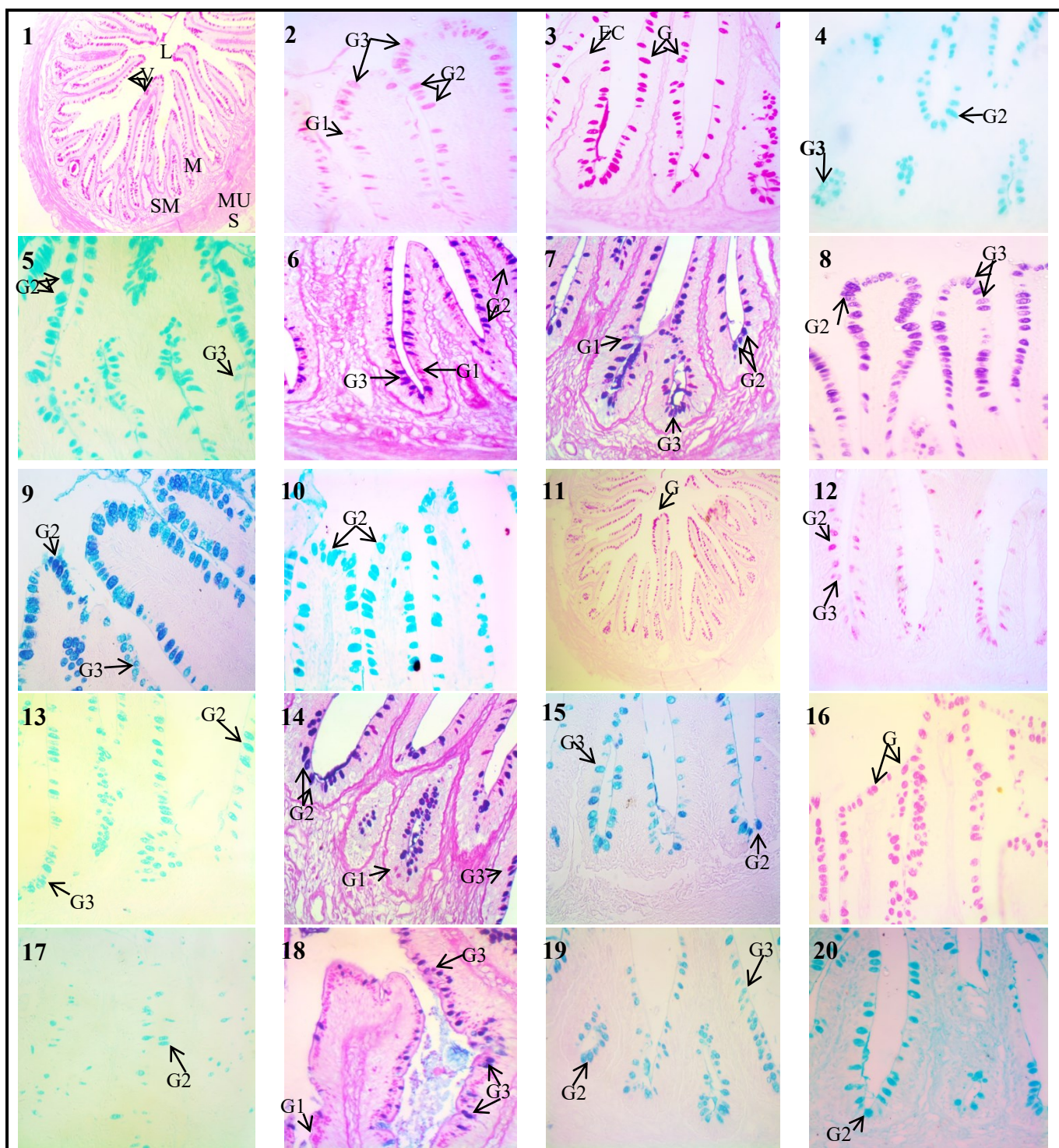


Fig.1. T.S. of intestine in control fish. PAS (100X), **Fig.2.**T.S. of intestine in control fish. P-PAS (400X), **Fig.3.** T.S. of intestine in control fish.D-PAS (400X).**Fig.4.** T.S. of intestine in control fish. AB pH 1.0 (400X), **Fig.5.** T.S. of intestine in control fish. AB pH 2.5 (400X), **Fig.6.** T.S. of intestine in control fish. AB pH 1.0 - PAS (400X), **Fig.7.** T.S. of intestine in control fish.AB pH 2.5-PAS (400X), **Fig.8.**T.S. of intestine in control fish. AF (400X), **Fig.9.** T.S. of intestine in control fish.AF-AB pH2.5 (400X), **Fig.10.**T.S. of intestine in control fish. Pepsin-AB pH 2.5(400X), **Fig.11.** T.S. of intestine in fish exposed to 5 ppm. PAS (100X), **Fig.12.** T.S. of intestine in fish exposed to 5 ppm. P-PAS (400X), **Fig.13.** T.S. of intestine in fish exposed to 5 ppm. AB pH 2.5 (400X),**Fig.14.** T.S. of intestine in fish exposed to 5 ppm. AB pH 2.5-PAS (400X), **Fig.15.** T.S. of intestine in fish exposed to 5 ppm. AF-AB pH2.5 (400X), **Fig.16.** T.S. of intestine in fish exposed to 12.5 ppm. PAS (400X), **Fig.17.** T.S. of intestine in fish exposed to 12.5 ppm. AB pH 2.5 (400X),**Fig.18.** T.S. of intestine in fish exposed to 12.5 ppm. AB pH 2.5-PAS (400X), **Fig.19.** T.S. of intestine in fish exposed to 12.5 ppm. AF-AB pH 2.5 (400X), **Fig.20.** T.S. of intestine in control fish.Pepsin-AB pH2.5 (400X).M- Mucosa, SM- Submucosa, MU- Muscularis, S- Serosa, EC- Epithelial cells, L- Lumen, G- Goblet cell, G1- Goblet cell type 1, G2- Goblet cell type 2, G3- Goblet cell type 3.

i. G1 (Goblet cells -Type I)

These cells showed moderate PAS reactivity which remained unaffected by diastase digestion but could completely be blocked by phenylhydrazine pretreatment (Figs. 2). These initial observations revealed the absence of glycogen but presence of only neutral mucosubstances in these cells. The absence of any alcianophilia in these cells with AB pH 1.0 (Fig. 4), AB pH 2.5 (Fig. 5), C.I. and AF indicated the absence of any acidic mucosubstances. Thus G1 type of goblet cells in the intestine of control fish elaborated only the neutral mucosubstances (moderate).

ii. G2 (Goblet cells -Type II)

These cells reacted intensely towards periodic acid Schiff staining technique and the reactivity was resistant to phenylhydrazine treatment and diastase digestion. These initial results revealed the absence of neutral mucosubstances and glycogen. Furthermore, the alcianophilia (moderate) was observed in these cells at AB pH 1.0 which enhanced slightly at AB pH 2.5 and C.I. reactivity. These histochemical reactivities indicated the presence of both sulfomucins and carboxymucins in these cells. The presence of sulfomucins confirmed by AF and AF-AB pH 2.5 (Fig.9) sequential staining techniques. Presence of carboxymucins at this site was also confirmed by blue-purple staining with AF-AB pH 2.5. Acid hydrolysis and sialidase digestion technique resulted in to reduction in the alcianophilia than at AB pH 2.5 indicated that these carboxymucins were sialomucins. Thus, these cells elaborated sulfomucins (predominant) and sialomucins (poor).

iii. G3 (Goblet cells -Type III)

These cells reacted intensely towards PAS and the reactivity was not blocked by diastase digestion however, it was reduced by phenylhydrazine treatment. These histochemical observations indicated the absence of glycogen but possible presence of neutral mucosubstances and acidic mucosubstances. These cells revealed alcianophilia (weak) with AB pH 1.0 which was of the same grade at AB pH 2.5 and at C.I. technique indicated the presence of only sulfomucins (weak) as acidic mucosubstances and absence of any carboxymucins. Presence of only sulfomucins in these cells was confirmed by AB pH 1.0-PAS (Fig.6), AF and AF-AB pH 2.5 (Fig.7) combined histochemical procedures. From these histochemical reactions it was concluded that the G3 goblet cells elaborated both neutral mucins and sulfomucins in equal (weak) amount.

Submucosa and Serosa

The histochemical staining reactivities of mucosubstances in submucosa were practically identical to those described in the epithelial cells of mucosa of this organ. Therefore, it was concluded that the submucosa in the intestine of control fish contained only the neutral mucosubstances in poor amount.

Muscularis

This layer exhibited poor to weak staining reactivity with PAS staining which was completely abolished after phenylhydrazine treatment indicated the presence of only neutral mucins but absence of any acidic mucosubstances. The PAS intensity was partially diminished by diastase digestion that indicated the presence of glycogen.

B. Fishes exposed to dichlorvos

a) LC 0 (5 ppm) Concentration-

The histochemical reactivities in the intestine of fish exposed to this concentration of dichlorvos are illustrated in microphotographs (Figs.11-15). The histochemical results obtained in epithelial cells showed only trace amount of neutral mucosubstances. G1 Goblete cells in the intestine of this fish, elaborated only weak amount of neutral mucosubstances, G2 Goblet cell also elaborated weak amount of sulfomucins and poor amount of sialomucins and G3 Goblet cells contained mixture of both neutral mucosubstances (weak) and sulfomucins (poor). Submucosa, muscularis and serosa in the intestine of fish exposed to 5 ppm of dichlorvos were contained poor amount neutral mucosubstances.

b) LC50 (12.5 ppm) concentration

The histochemical staining reactivities revealed (Figs. 16-20) trace amount of neutral mucosubstances in the epithelial cells but no glycogen. However G1 Goblet cells in this fish contained moderate amount of neutral mucosubstances, G2 Goblet cells contained moderate amount of sulfomucins and G3 Goblet cells contained the mixture of neutral mucosubstances (poor to weak) and sulfomucins (poor). Submucosa, muscularis and serosa in the intestine of fish exposed to 12.5 ppm of dichlorvos were contained only the neutral mucosubstances in trace amount.

DISCUSSION

The intestine plays a very important role in body of fish and it performs several functions such as complete digestion of food and absorption of important nutrients. The toxicants directly enter into the intestine along with contaminated food material while indirect entry of the toxicant may be along with the bile containing pesticide and their metabolites released from liver (Khan, 1976). The wall of intestine of different teleost fishes consist of common four layers; the mucosa, submucosa, muscularis and serosa. In the present study, the fish *C. gachua* also showed presence of all the four layers. The food material remains for longer period in intestine so the toxicants exert their effects on the intestinal wall and altered the physiological functions.

Mucous cells are predominantly present in the intestinal region of teleosts and main source of mucin. Mucin is a very high molecular weight carbohydrate rich protein substance secreted by the mucous cells or goblet cells (Kapoor, 1953; Mehrotra and Khanna 1969; Sinha and Moitra 1974; Gona, 1979; Moitra and Roy, 1979). Mucus performing different functions like transportation, absorption of ingested material and finally defecation of undigested food materials through rectum in intestine (Sarkar and Ghosh, 2010). In present investigation, the epithelial cells of control fish contained only neutral mucosubstances and glycogen in poor amount. Whereas G1 Goblet cells contained moderate amount of neutral mucosubstances, G2 Goblet cells contained poor amount of sulfomucins and sialomucins and G3 Goblet cells contained the mixture of neutral mucins and sulfomucins in weak amount. Submucosa and serosa also contained only the neutral mucosubstances in poor amount whereas muscularis contained poor amount of neutral mucosubstances and glycogen. Similar observations were reported by Cinar and Senol (2006) they reported the goblet cells containing periodic acid Schiff's reagent and Alcian blue positive mucosubstances in fish, *Pseudophoxinus antalyea*, by Channa and Mir (2007) in the intestinal tract of fish, *Schizothorax curvifrons*, by Raji and Norouzi (2010) in the intestine of walking catfish, *Clarias batrachus* and piranha *Serrasalmus nattereri*.

Toxicants in general alter the number, size and secretion of mucous cells in the intestine of fishes. In present investigation after exposure to lethal concentrations of pesticide, neutral mucosubstances was decreased in epithelial cells, G1 Goblet cells, G3 Goblet cells,

submucosa, muscularis and serosa whereas sulfomucins in G2 Goblet cells was increased. Mucin keeps the wall of intestine moist and enabling early transport of ingested material apart from protecting the epithelial cells from mechanical and chemical injury (Sinha and Chakrabarti, 1982). Here, decrease in quantity of neutral mucins over the mucosal lining may lead into erosion of epithelial lining and subsequent ulcer. Whereas increase in acidic mucins i.e. sulfomucins may lubricate the mucosal layer and enhance gaseous exchange. Singh et al. (1974) supports the phenomenon, according to them the acidic mucosubstances have the water binding properties which is necessary to keep the surface of intestine moist for gaseous exchange. Similar observations made by Ghosh and Chakrabarti (1990) in fish, *Notopterus notopterus* exposed to cadmium and arsenic and by Sarkar and Ghosh (2010) in fish, *H. fossilis* exposed to metanil yellow. Here it is assumed that fluctuations in the amount of mucosubstances might be because of pesticides induced damage of the cells that may lead in to erosion and subsequent impairment in digestion and absorption by the mucosal epithelium. In the intestinal region of fish the function of acid and neutral mucin is lubrication, protection and in addition it has formed a favourable environment for ionic and molecular diffusion. In the intestine of present fish, the mucous cells are found to be affected maximum due to the toxicity of dichlorvos. The excessive secretion of acidic mucosubstances which glide over the villi may provide protective membrane from toxic substances present in luminal medium.

CONCLUSION

From the results obtained in the present investigation and discussion, it is concluded that the harmful pesticides exert their effects on organ system and interfering with the physiological processes and metabolism by altering functional activity of cells with consequential changes in biochemical and molecular composition of fish, which alters the nutritional value of fish. As well as consumption of those fishes may be dangerous to human being in which pesticides have accumulated in their body. Therefore, the use of pesticides should be minimized around the water bodies.

Acknowledgement: The authors are grateful to Principal and Head, Dept of Zoology, S. G. M. College,

Karad, for providing necessary facilities during present work.

REFERENCES

- Cinar K and Senol N (2006) Histological and histochemical characterization of the mucosa of the digestive tract in flower fish (*Pseudophoxinus antalyae*). *AnatHistolEmbryol.*,35: 147-151.
- Channa A and Mir IH (2007) Neutral and acid mucin in the intestinal tract and gills of *Schizothorax curvifrons* Heckel. *J. Inland Fish. Soc. India.*, 39: 32-34.
- Ghosh, AR and Chakrabarti P (1990) Comparative toxicities of arsenic and cadmium to a freshwater fish, *Notopterus notopterus* (Pallas). *Environment and Ecology.* 8: 576-579.
- Gona O (1979) Mucous glycoproteins of teleostean fish: A comparative histochemical study. *J. Histochem.* 11: 709-718.
- Gopalakrishnan KS (1990) Studies on the toxic effects of some pesticides on the fish *Etroplus maculatus* (Bloch). Thesis submitted to the Cochin University of science and technology. pp 121-125.
- Kapoor, BG (1953) The anatomy and histology of the alimentary canal in relation to its feeding habits of a silurid fish, *Wallago attu* (BL. and SCHN). *J. Zool. Soc. India*, 5: 191-210.
- Kozaric Z, Kuzir S, Petrincic Z, Gjurcevic E, Baturina N (2007) Histochemistry of complex glycoproteins in the digestive tract mucosa of Atlantic bluefin tuna (*Thunnus thynnus*) L. *Vet Arh.*, 77 :441-452.
- Mehrotra, BK and Khanna SS (1969) Histomorphology of the oesophagus and the stomach in some Indian teleosts with inference on their adaptational features. *Zool. Beitr., Berl.* 15: 375-391.
- Moitra, SK and Roy, AK (1979) The comparative morphohistology and anatomy of the digestive system of two Indian freshwater Perches, *Ambassis nama* (Ham.) and *Ambassis ranga* (Ham.) in relation to their food and feeding habits. *Zool. Jb. Anat.* 102: 142-169.
- Oliveira-Ribeiro, CA and Fanta E (2000) Microscopic morphology and histochemistry of the digestive system of a tropical freshwater fish *Trichomycterus brasiliensis* (Lütken, 1874) (Siluroidei, Trichomycteridae). *Revista Brasileira Zoologia.*, 17(4): 953-971.
- Pathan, TS, Thete, PB, Shinde SE, Sonawane DL, Khillare, YK (2009) Histochemical changes in the liver of freshwater fish, *Rasbora daniconius*, exposed to paper mill effluent. *Emir J Food Agric.*, 21(2) : 71-78.
- Raji, AR, Norouzi E (2010) Histological and histochemical study on the alimentary canal in Walking catfish (*Claris batrachus*) and piranha (*Serrasalmus nattereri*). *Iran J Veter Res.*, 11(3) : 255-261.
- Santos, ML, Arantes FP, Pessali TC, Santos JE (2015) Morphological, histological and histochemical analysis of the digestive tract of *Trachelyopterus striatulus* (Siluriformes: Auchenipteridae). *Zoologia*, 32 (4): 296-305.
- Sarkar R and Ghosh AR (2010) Histochemical characterization of mucin in intestine and rectum of *Heteropneustes fossilis* (Bloch) induced by metanil yellow. *The Ecoscan.*, 4(4) : 297-300.
- Singh, BR, Guha G and Munshi JSD (1974) Mucous cells of the respiratory sac in an air-breathing fish, *Saccobranchius fossilis* (Bloch). *La Cellulae.* 70(1):1-15.
- Sinha, GM and Moitra SK (1974) Functional morpho-histology of the alimentary canal of an Indian freshwater major carp, *Labeo rohita* (Hamilton) during its different life-history stages. *Anat. Anz. Bd.* 138: 222 - 239.

© 2018 | Published by IJLSCI

Submit your manuscript to a IJLSCI journal and benefit from:

- ✓ Convenient online submission
- ✓ Rigorous peer review
- ✓ Immediate publication on acceptance
- ✓ Open access: articles freely available online
- ✓ High visibility within the field

Email your next manuscript to IRJSE
: editorirjse@gmail.com