

CASE REPORT

UNUSUAL CAUSE OF PROCTORRHAGIA FOR GASTROENTEROLOGISTS: RECTAL KAPOSI'S SARCOMA

Ion Dina¹, Octav Ginghina², Claudia Iacobescu¹, Sabina Zurac³, Rozalia Olsavszky⁴, Cristian Balalau⁵, Bianca Galateanu⁶, Corina Dalia Toderescu⁷, Carolina Negrei⁸

¹ „Sf. Ioan“ Emergency Hospital, Gastroenterology Clinic, University of Medicine and Pharmacy „Carol Davila“, Bucharest

² „Sf. Ioan“ Emergency Hospital, Surgical Clinic, University of Medicine and Pharmacy „Carol Davila“, Bucharest, Romania

³ Colentina University Hospital, Department of Pathology, University of Medicine and Pharmacy Carol Davila, Bucharest, Romania

⁴ „Dermestet“ Privat Practice, Bucharest, Romania

⁵ „Sf. Pantelimon“ Hospital Bucharest, Surgical Clinic, „Carol Davila“ University of Medicine and Pharmacy, Bucharest, Romania

⁶ Department of Biochemistry and Molecular Biology, University of Bucharest, Bucharest, Romania

⁷ „Vasile Goldis“ Western University of Arad, Faculty of Medicine, Pharmacy and Dental Medicine, Arad, Romania

⁸ Department of Toxicology, „Carol Davila“ University of Medicine and Pharmacy, Bucharest, Romania

ABSTRACT

Proctorrhagia is a frequent symptom encountered in clinical practice, in primary care medicine as well as in Gastroenterology Departments. The common causes of proctorrhagia include hemorrhoids, diverticular disease, colorectal tumors, angiodysplastic lesions, inflammatory bowel diseases or rectal polyps. The main diagnostic tool for establishing the diagnosis in a patient presenting with proctorrhagia is colonoscopy associated when necessary with histological examination of biopsied specimens. Taking into account that rectum is a possible localization, the differential diagnosis should consider the biological status of the patient and should be made according to the presence or absence of immunodeficiency virus. We report a case of a young heterosexual male, previously HIV-unknown,

RÉSUMÉ

Cause inhabituelle de la rectorrhagie pour les gastro-entérologues: le sarcome de Kaposi rectal

La rectorrhagie est un symptôme fréquemment rencontré dans la pratique clinique, par les médecins de soins primaires ainsi que par ceux des départements de gastroentérologie. Les causes communes de la rectorrhagie incluent les hémorroïdes, les maladies diverticulaires, les tumeurs colorectales, les lésions angiodysplasiques, les maladies inflammatoires de l'intestin ou les polypes rectaux. Le principal outil afin de mettre le diagnostic chez un patient présentant une rectorrhagie est associé à une coloscopie si nécessaire avec un examen histologique de spécimens prélevés. Compte tenu du fait que le rectum est une localisation

who presented for intermittent rectal blood loss and who was diagnosed after colonoscopic and histological assessment with rectal Kaposi's sarcoma.

Key words: proctorrhagia, HIV, Kaposi's sarcoma.

INTRODUCTION

Among the most common complaints that gastroenterologists deal with is rectorrhagia, defined as the passage of fresh blood through rectum, not necessarily related to defecation. Several conditions may be responsible for the appearance of rectal bleeding, as colonic diverticulosis, malignancies, anorectal pathology, inflammatory bowel diseases¹. The diagnostic procedure of choice is colonoscopy which enables direct visualization of colonic mucosa and also biopsy specimen prelevation. A tumor-like lesion found in rectum, with non-characteristic appearance represents a challenge for histopathologists to clarify the diagnosis. The clinical background should be outlined because an immunocompromised patient poses certain diagnostic problems. In immunocompetent subjects, Kaposi's sarcoma should not be taken into the differential diagnosis. Conversely, Kaposi's sarcoma is a common condition of immunodepressed patients, particularly of HIV-infected individuals². Kaposi's sarcoma is a vascular tumor, consisted of spindle-cells, with a nodule-like appearance that affects predominantly the skin and, to a lesser extent other internal organs³. There have been described four clinical types of Kaposi, the most common of them being Kaposi's sarcoma related to acquired immunodeficiency syndrome^{4,5}. Kaposi's sarcoma is the most frequent malignancy encountered in advanced HIV-infection and is always a defining condition of AIDS stage. When occurs in AIDS, the disease follows a highly aggressive course with multivisceral involvement, compared to other clinical forms^{4,6,7}. It seems that Kaposi expresses an infectious etiology, cause epidemiological studies state for a possible role of human herpes virus 8 in the pathogenesis of Kaposi disease, independent of HIV status^{7,8,9}. In addition, sexual behavior plays an important role in Kaposi progression with considerably high risk for HIV-infected homosexuals to develop Kaposi, compared to general population⁷. Regarding the clinical presentation, AIDS-related Kaposi exhibits skin and

possible, le diagnostic différentiel devrait tenir compte de l'état biologique du patient et devrait être effectué en fonction de la présence ou de l'absence du virus de l'immunodéficience. Nous rapportons un cas d'un jeune homme hétérosexuel, précédemment connu sans VIH, qui s'est présenté pour une perte de sang rectale intermittente et qui a été diagnostiqué, après une évaluation coloscopique et histologique, avec le sarcome de Kaposi rectal.

Mots clés: rectorrhagie, HIV, le sarcome de Kaposi.

mucosal lesions, lymphedema, pulmonary or gastrointestinal involvement⁴. Digestive symptoms as diarrhea, weight loss, bleeding or vomiting may occur as sole manifestations of Kaposi's sarcoma independent of cutaneous lesions. We present a case of a male heterosexual patient, with unknown HIV-status, who presented in our Gastroenterology Department for intermittent rectal bleeding and who was diagnosed with a rectal proliferation that proved to be Kaposi's sarcoma after histopathologic interpretation.

CASE REPORT

A 33-years old male patient was referred to our Endoscopy Department by his general practitioner for colonic investigation because he presented repetitive episodes of rectal bleeding with recent onset. The colonoscopy showed a poly globe-shaped flat mass lesion in the rectum located at 10 cm from the anal verge, with ulcerated mucosal surface, while the remaining colon up to the cecum and terminal ileum were normal [Fig 1].

The endoscopic appearance was atypical for rectal cancer as well as for inflammatory bowel disease or rectal ulcer. Several biopsy samples were taken and sent for histopathologic interpretation. The result was inconclusive, showing only nonspecific inflammation, without malignant features. Under such circumstances, the patient was admitted to our Gastroenterology Clinic for supplementary investigations, including a second colonoscopy with biopsy. Routine laboratory findings evidenced only mild normocytic anemia with hemoglobin level of 12.2 g/dl, mild leukopenia of 2900/mm³ and slight decrease in platelet number of 122.000/mm³. Taking into account the presence of pancytopenia, serology for syphilis and HIV infection were ordered. The first was negative, while antibodies against HIV were detected as positive, with a CD4 count of 140 cells/mm³. Colonoscopy with multiple biopsies, along with histopathologic examination were performed again. The histological assessment showed a spindle-cell proliferation within the chorion and

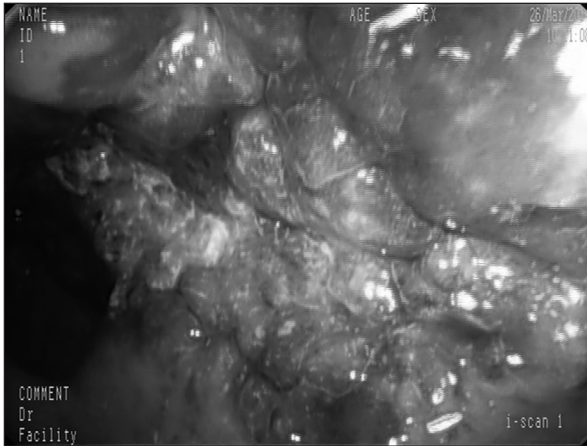


Figure 1. Rectal Kaposi- colonoscopic appearance.

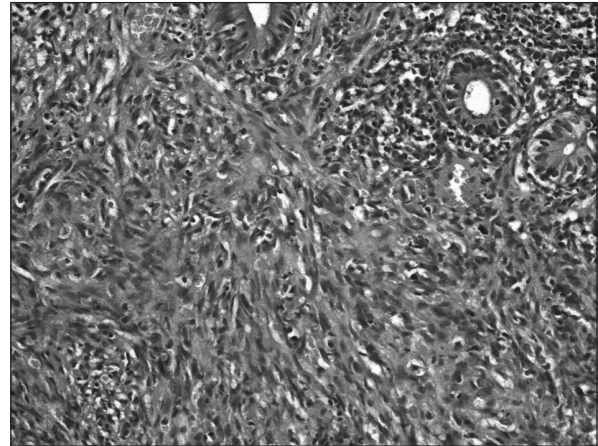


Figure 2. Sarcomatous proliferation with slit-like vascular spaces in rectal mucosa chorion, HEx200.

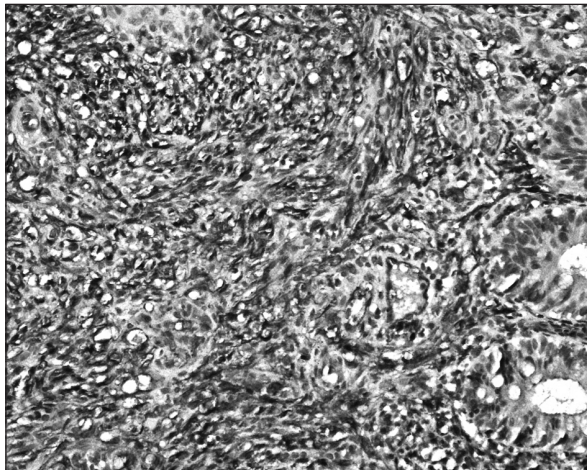


Figure 3a. Tumor cells with positivity for CD31; CD31x200

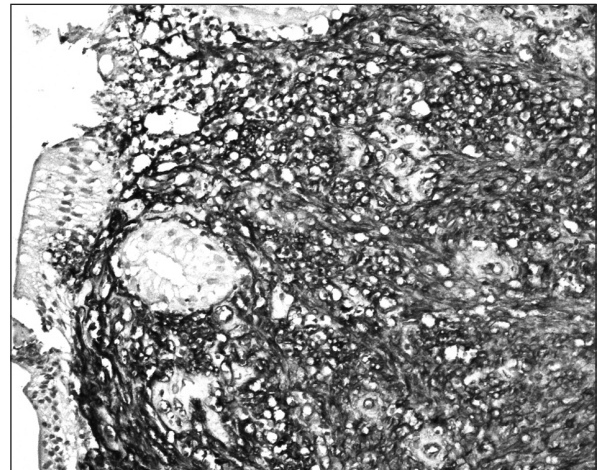


Figure 3b. Tumor cells with positivity for CD34; CD34x200

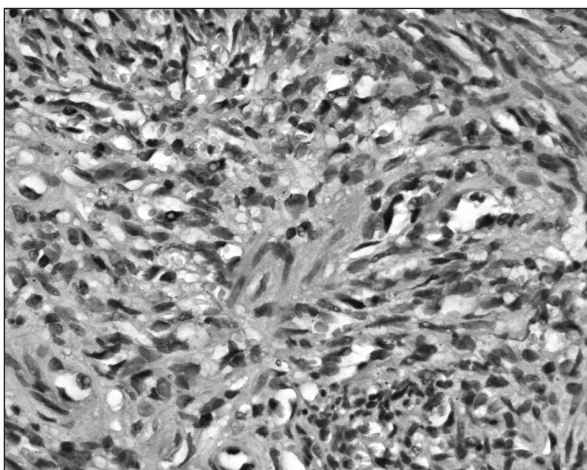


Figure 4. Rare tumor nuclei with positivity for HHV8; HHV8x400

colonic submucosa, with slit-like vascular spaces containing erythrocytes [Fig 2].

Immunohistochemistry evaluation revealed on the one hand tumor cells positivity for endothelial

markers CD31, CD34, FVIII and on the other hand negative staining for SMA and HHF35 [Fig 3a,b].

In addition, human herpes virus 8 was detected in the nucleus of tumor cells, therefore supporting the diagnosis of the Kaposi's sarcoma [Fig 4].

The patient was then referred to Infectious Disease Clinic for initiation of highly active anti-retroviral treatment (HAART).

DISCUSSION

Proctorrhagia is a common manifestation seen in Gastroenterology Departments which requires specific investigations. The majority of causes reveals a digestive disease, while in certain cases the background is represented by a systemic condition with rectum bleeding being an isolated symptom that gives a clue for diagnosis. Proctorrhagia secondary to rectum Kaposi's sarcoma is a rare entity and the diagnosis is sometimes challenging, as in our report, the

more as the patient was unknown to be HIV positive. Among patients with AIDS, approximately 30%-40% will develop Kaposi's sarcoma, typically with systemic dissemination and lymph node as well as intestinal involvement^{10,11}. Generally, the most frequent involvement of Kaposi is skin, but also gastrointestinal manifestations have been reported¹⁰. Another characteristic of AIDS-related Kaposi's sarcoma, known also as endemic form, is association with a homosexual behavior, with significant higher frequency in homosexual subjects, about 20 times more frequently in homosexuals than in heterosexuals with similar immunodeficiency¹¹. This aspect is not encountered in our case, the patient denied on one hand homosexual tendency and on the other hand intravenous drug administration or blood transfusions in the past. Usually, Kaposi of digestive tract is asymptomatic, or may present with bleeding from oral cavity, stomach or large bowel, as happened in our case¹¹. The systemic involvement in Kaposi's sarcoma predicts a poor outcome and an infaust long-term prognosis¹². Taking into account that the tumor growth begins in submucosa, the histologic diagnosis is possible only in 25 % of cases, explaining our delay of diagnosis through the lack of specificity of the first biopsy specimens¹². HHV-8 was found as an important marker of Kaposi, the majority of Kaposi lesions expressing this virus type³. In this stage of AIDS-related Kaposi's sarcoma, therapeutic options are palliative, including antiretroviral medication, chemo and radiotherapy¹¹. HAART could be considered the first-line treatment aiming to limit the extension of the lesions and to increase the survival rate¹¹. In this case, a common symptom like proctorrhagia finally evidenced a complex disease, leading to the diagnosis of AIDS. In conclusion, rectal Kaposi's sarcoma should be considered in the differential diagnosis of proctorrhagia independently of the patient's HIV status.

REFERENCES

1. Olde Bekkink M, McCowan C, Falk GA, Teljeur C, Van de Laar FA, Fahey T. Diagnostic accuracy systematic review of rectal bleeding in combination with other symptoms, signs and tests in relation to colorectal cancer. *Br J Cancer* 2010;102(1):48-58.
2. La Rosa L, Vaingurt, Ruben Miravalle et al. Perianal Kaposi's sarcoma. A case report and a review of the literature. *Acta Gastroenterol Latinoam*. 2013;43(1):39-43.
3. Pantanowitz L, Dezube BJ Kaposi sarcoma in unusual locations. *BMC Cancer* 2008;8:190.
4. Fatahzadeh M. Kaposi sarcoma. *Oral Surg Oral Med Oral Pathol Oral Radiol* 2012;113:2-16.
5. Centers for Disease Control. 1993 revised classification system for HIV infection and expanded surveillance case definition for AIDS among adolescents and adults. *MMWR Recomm Rep*. 1992;41 (RR-17):1-19.
6. Faghghi G, Radan M, Taheri S. Kaposi sarcoma with visceral involvement in a HIV-Neg female patient. *The Open Circulation and Vascular Journal*, 2009, 2, 37-39.
7. Wen KW, Damania B Kaposi sarcoma-associated herpesvirus (KSHV): Molecular biology and oncogenesis. *Cancer Lett*. 2010;289(2):140-50.
8. Mesri EA, Cesarman E, Boshoff C Kaposi's sarcoma and its associated herpesvirus. *Nature Reviews Cancer* 2010;707-19.
9. Sharma-Walia N, Paul AG, Bottero V, Sadagopan S, Veettil MV, Kerur N, Chandran B. Kaposi's sarcoma associated herpes virus (KSHV) induced COX-2: a key factor in latency, inflammation, angiogenesis, cell survival and invasion. *PLoS Pathog* 2010;6(2).
10. Kafmann T, Nisce LZ, Coleman M. Case report: Kaposi's sarcoma of the rectum - treatment with radiation therapy. *Br J Radiol*. 1996;69(822):573-574.
11. Manish Arora, Eric M Goldberg. Kaposi sarcoma involving the gastrointestinal tract. *Gastroenterol Hepatol (NY)*. 2010; 6(7): 459-462.
12. Kahl P, Buettner R, Friedrichs N et al. Kaposi's sarcoma of the gastrointestinal tract: report of two cases and review of the literature. *Pathol Res Pract*. 2007;203(4):227-231.