

Asian Pacific Journal of Reproduction

Journal homepage: www.apjr.net



doi: 10.4103/2305-0500.246342

©2018 by the Asian Pacific Journal of Reproduction. All rights reserved.

Role of follicle-stimulating hormone and estradiol benzoate in recovering spermatogenesis in tamoxifen-injured rats

Ali Olfati^{1,2✉}, Gholamali Moghaddam², Kaniaw Rafat Khafar³, Ali Mojtahedin⁴, Azad Abdolazadeh⁵

¹Research Center for Pharmaceutical Nanotechnology, Biomedicine Institute, Tabriz University of Medical Sciences, Tabriz, Iran

²Department of Animal Science, Faculty of Agriculture, University of Tabriz, Iran

³Sulaimani Technical Institute, Sulaimani Polytechnic University, Iraq

⁴Department of Physiology, Faculty of Agriculture and Natural Resources Moghan, University of Mohaghegh Ardabili, Ardabil, Iran

⁵Division of Histology, Department of Basic Sciences, Faculty of Veterinary Medicine, University of Tabriz, Tabriz, Iran

ARTICLE INFO

Article history:

Received 15 August 2018

Revision 8 September 2018

Accepted 12 October 2018

Available online 30 November 2018

Keywords:

Estradiol benzoate
Follicle-stimulating hormone
Gene expression
Spermatogenesis
Tamoxifen

ABSTRACT

Objective: To evaluate the effects of follicle-stimulating hormone (FSH) and estradiol benzoate (EB) on the recovery of spermatogenesis, histology, sexual hormones levels and testicular gene expression in testes of tamoxifen-injured rats. **Methods:** Forty adult rats were divided into eight groups in a factorial arrangement of tamoxifen and hormonal treatments. Half of the groups orally received 0.6 mg/kg tamoxifen, and 30 d later tamoxifen and non-tamoxifen groups (controls) were paired and assigned into four hormonal treatments with daily intramuscular injections for 10 consecutive days: 1 mL saline (control); 7.5 IU FSH; 12 µg/kg EB; and 7.5 IU FSH+12 µg/kg EB. One day after the last treatment, spermatozoa were recovered from epididymis, blood was processed for sex hormones concentration (testosterone, FSH and luteinizing hormone) and testes were processed for histology and RNA extraction for expression of genes related to apoptosis [caspase 3, inducible nitric oxide synthase (iNOS) and B-cell lymphoma-2 (Bcl-2)]. **Results:** Control groups did not show significant changes in most parameters, but hormonal treatments decreased caspase 3 and iNOS and increased Bcl-2 expression. Tamoxifen significantly decreased counts, motility and viability of spermatozoa, Bcl-2 expression and sex hormones. It increased intertubular space, caspase 3 and iNOS expression, and induced seminiferous tubular atrophy. The hormonal treatments reverted spermatogenesis, hormonal levels and histology compared with controls, however not attaining the same sperm quality as controls. **Conclusions:** Tamoxifen is clearly detrimental to spermatogenesis and overall testicular structure and function, whereas hormonal therapy with FSH and EB can improve testicular function and revert tamoxifen-induced azoospermia.

1. Introduction

Tamoxifen has commonly been used to treat breast cancer after surgery and radiation therapy. The effects of this drug are based on blocking the growth of cancer cells by interfering

with estrogen signaling (antagonist of the estrogen receptor), as observed in many tissues[1]. On this regard, the role of the tamoxifen-mediated pathway in its anti-estrogenic effects and the resulting changes of spermatogenesis are still unknown.

This is an open access article distributed under the terms of the Creative Commons Attribution-Non Commercial-Share Alike 4.0 License, which allows others to remix, tweak and build upon the work non-commercially, as long as the author is credited and the new creations are licensed under the identical terms.

For reprints contact: reprints@medknow.com

©2018 Asian Pacific Journal of Reproduction Produced by Wolters Kluwer- Medknow

How to cite this article: Olfati A, Moghaddam G, Rafat Khafar K, Mojtahedin A, Abdolazadeh A. Role of follicle-stimulating hormone and estradiol benzoate in recovering spermatogenesis in tamoxifen-injured rats. *Asian Pac J Reprod* 2018; 7(6): 248-253 .

✉ First and corresponding author: Ali Olfati, Research Center for Pharmaceutical Nanotechnology, Biomedicine Institute, Tabriz University of Medical Sciences, Tabriz, Iran.

Tel: +98-9195966273

E-mail: A.olfati65@gmail.com

Olfati *et al*[2] reported that pre-puberty exposure to tamoxifen in lamb has adverse effects on spermatogenesis and can suppress testicular activity. Spermatogenesis is a fundamental process of proliferation and differentiation of germ cells into spermatozoa, which is dependent on follicle stimulating hormone (FSH), produced by the adenohypophysis, and androgens, locally produced in response to luteinizing hormone (LH). Testosterone, as the major androgen in the testis, is essential for regulating the development, growth and metabolism of the male reproductive system. Our previous study indicated that a treatment with FSH and estradiol benzoate (EB) improved the spermatogenic recovery in this ram model[2].

Other studies have confirmed the negative effects of tamoxifen on the levels of circulating sexual hormones and fertility in humans[3], rats[4] and mice[5]. The decrease of circulating FSH, LH, and testosterone was also related to changes in gene expression in the testis[6].

Further understanding of chemotherapy drugs and their effects on the male reproductive system could help improve infertility treatments in patients. This study, using rat as a model, tests the hypothesis that exposure to tamoxifen alters testicular histology and function, and this may influence sex hormones and testicular gene expression, altogether suppressing spermatogenesis, whereas hormonal treatment could revert these effects. Therefore, the study is designed to evaluate the effect of FSH and EB on the testicular structure, apoptosis-related gene expression and sperm characteristics in tamoxifen-injured rats.

2. Materials and methods

2.1. Reagents and equipment

Reagents and equipment were purchased from Merck (Germany), except for tamoxifen (as citrate). Tamoxifen was prepared by Iran Hormone (Tehran, Iran) as tablets containing 10 mg tamoxifen. FSH (Gonaser[®], Laboratorios Girona, Spain), EB (Vetastrol, 2 mg/mL EB, CinnaGen Biopharma Co, Tehran, Iran) and testosterone, FSH and LH detection kits (Monobind Inc. Lake Forest, CA 92630, USA) were also purchased.

2.2. Animals

All the experimental protocols were approved by the Ethics Review Committee (No. February/2017 on 31 July 2017) of Tabriz University of Medical Sciences (permit number: A: 20-5235). Healthy adult male Wistar rats [(220±20) g; 6-week-old] were purchased from the Pasteur Research Center, Karaj, Iran. Rats were kept in an air-conditioned animal room under 12 h light: 12 h dark cycle under standard environmental conditions (22-23 °C, humidity 50%-55%) with free access to tap water and commercial dry pellet diet. During the experiment, rats were housed in polypropylene cages lined with pine wood husk, changed daily.

2.3. Experimental design

Forty rats were randomly assigned into eight groups, each comprising five rats. Four groups were assigned to tamoxifen treatment, receiving a 0.6 mg/kg oral gavage of tamoxifen (Tamoxifen was thoroughly suspended uniformly in distilled water). After 30 d, the tamoxifen and no-tamoxifen groups were paired and assigned into four hormonal treatments (intramuscular injection): 1 mL saline (control); 7.5 IU FSH; 12 µg/kg EB; and 7.5 IU FSH+12 µg/kg EB. Injections were administered for 10 consecutive days[2]. On completion of treatment, the rats were anesthetised with 0.64 mg/kg xylazine and 20 mg/kg ketamine (Alfasan, Woerden, the Netherlands) and then euthanized by exsanguination.

2.4. Histological analysis

The left testes were removed for histology parameters. After macroscopic observation, testicular tissue samples were fixed in 10% buffered neutral formaldehyde for at least 72 h. Tissue samples were directly dehydrated in a graded series of ethanol, cleared in xylene, and embedded in paraffin wax. Thin sections (5-7 µm), perpendicular to the longest axis of the testis were cut using a rotary microtome, stained with hematoxylin and eosin, and examined under a light microscope for histological studies (Olympus BX60, Japan).

2.5. Epididymal sperm analysis

In order to assess the epididymal sperm count, cauda epididymides were placed in 1 mL of Ham's F10 medium. The epididymis was cut into 2-3 pieces and incubated at 37 °C for few minutes (5% CO₂) in order to allow sperm to swim out the epididymal tubules. An aliquot of sperm suspension was diluted 1:20 with Ham's F10 medium and transferred into a Neubauer's hemocytometer. Spermatozoa were counted under a light microscope at ×400 and expressed as million/mL of suspension (World Health Organization, Department of Reproductive Health and Research, 2010). Sperm motility was determined by placing a drop of 10 µL of the sperm suspension in a 37 °C pre-warmed slide and covered with a coverslip. At least 10 fields were assessed for each sample using a bright-field microscope with a closed diaphragm and the percentage of motile spermatozoa was estimated subjectively[7]. Sperm viability was analyzed by eosin-nigrosin staining in 500 spermatozoa. A drop of stained sperm suspension was put on a clean slide and a thin smear was made and allowed for drying. This slide was examined under a light microscope at ×1 000 and spermatozoa with white and pink heads were considered as alive or dead, respectively[8].

2.6. Hormonal assays

Blood samples were obtained *via* the tail vein in order to evaluate the serum hormones. Samples were collected in vacuum tubes early in the morning before treatments. In order to evaluate the

testosterone, FSH and LH concentration, the serum was separated by centrifugation ($\times 4\ 000\ g$ for 10 min) and readily frozen at $-20\ ^\circ\text{C}$. Samples were assessed in groups by radioimmunoassay (MonobindInc kits). Standard commercial kits were used for analysis and the procedures were adopted as recommended by the manufacturer.

2.7. Gene expression analysis

The right testes were processed for genes expression. RNA was isolated with TRIzol reagent (Life Technologies) and quality and quantity were assessed by Nanodrop. The extracted RNAs were then stored at $-80\ ^\circ\text{C}$. The cDNA synthesis was performed with Takara cDNA syntheses kit (Takara Cat. No. 6130) according to the manufacturer's protocol.

Quantitative analysis was carried out using a Real-Time PCR System, Light Cycler 96 system (Roche Life Science). The relative quantification of mRNA expression level of *caspase 3*, *Bcl-2* and *iNOS* was performed using gene-specific primers and SYBR Green Master Mix (TAKARA Cat. No. RR820W), with glyceraldehyde-3-phosphate dehydrogenase as the reference gene. Primers were designed using Oligo 7 software and tested for spasticity and accuracy in the National Center for Biotechnology Information website. Duplicated cycle threshold values were measured for each sample and the comparative cycle threshold method was used to determine the relative expression level of the target genes[9].

2.8. Statistical analysis

Data (mean \pm SEM) were analyzed in the R statistical environment (v.3.4.3) by linear mixed-effects methods. Tamoxifen and hormonal treatments were included as fixed factors, with the replicate in the random part of the models. Since the interactions of tamoxifen and hormonal treatments were significant in all cases, each factor was studied within each level of the other. If it was significant, analyses were followed by a multiple comparison test with Holm's adjustment. $P < 0.05$ was considered significant.

3. Results

The administration of tamoxifen for 30 d clearly decreased spermatogenesis and altered testicular and hormonal results. The sperm production and quality (Table 1), blood serum levels of testosterone, FSH and LH of tamoxifen groups (Figure 1) significantly decreased in comparison to those in the control groups ($P < 0.05$). The hormonal treatments in the tamoxifen-treated animals significantly increased sex hormones levels and sperm parameters, but except for sperm counts, they did not recover up to the values in the no-tamoxifen group ($P < 0.05$).

Table 1

Sperm variables after saline or tamoxifen injections and subsequent hormonal treatments for 10 d (mean \pm SEM).

Groups	Spermatozoa ($\times 10^6$)	Viability (%)	Motility (%)
Saline	37.02 \pm 0.81	75.13 \pm 0.98	71.12 \pm 1.02
FSH	37.10 \pm 0.73	76.21 \pm 0.46	70.14 \pm 0.43
EB	36.15 \pm 0.44	76.31 \pm 0.54	69.21 \pm 0.65
FSH+EB	38.14 \pm 1.01	76.12 \pm 0.69	73.31 \pm 0.62
Saline+tamoxifen	22.15 \pm 1.32 ^b	30.12 \pm 0.06 ^b	26.12 \pm 0.72 ^b
FSH+tamoxifen	33.21 \pm 0.76 ^a	49.21 \pm 0.99 ^{ac}	43.31 \pm 0.93 ^{ac}
EB+tamoxifen	36.31 \pm 0.52 ^a	49.26 \pm 0.43 ^{ad}	44.31 \pm 0.98 ^{ad}
FSH+EB+tamoxifen	37.14 \pm 0.68 ^a	57.12 \pm 0.67	49.14 \pm 1.14 ^{ac}

Note: EB: Estradiol benzoate; a: $P < 0.05$ compared with saline+tamoxifen group, b: $P < 0.001$ compared with saline group; c: $P < 0.05$ compared with FSH group; d: $P < 0.05$ compared with EB group; e: $P < 0.05$ compared with FSH+EB group.

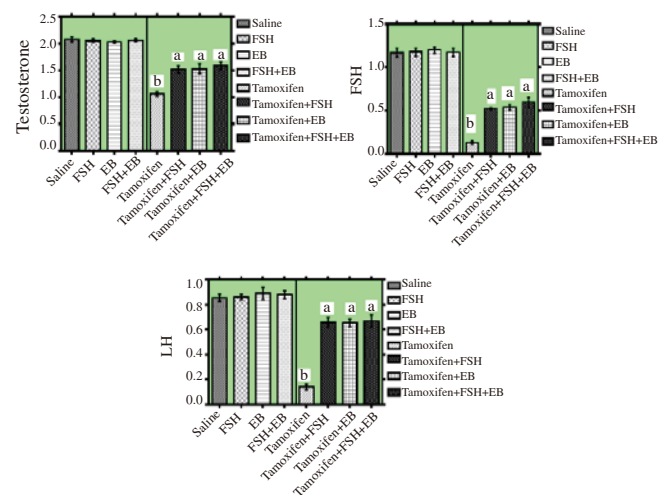


Figure 1. Blood serum hormones in no-tamoxifen or tamoxifen groups and subsequent hormonal treatments for 10 d.

Graphs show mean \pm SEM; Letters indicate that treatments differ $P < 0.05$ within each tamoxifen group; EB: Estradiol benzoate.

The testicular histological structure and the seminiferous tubules architecture of no-tamoxifen rats were normal irrespective of the hormonal treatment (Figure 2), whereas the tamoxifen treatment caused extensive disruption of the histology (Figure 3a). We observed atrophy of the seminiferous tubules with damage to the germinal epithelium and shrinkage of the basal lamina. It was accompanied by an increase of the interstitial space, which presented congested blood vessels and vascular hyperemia. The administration of FSH and EB, especially when combined, recovered the histological structure (Figures 3b, c and d). FSH still showed increased interstitial space and some damage in the seminiferous tubules, but EB and FSH+EB showed almost complete repair, with a clearly functional epithelium. In hormone-treated groups, we observed Leydig cells adjacent to the basal lamina, and elongating and round spermatids in the epithelium.

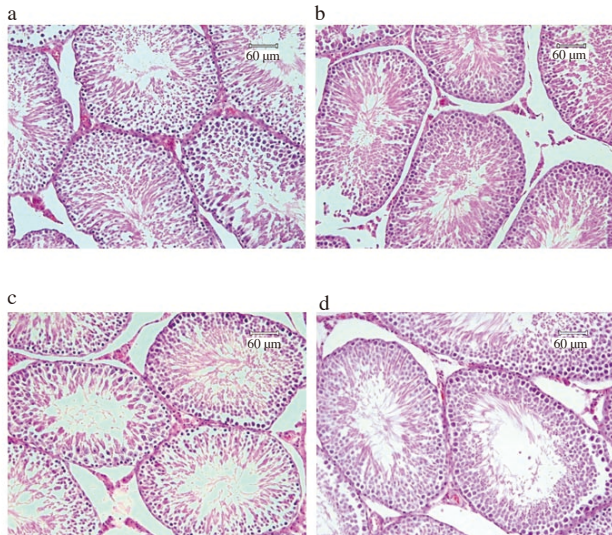


Figure 2. Testicular histological structure of no-tamoxifen rat after treatment for 10 d with: (a) 1 mL saline (control); (b) 7.5 IU FSH; (c) 12 µg/kg EB; (d) 7.5 IU FSH+12 µg/kg EB.

The histological structure and seminiferous tubule architecture were normal (hematoxylin and eosin, ×400, bar scale = 60 µm). EB: Estradiol benzoate.

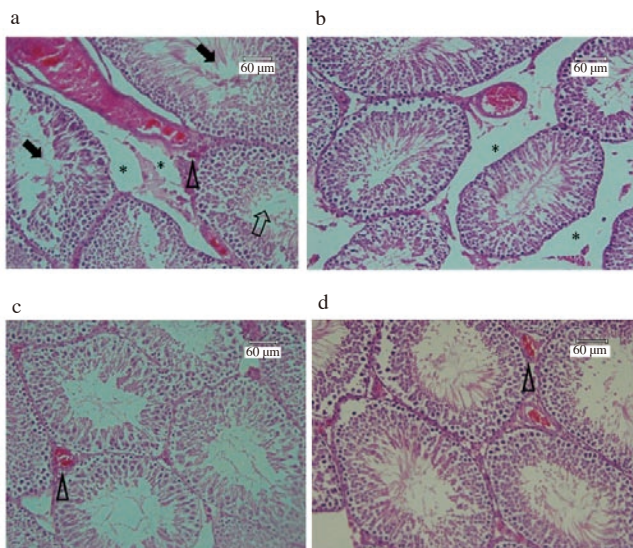


Figure 3. Testicular histological structure and the regeneration of germinal epithelium 30 d after orally gavage of tamoxifen (600 mg/kg) and a hormonal treatment: (a) 1 mL saline (control); (b) 7.5 IU FSH; (c) 12 µg/kg EB; (d) 7.5 IU FSH+12 µg/kg EB.

Sections of testis tissues from rats treated with tamoxifen and saline (A) show extensive atrophy in the seminiferous tubules, destruction of the germinal epithelium (black arrows), increased interstitial space (black asterisks), congested blood vessels and vascular hyperemia (hollow arrow head) and shrinkage of the basal lamina (hollow arrowhead), compared to Figure 1 (no-tamoxifen). After the 10-day-hormone treatments, FSH (B) still presents signs of damage, but in the EB (C) and especially the FSH+EB groups (D), we observed repair of the damage, with an organized germinal epithelium (hematoxylin and eosin, ×400, bar scale = 60 µm). EB: Estradiol benzoate.

However, neither *caspase 3* nor *iNOS* expressions were significantly modified by the tamoxifen treatment, whereas *Bcl-2* expression was increased in the tamoxifen-treated group compared to the saline group (Figure 4). In general, hormonal treatments considerably reduced *caspase 3* expression in both experimental groups compared to the controls, and to a lesser degree they also decreased *iNOS* expression while increasing *Bcl-2* expression. However, the effects of the hormonal treatments were complex. Thus, FSH was the only one significantly increasing *Bcl-2* expression compared to the saline group, but it was the only one decreasing the expression of this gene in the tamoxifen group ($P < 0.05$). For this same gene, the effect of EB+FSH did not reach significance in any of the groups, but EB alone was the only treatment significantly increasing its expression in the tamoxifen group.

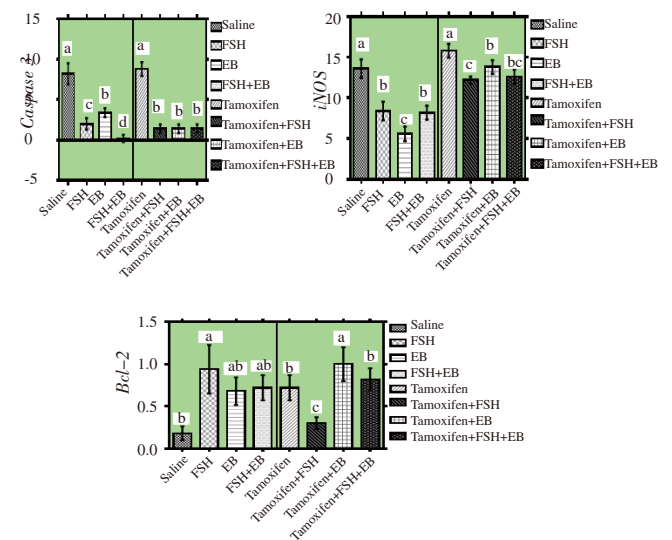


Figure 4. Relative expression (with respect to the non-treated groups) of *caspase 3*, *iNOS* and *Bcl-2* genes in the rat testis after tamoxifen treatment and subsequent hormonal treatments for 10 days.

Graphs show mean±SEM; Letters indicate that treatments differ $P < 0.05$ within each group; EB: Estradiol benzoate.

4. Discussion

One of our more relevant findings was the effects of the hormonal treatments on spermatogenesis recovery in the tamoxifen-injured rats. Our findings suggest that FSH and estrogen are main players in stimulating spermatogonia proliferation in tamoxifen-injured rats. FSH and EB stimulate germ cell development, increasing germ cell numbers and sperm production[10]. Jafarian *et al*[11] reported that the simultaneous use of FSH and estradiol synergistically restored spermatogenesis in azoospermic mice. Tamoxifen disrupts estradiol signaling, which is critical for the maintenance of testicular function, and concomitantly alters hormonal balance and sperm production.

It seems that supplementation with FSH or EB can counteract tamoxifen effects and help recover the hormonal balance. One of the effects seems to be a partial recovery of LH levels, which results in testosterone production, possibly contributing to the restoration of spermatogenesis.

Similarly, FSH regulates spermatogenesis through receptors on the Sertoli cells, with FSH directly influencing the process[12]. Androgens also act to maintain spermatogenesis through its effects on peritubular myoid cells[13].

The effects of tamoxifen reflected on the disruption of the histological structure of the testicle. Earlier reports have demonstrated that tamoxifen treatment in mice (0.25 mg/kg daily for 14 weeks[5]) and lambs (660 µg/kg daily for 30 d[2]) caused several histopathological changes in testis and epididymis such as thickening tunica albuginea, distortion and deforming some seminiferous tubules, degenerating Leydig cells and increasing interstitial space. Whereas we would need mechanistically experiments to confirm it, the antiestrogenic effect of tamoxifen seems to be the culprit here. The subsequent hormonal disruption could worsen its effects, leading to the spermatogenic arrest.

Our study shows new information for the rat as an animal model for tamoxifen effects on the male reproductive system. Maintenance of normal male fertility depends on spermatogenesis, which is under complex endocrine control by involving mechanisms in gonadotropin and steroid hormones[14]. Our hormonal evaluation confirms that tamoxifen destroys the sexual hormones homeostasis (testosterone, FSH and LH), likely by acting on estradiol receptors in the testicle and in the hypothalamus-pituitary axis. Tamoxifen-injured rats showed reduced serum testosterone, FSH and LH levels, which may be responsible for the inhibition of spermatogonial proliferation and differentiation in the testicles of these animals. In male mammals, estrogen has an important role in the regulation of spermatogenesis and testicular functions[2]. Balasinor *et al*[15] demonstrated that the reduced testosterone and LH levels were due to a decrease in hypothalamic luteinizing hormone-releasing hormone concentration and in LH pulsatility following tamoxifen treatment in a rat model. However, these authors noticed no decrease on circulating FSH after 90 days, and even an increase by day 40, under the same experimental conditions, which was attributed to the modulation of inhibin and activin. However, we have detected a very pronounced effect on circulating FSH levels, which could be due to the different concentration range used in this study. This effect on FSH, together with LH and testosterone decrease, helps to explain the radical effects of tamoxifen on the testicle, since FSH is critical for Sertoli cells function on spermatogenesis maintenance.

The treatment of tamoxifen-injured male rats with EB or FSH induced the recovery of testosterone and FSH levels, causing testicular restoration and qualitatively normal spermatogenesis. Estradiol normally inhibits FSH production in the male reproductive system by negative feedback both at central (hypothalamus-pituitary axis) as well as peripheral (gonad) targets[16]. Our results suggest that the EB

supplementation did not block but rather enhanced FSH secretion.

Our study also confirmed that the histological disruption in the testis of tamoxifen-treated rats was related to widespread apoptosis. The testicular gene expression of the apoptosis-related *caspase 3*, *Bcl-2* and *iNOS* was altered towards increased apoptosis. The exact biological pathways leading to the testicular expression of *caspase 3* and *iNOS*, and to the repression of *Bcl-2* in chemotherapy are not known, but our results indicate active apoptosis in the testicular tissue. One of the supposed mechanisms underlying the restoration of spermatogenesis by the FSH and EB treatment is the suppression of testicular apoptosis and the improvement of the mechanics for the control of cell shape changes.

Verma and Krishna[17] have reported that the decreased estrogenic effect due to tamoxifen may be directly responsible for decreased testicular expression of aromatase, which in turn may be responsible for the decreased synthesis of estradiol in the testis. Estrogen acts as a regulator of the proliferation/apoptosis balance in rat, especially in germ cells[18], and other studies have showed that estrogens are involved in several aspects of rodent spermatogenesis and control of apoptosis[19,20]. Estrogen acts as a regulator of the proliferation/apoptosis balance in rat, especially in germ cells[18]. Moreover, the decrease of testosterone secretion in tamoxifen-treated rats could worsen the effects of decreasing estrogen synthesis, since testosterone regulates some genes supporting the complex development of germ cells[21].

FSH and EB treatments could regulate the expression of these genes, not only on the tamoxifen group, but also in untreated rats, suggesting a direct effect on promoting or arresting apoptosis in the testicle (possibly in the spermatogenic cells). However, we need to confirm if they directly affected the testicular tissues, or if their effects were mediated by other systems. For instance, FSH and EB could increase the sensitivity of pituitary gonadotropin-releasing hormone receptors, affecting the hormonal balance[22]. However, this seems unlikely, since we have observed changes in the gene expression in the saline groups, but no apparent effects of the hormonal treatments on circulating hormones.

In conclusion, the administration of tamoxifen can impair spermatogenesis and cause infertility, seriously altering the histological structure of the testicle and the hormonal balance. These effects can be caused either directly by acting on testis or indirectly by negative effects on the regulation of gonadotropin secretion. These questions should be addressed in future mechanistic studies. FSH and EB help to recover spermatogenesis and histological testicular structure, and effectively inhibit germ cell apoptosis in the testis of tamoxifen-injured rats.

Conflict of interest statement

The authors declare that they have no conflict of interest.

Acknowledgments

Authors would like to acknowledge Research Center for Pharmaceutical Nanotechnology, Biomedicine Institute and Immunology Research Center, Tabriz University of Medical Sciences that has provided excellent assistance with the preparation of this research and also to thank all of the members of our laboratories (Prof. Dr. Mehrdad Payandeh and Dr. Mehran Mesgari-Abbasi) for their scientific contributions during these years.

References

- [1] Balasinor N, Gill-Sharma MK, Parte P, D'Souza S, Kedia N, Juneja HS. Effect of paternal administration of an antiestrogen, tamoxifen on embryo development in rats. *Mol Cell Endocrinol* 2002; **190**(1-2): 159-166.
- [2] Olfati A, Moghaddam G, Baradaran B, Hamidian G. The effect of estradiol benzoate and FSH on hormonal levels and stereology structure of testis in Ghezel lambs treated with Tamoxifen citrate. *Revue Méd Vét* 2018; **169**(1-3): 58-64.
- [3] Pemmaraju N, Munsell MF, Hortobagyi GN, Giordano SH. Retrospective review of male breast cancer patients: Analysis of Tamoxifen-related side-effects. *J Ann Oncol* 2012; **23**: 1471-1474. Doi: 10.1093/annonc/mdr459.
- [4] Gill-Sharma MK, Balasinor N, Parte P. Effect of intermittent treatment with Tamoxifen on reproduction in male rats. *Asian J Androl* 2001; **3**: 115-119.
- [5] Taha SM, Shatha MH, Fahem MM, Najat M. Hormonal and histopathological changes in male reproductive system of albino mice after Tamoxifen administration. *J Genet Environ Resour Conserv* 2016; **4**(1): 51-56.
- [6] Zhou W, Bolden-Tiller OU, Shao SH, Weng CC, Shetty G, AbuElhija M, et al. Estrogen-regulated genes in rat testes and their relationship to recovery of spermatogenesis after irradiation. *Biol Reprod* 2011; **85**: 823-833. DOI: 10.1095/biolreprod.111.091611.
- [7] Sakhaee E, Emadi L, Abshenas J, Kheirandish R, Azari O, Amiri E. Evaluation of epididymal sperm quality following experimentally induced copper poisoning in male rats. *Andrologia* 2012; **44**(suppl 1): 110-116. DOI: 10.1111/j.1439-0272.2010.01147.x.
- [8] Kolahian S, Sadri H, Larijani A, Hamidian G, Davasaz A. Supplementation of diabetic rats with leucine, zinc, and chromium: Effects on function and histological structure of testes. *Int J Vit Nut Res* 2016; **85**(5-6): 311-321. DOI: 10.1024/0300-9831/a000244.
- [9] Rao X, Huang X, Zhou Z, Lin X. An improvement of the 2⁻(-delta delta CT) method for quantitative real-time polymerase chain reaction data analysis. *Biostat Bioinforma Biomath* 2013; **3**(3): 71-85.
- [10] O'Shaughnessy PJ. Hormonal control of germ cell development and spermatogenesis. *Semin Cell Dev Biol* 2014; **29**: 55-65. DOI: 10.1016/j.semdb.2014.02.010.
- [11] Jafarian A, Akhondi MM, Pezhhan N, Sadeghi MR, Zarnani AH, Salehkhoh S. Stimulatory effects of estradiol and FSH on the restoration of spermatogenesis in azoospermic mice. *J Reprod Infertil* 2009; **9**(4): 317-324.
- [12] Ramaswamy S, Weinbauer GF. Endocrine control of spermatogenesis: Role of FSH and LH/ testosterone. *Spermatogenesis* 2014; **4**(2): e996025. DOI: 10.1080/21565562.2014.996025.
- [13] Welsh M, Saunders PTK, Atanassova N, Sharpe RM, Smith LB. Androgen action via testicular peritubular myoid cells is essential for male fertility. *FASEB J* 2009; **23**(12): 4218-4230. DOI: 10.1096/fj.09-138347.
- [14] Dumasia K, Kumar A, Kadam L, Balasinor NH. Effect of estrogen receptor-subtype specific ligands on fertility in adult male rats. *J Endocrinol* 2015; **225**: 169-180. DOI: joe.endocrinology-journals.org.
- [15] Balasinor N, Parte P, Gill-Sharma MK, Kini J, Juneja HS. Mechanism delineating differential effect of an antiestrogen, Tamoxifen, on the serum LH and FSH in adult male rats. *J Endocrinol Invest* 2006; **28**: 485-496.
- [16] Hayes FJ, Seminara SB, Decruz S, Boepple PA, Crowley JW. Aromatase inhibition in the human male reveals a hypothalamic site of estradiol feedback. *J Clin Endocrinol Metab* 2000; **85**: 3027-3035. DOI: 10.1210/jcem.85.9.6795.
- [17] Verma R, Krishna A. Effect of Tamoxifen on spermatogenesis and testicular steroidogenesis. *Biochem Biophys Res Commun* 2017; **486**: 36-42. DOI: 10.1016/j.bbrc.2017.02.092.
- [18] Bois C, Delalande C, Nurmio M, Parvinen M, Zanatta L, Toppari J, et al. Age- and cell-related gene expression of aromatase and estrogen receptors in the rat testis. *J Mol Endocrinol* 2010; **45**: 147-59.
- [19] O'Donnell L, Robertson KM, Jones ME, Simpson ER. Estrogen and spermatogenesis. *Endocr Rev* 2001; **22**: 289-318. DOI: 10.1210/er.22.3.289.
- [20] Carreau S, Hess RA. Oestrogens and spermatogenesis. *Philos Trans R Soc Lond B Biol Sci* 2010; **365**(1546): 1517-1535. DOI: 10.1098/rstb.2009.0235.
- [21] Sarkar D, Chowdhury JP, Singh SK. Effect of polybrominated diphenyl ether (BDE-209) on testicular steroidogenesis and spermatogenesis through altered thyroid status in adult mice. *Gen Comp Endocrinol* 2016; **239**: 50-61. DOI: 10.1016/j.ygcen.2015.11.009.
- [22] Kumar A, Dumasia K, Deshpande S, Raut S, Balasinor NH. Delineating the regulation of estrogen and androgen receptor expression by sex steroids during rat spermatogenesis. *J Steroid Biochem Mol Biol* 2018; **182**: 127-136. DIO: 10.1016/j.jsbmb.2018.04.018.