

Asian Pacific Journal of Reproduction

Journal homepage: www.apjr.net



doi: 10.12980/apjr.6.20170105

©2017 by the Asian Pacific Journal of Reproduction. All rights reserved.

Ultrasound guided testicular fine needle aspiration in buck (*Capra hircus*)—An animal model

Sattwikesh Paul^{1✉}, Nasrin Sultana Juyena², Shonkor Kumar Das³, Raihana Nasrin Ferdousy², Rahul Deb Sarker⁴, Soheli Jahan Mou²

¹Department of Surgery and Radiology, Faculty of Veterinary Medicine and Animal Science, Bangabandhu Sheikh Mujibur Rahman Agricultural University, Gazipur, Bangladesh

²Department of Surgery and Obstetrics, Faculty of Veterinary Science, Bangladesh Agricultural University, Mymensingh

³Department of Anatomy and Histology, Faculty of Veterinary Science, Bangladesh Agricultural University, Mymensingh

⁴Department of Pathology, Faculty of Veterinary Science, Bangladesh Agricultural University, Mymensingh.

ARTICLE INFO

Article history:

Received 12 October 2016

Revision 20 November 2016

Accepted 10 December 2016

Available online 1 January 2017

Keywords:

Testicular fine needle aspiration

Spermatic index

Sertoli cell index

ABSTRACT

Objective: To establish ultrasound guided testicular fine needle aspiration (TFNA) as well as to assess the effectiveness of uni-directional (UD) and multi-directional (MD) TFNA in buck according to testicular cells, echotexture and gross changes of testicle, age of buck was considered. **Methods:** A total of 120 samples were collected with both directions (UD, $n=60$) and (MD, $n=60$) suction from testis of 10 apparently healthy bucks. All slides were stained with May-Grünwald-Giemsa and examined under light microscope with $1000\times$ magnifications to count spermatogenic cells, spermatozoa and sertoli cells. The percentage of spermatozoa and sertoli cells were expressed as spermatic index and sertoli cell index. **Results:** Results revealed no difference in the presence of various spermatogenic and sertoli cells in cell cluster of slides made either unidirectional TFNA or multidirectional TFNA. Early spermatids were the most numerous, followed by late spermatids, primary spermatocytes, spermatogonia. Sertoli cell index was higher in TFNA smears of young bucks prepared 7-13 mo of age and spermatic index was higher in adult bucks 14-24 mo of age. No echogenic change was observed in the echotexture of testis after TFNA. **Conclusions:** It seems that TFNA has no serious ill effect on the buck testis when uni-direction aspiration is performed. Moreover, the possibility to standardize this method might provide a greater impulse to the clinical diagnostics of male animal infertility.

1. Introduction

Goats among the first domesticated species for the production of meat, milk, skin, and fiber, are an integral part of rural's symbiotic system of crop and livestock production in Bangladesh. Bangladesh possesses 34.5 million goats at present, which constitute about 4.49% of the total population in the world[1]. In Bangladesh the Black Bengal goat having variation in color, size and weight comprised more than 90% of goat population[2]. Fertility assessment is one of the most talks of the topics in livestock sector now a day. Sub-fertile sires can easily be identified and eliminated by evaluating reproductive soundness. Identification of fertility problems in bucks requires accurate diagnostic techniques. Moreover, various chemical castration procedures are followed to control breeding male and fattening purposes, for which study of spermatogenesis and semen production are necessary to evaluate the efficacy of castration method. Testicular Fine Needle Aspiration (TFNA) cytology and trans-scrotal ultrasonography can be employed in assessing fertility in bucks, as well as the diagnosis of testicular

lesions. Recent technical advances of ultrasonogram applications and post processing developments have enabled new aspects in the structural and functional analysis of testicular tissue and therefore male fertility[3]. Accurate measurement of scrotal circumference can be done by trans-scrotal scanning through visualization of tissue interfaces within the scrotum[4]. Moreover, palpable and non-palpable testicular lesions can easily be assessed by this method[5].

TFNA is a painless, minimally invasive and cost-effective procedure. It is a less time consuming procedure which have the ability to present all spermatogenic cells with their defined characteristics. TFNA has established itself as the useful diagnostic tool for male infertility[6–8]. It is advantageous to use TFNA as this technique avoids the problems of post-operative hemorrhage, fibrosis, adhesions, and risk of development of anti-sperm

This is an open access article distributed under the terms of the Creative Commons Attribution-Non Commercial-Share Alike 3.0 License, which allows others to remix, tweak and build upon the work non-commercially, as long as the author is credited and the new creations are licensed under the identical terms.

For reprints contact: reprints@medknow.com

©2017 Asian Pacific Journal of Reproduction Produced by Wolters Kluwer- Medknow

How to cite this article: Sattwikesh Paul, Nasrin Sultana Juyena, Shonkor Kumar Das, Raihana Nasrin Ferdousy, Rahul Deb Sarker, Soheli Jahan Mou. Ultrasound guided testicular fine needle aspiration in buck (*Capra hircus*)—An animal model. Asian Pac J Reprod 2017; 6(1): 23-28.

✉ Corresponding author: Sattwikesh Paul, Assistant Professor, Department of Surgery and Radiology, Faculty of Veterinary Medicine and Animal Science, Bangabandhu Sheikh Mujibur Rahman Agricultural University, Gazipur-1706, Bangladesh.
E-mail: paulsattwik@gmail.com.

antibodies. However, all of the conditions may appear when open biopsy of testes is performed[9]. In addition, TFNA has recognized widely in Intra Cytoplasmic Sperm Injection (ICSI) in assisted reproduction technique (ART)[10]. But, there are few reports of TFNA in domestic animals, such as, in dog[11] and[12], bull[13], stallion[14] and alpacas[15] rather than in man. Studies on TFNA in buck are very scanty. Therefore, this study was designed, to establish ultrasonoguided testicular fine needle aspiration in bucks, to assess the effectiveness of uni-directional and multidirectional TFNA in buck according to qualitative and quantitative identification of testicular cells; echotexture of testicle and gross changes in testicular size (wide and length) and architecture after TFNA.

2. Materials and methods

2.1. Animals

Ten bucks were divided into two groups according to age and each group contained 5 bucks. Samples ($n=60$) were collected through unidirectional TFNA from both right and left testes. After one month multidirectional TFNA was performed to collect samples ($n=60$) from all bucks. All TFNA samples were monitored with trans-scrotal ultrasonography.

2.2. Ultrasonography of testis

B-mode digital Ultrasound system (Vet Eickemeyer Magic 5 000) with transrectal probe 5 MHz, probe type: C20615S) was used for ultrasonographic scanning. Buck was restrained in lateral recumbency by an assistant. The buck was cleaned over the inguinal area. The testis and epididymis were grasped at the scrotal neck and the transducer was progressed cranially along the neck of the testis to the cauda epididymis. Local infiltration of 2% Lidocaine Hydrochloride (Jasocaine®, Jayson Pharmaceuticals Ltd., Bangladesh) was performed in spermatic cord. Desensitization was confirmed by needle pricking. The testis and scrotum were grasped with one hand so that the scrotal skin tensed over the site to be aspirated. The ultrasonography machine was activated and the probe was placed over the site of fine needle insertion to the testis. A 21 gauge 2.3'' butterfly needle attached to a 50 mL syringe was advanced at right angles to the skin and inserted smoothly into the testes using a method similar to that described by Larkin[16]. Inserted needle was observed ultrasonographically for proper placement and direction of needle in the testis. The ultrasound monitor and operator's eye were at comparable level for accurate reading of ultrasound images. The technique used for scanning was similar to that described by Ahmad *et al.*[17] in small ruminants. During TFNA probe was set on the testes to monitor sample aspiration.

2.3. Aspiration of testicular tissue

Suction pressure was applied to aspirate testicular tissue. The aspirate was then expelled onto a clean glass slide and spread using the edge of a second glass slide with a 45 degree angle. For multi directional technique fine needle was inserted into the testis in 3-4 different directions. All slides ($n=120$) were air-dried, stained with modified May-Grünwald-Giemsa (MGG)[18]. Briefly, smears were immersed into May-Grünwald stain for 3 min, rinsed with water, then immersed into Giemsa (diluted 1:2 in distilled water) for 10 min. Then the extra stain was rinsed and samples were again air-dried. The cytological smears were examined under light microscope with 1 000 magnification with immersion oil. An adequate and informative TFNA specimen was defined by observing several clusters or cords of cells that contained 10 or more cells, and for interpretation at least 200 well-dispersed spermatogenic cells and

Sertoli cells were counted from different clusters on each slide. Various cell types were identified by their distinctive morphology and criteria described by Schenck *et al.*[19]. Spermatogonia (Sg), primary spermatocytes (Ps), secondary spermatocytes (Ss), early spermatids (Es), late spermatids (Ls), spermatozoa and Sertoli cells were identified and counted. Wide and length of the testis were measured before and after needle insertion with the help of slide calipers. Before taking the measurement gentle pressure was given at the base of the scrotum for apposition of the testis. Post operated data were collected for at least five consecutive days. All data were recorded.

2.4. Castration of buck

Open method castration was done in four bucks (2 for each direction) following aseptic method after 6 d of TFNA. After castration each testis was sectioned to observe any tract or mark of TFNA with two directions.

2.5. Statistical analysis

The results were given as mean±SEM. The spermatozoa were expressed as the spermatogenic index (SI=the number of spermatozoa/the number of total spermatogenic cells), and the Sertoli cells were expressed as Sertoli cell index (SEI= the number of Sertoli cell/the number of total spermatogenic cells). Statistical analysis was performed using SPSS version 17.0. Paired *t*-test was performed to analyze significant variations among cellular types in two methods of TFNA and two age groups. ANOVA was carried out to analyze significant variation among testicular size (wide and length) recorded before and after TFNA. $P<0.05$ value was considered as significant.

3. Results

3.1. Qualitative and quantitative identification of testicular cells

The study was conducted to establish the ultrasonoguided fine needle aspiration technique in buck. It is assumable that multi-direction suction of tissue gives diversified cells than uni-direction suction during TFNA. The cytological appearance of spermatogenic cells in an air-dried MGG stained smear showed various transitional forms, from spermatogonia to spermatozoa, characterized by diminution of nuclear size and condensation of chromatin.

There was no difference in the presence of various spermatogenic cells and Sertoli cells in cell cluster of TFNA slides prepared after two directions suction (Figure 1).

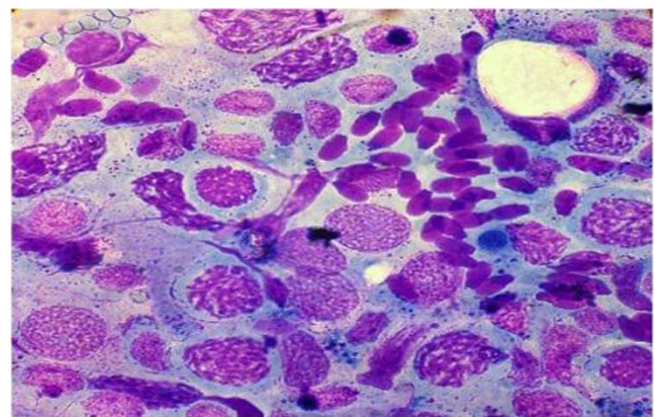


Figure 1. Presence of different spermatogenic cells and Sertoli cells in cell cluster considered for cell counting.

In the cytological smear, sertoli cells were identified as having a nude and large round or little oval shape, vesicular nucleus which shows finely granular chromatin and usually contains a large nucleolus. Nucleolus always took different color from nucleus (*e.g.* Red colored nucleus, blue colored nucleolus) Cytoplasm was not always seen (Figure 2a). The spermatogonia were usually uninucleate but occasionally are binucleate or multinucleate. The nuclei were round or oval, slightly eccentric and dark or pale, depending on their chromatin density. The chromatin frequently had a denser area peripherally, with a fine homogenous chromatin pattern. Pale colored spermatogonia were found in this study (Figure 2b). Primary spermatocytes had a large nucleus with thread-like or coarse chromatin. As chromosomal structures became very prominent, the nuclear outline may become irregular. The cytoplasm, if present, was basophilic; it was more deeply stained in the periphery of the cell (Figure 2c). Secondary spermatocytes were rarely identified because of their short lifespan and immediate transformation into spermatids. Nucleus was smaller than primary spermatocytes and granular and eccentric. Nearly red or violet colored granules were seen in red colored nucleus. Nucleolus was not normally seen (Figure 2d). Spermatids were of two types-Es and Ls. Early spermatids had a much smaller, round or irregularly triangular nucleus. Chromatin was finely, homogeneously granular and doubly (some) colored. Granular nucleus was always seen in the central of cytoplasm. Cytoplasm was basophilic, granular and vacular (Figure 2e). The nucleus of Ls was small, homogenous and eccentric in basophilic granular cytoplasm (Figure 2f). Spermatozoa had oval nuclei with very dense chromatin with or without tail (Figure 2g). Leydig cells were not detected or, possibly, could not recognize.

Quantitative analysis of testicular cytology was performed. The number (mean±SEM) of various spermatogenic cells were shown in Table 1. In this study, both age and TFNA direction were considered to describe numerosity of cells. Early spermatids were the most numerous, followed by Ls, Ps, Sg in bucks of two age groups although significant variation was existed in numbers of cells (Table 1). There was no significant difference in Sg and Ss between age groups as well as between TFNA directions. But Sg in right testis varied significantly ($P<0.05$) between age groups. Similarly, significant ($P<0.01$) variation was existed in number of Ps, Es and Ls. Regarding the needle direction, we found significant ($P<0.01$) variations in number of spermatids Es and Ls.

SI and SEI are considered for demonstration of the efficacy of spermatogenesis and are presented in Table 2. SEI was higher in TFNA smears of bucks of 7-13 mo of age. Whereas, SI was higher in TFNA smears of bucks in 14-24 mo age group. Insignificant variation was found in SEI and SI when needle direction was considered.

3.2. Observation

3.2.1. Trans-scrotal ultrasonography

After needle insertion into the testis a hyper-echoic area was seen (Figure 3a). A wavy hyper-echoic area was also identified in ultrasonography picture during aspiration (Figure 3b). There was no echogenic change in the echotexture of testis during monitoring after both uni-direction and multi-direction suction (Figure 3c). However one buck was identified having several hyper-echoic areas within the testis from the beginning (Figure 4) which might be microlith.

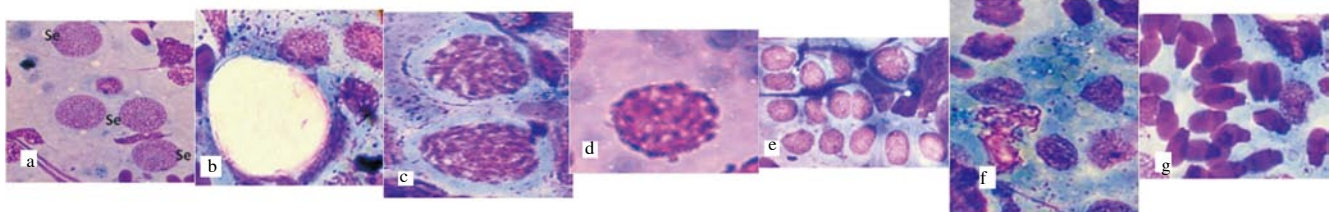


Figure 2. Photographic demonstration of different types of cells in TFNA samples; a) Sertoli cells b) spermatogonia c) primary spermatocyte d) Secondary spermatocyte e) early spermatid f) late spermatid g) spermatozoa

Table 1

Numerosity of spermatogenic cells (mean±SEM) in smear of TFNA regarding age and needle direction in bucks.

Groups	Needle direction	Sg		Ps		Ss		Es		Ls	
		LT	RT	LT	RT	LT	RT	LT	RT	LT	RT
7-13 mo	UD	2.2±1.1	0.9±0.5	14.6±5.4*	16.5±5.3*	0.6±0.3	0.2±0.1	58.3±8.7 ^a	82.3±13.2	25.8±3.8a	29.5±5.0
	MD	1.7±0.6	1.6±0.4	11.1±2.6	14.1±5.1*	0.3±0.2	0.2±0.1	75.8±14.2 ^{ab}	72.1±10.0 ^{**}	40.0±8.3b	32.7±5.7
14-24 mo	UD	1.9±0.4	1.6±0.5	9.4±0.7	4.5±1.0	0.5±0.2	0.3±0.2	79.5±6.4	81.2±7.9 ^a	40.2±2.5 ^{***a}	45.7±6.0*
	MD	2.0±0.5	0.3±0.2 ^b	9.7±1.8	6.2±1.7	0.3±0.5	0.3±0.1	88.3±7.9	54.0±9.0 ^b	52.1±4.4 ^{tb}	48.2±4.2*

^{a,b,c} Letters indicate significant variation between direction within age group ($P<0.05$). *Indicates significant variations in the same direction between two age groups. Sg- spermatogonia, Ps- primary spermatocytes, Ss- secondary spermatozoa, Es- early spermatids, Ls- late spermatids.

Table 2

Spermatic index (SI) and sertoli cell index (SEI) of TFNA smears in bucks.

Groups	Cells Needle direction	SI		SEI	
		LT	RT	LT	RT
7-13 mo	UD	10.3±3.4	10.8±4.2	26.7±5.3 ^{**}	23.6±3.0 ^{**}
	MD	8.7±2.8	9.6±3.2	21.4±7.5 ^{**}	19.1±3.7*
14-24 mo	UD	35.6±5.3 ^{**}	33.6±5.9 ^{**}	10.2±3.4	12.5±2.9
	MD	31.7±4.4 ^{**}	44.4±6.5 ^{**}	8.6±1.3	11.4±4.0

Values are mean±SEM. *Indicates significant ($P<0.05$) and ^{**}indicates highly significant ($P<0.01$), variations in the same direction between two age groups.

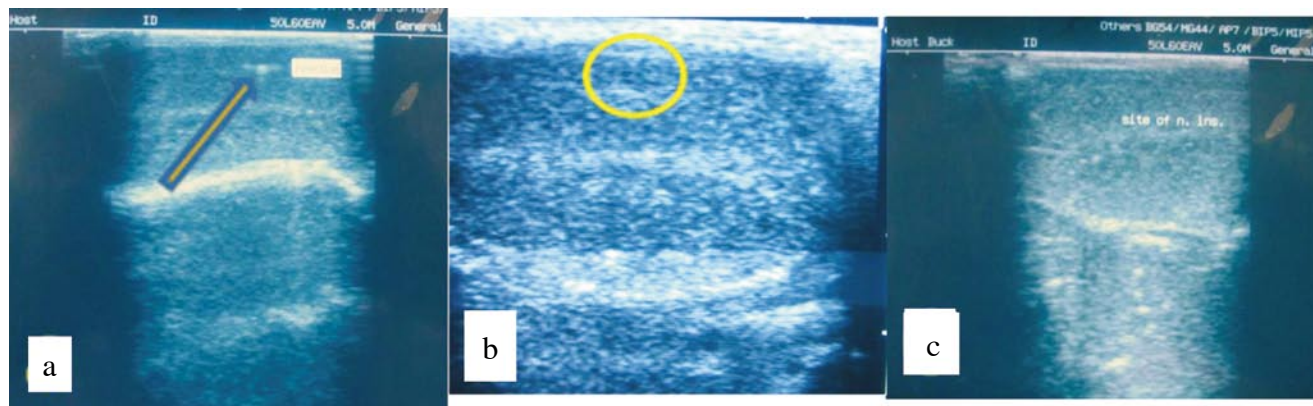


Figure 3. Presence of needle head within testis (a); a wavy hyper-echoic area (yellow) circle during aspiration (b); normal echotexture of testis after TFNA (c).

3.2.2. Testicular width and length

Testicular size was changed due to scrotal skin swelling, although there was no echotextural change observed in ultrasonophy monitoring. Swelling was not marked in testes after uni-direction suction, for this data were excluded. But, more swelling with pain was present after multi-direction suction, which disappeared within 2-4 d. Table 3 represents the changes in testicular size (length and width) which indicated the swelling after TFNA. Variations among the observations in testicular width and length were insignificant.

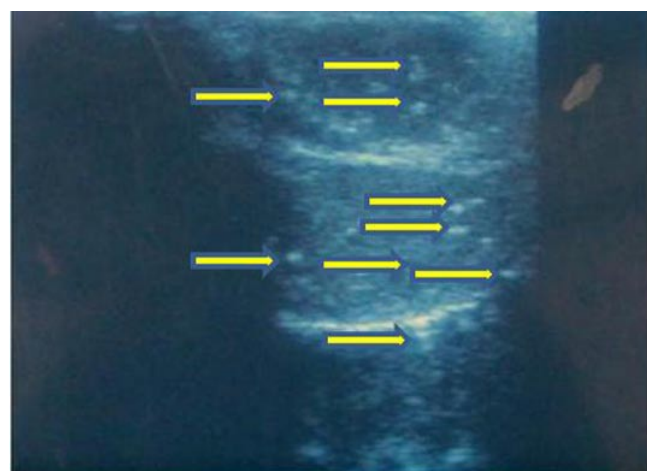


Figure 4. Presence of several hyperechoic areas in testis (Arrow head).

Table 3

Changes in testicular size after TFNA.

Observations	Width		Length	
	LT	RT	LT	RT
D ₀	3.5±0.3	3.4±0.3	5.1±0.4	5.3±0.5
D ₁	3.7±0.3	3.5±0.3	5.4±0.4	5.5±0.5
D ₂	3.7±0.3	3.5±0.3	5.4±0.4	5.4±0.5
D ₃	3.6±0.3	3.4±0.3	5.2±0.4	5.4±0.5
D ₄	3.6±0.3	3.4±0.3	5.2±0.4	5.4±0.4
D ₅	3.5±0.3	3.3±0.3	5.2±0.4	5.3±0.5
D ₆	3.6±0.1	3.4±0.1	5.2±0.2	5.3±0.2

Values are expressed as mean±SEM.

3.2.3 Cross sectional observation of testes after TFNA

After castration testes were examined carefully. No change of the testicular tissue was observed in testis of bucks after uni-direction suction of tissue. In contrast, marked bloody needle line was present in cross section of testis having multi-direction suction for TFNA .

4. Discussion

Reproductive soundness evaluation facilitates the elimination of sub-fertile sires from breeding programs. Proper clinical examination and reproductive analysis of male animals are necessary for evaluation of breeding soundness and infertility. Several techniques, e.g. testicular palpation, ultrasonography of reproductive organs and testicular biopsy can be performed during sire selection[20]. Generally, testicular biopsy has been used to evaluate and classify males with varying degrees of testicular failure[21] and it provides a definitive assessment of seminiferous tubule and interstitial cellular architecture[22]. Among different biopsy techniques, TFNA has gained increasing popularity as a painless, minimally invasive and cost-effective procedure, which can provide a more representative sample of the testis in much shorter time as compared to open biopsy[15]. There is limited study on the use TFNA in animals. The study was concentrated to evaluate ultrasound guided TFNA technique with uni and multi directions of tissue collection through qualitative and quantitative study of testicular tissues, echotexture observation of testes in buck.

In this study, spermatogenic cells were well characterized and were identified by their distinctive morphology described by Schenck and Schill[19]. Percentages from spermatogonia to late spermatids were increased showing a normal evolution of the spermatogenic process in smears. Considering the numerosity of cells, early spermatids were the most numerous in buck TFNA. We are unknown of data regarding testicular cytology in buck. However, Stelletta *et al.*[15] have reported higher number of early spermatocytes in Alpaca. In a study, Foresta and Varotto[23] reported greater numbers of late spermatids in cytological smears of men with normal fertility. The testis is an ideal organ for evaluation by FNA because of its uniform cellularity and easy accessibility[24]. The identified patterns represent histological diagnoses but are based on relative numbers of three easily identified germ cell types on cytologic assessment: primary spermatocytes, spermatids, and spermatozoa. The number of secondary spermatocytes was very small. This finding is in agreement with Stelletta *et al.*[15]. After production secondary spermatocytes rapidly divide to produce haploid spermatids (Meiosis II). The brevity of this stage means that secondary spermatocytes are rarely seen in histological studies and the small number might be due to their short life span[21]. Leydig cell was not observed in our study. Aspiration of interstitial tissue is difficult and hence Leydig cells are usually not visualized in the cytological smears[11,15].

Regarding the needle direction, authors found significant ($P<0.01$)

variations in number of early and late spermatids. It might be a result of technical process of preparing aspiration smears, which could be attributable to the usual counting technique. These findings may be a normal cytological finding for buck's testes, which needs a further confirmation. Spermiogenic Index demonstrates the efficacy of the spermiogenesis[23]. The relationship between spermatogenic and sertoli cell numbers or SEI has been studied as an indicator of tubular germ cell potential or the spermatogenesis efficiency[25,26]. In both testes, there were significant differences ($P>0.05$) between SEI obtained from bucks of two age groups. In both humans and horses, the number of sertoli cells is related to the level of spermatogenesis as measured as daily sperm production per testis This relationship is higher for horses ($r^2=0.68$) than for humans ($r^2=0.39$). The spermatogenic cells are in close contact with sertoli cells which are thought to provide structural and metabolic support to the developing sperm cells. Proliferation of sertoli cells is greatly reduced in the adult compared to the early proliferation rates prior to puberty[27].

In trans-scrotal ultrasonography, the testis of bucks appeared as a homogeneously hypoechogenic structure. The mediastinum testis was represented as a hyperechoic line in longitudinal images. These observations are similar to those described for boar[28], dog[29], bull[30], rams and male goats[17] and camels[31]. Ahmad *et al.*[32] recorded an increase in the echogenicity of testicular parenchyma with advancement in age of the bull; the mean number of pixels of testicular ultrasonograms increased significantly up to 24 mo of age and then leveled off as the age increased. One buck was identified having several hyperechoic areas within the testis from the beginning (Figure 4). These hyperechoic areas were assumed to represent mineralization in the testes. Ahmad *et al.*[33] and Ahmad and Noakes[5] observed hyperechoic areas in the testicular parenchyma of infertile bucks. According to Lenz and Giwerman[34], such bright echogenic spots were representing microlithiasis or microcalcifications.

Ultrasonography demonstrated hypoechoic areas inside the testicular parenchyma just after aspiration of the buck testis. Carpi *et al.*[35] also revealed similar hypoechoic areas in human testes during ultrasonography at the time of TFNA and denoted these areas as intra-testicular bleeding. This intra-testicular hemorrhage was evident in testicular cross section after the multi-directional suction has taken place. In this study, there was no echogenic change in the echotexture of testis during monitoring after both uni-direction and multi-direction suction (Figure 3c).

Testicular ultrasonography can be used as a diagnostic tool for acute scrotal pain to more chronic and nonspecific symptoms[36,37]. In animal studies trans-scrotal ultrasonography has been shown to demonstrate the ultrasonic morphology of testes of bulls[38], rams and boars[28]; to assess testicular trauma, evaluation of testicular swelling or masses[39], infertility[40], male hypogonadism[41], testicular interventions etc. It is also helpful not only for diagnosis of testicular torsion, cryptorchidism, scrotal hernia, varicocele but also follow-up of testicular microlithiasis[42].

Sperm production ability and fertility is largely depends on testicular size[43,45]. Length and width of testis or the total scrotal diameter is used to determine the size of the testis. Testicular size (wide and lengthy) was measured up to 5th day of post-aspiration. Swelling was not observed in testes after uni-direction suction, for this data were excluded. But, more swelling with pain was present

after multi-direction TFNA suction, which disappeared within 2-4 d. Following FNA in 7 dogs, there was no pain or local trauma[12]. The extent of testicular damage by multiple punctures and negative pressure applied during aspiration is still unknown[45,46]. The number of punctures and of excursions at each puncture site insignificant technical aspects of FNA[46]. Gouletsou *et al.*[46] observed skin hemorrhage and mild swelling of the scrotum immediately after multi-direction FNA at insertion point which lasted for 2-5 d post-aspiration days in cat. When castration was performed at 6th day post-aspiration, the entrance point of the needle could be detected on the surface of the testis. In multi-direction TFNA after testicular cross section, hemorrhagic areas were evident indicating the path of the needle inside the testicular parenchyma. Similar finding was reported by Gouletsou *et al.*[46].

This study confirms that TFNA can evaluate all classically defined histological types of spermatogenic cells. Though, swelling with pain and marked haemorrhagic areas was present in cross section of testis having multi direction suction for TFNA, there is no echogenic change in the echotexture of testis during monitoring after both uni-direction and multi direction suction. During this study, semen could not be collected and evaluated to correlate TFNA cytology with sperm production. However, further study should be performed to standardize the numerosity of testicular cells from TFNA smears in both fertile and infertile bucks considering age, breeding activities, seasonality and pathological influences. This study could help us for the assessment of function of testicular cells in determining breeding soundness of not only buck but also other male animals more effectively and efficiently.

The cytological appearance of testicular cells after TFNA can be well defined and early spermatids are the most numerous, followed by late spermatids, primary spermatocytes, spermatogonia in bucks. In case of indices Sertoli cell index is higher in TFNA smears of bucks of 7-13 mo of age and Spermiogenic index is higher in TFNA smears of bucks in 14-24 mo age. Insignificant variation is found in testicular cells when needle direction was considered. Testicular fine needle aspiration (TFNA) has no serious ill effect on the buck testis and uni-direction aspiration is advisable to study testicular cytology.

Conflict of interest statement

The authors declare that they have no conflict of interest.

Acknowledgements

The author is thankful to University Grant Commission (UGC) for National Science and Technology (NST) Fellowship and financial assistance. The author is also thankful to Dr. Md. Musharraf Uddin Bhuiyan, Professor, Department of Surgery and Obstetrics, Bangladesh Agricultural University, Mymensingh and honorable In-charge, Community-based Dairy Veterinary Foundation (CDVF), Bangladesh Agricultural University, Mymensingh for his affectionate encouragement and for the opportunity of examining prepared slide samples used in the research work. The author is also thankful to the Department of Surgery and Obstetrics to give ethical approval of the research work.

References

- [1] FAO. *The State of the world's animal genetic resources for food and agriculture*. Rome, Italy; 2011.
- [2] Hossain MA. *A study on the distribution pattern, rearing practices, milk production and reproductive performance of Black Bengal goats in some selected areas of Mymensingh district*. MS Thesis. Department of Dairy Science, Bangladesh Agricultural University, Mymensingh, Bangladesh; 2004.
- [3] Schurich M, Aigner F, Frauscher F. The role of ultrasound in assessment of male fertility. *Eur J Obstet Gynecol Reprod Biol* 2009; **144**(Suppl 1): 192-198.
- [4] Love CC. Ultrasonographic evaluation of the testis, epididymis, and spermatic cord of the stallion. *Veter Clin North Am: Equ Pract* 1992; **8**(1): 167-182.
- [5] Ahmad N, Noakes DE. Ultrasound imaging in determining the presence of testicular degeneration in two male goats. *Brit Vetery J* 1995; **151**: 101-110.
- [6] Mahajan AD, Imdad AN, Walwalkar SJ, Rege JD, Pathak HR. The role of fine-needle aspiration cytology of the testis in the diagnostic evaluation of infertility. *Brit J Urol Intern* 1999; **8**: 485-488.
- [7] Tibary A. *Testicular ultrasonography and biopsy in small ruminants and lambs*. In: Vancouver BC. Proceedings of the annual conference of the society for theriogenology. Canada; 2001, p. 369-378.
- [8] Tibary A. *Testicular biopsy*. In: Orlando, F.L., Proceedings of the North American Veterinary Conference; 2004, p. 297-298.
- [9] Agarwal MS, Gupta A, Chaturvedi K, Lavania P. Assessment of the utility of testicular FNAC in infertile males with special reference to differential counts. *Indian J Urol* 2004; **20**: 148-153.
- [10] Anˆdogˆan IA, Bayazıt Y, Yaman M, Ersoˆz C, Dora S. Fine needle aspiration cytology of the testis as the first-line diagnostic modality in azoospermia: A comparative study of cytology and histology. *Andrologia* 2003; **35**: 121-125.
- [11] Dahlbom M, Makinena NDJ, Suominen T. Testicular fine needle aspiration cytology as a diagnostic tool in dog infertility. *J Small Anim Prac* 1997; **38**: 506-512.
- [12] Romagnoli S, Bonaccini P, Stelletta C, Garolla A, Menegazzo M, Foresta C, et al. Clinical use of testicular fine needle aspiration cytology in oligozoospermic and azoospermic dogs. *Reprod Domestic Anim* 2009; **44**: 329-333.
- [13] Chapwanya A, Callanan J, Larkin H, Keenan L, Vaughan L. Breeding soundness evaluation of bulls by semen analysis, testicular fine needle aspiration cytology and trans-scrotal ultrasonography. *Irish Veter J* 2008; **61**: 315-318.
- [14] Leme DP, Papa FO. Cytological identification and quantification of testicular cell types using fine needle aspiration in horses. *Equine Veter J* 2000; **32**: 444-446.
- [15] Stelletta C, Juyena NS, Ponce Salazar D, Gutierrez G, Ruiz J. Testicular cytology of alpaca: Comparison between impressed and smeared slides. *Anim Reprod Sci* 2001; **125**: 133-137.
- [16] Larkin HA. Veterinary cytology-Fine needle aspiration of masses or swellings on animals. *Irish Veter J* 1994; **47**: 65-73.
- [17] Ahmad N, Noakes DE, Subandrio AL. B-mode, real time ultrasonographic imaging of the testis and the epididymis of sheep and goats. *Veter Record* 1991; **128**: 491-496.
- [18] Foresta C. *Citologia testicolare per agoaspirazione nella diagnostica dell' infertilit  maschile*. Piccin Nuova Libreria, Padova; 1993.
- [19] Schenck U, Schill WB. Cytology of the human seminiferous epithelium. *Acta Cytologica* 1988; **32**: 689-696.
- [20] Tibary J, Vaughan J. Reproductive physiology and infertility in male South American camelids: A review and clinical observations. *Small Ruminant Res* 2006; **61**: 283-298.
- [21] Papis Z, Katona G, Skrabalo Z. The cytologic identification and quantification of testicular cell subtypes. *Acta Cytologica* 1988; **32**: 697-706.
- [22] Turek PJ, Cha I, Ljung BM. Systematic fine-needle aspiration of the testis: correlation to biopsy and results of organ "mapping" for mature sperm in azoospermic men. *Urology* 1997; **49**: 743-748.
- [23] Foresta C, Varotto A. Assessment of cytology by fine needle aspiration as a diagnostic parameter in the evaluation of the oligospermic subject. *Fertil Steril* 1992; **58**: 1028-1033.
- [24] Meng MV, Cha I, Ljung BM, Turek PJ. Testicular fine needle aspiration in infertile men: Correlation of cytologic pattern with histology on biopsy. *Am J Surg Pathol* 2001; **25**: 71-79.
- [25] Griswold MD. Interactions between germ cells and Sertoli cells in the testis. *Biol Reprod* 1995; **52**: 211-216.
- [26] Blanchard TL, Johnson L. Increased germ cell degeneration and reduced germ cell: Sertoli cell ratio in stallions with low sperm production. *Theriogenology* 1997; **47**: 665-677.
- [27] Johnson L. Spermatogenesis and aging in the human. *J Androl* 1986; **7**: 331-354.
- [28] Cartee RE, Powe TA, Gray BW, Hudson RS, Kuhlert DL. Ultrasonographic evaluation of normal boar testicles. *Am J Veter Res* 1986; **47**: 2543-2548.
- [29] England GCW. Relationship between ultrasonographic appearance, testicular size, spermatozoal output and testicular lesions in the dog. *J Small Anim Prac* 1991; **32**: 306-311.
- [30] Cartee RE, Gray BW, Powe TA, Hudson RS, Whitesides J. Preliminary implications of Bmode ultrasonography of the testicles of beef bulls with normal breeding soundness examination. *Theriogenology* 1989; **31**: 1149-1157.
- [31] Pasha RH, Qureshi AS, Lodhi LA, Jamil H. Biometric and ultrasonographic evaluation of the testis of one-humped camel (*Camelus dromedarius*). *Pak Veter J* 2011; **31**: 129-133.
- [32] Ahmed RM, El-Khawaga, Mohamed MM, Kandiel Gamal A, Sosa Mahmoud EA, Abou El-Roos, et al. Ultrasound imaging of the testes and accessory sex glands in buffalo bulls treated with gonadotrophic releasing hormone. *J Reprod Infert* 2012; **3**(1): 8-16.
- [33] Ahmad N, Noakes DE, Middleton DJ. Use of ultrasound to diagnose testicular degeneration in a goat. *Veter Rec* 1993; **132**: 436-439.
- [34] Lenz S, Giwercman A. Carcinoma-in-situ of the testis: Is ultrasound of testes useful as a screening method? *J Med Ultr* 2008; **16**: 256-267.
- [35] Carpi A, Menchini, Fabris FG, Palego P, Di Coscio G, Romani R, Nardini V, et al. Fine-needle and large-needle percutaneous aspiration biopsy of testicles in men with nonobstructive azoospermia: Safety and diagnostic performance. *Fertil Steril* 2005; **83**: 1029-1033.
- [36] Fernandez-Usagre FJ, Rangel-Villalobos ME, Garcia de la Oliva A, Blanco Yun A. Doppler ultrasonography of scrotal injury. *Radiologia* 2007; **49**(3): 183-187.
- [37] Cokkinos DD, Antypa E, Kalogeropoulos I, Tomais D, Ismailos E, Matsiras I. Contrast-enhanced ultrasound performed under urgent conditions. Indications, review of the technique, clinical examples and limitations. *Insights Imaging* 2013; **4**(2): 185-198.
- [38] Eilts BE, Pechman RD. B-mode ultrasound observations of bull testes during breeding soundness examinations. *Theriogenology* 1988; **30**(6): 1169-1175.
- [39] Horstman WG. Scrotal imaging. *Urologic Clin North Am* 1997; **24**(3): 653-671.
- [40] Diamond DA, Zurakowski D, Bauer SB, Borer JG, Peters CA, Cilento BG. Relationship of varicocele grade and testicular hypotrophy to semen parameters in adolescents. *J Urol* 2007; **178**(4 Pt 2): 1584-1588.
- [41] Isidori AM, Giannetta E, Lenzi A. Male hypogonadism. *Pituitary* 2008; **11**(2): 171-180.
- [42] Karmazyn B. Scrotal ultrasound. *Ultr Clin* 2010; **5**: 61-74.
- [43] Bravo WP. Relationship between testicular size and fertility. *Alpaca Regis J* 1996; **1**: 45-46.
- [44] Galloway DB. *The development of the testicles in alpacas in Australia*. In: Proceedings of the Australian Alpaca Industry Conference. Canberra; 2000, p. 21-23.
- [45] Westlander G, Ekerhovd E, Granberg S, Lycke N, Nilsson L, Werner C, et al. Serial ultrasonography, hormonal profile and antisperm antibody response after testicular sperm aspiration. *Hum Reprod* 2001; **16**: 2621-2627.
- [46] Gouletsou PG, Galatosb AD, Siderib AI, Kostoulasc P. Impact of fine needle aspiration (FNA) and of the number of punctures on the feline testis: Clinical, gross anatomy and histological assessment. *Theriogenology* 2012; **78**: 172-181.