

Inflammatory Myofibroblastic Tumor of the Liver: A Case Report with Immunohistochemical and Ultrastructural Study

Tuenjai Chuangsuwanich, M.D.*, Kleophant Thakerngpol, M.Sc.*, Nusara Chomanee, B.Sc.*, Anchalee Aramtiantamrong, M.D.**,
Pichamonch Pengvanich, M.D.***, Mongkol Laohapensang, M.D.***

*Department of Pathology, ***Department of Surgery, Faculty of Medicine Siriraj Hospital, Mahidol University, Bangkok 10700, **Department of Pediatrics, Nopparatjathane Hospital, Bangkok, Thailand.

ABSTRACT

We report a case of hepatic inflammatory myofibroblastic tumor in an 11-year-old boy presented with chronic pyrexia. Investigations revealed anemia, leukocytosis, thrombocytosis, increased C-reactive protein and a liver mass. The resected 7 cm., mass displayed myofibroblastic proliferation with ganglion-like morphology within dense chronic inflammatory background. The diagnosis was confirmed with immunoperoxidase and ultrastructural study.

Keywords: Inflammatory myofibroblastic tumor, ganglion-like, liver, ultrastructure, intracytoplasmic inclusion

Siriraj Med J 2014;66:45-48

E-journal: <http://www.sirirajmedj.com>

INTRODUCTION

Inflammatory myofibroblastic tumor (IMT) is a rare lesion characterized by myofibroblastic proliferation in a chronic inflammatory background. The tumor first described in the lung as an inflammatory pseudotumor has later been recognized in extrapulmonary sites.¹ The patients may present with a clinical syndrome of fever, malaise and weight loss with mass in the involved organ and abnormal laboratory findings related to reactive inflammatory response.

Childhood hepatic IMT is rare. We report the first published case in Thailand with an ultrastructural study proven for myofibroblast.

CASE REPORT

An 11-year-old boy was referred to Siriraj Hospital for proper management of his liver mass. He presented with a high-graded fever for 1 month without any specific symptom. Physical examination revealed moderate anemia

without jaundice, hepatosplenomegaly nor lymphadenopathy. Laboratory findings revealed white blood cell count, 15,650/mm³ with 72% neutrophils, thrombocytosis (platelet count, 643,000/mm³) and hypochromic microcytic anemia (hematocrit, 21%). Bone marrow aspiration was normal. All liver function tests were within normal limits except for hypergammaglobulinemia (albumin/globulin, 2.9/4.8 g/dl). C-reactive protein was slightly elevated (CRP>120 mg/L; normal value, <5). Serum AFP and β -hCG levels were normal. Other laboratory findings included LDH of 191 U/L. Serologic tests for leptospirosis, EBV, melioidosis, human immunodeficiency virus, cytomegalic inclusion disease and mycoplasma infection were unremarkable, and negative for malarial parasite. Antinuclear antibody was positive and rheumatoid factor was negative. Initially, he was treated with intravenous antibiotics for 1 week. Abdominal CT with contrast revealed hepatomegaly with a slightly hypodense, homogeneous, 7x7x6 cm mass in segment 3 without internal calcification and less enhancement than in normal liver. Hepatic and portal veins were intact. No lymphadenopathy was detected. (Fig 1A)

Left lateral hepatic segmentectomy was performed and revealed a protruding subcapsular well-circumscribed mass at the inferior surface of segment 3. The remaining liver was unremarkable.

Correspondence to: Tuenjai Chuangsuwanich

E-mail: tuenjai_ch@yahoo.com

Received 20 November 2013

Revised 16 January 2014

Accepted 17 January 2014

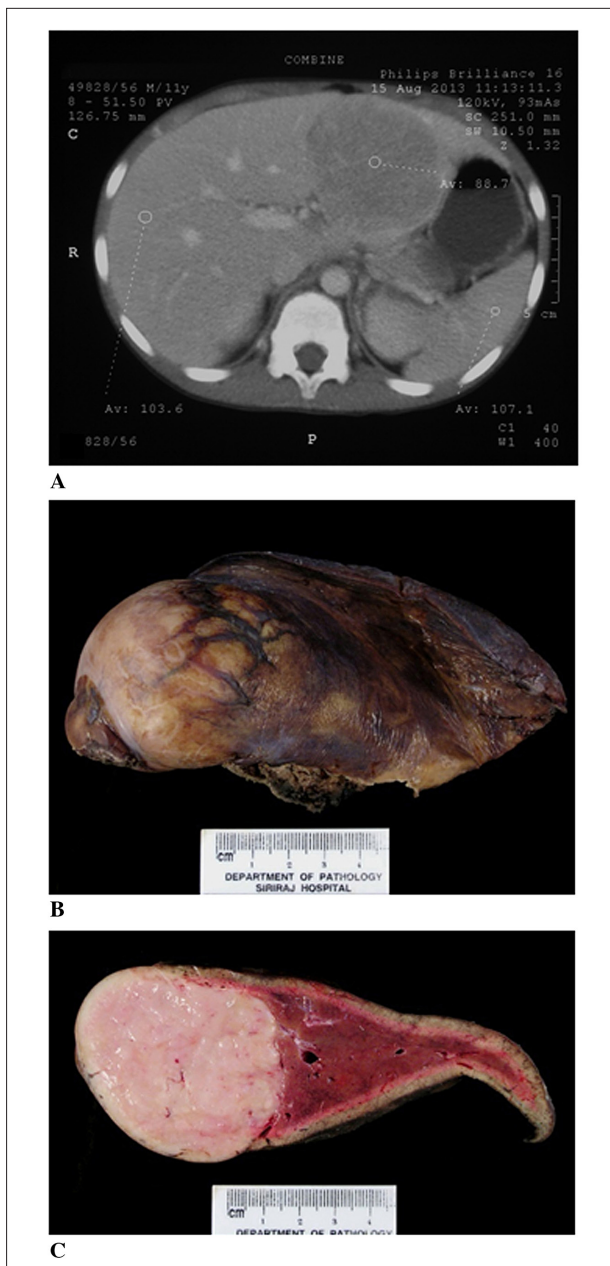


Fig 1. A) Computed tomography scan of the liver showing a hypodense mass. B&C) Tumor mass with normal remaining liver

Pathologic findings

The specimen measured 13.5x8x6.5 cm and weighed 280 g. The liver capsule was intact with focal bulging area. Serial sectioning revealed a 7.5x6x6 cm, round and well-circumscribed mass, homogeneous white-tan and soft to rubbery in consistency. (Fig 1B, 1C). The surgical resection margin was free. Remaining liver parenchyma showed no remarkable change.

Microscopically, the mass consisted of many large polygonal and spindle cells set in a profuse inflammatory background (Fig 2A). The tumor cells had eccentric vesicular nuclei with prominent nucleoli with some ganglion-like cells and bi or multinucleation and 0-1 mitotic figures/10 high power fields. Few cells exhibited intracytoplasmic PAS-eosinophilic inclusions (Fig 2B). By immunoperoxidase tumor cells were strongly reactive

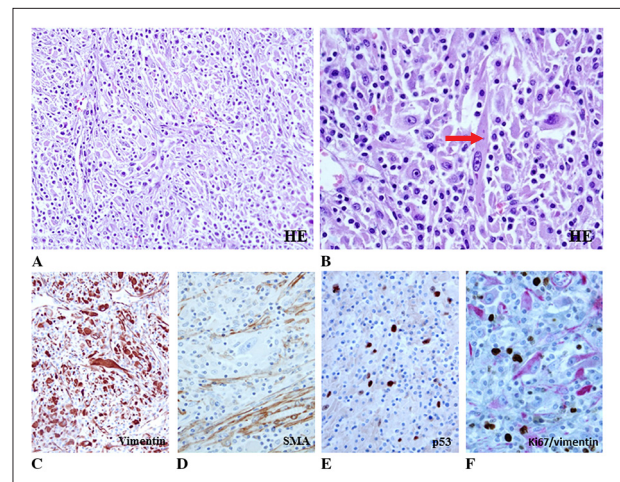


Fig 2. A&B) H&E stain demonstrating elongated, polygonal, and ganglion-like tumor cells admixed with lymphocytes, plasma cells and histiocytes. Few cells with intracytoplasmic inclusions (arrow). C-E) Immunoperoxidase study: vimentin(+); smooth muscle actin (SMA, rare, weak), p53(+). F) Dual immunostains with Ki67 (nuclear, brown color) and vimentin (cytoplasmic, red color) demonstrating no Ki67 activity of polygonal tumor cells, indicative of low proliferation activity.

for vimentin, weakly and rarely reactive for smooth muscle actin (Fig 2C, 2D), muscle specific actin, and desmin; negative for smooth muscle myosin heavy chain and myogenin, but reacted for CD10, and negative for CD34, epithelial markers [cytokeratin(CK)8/CK18, CK5/CK6, CK19, and epithelial membrane antigen (EMA)], S-100 protein, CD21, CD23, CD138, CD30, CD117, and CD68. They were negative for ALK1 (anaplastic lymphoma kinase-1), IgG4 and Epstein-Barr virus. Also p53 was moderately diffusely reactive (Fig 2E). The inflammatory cells comprised admixture of polymorphic lymphoid cells with predominant T-cells without abnormal T4 or T8 predilection, plasma cells, numerous histiocytes and some dendritic cells. Ki67 proliferation index was very low (Fig 2F). Special stains for microorganism (Gram, GMS and AFB) were negative. The results suggested an inflammatory myofibroblastic tumor with dominant fibroblastic differentiation. There was no entrapped hepatobiliary tissue. The remaining liver parenchyma displayed some chronic inflammatory cell infiltration in the portal tract only at the area near the tumor focus. Due to the very minimal reactivity of smooth muscle markers in the ganglion-like cells we performed an ultrastructural study by using paraffin embedded tissue. The elongated and large rounded cells contained many swollen mitochondria, cisternae of rough endoplasmic reticulum and some parallel bundles of longitudinally oriented microfilaments of 9 nm in diameter with a few associated dense bodies. A few large intracytoplasmic nonmembrane-bound aggregates of microfilaments were noted. (Fig 3)

Postoperatively, the patient recovered well after a few days with CRP 11.95 mg/ml, and ESR 85 mm/hr (normal value, 0-15) on the ninth day. He had no fever, did not receive any treatment and has been well without any abnormal laboratory tests 8 weeks after postoperation.

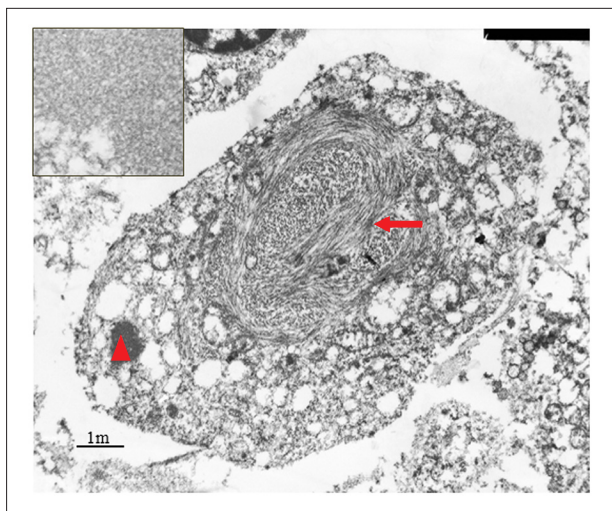


Fig 3. Ultrastructure of tumor cells showing intermediate filaments, microfilaments and some rough endoplasmic reticulum: arrow indicates dense body on microfilaments. Inset magnifying nonmembrane bound particle (arrow head, \blacktriangle) showing long and cross-sections of microfilaments; this particle is comparable to intracytoplasmic inclusion at light microscopy.

DISCUSSION

IMT is an uncommon tumor occurring in all age groups though more prevalent in children. Its pathogenesis is still uncertain with the majority of cases being idiopathic. A few may be related with preexisting or associated illnesses including infection and some immunological disorders either autoimmune or immunodeficiency diseases.² It is considered as a neoplasm of an intermediate biologic potential according to the WHO classification of soft tissue tumors, usually with benign clinical course and a few exceptional cases showing recurrence or metastasis.^{1,2} The tumor has no radiological characteristics and may mimic a malignant tumor. One of the supports that this lesion is a neoplasm among the spectrum of the inflammatory pseudotumors is a clonality associated with the ALK gene. More than 50% of the cases have ALK rearrangements with other genes resulting in overexpression of ALK1 protein showing either smooth or granular cytoplasmic, or strong membrane or uncommonly a nuclear membrane staining. It is still uncertain to predict the clinical outcome based on the existence or absence of the ALK1 protein as some gene fusions have been reported to correlate with good clinical course and others with aggressiveness.¹⁻⁴ Other factors postulated to be associated with aggressive IMT were cellular atypia, ganglion-like cells, p53 expression and aneuploidy, although in some studies such a relation could not be determined.² A combination of several factors including etiology, tumor size, location, involvement of adjacent vital structures, reactivity to ALK1 and types of ALK fusion partner could be related to the clinical outcome. The management depends on the involved organ and the etiology with surgery as the principle treatment. Regression either spontaneously or after nonsteroidal anti-inflammatory or corticosteroid

treatment and targeted therapy to the aggressive tumor with positive ALK1 protein has been reported.^{1,5}

Hepatic IMT accounted for 0.2% of 1,403 resected liver masses.⁶ According to the review of 35 pediatric liver IMTs by Nagarajan, et al,⁷ and 6 additional cases⁸ including one from ours, the age ranged 3-15 years, fever present in 41.7%; anorexia, weight loss and night sweats less than 17%, abdominal pain in 39% and abdominal mass in 24.3%. Most had idiopathic etiology, and one case was associated with *Mycobacterium tuberculosis*. The tumors ranged from 2 to 14 cm in size. In nearly half of the cases, either singly or in combination, elevated white blood cell count, ESR and CRP were present. The major treatment included surgery a few of which need liver transplantation.⁸ All reported cases recovered.

Our case had typical clinical and laboratory features of IMT. The histopathology including immunoperoxidase and the ultrastructural study confirmed a tumor of myofibroblast with profuse chronic inflammatory background and could exclude many tumors in its differential diagnoses. To the best of our knowledge the presence of intracytoplasmic inclusions in IMT which were consistent with aggregates of microfilaments has not been reported before.⁹ The etiology of the disease was not identified based on the serology and histopathology. Apart from the morphology of the ganglion-like cells there were not any worrisome features (no necrosis, active mitosis or increased proliferation activity). The presence of p53 immunoreactivity was not considered as an aggressive predictor.² Total removal of the tumor was effective. Laboratory parameters used to follow up include complete blood count, ESR, C-reactive protein level and ultrasound. Since the disease is uncommon with limited experience, long term follow up is still required.

CONCLUSION

IMT should be in the differential diagnosis in a child or young adult with mass lesion presenting with pyrexia, anemia, thrombocytosis and increased C-reactive protein.

ACKNOWLEDGMENTS

The authors appreciate the assistance of Assistant Professor Suchart Benjarussamerroj for the review of the diagnosis and Mutita Sivakronnest for the preparation of the photographs.

REFERENCES

1. Coffin CM, Fletcher JA. Inflammatory myofibroblastic tumour. In: Fletcher CDM, Unni KK, Mertens F, editors. Pathology and genetics of tumors of soft tissue and bone. Lyon: IARC Press; 2002.p.91-93.
2. Coffin CM, Hornick JL, Fletcher CD. Inflammatory myofibroblastic tumor: comparison of clinicopathologic, histologic, and immunohistochemical features including ALK expression in atypical and aggressive cases. *Am J Surg Pathol*. 2007 Apr;31(4):509-20.

3. Cook JR, Dehner LP, Collins MH, Ma Z, Morris SW, Coffin CM, et al. Anaplastic lymphoma kinase (ALK) expression in the inflammatory myofibroblastic tumor: a comparative immunohistochemical study. *Am J Surg Pathol*. 2001 Nov;25(11):1364-71.
4. Chen ST, Lee JC. An inflammatory myofibroblastic tumor in liver with ALK and RANBP2 gene rearrangement: combination of distinct morphologic, immunohistochemical, and genetic features. *Hum Pathol*. 2008 Dec;39(12):1854-8.
5. Butrynski JE, D'Adamo DR, Hornick JL, Dal Cin P, Antonescu CR, Jhanwar SC, et al. Crizotinib in ALK-rearranged inflammatory myofibroblastic tumor. *N Engl J Med*. 2010 Oct 28;363(18):1727-33.
6. Torzilli G, Inoue K, Midorikawa Y, Hui AM, Takayama T, Makuuchi M. Inflammatory pseudotumors of the liver: prevalence and clinical impact in surgical patients. *Hepatogastroenterology*. 2001 Jul-Aug;48(40):1118-23.
7. Nagarajan S, Jayabose S, McBride W, Prasad I, Tanjavur V, Marvin MR, et al. Inflammatory myofibroblastic tumor of the liver in children. *J Pediatr Gastroenterol Nutr*. 2013 Sep;57(3):277-80.
8. Kim SJ, Kim WS, Cheon JE, Mi SS, Youn BJ, Kim IO, et al. Inflammatory myofibroblastic tumors of the abdomen as mimickers of malignancy: imaging features in nine children. *Am J Roentgenol*. 2009 Nov;193:1419-24.
9. Pettinato G, Manivel JC, De Rosa N, Dehner LP. Inflammatory myofibroblastic tumor (plasma cell granuloma). Clinicopathologic study of 20 cases with immunohistochemical and ultrastructural observations. *Am J Clin Pathol*. 1990 Nov;94(5):538-46.