

# An Innominate Muscle in Popliteal Region: Clinical Exposition

Alok Saxena, M.Sc.\*, Sachin Soni, M.S.\*\*, Tuhin Ghulyani, MS.\*\*, Amal Rani Das, MS.\*\*\*

\*Senior Resident, \*\*Assistant Professor, \*\*\*Professor

Department of Anatomy, Veer Chandra Singh Garhwali Government Medical Science & Research Institute, Srikot, Uttarakhand, India.

## ABSTRACT

Variations are important findings for anatomists, radiologists and surgeons. Variations may be either skeletal or neurovascular. It may simulate the normal/abnormal (malignant) structures and misguide the radiologists and surgeons during diagnostic and surgical procedures. Hence, it becomes essential to disseminate the knowledge of variations. Keeping this in mind, we report a case of a third head of gastrocnemius in a male cadaver. This muscle was observed in the right popliteal fossa, arising from lateral condyle of femur and merging with two heads of gastrocnemius.

**Keywords:** Caput tertium, gastrocnemius tertius, popliteal vascular entrapment syndrome

Siriraj Med J 2013;65:85-87

E-journal: <http://www.sirirajmedj.com>

## INTRODUCTION

Variations are not uncommon in the popliteal region and are usually identified during diagnostic procedures, surgeries and dissection. We incidentally found an aberrant muscle in a right popliteal fossa. Muscles of the posterior compartment of legs are assembled in two groups; the superficial group consists of gastrocnemius, plantaris and soleus whereas the deep group contains popliteus, tibialis posterior, flexor digitorum longus and flexor hallucis longus.<sup>1</sup> The genetic composition of an individual is responsible for the muscular variation. Most variations are benign and some are due to miscalculation of developmental timing.<sup>2</sup>

The popliteus, plantaris and gastrocnemius are more likely to present variations. Popliteus has its tendinous origin from a depression on the lateral aspect of the lateral femoral condyle and inserts into a medial triangular area above the soleal line on the posterior tibial surface. Plantaris, a 7-10 cm long fusiform belly originates from the lower lateral supracondylar line and oblique popliteal ligament and ends in a long slender tendon fusing with the tendoachilles. Gastrocnemius takes its origin by two heads from corresponding femoral condyles. The upper

and posterior part of the medial condyle along with the popliteal surface of the femur offers the origin to the medial head. Lateral head arises from the lateral surface of the lateral condyle. The fleshy part of the muscle pulls out and up to the middle portion of the calf and gradually inserts into the broad aponeurosis terminating in the tendon of soleus and forms tendo calcaneus or tendoachilles.<sup>1</sup>

## CASE REPORT

We observed an anomalous muscle during routine dissection curriculum in the department of Anatomy, VCSG Government medical science and research institute. The dissected cadaver was an unclaimed male body, age around 45 years, brought to the college after completing all legal formalities applicable under the laws of our country. This anomalous muscle was commencing from the posterior surface of the lateral condyle of the right femur, crossing the knee joint and merging with the medial part of the lateral head of gastrocnemius ( $G_L$ ). The medial and lateral heads of the gastrocnemius were incised near their origin to clearly visualize the muscle (Fig 1). This anomalous muscle was closely related and posterior to the popliteal vessels (Fig 2). A branch from the tibial nerve was supplying this slip from its deep surface. This muscle was identified as a third head of gastrocnemius. Morphometric analysis of this muscle revealed its length was 12.2 cm, maximum width 1.3 cm and maximum thickness of 1 cm. Pictorial documentation of anatomical landmarks was done.

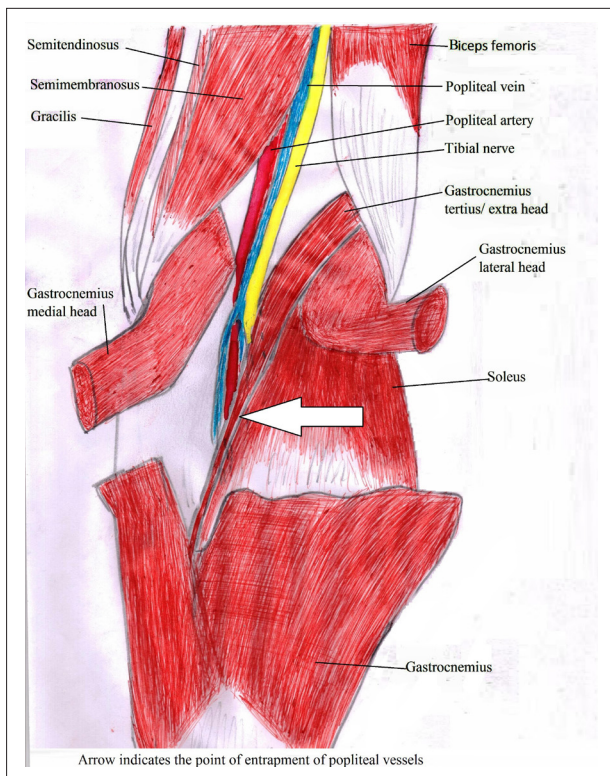
Correspondence to: Alok Saxena

E-mail: [alok.sxna@gmail.com](mailto:alok.sxna@gmail.com)

Received 9 November 2012

Revised 19 March 2013


Accepted 10 March 2013



**Fig 1.** Showing medial and lateral head of Gastrocnemius ( $G_M$ ,  $G_L$ ) in right knee. Note the Gastrocnemius Tertius ( $G_T$ ) merging with lateral head of gastrocnemius ( $G_L$ ).

## DISCUSSION

It is not uncommon to find variations in the popliteal region. We found a third head of gastrocnemius or gastrocnemius tertius ( $G_T$ ) or caput tertium in this region. It may mimic an additional head of the popliteus with dual origin from the plantaris. The interest of clinicians in the popliteus was first developed by Last 1948 and 1950. A cadaveric study done by Bartonicek showed two heads of popliteus on both knees.<sup>3</sup>



**Fig 2.** Posterior relationship of  $G_T$  with popliteal vein ( $P_V$ ) and popliteal artery ( $P_A$ ). Gastrocnemius Tertius ( $G_T$ ) was reflected to visualize these vessels.

The plantaris muscle shows extensive variability. It may arise from fascia covering the popliteus, the origin of lateral head of gastrocnemius ( $G_L$ ), fibula between flexor hallucis longus and fibularis longus or fascia cruris.<sup>4</sup> It sometime presents as an accessory head. As discussed in literature, one slip was arising from the lower lateral supracondylar line and other from the posterior surface of the lateral femoral condyle with its few fibres merging with the  $G_L$ .<sup>5</sup> Plantaris has been observed taking origin from the lateral retinaculum in 19 knees examined using MRI.<sup>6</sup>

The medial and lateral heads of the gastrocnemius usually arise from the corresponding condyles of a femur but a  $G_T$  may arise from a linea aspera, long head of biceps femoris, lateral femoral epicondyle, knee joint capsule, and the mid part of fibula or fascia of leg.<sup>7</sup> The  $G_T$  arising from the popliteal surface and lower part of the medial supracondylar ridge was observed in a cadaver. It was inserting into the medial head of the gastrocnemius ( $G_M$ ).<sup>2,8</sup> Another cadaveric study showed two bellies of  $G_T$  on the left side, and the superficial belly was originating from a part just above the plantaris tendon and the deep belly from the same tendon. The former was inserted into the outer aspect of  $G_L$  and the latter into the inner aspect of the  $G_M$ . The same study revealed another  $G_T$  on the right side arising from the lateral condyle of the femur and inserted into the  $G_M$ .<sup>7</sup> An MRI study conducted on 1,039 patients exposed 21  $G_T$ s. The beginning of  $G_T$  was from the midline of the posterior distal femur and inserted into either the medial or lateral head of the gastrocnemius or by joining confluence of both heads.<sup>6</sup> The gastrocnemius develops from upward migration of the calcaneum blastomere towards the inferior femoral epiphysis. The medial head gets its attachment a little higher than the lateral head. Congenital growth of excess muscle results in  $G_T$ .<sup>7</sup>

Popliteal vascular entrapment syndrome, a rare disorder can cause calf claudication, aneurysm formation, distal arterial emboli or popliteal vessel thrombosis.<sup>9</sup> Several authors have proposed the factors causing popliteal artery entrapment syndrome mostly by the  $G_M$  or by its anomalous slip.<sup>10-12</sup> An abnormal slip of the gastrocnemius can cause both popliteal artery and vein entrapment.<sup>13</sup> Liu et al presented a case showing popliteal vascular entrapment by aberrant slip of the  $G_L$ .<sup>9</sup>

We verified this muscle as  $G_T$  after careful citations of previous literatures. We conclude that  $G_T$  can cause popliteal vascular syndrome since it is in close relation with the popliteal vessels and can compress them. It is an important finding for radiologists and surgeons to deal with popliteal vascular syndrome. Variations are equally important for anatomists to enhance the knowledge of students.

## REFERENCES

1. Standring S. Gray's Anatomy (40<sup>th</sup> ed). Churchill Livingstone, London, 2008. p.1407-21.
2. Singla RK, Gupta R. Caput Tertium Gastrocnemius: A Case Report. JCDR. 2012; 6(6):1059-61.

3. Bartonicek J. Rare Bilateral Variation of the Popliteus Muscle. *Anatomical Case Report and Review of the Literature. Surg Radiol Anat.* 2005 Nov; 27(4):347-50.
4. Bergman RA, Afifi AK, Miyauchi R. *Illustrated Encyclopedia of Human Anatomic Variation: Opus I: Muscular System: Plantaris* <http://www.anatomyatlases.org/AnatomicVariants/MuscularSystem/Text/P/29Plantaris.shtml> (Last cited on 20th November 2012)
5. Upasna, Kumar A. Bicipital Origin of Plantaris Muscle: A Case Report. *Int J Anat Variation.* 2011; 4:177-9.
6. Koplas MC, Grooff P, Piraino D, Recht M. Third Head of the Gastrocnemius: An MR Imaging Study Based on 1,039 Consecutive Knee Examinations. *Skeletal Radiol.* 2009 Apr;38(4):349-54.
7. Yildirim FB, Sarikcioglu L, Nakajima K. The Co-existence of the Gastrocnemius Tertius and Accessory Soleus Muscles. *J Korean Med Sci.* 2011 Oct;26(10):1378-81.
8. Sharma P, Arora A, Sharma R, Salwan SK. Caput Tertium Gastrocnemius: Its Phylogenetic and Clinical Basis. *IJABPT* 2011; 2(4):380-3.
9. Liu PT, Moyer CA, Huettl EA, Fowl RJ, Stone WM. Popliteal Vascular Entrapment Syndrome Caused by a Rare Anomalous Slip of the Lateral Head of the Gastrocnemius Muscle. *Skeletal Radiol.* 2005 Jun;34(6):359-63.
10. Bouhoutsos J, Daskalakis E. Muscular Abnormalities Affecting the Popliteal Vessels. *Br J Surg.* 1981 Jul;68(7):501-6.
11. Murray A, Halliday M, Croft RJ. Popliteal Artery Entrapment Syndrome. *Br J Surg.* 1991 Dec;78(12):1414-9.
12. Scheepers PA, Khan N, Vermeulen WJN. A Case of Popliteal Artery Entrapment. *SA J Radiol.* 2004. p. 27-9.
13. Rich NM, Hughes CW. Popliteal Artery and Vein Entrapment. *Am J Surg.* 1967 May;113(5):696-8.