



# Magnetic resonance spectroscopy for quantitative analysis of fatty liver disease: a systematic review

Maryam Tavakoli (MD)<sup>1,2</sup>, Donya Farrokh (MD)<sup>\*2,3</sup>

<sup>1</sup>Department of Radiology, Faculty of Medicine, North Khorasan University of Medical Sciences, Bojnord, Iran.

<sup>2</sup>Surgical Oncology Research Center, Mashhad University of Medical Sciences, Mashhad, Iran.

<sup>3</sup>Department of Radiology, Faculty of Medicine, Mashhad University of Medical Sciences, Mashhad, Iran.

### ARTICLE INFO

#### Article type

Systematic review article

#### Article history

Received: 6 Dec 2015

Revised: 12 May 2016

Accepted: 13 Jul 2016

#### Keywords

Fatty liver

Magnetic Resonance Spectroscopy

Steatohepatitis

### ABSTRACT

**Introduction:** Magnetic resonance spectroscopy (MRS) is a sensitive and non-invasive imaging method that provides information about the metabolite variations due to pathological damages. In this study, we aimed to systematically review studies in which the MRS had been used for quantitative analysis of steatohepatitis.

**Methods:** PubMed and Scopus were methodically searched in June 2015 with following search method (((magnetic resonance spectroscopy OR MR spectroscopy OR MRS)) AND (hepatic steatosis OR steatohepatitis OR fatty liver)) AND Quantitative) to find relevant documents in which the diagnostic value of MRS had been investigated in patients with hepatic steatosis. Obtainable information were extracted and used for further evaluation based on the main purpose of this study.

**Results:** Of 88 articles found in the PubMed and 328 found in the Scopus, only 10 relevant documents were selected and used for data extraction according to inclusion/exclusion criteria. Of total 2963 participants enrolled in the selected studies, 1428 were male and 1535 were female. The results of this review showed that MRS is reliable technique for quantitative assessment of steatohepatitis.

**Conclusion:** Findings showed that MRS as a non-invasive imaging method can quantitatively determine even small changes of metabolites due to pathological damages. As well, findings suggested that the results obtained by MR spectroscopy can be considered as reference standard in quantitative analysis. Based on the results of studied documents, MRS as a sensitive tool is helpful in the quantitative assessment of patients with fatty liver disease.

Please cite this paper as:

Tavakoli M, Farrokh D. Magnetic resonance spectroscopy for quantitative analysis of fatty liver disease: a systematic review. *Rev Clin Med.* 2017;4(2):45-49.

## Introduction

Nonalcoholic fatty liver, commonly known as hepatic steatosis, is a liver inflammation caused by excessive accumulation of the fat in the liver cells (1). In fatty liver disease, hepatic accumulation of excess fat often leads to impaired normal functioning of the liver, which can cause rapid progression of liver failure, liver cirrhosis and other hepatic infections (2,3). Although the main cause of fatty liver disease is unknown, but it is suggested that the disease is closely associated with some metabolic disorders such as obesity, diabetes, and high cho-

lesterol as well as high blood triglycerides (4). Fatty liver disease is divided into three main categories of alcoholic, and nonalcoholic fatty liver and acute fatty liver of pregnancy (AFLP), which is a rare but potentially fatal condition of liver complication (5). Alcohol and some particular drug consumption as well as some metabolic disorders can be considered as the main possible causes of hepatic steatosis. In recent years, the prevalence of obesity and metabolic disease in the population, especially among young people is considerably increased

**\*Corresponding author:** Donya Farrokh.

Surgical Oncology Research Center, Mashhad University of Medical Science, Mashhad, Iran.

**E-mail:** farrokh@umms.ac.ir

**Tel:** 09155101417

This is an Open Access article distributed under the terms of the Creative Commons Attribution License (<http://creativecommons.org/licenses/by/3.0>), which permits unrestricted use, distribution, and reproduction in any medium, provided the original work is properly cited.

(6,7). About 10 to 20 percent of people in the United States suffer from this disease, and most cases of fatty liver are diagnosed between the ages of 50 to 60 years (7).

Fatty liver is not specific to any particular age or sex, and it may be observed even in children, especially those who have related genetic disorders. However, the incidence of the disease may rise in elderly, because fat and blood sugar is increased in these populations. Although some symptoms such as fatigue and pain in the upper-right abdomen is common in all patients; but, the most important problem is that there is no major clinical symptoms for fatty liver, and the disease can only be diagnosed by biochemical testing or ultrasound (8,9). Considering that in different pathologies the amounts and proportions of detectable metabolites varies, it is possible to determine the type of lesion and the progression of pathologies by measuring these metabolites. Major clinical examinations that are used to determine the risk of fatty liver include blood tests, imaging, and testing of liver tissue. Magnetic resonance spectroscopy (MRS) can be effectively used in diagnosis of pathological lesions, diabetes, and malignancies by detection of metabolites in the damaged area (10). Previously, such information had been obtained only through the biopsy, which is a difficult, time-consuming and sometimes dangerous procedure. In recent years, these data can be obtained in a few minutes by using MRS as a completely non-invasive and harmless technique. Findings show that MRS is a suitable technique to determine liver damages such as hepatic steatosis. In this study, we aimed to systematically review the literatures in which the MRS had been used to determine hepatic steatosis quantitatively.

## Methods

### Search methods

All articles in which the MRS had been used to diagnose hepatic steatosis were searched in the PubMed and Scopus as two major databases. For this purpose, these databases were searched using the key terms “magnetic resonance spectroscopy”, and “hepatic steatosis”. Following search strategy “(((magnetic resonance spectroscopy OR MR spectroscopy OR MRS)) AND (hepatic steatosis OR Steatohepatitis OR fatty liver)) AND Quantitative)” was used to find related documents in which the fatty liver disease had been quantitatively diagnosed using MRS. Google Scholar and Google search engine were searched as well with the previously described search method to include other possible relevant articles. The databases search was completed on June 2015. As well, relevant articles found through manually reference list searching of previously collected articles were also included to

reduce the data loss.

### Study selection and inclusion/exclusion criteria

To avoid any possible errors and misinterpretation of data in all processes of data extraction, only English articles were selected and used for further evaluation. Articles with various types of study designs were collected and included for further data collection. But, letters, case reports, editorials, conference papers, review articles and meta-analysis were excluded from further evaluation. The records were then limited to those studies, which were conducted on human. Thus, studies conducted in vitro or on animal models were subsequently excluded from further assessment. Those studies in which MRS had been used to detect pathological changes other than hepatic steatosis were also excluded from further assessment. As well, to avoid data loss in further processes of data analysis, articles with full text unavailability were omitted during article selection. No time limitation was defined for literature search. Therefore, the general inclusion criteria for article selection were all English documents in which the practicality of MRS technique had been evaluated to detect hepatic steatosis in patients with fatty liver disease. For further evaluation of the papers in detail, articles with subject or language irrelevancy, as well as documents with duplicated data were excluded by reviewing the title, keywords and abstract of selected literatures.

### Data extraction

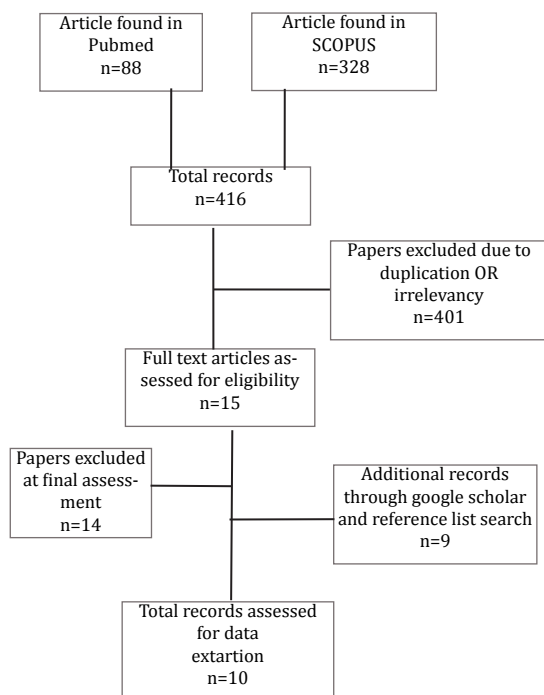
Data including the date of publication, the name of first author, the country of study, study design, method of assessment and other available critical findings were extracted and used for data synthesis based on the main purpose of this study. All other obtainable information including total number of participants and demographic data of studied populations were collected as possible regarding the previously defined inclusion and exclusion criteria. Data were categorized based on the findings of selected documents reporting the sensitivity and usefulness of MRS technique for quantitatively and correctly detection of fatty liver disease. All processes including articles selection and data extraction were performed with standard protocol by two independent reviewers according to the recommendation of PRISMA 2009 checklist (11). The authors tried to resolve any possible discrepancies before proceeding to the next step of data synthesis.

## Results

### Study search results

Total of 416 articles were found in database searches where 88 were in the PubMed, and 328 records were in the Scopus. By reviewing the title

and abstract of articles, almost 196 articles were omitted in the first step of article selection due to subject irrelevancy. Moreover, 139 and 66 documents were also excluded in subsequent process of article selection due to language irrelevancy and duplication, respectively. By comprehensive reviewing of the articles and considering the previously defined inclusion/exclusion criteria, only 15 unique records seemed to be more relevant to the purpose of this study. By manual reference screening of the previously included articles, 7 additional documents were also included and used for data extraction. Two unique documents were also found through searching in Google Scholar with previously described search strategy. Finally, after several strict step by step processes in the selection of appropriate documents, only 10 relevant articles, which fully met the defined inclusion criteria were selected and used for data synthesis regarding the results in which the practicality and efficiency of MRS had been reported on quantitative analysis of hepatic steatosis. Figure 1 shows the strategy of literature search and processes of study selection.



**Figure 1.** Flowchart for processes of article selection.

### General characteristics of the included documents

A total of 2963 participants had been enrolled in the selected studies in which the usefulness of MRS had been practically evaluated in patients with fatty liver disease. Male to female ratio was 0.89 where 1428 of participants were male and 1535 were female. The age of studied population in the selected studies varied from 11 to 82.

Minimum and maximum numbers of the patients participating in the selected literatures were 12 and 2287, respectively. Different methods including histopathological evaluation, SteatoTest, and liver biopsy as well as MR examinations including magnetic resonance imaging (MRI) and MRS had been used in the selected literatures to evaluate variables such as fatty liver index (FLI), hepatic steatosis index (HSI) and other detectable histopathological indexes. Although the methods differed in each study, but the basic procedures for spectroscopic analysis in the included literatures were as follows: First, MRS measurements performed in patients were in supine position, breathe freely; the data were then processed with software such as jMRUI. Afterwards, signal resonances from water and fat were analyzed and fitted with lorentzian line shapes. Then, depending on the aim of the study, correction for T2 relaxation had been performed.

The most recent and old publication was published in 2014 and 2005, respectively. General characteristics of included articles in this literature review are summarized in Table 1 in chronological order of their published time.

### Study results

The results of this literature review showed that the MRS is a suitable and accurate technique in clinical practice, especially for pathological assessment. Almost all of the included articles showed that the quantification of liver fat and intrahepatic lipid content with proton MRS is very accurate and correlates with histopathologic findings. Findings also showed that MRS is a more accurate method with a higher sensitivity compared to MRI, so that even small amounts of hepatic lipids can be precisely detected by MRS. Comparative studies included in this review had concluded that biological markers and indexes such as SteatoTest, FLI and HSI as well as biopsies cannot replace H-MR spectroscopy for the assessment of small quantities of liver fat content. Therefore, (1) H-MRS can be considered as a reliable method for the quantitative assessment of liver steatosis. In another study, it was shown that phosphorus magnetic resonance spectroscopy ((<sup>31</sup>P-MRS) can detect biochemical changes in different states of fatty liver disease; in addition, it has reasonable diagnostic accuracy for hepatic steatosis.

### Discussion

There are several diagnostic tools including biopsies, MRI, and evaluation of other pathological biomarkers for detection and assessment of liver function. Although biopsy is the current reference standard for assessment of pathological metabolite

**Table 1.** General characteristics of the included articles.

Author Year Reference	Country	Study design*	Study population@	Sex	Patients number
Abrigo JM 2014 (19)	Hong Kong	CSS	Steatohepatitis	Male: 79 Female: 72	151
Georgoff P 2012 (20)	USA	PCSS	Steatohepatitis	Male: 38 Female: 14	52
Guiu B 2012 (21)	France	CT	T2D patients	Male: 110 Female: 110	220
Koelblinger C 2012 (22)	Austria	PCS	Liverresection	Male: 17 Female: 18	35
Van Werven JR 2011 (23)	Netherlands	PCS	Morbidly obese patients	Male: 7 Female: 31	38
Sharma P 2009 (24)	USA	ES	Hepatic steatosis	Male: 11 Female: 1	12
Zhong L 2009 (25)	China	RCT	Diffusefatty liver patients	Male: 16 Female: 20	36
Wang N 2008 (26)	China	CCS	Fatty liver disease	Male: 38 Female: 4	42
Machann J 2006 (27)	Germany	CS	Fatty liver disease	Male: 32 Female: 58	90
Szczepaniak LS 2005 (28)	USA	RCT	Hepatic steatosis	Male: 1080 Female: 1207	2287

\*RCT: Randomized controlled trial, CSS: Cross-sectional study, CCS: Case-Control studies, PCSS: Prospective cross-sectional, ES: Evaluation study, CS: Comparative study, PCS: Prospective cohort study, CT: Clinical trials. @ T2D: Type 2 diabetic patients.

changes, but because this approach is an invasive technique and could be encountered an error at various stages of sampling and monitoring; therefore, it is suggested that MRS can be considered as a non-invasive and reliable clinical reference standard in this regard (12,13).

Studies suggested that MRS can be used for quantitative characterization of pathologically damaged tissues. This method is widely used for properly evaluation of metabolite changes including abnormal accumulation of a compound in tissues (14,15). Clinical evaluations have shown that histologically non-significant alterations in the level of metabolites can also be detected by MRS (15). Due to high accuracy, MRS may also be used for evaluation of postmortem neuronal pathology (16). It is also shown that MRS is a robust method to characterize hepatocellular pathology with high accuracy (17). Since the capabilities and practicality of MRS are still under study; however, spectroscopy techniques, especially <sup>1</sup>H-MRS are still a trustful research tool for clinical evaluation in routine liver examinations (13). In this regard, many trials are registered to National Institutes of Health (NIH) (<https://clinicaltrials.gov/ct2/show/NCT00940537>) to evaluate the efficiency and

accuracy of MRS for metabolic variations, especially for any changes in fat and triglyceride content.

MRS is an accurate, reliable and non-invasive method for detection of even small quantities of liver fat contents. Findings suggest that MR spectroscopy can serve as a reference standard for quantification of hepatic steatosis (18). Moreover, it was found that MRS can be considered as a sensitive and specific assessment technique for the detection of fatty liver disease. Also the results showed that sensitivity and specificity of MRS as a non-invasive technique for the detection of hepatic steatosis is near to 100%. Therefore in some studies, this technique has been used as reference standard to evaluate the practicality of other techniques such as MRI and biopsies. However, potential limitations of MRS include the blurred image quality due to lower magnetic field strength during free breathing. Moreover, in patients with low lipid content, MRS results may lead to falsely augment measured lipid.

Findings show that compared to computed tomography (CT) scan and MRI, <sup>1</sup>H MRS reflects the severity of fatty liver disease with considerable accuracy. In addition, it is a sensitive, non-invasive, and the most accurate quantitative technique for

the detection of liver fat content.

## Conclusion

Findings of articles included in this literature review demonstrated that the magnetic resonance spectroscopy is a widely used non-invasive imaging technique that provides spectroscopic information about metabolic changes in pathologically damaged area. The results of this study also showed that MRS can be used as a reference standard method to evaluate pathologies, and other techniques such as SteatoTest, FLI, HSI and biopsies cannot replace MR spectroscopy for the assessment of liver fat content. As well, findings showed that MRS is a suitable technique for quantitative evaluation of liver steatosis.

## Conflict of Interest

The authors declare no conflict of interest.

## References

- Hijona E, Hijona L, Arenas JI, et al. Inflammatory mediators of hepatic steatosis. *Mediators Inflamm*. 2010;2010:837419.
- Farrell GC, Larter CZ. Nonalcoholic fatty liver disease: from steatosis to cirrhosis. *Hepatology*. 2006;43:S99-S112.
- Adinolfi LE, Gambardella M, Andreana A, et al. Steatosis accelerates the progression of liver damage of chronic hepatitis C patients and correlates with specific HCV genotype and visceral obesity. *Hepatology*. 2001;33:1358-1364.
- Marchesini G, Brizi M, Bianchi G, et al. Nonalcoholic fatty liver disease: a feature of the metabolic syndrome. *Diabetes*. 2001;50:1844-1850.
- Tsochatzis EA, Papatheodoridis GV. Is there any progress in the treatment of non-alcoholic fatty liver disease? *World J Gastrointest Pharmacol Ther*. 2011;2:1-5.
- Clark JM. The epidemiology of nonalcoholic fatty liver disease in adults. *J Clin Gastroenterol*. 2006;40:S5-10.
- Williams CD, Stengel J, Asike MI, et al. Prevalence of nonalcoholic fatty liver disease and nonalcoholic steatohepatitis among a largely middle-aged population utilizing ultrasound and liver biopsy: a prospective study. *Gastroenterology*. 2011;140:124-131.
- McCullough AJ. The clinical features, diagnosis and natural history of nonalcoholic fatty liver disease. *Clin Liver Dis*. 2004;8:521-533.
- Falck-Ytter Y, Younossi ZM, Marchesini G, et al. Clinical features and natural history of nonalcoholic steatosis syndromes. *Semin Liver Dis*. 2001;21:17-26.
- Dagnelie PC, Leij-Halfwerk S. Magnetic resonance spectroscopy to study hepatic metabolism in diffuse liver diseases, diabetes and cancer. *World J Gastroenterol*. 2010;16:1577-1586.
- Liberati A, Altman DG, Tetzlaff J, et al. The PRISMA statement for reporting systematic reviews and meta-analyses of studies that evaluate health care interventions: explanation and elaboration. *Ann Intern Med*. 2009;151:W65-94.
- Reeder SB, Cruite I, Hamilton G, et al. Quantitative assessment of liver fat with magnetic resonance imaging and spectroscopy. *J Magn Reson Imaging*. 2011;34:729-749.
- Springer F, Machann J, Claussen CD, et al. Liver fat content determined by magnetic resonance imaging and spectroscopy. *World J Gastroenterol*. 2010;16:1560-1566.
- Gujar SK, Maheshwari S, Bjorkman-Burtscher I, et al. Magnetic resonance spectroscopy. *J Neuroophthalmol*. 2005;25:217-226.
- Brunetti-Pierri N, Bhattacharjee MB, Wang ZJ, et al. Brain proton magnetic resonance spectroscopy and neuromuscular pathology in a patient with GM1 gangliosidosis. *J Child Neurol*. 2008;23:73-78.
- Sweet RA, Panchalingam K, Pettegrew JW, et al. Psychosis in Alzheimer disease: postmortem magnetic resonance spectroscopy evidence of excess neuronal and membrane phospholipid pathology. *Neurobiol Aging*. 2002;23:547-553.
- Soper R, Himmelreich U, Painter D, et al. Pathology of hepatocellular carcinoma and its precursors using proton magnetic resonance spectroscopy and a statistical classification strategy. *Pathology*. 2002;34:417-422.
- Williamson R, Perry E, Glancy S, et al. The use of ultrasound to diagnose hepatic steatosis in type 2 diabetes: intra- and interobserver variability and comparison with magnetic resonance spectroscopy. *Clin Radiol*. 2011;66:434-439.
- Abrigo JM, Shen J, Wong VW, et al. Non-alcoholic fatty liver disease: spectral patterns observed from an in vivo phosphorus magnetic resonance spectroscopy study. *J Hepatol*. 2014;60:809-815.
- Georgoff P, Thomasson D, Louie A, et al. Hydrogen-1 MR spectroscopy for measurement and diagnosis of hepatic steatosis. *AJR Am J Roentgenol*. 2012;199:2-7.
- Guiu B, Crevisy-Girod E, Binquet C, et al. Prediction for steatosis in type-2 diabetes: clinico-biological markers versus 1H-MR spectroscopy. *Eur Radiol*. 2012;22:855-863.
- Koelblinger C, Krssak M, Maresch J, et al. Hepatic steatosis assessment with 1H-spectroscopy and chemical shift imaging at 3.0 T before hepatic surgery: reliable enough for making clinical decisions? *Eur J Radiol*. 2012;81:2990-2995.
- van Werven JR, Schreuder TC, Aarts EO, et al. Hepatic steatosis in morbidly obese patients undergoing gastric bypass surgery: assessment with open-system 1H-MR spectroscopy. *AJR Am J Roentgenol*. 2011;196:W736-742.
- Sharma P, Martin DR, Pineda N, et al. Quantitative analysis of T2-correction in single-voxel magnetic resonance spectroscopy of hepatic lipid fraction. *J Magn Reson Imaging*. 2009;29:629-635.
- Zhong L, Chen JJ, Chen J, et al. Nonalcoholic fatty liver disease: quantitative assessment of liver fat content by computed tomography, magnetic resonance imaging and proton magnetic resonance spectroscopy. *J Dig Dis*. 2009;10:315-320.
- Wang N, Dong H, Wei S, et al. Application of proton magnetic resonance spectroscopy and computerized tomography in the diagnosis and treatment of nonalcoholic fatty liver disease. *J Huazhong Univ Sci Technolog Med Sci*. 2008;28:295-298.
- Machann J, Thamer C, Schnoedt B, et al. Hepatic lipid accumulation in healthy subjects: a comparative study using spectral fat-selective MRI and volume-localized 1H-MR spectroscopy. *Magn Reson Med*. 2006;55:913-917.
- Szczepaniak LS, Nurenberg P, Leonard D, et al. Magnetic resonance spectroscopy to measure hepatic triglyceride content: prevalence of hepatic steatosis in the general population. *Am J Physiol Endocrinol Metab*. 2005;288:E462-468.