



Материал поступил в редакцию: 16-05-2016

Материал принят к печати: 21-11-2016

УДК 616-002.77

Sarcoidosis: Internal medicine perspective

Mehtap Tinazli, Gaukhar Bakhtiyarova

Near East University Hospital, Internal Medicine Department, Northern Cyprus, Nicosia

Abstract

Sarcoidosis is a systemic autoimmune disease characterized by noncaseating granulomatous inflammation with unknown etiology. Although the lungs and respiratory system are most commonly involved, sarcoidosis may involve virtually any part of the body, including the locomotor system, eyes, skin, lymph nodes. Diagnosis attained via consensus between the clinical presentation and natural history, pattern of major organ involvement, confirmatory biopsy, and response to therapy. Histopathological features remain the gold standard in diagnosis. Radiologic staging in sarcoidosis is based on the chest X-ray. If chest radiographs normal, high-resolution computed tomography (HRCT) can demonstrate pathological changes in a detailed manner. Sarcoidosis generally follows a benign course with occasional spontaneous remissions. The most important causes of mortality are acute and chronic respiratory failure, pulmonary hypertension and hemoptysis due to aspergillosis. When treatment is indicated, glucocorticoids remain the only recognized effective therapy for active sarcoidosis. Level of evidence for management of sarcoidosis is low, generally reflecting the results of limited number of clinical studies, case series and expert opinion. In selected cases, biological agents including, tumour necrosis factor inhibitors, seem to be promising.

Keywords: Sarcoidosis – diagnosis – treatment.*J Clin Med Kaz* 2016; 3(41):6-13 doi: 10.23950/1812-2892-2016-3-6-13**Corresponding author:** Mehtap Tinazli, Near East University Medical Faculty Hospital, Turkish Republic North Cyprus, Nicosia. Tel: +90533 8878360. E-mail: mehtap.canbaz@hotmail.com**САРКОИДОЗ: ДӘРІГЕР-ТЕРАПЕВТТІҢ КӨЗҚАРАСЫ****М. Тыназлы, Г. Бахтиярова**

Таяу Шығыс Университеті Медицина факультеті клиникасы, Ішкі аурулар кафедрасы, Никосия

Тұжырымдама

Саркоидоз, казеозды емес, гранулематозды қабынуымен сипатталатын этиологиясы белгісіз жүйелі аутоиммунды ауру. Өкпе және тыныс алу жүйесінің ең жиі зақымдалуына қарамастан, саркоидоз адам ағзасының кез келген бөлігін, соның ішінде тірек-қимыл жүйесі, көз, тері, лимфа түйіндерін қамтуы мүмкін. Диагноз клиникалық белгілері және шынайы ауру тарихы, ірі мүше зақымдауын растайтын биопсиясымен, терапияға жауап беру консенсус арқылы қоюлуда. Гистопатологиялық ерекшеліктері диагностикада алтын стандарт болып қалуда. Рентгенологиялық зерттеуде кеуде қуысы рентгенографиялық тұрғыдан қалыпты болса, ажыратымдылығы жоғары компьютерлік томография (HRCT) арқылы егжей-тегжейлі түрде патологиялық өзгерістерін көрсете алады. Саркоидоз, әдетте зарарсыз ағымды, кездейсоқ кенеттен ремиссиясы кездесетін ауру. Өлімнің ең маңызды себептері жедел және созылмалы тыныс жетіспеушілігі, өкпелік гипертензия, аспергиллез салдарынан қан құсу болып табылады. Саркоидоздың белсенді түрінде ең тиімді сапалы ем глюкокортикоидтар болып табылады. Саркоидозды бақылау және басқару үшін дәлелдемелер деңгейінің төмендігін, әдетте, клиникалық зерттеулер, бақылау серияларының және сараптамалық қорытынды саны шектеулі нәтижелерін көрсетеді. Таңдалған жағдайларда ісіктердің некротикалық фактор ингибиторлары, оған қоса алғанда, биологиялық агенттері перспективалы болып көрінеді.

Маңызды сөздер: саркоидоз – диагностикасы - емі.**САРКОИДОЗ: ВЗГЛЯД ТЕРАПЕВТА****Тыназлы М., Бахтиярова Г.**

Клиника Ближневосточного университета, медицинский факультет, кафедра Внутренних болезней, Никосия

Резюме

Саркоидоз представляет собой системное аутоиммунное заболевание, характеризующееся неказеозным, гранулематозным воспалением с неясной этиологией. Несмотря на то, что, легкие и дыхательная система наиболее часто вовлечены, саркоидоз может вовлечь практически любой орган и систему, в том числе и опорно-двигательную систему, органы зрения, кожу, лимфатические узлы. Диагностика достигается с помощью консенсуса между клиническими проявлениями и историей заболевания, структурой крупного поражения органов, подтверждающиеся биопсией, и ответом на терапию. Гистопатологические особенности остаются золотым стандартом в диагностике. Радиологическая диагностика на саркоидоз основана на рентгенограмме грудной клетки. Если грудная клетка радиологически нормальная, компьютерная томография высокого разрешения (КТВР) может продемонстрировать патологические изменения в детальном порядке. Саркоидоз обычно имеет доброкачественное течение с редкими спонтанными ремиссиями. Наиболее важными причинами смертности являются острая и хроническая дыхательная недостаточности, легочная гипертензия и кровохарканье из-за аспергиллеза. В лечении показана глюкокортикоидная терапия, являющаяся единственной эффективной терапией при активном саркоидозе. Уровень фактических данных для ведения (менеджмента) саркоидоза является низким, как правило, отражает результаты ограниченного числа клинических исследований, серии наблюдений и мнения экспертов. В некоторых случаях перспективным являются биологические агенты, ингибиторы фактора некроза опухоли.

Ключевые слова: саркоидоз – диагностика – лечение.

Introduction

Sarcoidosis is systemic inflammatory disorder characterized by the presence of noncaseating granulomatous inflammation in affected organs [1]. The etiology of sarcoidosis remains undetermined, clinical manifestations of this disease are protean, and a diagnosis of sarcoidosis is often made by the exclusion of other processes. It is characterized by a seemingly exaggerated immune response against a difficult-to-discern antigen [2].

What helps distinguish sarcoidosis from other systemic disorders is a consideration of clinical presentation and natural history, confirmatory biopsy, and appropriate response to therapy. Although this disease most commonly affects the lungs, virtually any part of the body may be affected. And the presence and behavior of characteristic extrapulmonary manifestations may assist in supporting a diagnosis of sarcoidosis.

Epidemiology

The worldwide prevalence varies widely and has been reported to be 1 to 10 cases per 100,000 population in a diverse array of countries (Denmark, Belgium, Japan, Korea, Czechoslovakia). In Sweden, for reasons that are not clear, the prevalence is estimated to be between 60 to 80 per 100,000 [3,4]. Sarcoidosis affects people of all racial and ethnic groups and occurs at all ages, although it usually develops before the age of 50 years, with the incidence peaking at 20 to 39 years [5]. The incidence of sarcoidosis varies widely throughout the world, probably because of differences in environmental exposures, surveillance methods, and predisposing HLA alleles and other genetic factors. The highest annual incidence of sarcoidosis has been observed in northern European countries (5 to 40 cases per 100,000 people) [6]. In Japan, the annual incidence ranges from 1 to 2 cases per 100,000 people [6] and peaks in the third decade of life. The adjusted annual incidence among black Americans is roughly three times that among white Americans (35.5 cases per 100,000 as compared with 10.9 per 100,000). In black Americans, the peak incidence occurs later in life — in the fourth decade in both men and women — as compared with other groups [5]. Sarcoidosis is also more likely to be chronic and fatal in black Americans [7].

A preponderance of cases of sarcoidosis in females is consistent across racial and ethnic groups. In Scandinavia, the incidence in women appears to be bimodal, with one peak at 25 to 29 years of age and another at 65 to 69 years of age [8].

Socioeconomic status does not affect the risk of sarcoidosis, but low income and other financial barriers to care are associated with more severe sarcoidosis at presentation, even with adjustment for the demographic characteristics of race or ethnic group, sex, and age [9].

Genetic and Familial associations in Sarcoidosis

Familial sarcoidosis was first reported in 1923 in two affected sisters [10]. No formal twin study has been reported, but the concordance appears to be higher in monozygotic twins than in dizygotic twins [11]. In A Case-Control Etiologic Sarcoidosis Study (ACCESS), patients with sarcoidosis stated five times as often as control subjects that they had siblings or parents with sarcoidosis [12]. Although siblings of patients with sarcoidosis are at increased risk for the disease, the phenotypic features and clinical outcomes in affected sibling pairs exhibit minimal concordance, with the exception that probands with ocular or hepatic involvement are more likely to have siblings with similar manifestations (odds ratio for ocular

involvement, 3.0; 95% confidence interval [CI], 1.7 to 5.4; odds ratio for hepatic involvement, 3.3; 95% CI, 1.5 to 7.4) [13]. The first reported association between sarcoidosis and specific gene products was the association between class I HLA-B8 antigens and acute sarcoidosis [14]. Subsequently, HLA class II antigens, encoded by HLA-DRB1 and DQB1 alleles, have been consistently associated with sarcoidosis [15,16]. The antigen-binding properties of the HLA class II peptide-binding groove are determined by polymorphic amino acid residues. These residues form pockets in the groove, interacting with the antigenic peptide side chains. A recent study suggests that pocket 9 of HLA-DQ and pocket 4 of HLA-DR are the most important regions involved in the association with sarcoidosis [17]. For example, HLA-DQB1*0201 and HLA-DRB1*0301 are strongly associated with acute disease and a good prognosis [18]. The results of studies of non-HLA candidate genes have been inconsistent [19]. Genes encoding for tumor necrosis factor α (TNF- α), interferon- γ , and chemokine receptors are logical candidates on the basis of their functions, but associations with sarcoidosis have not been confirmed [20,21]. To date, two genomewide scans for loci associated with sarcoidosis have been reported: one in white Germans [22] which showed the strongest linkage signals at chromosomes 3p and 6p, and the other in black Americans [23] which showed the strongest signals at chromosomes 5p and 5q. However, the outcome of genomewide scans is known to be influenced by the population studied.

Environmental causes

Because sarcoidosis most commonly involves the lungs, eyes, and skin, the search for environmental causes has centered on exposures to airborne antigens. Some of the earliest studies of sarcoidosis reported associations with exposures to irritants found in rural settings, such as emissions from wood-burning stoves and tree pollen [24]. More recently, associations with sarcoidosis and exposure to inorganic particles [25], insecticides [26], and moldy environment [26,27] have been reported. Occupational studies have shown positive associations with service in the U.S. Navy [28] metalworking [27], firefighting [29] and the handling of building supplies [30]. Recently, Izbicki et al. reported an increased incidence of sarcoidosis among New York City Fire Department rescue workers involved in the 2001 World Trade Center disaster [31].

Clinical features

Sarcoidosis typically involves more than one organ. Alternative diagnosis must always be excluded when considering rare and unusual presentations of sarcoidosis [32].

Sarcoidosis often first comes to attention when abnormalities are detected on a chest radiograph during a routine screening examination. Systemic symptoms such as fatigue, night sweats, and weight loss are common; the organ system that is most affected varies with the given patient. Löfgren's syndrome, an acute presentation consisting of arthritis, erythema nodosum, and bilateral hilar adenopathy, occurs in 9 to 34% of patients [4].

This acute variant of the disease presents differently in men and women [33]. Erythema nodosum is observed predominantly in women, and marked ankle periarticular inflammation or arthritis without erythema nodosum is more common in men [34][Figure 1].

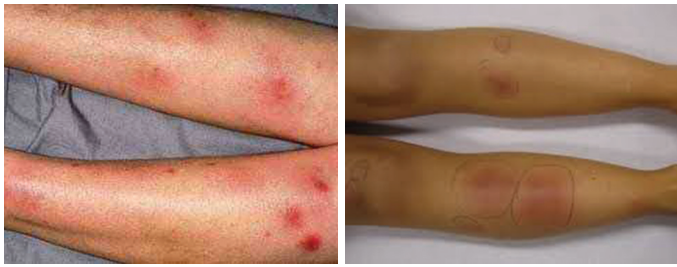

Figure 1 - Erythema Nodosum

Two thirds of patients with sarcoidosis generally have a remission within a decade after diagnosis, with few or no consequences; remission occurs for more than half of patients within 3 years. Unfortunately, up to a third of patients have unrelenting disease, leading to clinically significant organ impairment. A recurrence after 1 or more years of remission is uncommon (affecting <5% of patients), but recurrent disease may develop at any age and in any organ. Less than 5% of patients die from sarcoidosis; death is usually the result of pulmonary fibrosis with respiratory failure or of cardiac or neurologic involvement [35].

Lacrimal and salivary gland involvement causing glandular enlargement and the sicca syndrome may be a feature of an acute presentation of sarcoidosis, known as Heerfordt's syndrome «uveoparotid fever». Heerfordt's syndrome is a constellation of fever, granulomatous inflammation of the lacrimal and parotid glands, uveitis, bilateral hilar adenopathy, and cranial neuropathies.

Pulmonary Involvement

Respiratory symptoms often include dyspnea, cough, vague chest discomfort, and wheezing. Chest radiographs in patients with sarcoidosis have been classified into four stages [36] stage 1, bilateral hilar lymphadenopathy without infiltration; stage 2, bilateral hilar lymphadenopathy with infiltration; stage 3, infiltration alone; and stage 4, fibrotic bands, bullae, hilar retraction, bronchiectasis, and diaphragmatic tenting. These so-called stages represent radiographic patterns and do not indicate disease chronicity or correlate with changes in pulmonary function [37]. Airway hyperreactivity occurs in 5 to 83% of patients [38]. In 80% of patients presenting with abnormal spirometric findings, the values return to the normal range within 2 years [37]. Pulmonary hypertension is a well-described complication of sarcoidosis. Studies have shown that pulmonary-artery pressure is elevated in 6 to 23% of patients at rest and in as many as 43% with exertion [39]. Fibrosis — and the resulting obliteration of the pulmonary vessels — is the most common mechanism for pulmonary hypertension in sarcoidosis, although granulomatous infiltration of the pulmonary arterioles can cause pulmonary hypertension in the absence of pulmonary fibrosis [40] [Figure 2].

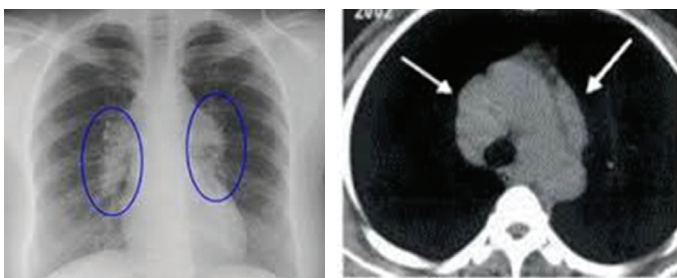


Figure 2 - Pulmonary sarcoidosis. Bilateral lymphadenopathy

Cutaneous Involvement

Although not life-threatening, the unsightly skin lesions of sarcoidosis can be emotionally devastating. Skin involvement is common (occurring in 25 to 35% of patients with sarcoidosis) and often overlooked or misinterpreted, given the variability of the lesions. Macules, papules, and plaques may arise as single isolated lesions or in crops. Lesions commonly involve the nape of the neck and upper back extremities, and trunk, and may appear in scars and tattoos. In black American patients, skin lesions frequently leave scars, pits, and pale, depigmented areas.

Lupus pernio, the term for sarcoidosis-related indurated, lumpy, violaceous lesions on the nose, cheeks, lips, and ears, can be disfiguring, eroding into underlying cartilage and bone. Lupus pernio is more common in women than in men and is associated with chronic disease and extrapulmonary involvement [41] [Figure 3].

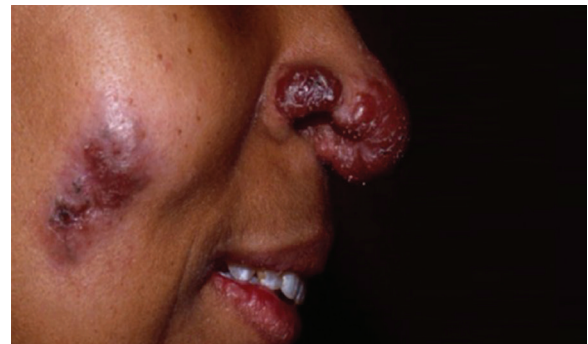

Figure 3 - Chronic cutaneous sarcoidosis

Liver and Spleen Involvement

Just over 10% of all patients with sarcoidosis have elevated serum aminotransferase and alkaline phosphatase levels [42]. A cholestatic syndrome characterized by pruritus and jaundice, hepatic failure, or portal hypertension can develop; yet liver involvement is usually clinically silent. Detection of hepatic and splenic lesions on computed tomography is described in 5% and 15% of patients, respectively [43]. Nearly 60% of patients with hepatic manifestations of sarcoidosis have constitutional symptoms such as fever, night sweats, anorexia, and weight loss. Liver involvement is at least twice as common in black Americans as in white Americans [44]. Portal hypertension with variceal bleeding, a hepatopulmonary syndrome with refractory hypoxemia, and cirrhosis leading to liver failure occur in only 1% of patients with sarcoidosis [45].

Neurologic Involvement

The central nervous system is involved in up to 25% of patients with sarcoidosis who undergo autopsy, but only 10% of all patients with sarcoidosis present with neurologic symptoms. The most common problems, listed in decreasing order of frequency, are cranial-nerve palsies, headache, ataxia, cognitive dysfunction, weakness, and seizures [46]. Neurologic involvement precedes the diagnosis of sarcoidosis in up to 74% of patients and is the only manifestation in 10 to 17% of patients with neurosarcoidosis [47]. Analysis of cerebrospinal fluid in patients with central nervous system involvement indicates nonspecific lymphocytic inflammation. The diagnostic value of measuring ACE levels in cerebrospinal fluid is controversial, since ACE levels are neither sensitive nor specific for the diagnosis. In a third of patients, oligoclonal immunoglobulin bands in the cerebrospinal fluid are elevated, making it difficult to differentiate sarcoidosis from multiple sclerosis [48].

Ocular Involvement

The eye and adnexa are involved in 25 to 80% of patients with sarcoidosis, necessitating routine slit-lamp and fundoscopic examination. Anterior uveitis is the most common manifestation, occurring in 65% of patients with ophthalmologic involvement; chronic anterior uveitis, with insidious symptoms leading to glaucoma and vision loss, is more common than acute anterior uveitis. Posterior-segment involvement is reported to occur in nearly 30% of the patients with ocular sarcoidosis and is frequently accompanied by central nervous system involvement [49] [Figure 4].

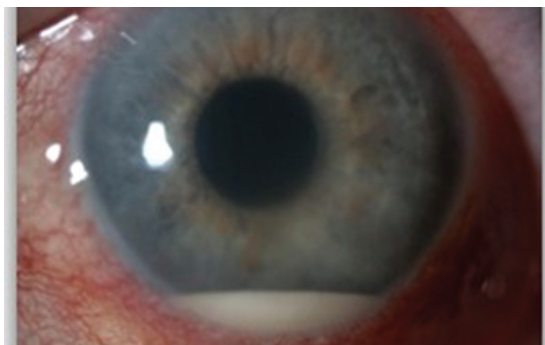

Figure 4 - Uveitis with hypopyon

Cardiac Sarcoidosis

Cardiac granulomas are found in about 25% of patients with sarcoidosis who are examined at autopsy, but cardiac sarcoidosis is clinically apparent in only about 5% of all patients. The most common location for granulomas and scars is the left ventricular free wall, followed by the intraventricular septum, often with involvement of the conducting system. Cardiac sarcoidosis is manifested clinically as a cardiomyopathy with loss of muscle function or tachyarrhythmias and bradyarrhythmias (palpitations, syncope, and death). Endomyocardial biopsy has a low diagnostic yield (less than 20%) because cardiac involvement tends to be patchy, and granulomas are more likely to be located in the left ventricle and basal ventricular septum than in the right ventricle, where endomyocardial biopsies are usually performed [50]. Cardiac MRI with gadolinium enhancement and PET scanning are valuable aids in the diagnosis of myocardial sarcoidosis. Since sudden death may be the first sign of cardiac sarcoidosis, electrophysiological studies to detect any conduction delays or increased risk of sustained arrhythmias should be strongly considered in all patients with suspected cardiac sarcoidosis. Most authorities recommend placement of an electronic pacemaker for complete heart block and an automatic implantable cardioverter-defibrillator for ventricular fibrillation or tachycardia and markedly reduced left ventricular ejection fraction [51].

Hypercalcemia and Renal Disease

Hypercalciuria occurs in 40% of patients with sarcoidosis, hypercalcemia in 11%, and renal calculi in 10%. Therefore, 24-hour urinary excretion of calcium should be measured in all patients with sarcoidosis [52].

Musculoskeletal Involvement

As noted, frank arthritis tends to occur in patients with acute presentations of sarcoidosis (Löfgren syndrome). Arthralgias occur commonly in patients with chronic active sarcoidosis. Chronic sarcoid arthritis is a rare manifestation (<1%) that can result in joint deformities, and is associated with other chronic

manifestations such as cutaneous sarcoidosis [53].

Bone

Cystic, punched-out lesions and lacey reticulations are commonly observed on plain radiographs or other imaging studies, often as incidental findings. Such lesions, typically located in the bones of the hands and feet, can also be found in the skull and vertebrae. Lesions involving the pelvis may be associated with pain that mimics sacroiliitis [54].

Abdominal Involvement

Granulomatous inflammation may be detected in more than 50% of liver disease is present in not more than 10% of all cases. Elevated liver enzymes often resolve spontaneously or with therapy with glucocorticoids. Chronic granulomatous hepatitis may progress to cirrhosis, however, particularly if severe and left untreated [55].

Other Important manifestations

A wide range of hematological manifestations may be found in up to one third of patients with sarcoidosis [56]. Peripheral adenopathy occurs commonly at time of disease presentation, and bulky adenopathy may persist in 10% of cases. Massive splenomegaly may be present in 55% of cases. Anemia, lymphopenia and leucopenia may be observed in 30% to 50% of all cases and is more common than thrombocytopenia [57].

Diagnosis

The diagnosis of sarcoidosis is established on the basis of compatible clinical and radiologic findings, supported by histologic evidence in one or more organs of noncaseating epithelioid-cell granulomas in the absence of organisms or particles. A diagnosis of sarcoidosis is reasonably certain without biopsy in patients who present with Löfgren's syndrome. In all other cases, a biopsy specimen should be obtained from the involved organ that is most easily accessed, such as the skin, peripheral lymph nodes, lacrimal glands, or conjunctiva. If diagnosis requires pulmonary tissue, transbronchial biopsy by means of bronchoscopy has a diagnostic yield of at least 85% when multiple lung segments are sampled.

Sarcoidal granulomas have no unique histologic features to differentiate them from other granulomas. Special stains for acid-fast bacilli and fungi, as well as cultures of such organisms, are essential. If the results of lung biopsy with bronchoscopy are negative and other organs are not obviously involved, biopsy of intrathoracic lymph nodes, which are often enlarged in patients with sarcoidosis, may be necessary to confirm the diagnosis. Endoscopic ultrasound-guided, fine-needle aspiration of intrathoracic lymph nodes has been reported to provide a diagnostic yield of approximately 82% and may obviate the need for mediastinoscopy [58].

The Kveim-Siltzbach test has been used for many years in the diagnosis of sarcoidosis. The test is performed by injecting homogenate of human sarcoid tissue extract intradermally; 4 weeks later, the papule that develops at the site of injection is biopsied. This test is now used less often for several reasons. First, no commercially available preparation of the antigen exists. Second, the use of human tissue extracts for clinical purposes presents many constraints. Third, each new Kveim-Siltzbach preparation requires validation *in vivo*. Kveim-Siltzbach testing, if available, is most useful in patients whose lesions are not easily accessible by biopsy (i.e., lesions at sites other than the skin, lacrimal glands, peripheral lymph nodes, and conjunctivae) and who do not need immunosuppressive treatment during the 4-week waiting period between injection

and biopsy [59,60].

Recently, several reports suggested that 18F-fluorodeoxyglucose positron-emission tomography (18FDG PET) may be useful in assessing the extent of organ involvement and in pinpointing the organs that are candidates for diagnostic biopsy [61].

Sarcoidal granulomas produce angiotensin-converting enzyme (ACE), and ACE levels are elevated in 60% of patients with sarcoidosis. However, the value of serum ACE levels in diagnosing or managing sarcoidosis remains controversial. Although ACE levels are influenced by ACE gene polymorphisms, and genotype-corrected reference values may be used to improve interpretation [62], as a diagnostic tool, measurement of serum ACE levels lacks sensitivity and specificity [63].

Radiographic features

Chest radiographs detect abnormalities in 90% of all patients with sarcoidosis [64].

Chest radiograph abnormalities are assigned a category (stage) according to the Scadding system: 0, normal; I, bilateral hilar lymphadenopathy (BHL); II, BHL+ interstitial infiltrates; III, interstitial infiltrates only; IV, fibrocystic lung disease.

Computed tomography scans of the chest reveal that the pulmonary infiltrates of sarcoidosis are typically nodular in appearance, and tend to distribute themselves along bronchovascular structures.

Classic findings associated with sarcoidosis revealed by 67-gallium scanning include uptake in the parotid and lacrimal glands («panda sign») and uptake in bilateral hilar and right paratracheal lymph nodes («lambda sign»).

Although these are highly typical of sarcoidosis, a biopsy is still required to confirm diagnosis.

Therapy. Medications

Most patients with sarcoidosis are not disabled by the illness, so the decision to provide treatment should reflect a weighing of the risks of using corticosteroids, the most common therapy, against the potential benefits. A general rule is to consider instituting treatment when organ function is threatened. Detection of granulomatous disease on physical examination, biopsy, imaging studies, or serologic testing is not a mandate to provide treatment. An international expert panel has suggested initiating treatment with oral prednisone at a dose of 20 to 40 mg per day [60]. The panel recommends evaluating the response to treatment after 1 to 3 months. If there has been a response, the prednisone dose should be tapered to 5 to 15 mg per day, with treatment planned for an additional 9 to 12 months. Lack of a response after 3 months suggests the presence of irreversible fibrotic disease, nonadherence to therapy, or an inadequate dose of prednisone. Once treatment with prednisone has been initiated, limiting it to short courses is unlikely to be helpful.

Most published data on the use of immunosuppressive and cytotoxic drugs in patients with sarcoidosis are anecdotal and based on small numbers of patients [65]. The only randomized, controlled trial that has been reported to date compared methotrexate with placebo in patients receiving corticosteroids [66]. After 12 months, those receiving methotrexate required significantly smaller amounts of corticosteroids than the control group. No significant differences were found between the methotrexate and control groups in terms of lung function, chest radiographs, symptoms, or side effects.

Hydroxychloroquine has been used with some success, particularly for hypercalcemia [67] skin disease, and neurologic involvement [68]. Bachelez et al. reported on the use of minocycline in 12 patients; the drug was effective for the treatment of skin lesions in 10 patients and diminished lung disease in 2 [69]. Several mechanisms have been proposed supporting the use of tetracyclines and their analogues in sarcoidosis. These drugs inhibit matrix metalloproteinases, angiogenesis, apoptosis, and in vitro granuloma formation by monocytes exposed to dextran beads [70].

Since TNF- α plays a central role in granuloma formation, agents that inhibit TNF- α would appear to be potentially useful in treating sarcoidosis [71].

Both thalidomide and pentoxifylline suppress TNF- α production, but neither has been well studied in sarcoidosis. Several case reports, a few case series, and one randomized, controlled trial involving the use of the TNF- α blockers infliximab and etanercept to treat chronic or refractory sarcoidosis have been published [72,73].

Immunopathogenesis

The development and accumulation of granulomas constitute the fundamental abnormality in sarcoidosis. Although the inciting event in sarcoidosis is unknown, in principle, granulomas generally form to confine pathogens, restrict inflammation, and protect surrounding tissue. Granulomas are compact, centrally organized collections of macrophages and epithelioid cells encircled by lymphocytes. Macrophages, in the face of chronic cytokine stimulation, differentiate into epithelioid cells, gain secretory and bactericidal capability, lose some phagocytic capacity, and fuse to form multinucleated giant cells [74]. In more mature granulomas, fibroblasts and collagen encase the ball-like cluster of cell and in some cases, sclerosis ensues, altering organ architecture and function. A cardinal feature of sarcoidosis is the presence of CD4+ T cells that interact with antigen-presenting cells to initiate the formation and maintenance of granulomas [75]. The oligoclonal $\alpha\beta$ T-cell repertoire observed in sarcoidosis suggests that the triggering antigens favor progressive accumulation and activation of selective T-cell clones [76]. These activated CD4+ cells differentiate into type 1 helper T (Th1)-like cells and secrete predominantly interleukin-2 and interferon- γ , augment macrophage TNF- α production, and amplify the local cellular immune response [77]. A subgroup of regulatory T cells, natural killer T cells, has been found to be greatly reduced in peripheral blood from patients with sarcoidosis who do not have Löfgren's syndrome [78]. However, there are conflicting data on the accumulation of natural killer T cells in granulomatous lesions. For example, natural killer T cells were found in lymph-node specimens but not in skin lesions [79].

Sarcoidosis also presents an «immune paradox»: despite extensive local inflammation, anergy may develop, as indicated by suppression of the immune response to tuberculin [80]. Expansion of CD25bright regulatory T cells, a subgroup of CD4+ T lymphocytes, in active sarcoidosis, may account for this anergy [80] by abolishing interleukin-2 production and strongly inhibiting T-cell proliferation [80].

Sarcoidosis has been reported to develop after interferon alfa therapy for hepatitis C [81]. Some studies have suggested that hepatitis C infection itself may increase the risk of sarcoidosis, [82] but it appears more likely that treatment with interferon alfa increases interferon- γ and interleukin-2, thus promoting granuloma formation [83].

Although granulomas may resolve with little consequence, pulmonary fibrosis occurs in 20 to 25% of patients with sarcoidosis. The pathogenesis of pulmonary fibrosis in sarcoidosis remains uncertain. Immunopathology in sarcoidosis

also has the role of cytokines such as interferons, interleukins, ligands SS motivating 18 chemokines [84, 85, 86, 87].

References

1. Hunninghake GW, Costabel U, Ando M, et al. ATS/ERS/WASOG statement on sarcoidosis. American Thoracic Society/European Respiratory Society/World Association of Sarcoidosis and other Granulomatous Disorders. *Sarcoidosis Vas Diffuse Lung Dis* 1999;16:149-173.
2. Ten Berge B, Kleinjan A, Muskens F, Hammad H, Hoogsteden HC, Hendriks RW, et al. Evidence for local dendritic cell activation in pulmonary sarcoidosis. *Respir Res*. 2012 18. 13:33.
3. Kitaichi M. Prevalence of sarcoidosis around the world. *Sarcoidosis Vas Diffuse Lung Dis* 1998;15:16-18.
4. Siltzbach LE, James DG, Neville E, et al. Course and prognosis of sarcoidosis around the world. *Am J Med* 1974;57:847-852.
5. Rybicki BA, Major M, Popovich J Jr, Maliarik MJ, Iannuzzi MC. Racial differences in sarcoidosis incidence: a 5-year study in a health maintenance organization. *Am J Epidemiol* 1997;145:234-241.
6. Pietinalho A, Hiraga Y, Hosoda Y, Lofroos AB, Yamaguchi M, Selroos O. The frequency of sarcoidosis in Finland and Hokkaido, Japan: a comparative epidemiological study. *Sarcoidosis* 1995;12:61-6.
7. Baughman RP, Teirstein AS, Judson MA, et al. Clinical characteristics of patients in a case control study of sarcoidosis. *Am J Respir Crit Care Med* 2001;164:1885-1889.
8. Milman N, Selroos O. Pulmonary sarcoidosis in the Nordic countries 1950-1982: epidemiology and clinical picture. *Sarcoidosis* 1990;7:50-57.
9. Rabin DL, Thompson B, Brown KM, et al. Sarcoidosis: social predictors of severity at presentation. *Eur Respir J* 2004;24:601-608.
10. Martenstein H. Knochveränderungen bei lupus pernio. *Z Haut Geschlechtskr* 1923;7:308-308.
11. Familial associations in sarcoidosis: a report to the Research Committee of the British Thoracic and Tuberculosis Association. *Tubercle* 1973;54:87-98.
12. Rybicki BA, Iannuzzi MC, Frederick MM, et al. Familial aggregation of sarcoidosis: A Case-Control Etiologic Study of Sarcoidosis (ACCESS). *Am J Respir Crit Care Med* 2001;164:2085-2091.
13. Judson MA, Hirst K, Iyengar SK, et al. Comparison of sarcoidosis phenotypes among affected African-American siblings. *Chest* 2006;130:855-862.
14. Brewerton DA, Cockburn C, James DC, James DG, Neville E. HLA antigens in sarcoidosis. *Clin Exp Immunol* 1977;27:227-229.
15. Rossman MD, Thompson B, Frederick M, et al. HLA-DRB1*1101: a significant risk factor for sarcoidosis in blacks and whites. *Am J Hum Genet* 2003;73:720-735.
16. Iannuzzi MC, Maliarik MJ, Poisson LM, Rybicki BA. Sarcoidosis susceptibility and resistance HLA-DQB1 alleles in African Americans. *Am J Respir Crit Care Med* 2003;167:1225-1231.
17. Voorter CE, Amicosante M, Berretta F, Groeneveld L, Drent M, van den Berg-Loonen EM. HLA class II amino acid epitopes as susceptibility markers of sarcoidosis. *Tissue Antigens* 2007;70:18-27.
18. Sato H, Grutters JC, Pantelidis P, et al. HLA-DQB1*0201: a marker for good prognosis in British and Dutch patients with sarcoidosis. *Am J Respir Cell Mol Biol* 2002;27:406-412.
19. Iannuzzi MC, Rybicki BA. Genetics of sarcoidosis: candidate genes and genome scans. *Proc Am Thorac Soc* 2007;4:108-116.
20. Valentonyte R, Hampe J, Croucher PJ, et al. Study of C-C chemokine receptor 2 alleles in sarcoidosis, with emphasis on family-based analysis. *Am J Respir Crit Care Med* 2005;171:1136-1141.
21. Rybicki BA, Maliarik MJ, Poisson LM, Iannuzzi MC. Sarcoidosis and granuloma genes: a family-based study in African-Americans. *Eur Respir J* 2004;24:251-257.
22. Schurmann M, Reichel P, Muller-Myhsok B, Schlaak M, Muller-Quernheim J, Schwinger E. Results from a genome-wide search for predisposing genes in sarcoidosis. *Am J Respir Crit Care Med* 2001;164:840-846.
23. Iannuzzi MC, Iyengar SK, Gray-McGuire C, et al. Genome-wide search for sarcoidosis susceptibility genes in African Americans. *Genes Immun* 2005;6:509-518.
24. Bresnitz EA, Strom BL. Epidemiology of sarcoidosis. *Epidemiol Rev* 1983;5:124-156.
25. Rybicki BA, Amend KL, Maliarik MJ, Iannuzzi MC. Photocopier exposure and risk of sarcoidosis in African-American sibs. *Sarcoidosis Vas Diffuse Lung Dis* 2004;21:49-55.
26. Newman LS, Rose CS, Bresnitz EA, et al. A case control etiologic study of sarcoidosis: environmental and occupational risk factors. *Am J Respir Crit Care Med* 2004;170:1324-1330.
27. Kucera GP, Rybicki BA, Kirkey KL, et al. Occupational risk factors for sarcoidosis in African-American siblings. *Chest* 2003;123:1527-1535.
28. Gorham ED, Garland CF, Garland FC, Kaiser K, Travis WD, Centeno JA. Trends and occupational associations in incidence of hospitalized pulmonary sarcoidosis and other lung diseases in Navy personnel: a 27-year historical prospective study, 1975-2001. *Chest* 2004;126:1431-1438.
29. Prezant DJ, Dhala A, Goldstein A, et al. The incidence, prevalence, and severity of sarcoidosis in New York City firefighters. *Chest* 1999;116:1183-1193.
30. Barnard J, Rose C, Newman L, et al. Job and industry classifications associated with sarcoidosis in A Case-Control Etiologic Study of Sarcoidosis (ACCESS). *J Occup Environ Med* 2005;47:226-234.

31. Izbicki G,Chavko R,Banauch GI, et al. World Trade Center “sarcoid-like” granulomatous pulmonary disease in New York City Fire Department rescue workers.Chest2007;131:1414-1423.
32. Moller DR. Rare manifestations of sarcoidosis. In : Drent M, Costabel U, eds. Sarcoidosis. Vol 10. Wakefield, UK: *European Respiratory Society Journals, Ltd.*; 2005:233-250.
33. Grunewald J, Eklund A. Sex-specific manifestations of Lofgren’s syndrome. *Am J Respir Crit Care Med*2007;175:40-44
34. Idali F, Wilken M, Wahlstrom J et al. Reduced Th1 response in the lungs of HLA-DRB1*0301 patient with pulmonary sarcoidosis. *Eur Respir* 2006;27:451-459.
35. Michael C. Iannuzzi M.D. Benjamin A, Rybicki Ph.D. and Alvin S, Teirstein, M.D. Sarcoidosis. *N Engl J Med* 2007; 357: 2153-2165.
36. Scadding JG. Prognosis of intrathoracic sarcoidosis in England: a review of 136 cases after five years observation. *BMJ* 1961;2:1165-1171.
37. Judson MA, Baughman RP, Thompson BW, et al/ two year prognosis of sarcoidosis: the ACCESS experience. *Sarcoidosis Vasc Diffuse Lung Dis* 2003;20: 204-211.
38. Shorr AF,Torrington KG,Hnatiuk OW. Endobronchial involvement and airway hyperreactivity in patients with sarcoidosis. *Chest* 2001;120:881-886.
39. Fisher KA,Serlin DM,Wilson KC,Walter RE,Berman JS,Farber HW. Sarcoidosis-associated pulmonary hypertension: outcome with long-term epoprostenol treatment.Chest2006;130:1481-1488
40. Handa T, Nagai S, Miki S, et al. Incidence of pulmonary hypertension and its clinical relevance in patients with sarcoidosis. *Chest*2006;129:1246-1252.
41. Yanardag H,Pamuk ON,Pamuk GE. Lupus pernio in sarcoidosis: clinical features and treatment outcomes of 14 patients. *J Clin Rheumatol* 2003;9:72-76.
42. Baughman RP,Teirstein AS,Judson MA, et al. Clinical characteristics of patients in a case control study of sarcoidosis.*Am J Respir Crit Care Med* 2001;164:1885-1889.
43. Scott GC,Berman JM,Higgins JL Jr. CT patterns of nodular hepatic and splenic sarcoidosis: a review of the literature. *J Comput Assist Tomogr* 1997;21:369-372.
44. Judson MA. Hepatic, splenic, and gastrointestinal involvement with sarcoidosis.Semin Respir Crit Care Med2002;23:529-541.
45. Harder H,Buchler MW,Frohlich B, et al. Extrapulmonary sarcoidosis of liver and pancreas: a case report and review of literature. *World J Gastroenterol* 2007;13:2504-2509.
46. Scott TF,Yandora K,Valeri A,Chieffe C,Schramke C. Aggressive therapy for neurosarcoidosis: long-term follow-up of 48 treated patients. *Arch Neurol* 2007;64:691-696.
47. Spencer TS,Campellone JV,Maldonado I,Huang N,Usmani Q,Reginato AJ. Clinical and magnetic resonance imaging manifestations of neurosarcoidosis.Semin Arthritis Rheum2005;34:649-661.
48. Kellinghaus C,Schilling M,Ludemann P. Neurosarcoidosis: clinical experience and diagnostic pitfalls.Eur Neurol2004;51:84-88.
49. Bonfioli AA,Orefice F. Sarcoidosis.*Semin Ophthalmol* 2005;20:177-182.
50. Uemura A,Morimoto S,Hiramitsu S,Kato Y,Ito T,Hishida H. Histologic diagnostic rate of cardiac sarcoidosis: evaluation of endomyocardial biopsies. *Am Heart J*1999;138:299-302.
51. Grimm W,Alter P,Maisch B. Arrhythmia risk stratification with regard to prophylactic implantable defibrillator therapy in patients with dilated cardiomyopathy: results of MACAS, DEFINITE, and *SCD-HeFT.Herz* 2004;29:348-352.
52. Berliner AR,Haas M,Choi MJ. Sarcoidosis: the nephrologist’s perspective.*Am J Kidney Dis* 2006;48:856-870.
53. Kaplan H. Sarcoid arthritis. A review. *Arch Intern Med* 1963;112:924-935.
54. Wilcox A, Bharadwaj P, Sharma OP. Bone sarcoidosis. *Curr Opin Rheumatol* 2000;12:321-330.
55. Kennedy PT, Zakaria N, Modawi SB, et al. Natural history of hepatic sarcoidosis and its response to treatment. *Eur J Gastroenterol Hepatol* 2006;18:721-726.
56. Lower EE, Smith JT, Martelo OJ, Baughman RP. The anemia of sarcoidosis. *Sarcoidosis* 1988;5:51-55.
57. Fasano MB, Sullivan KE, Sarpong SB, et al. Sarcoidosis and common variable immunodeficiency. Report of 8 cases and review of the literature. *Medicine (Baltimore)* 1996;75:251-261.
58. Annema JT,Veselic M,Rabe KF. Endoscopic ultrasound-guided fine-needle aspiration for the diagnosis of sarcoidosis.*Eur Respir J* 2005;25:405-409.
59. Judson MA,Baughman RP,Teirstein AS,Terrin ML,Yeager H Jr. Defining organ involvement in sarcoidosis: the ACCESS proposed instrument. *Sarcoidosis Vasc Diffuse Lung Dis* 1999;16:75-86.
60. Statement on sarcoidosis: joint statement of the American Thoracic Society (ATS), the European Respiratory Society (ERS) and the World Association of Sarcoidosis and Other Granulomatous Disorders (WASOG) adopted by the ATS Board of Directors and by the ERS Executive Committee, February 1999. *Am J Respir Crit Care Med* 1999;160:736-755.
61. Nunes H,Brillet PY,Valeyre D,Brauner MW,Wells AU. Imaging in sarcoidosis.Semin Respir Crit Care Med2007;28:102-120.
62. Kruit A,Grutters JC,Gerritsen WB, et al. ACE I/D-corrected Z-scores to identify normal and elevated ACE activity in sarcoidosis. *Respir Med* 2007;101:510-515.
63. Studdy PR,Bird R. Serum angiotensin converting enzyme in sarcoidosis its value in present clinical practice.*Ann Clin Biochem* 1989;26:13-18.
64. Johns CJ,Michele TM. Theclinical management of sarcoidosis. A 50-year experience at the Johns Hopkins Hospital. *Medicine* 1999;78:65-111.
65. Paramothayan S,Lasserson TJ,Walters EH. Immunosuppressive and cytotoxic therapy for pulmonary sarcoidosis.*Cochrane Database Syst Rev*2006;3:CD003536-CD003536.

-
-
66. Baughman RP, Winget DB, Lower EE. Methotrexate is steroid sparing in acute sarcoidosis: results of a double blind, randomized trial. *Sarcoidosis Vasc Diffuse Lung Dis* 2000; 17: 60-66.
 67. Adams JS, Diz MM, Sharma OP. Effective reduction in the serum 1.25-dihydroxyvitamin D and calcium concentration in sarcoidosis-associated hypercalcemia with short-course chloroquine therapy. *Ann Intern Med* 1989; 111:437-438.
 68. Sharma OP. Effectiveness of chloroquine and hydroxychloroquine in treating selected patients with sarcoidosis with neurological involvement. *Arch Neurol* 1998;55:1248-1254.
 69. Bachelez H, Senet P, Cadranet J, Kaoukhov A, Dubertret L. The use of tetracyclines for the treatment of sarcoidosis. *Arch Dermatol* 2001;137:69-73.
 70. Sapadin AN, Fleischmajer R. Tetracyclines: nonantibiotic properties and their clinical implications. *J Am Acad Dermatol* 2006;54:258-265.
 71. Baughman RP, Iannuzzi M. Tumour necrosis factor in sarcoidosis and its potential for targeted therapy. *Biodrugs* 2003;17:425-431.
 72. Denys BG, Bogaerts Y, Coenegrachts KL, De Vriese AS. Steroid-resistant sarcoidosis: is antagonism of TNF-alpha the answer? *Clin Sci (Lond)* 2007;112:281-289.
 73. Baughman RP, Drent M, Kavuru M, et al. Infliximab therapy in patients with chronic sarcoidosis and pulmonary involvement. *Am J Respir Crit Care Med* 2006;174:795-802.
 74. Hernandez-Pando R, Bornstein QL, Aguilar Leon D, Orozco EH, Madrigal VK, Martinez Cordero E. Inflammatory cytokine production by immunological and foreign body multinucleated giant cells. *Immunology* 2000;100:352-358.
 75. Agostini C, Adami F, Semenzato G. New pathogenetic insights into the sarcoid granuloma. *Curr Opin Rheumatol* 2000;12:71-76.
 76. Silver RF, Crystal RG, Moller DR. Limited heterogeneity of biased T-cell receptor V beta gene usage in lung but not blood T cells in active pulmonary sarcoidosis. *Immunology* 1996;88:516-523.
 77. Zissel G, Prasse A, Muller-Quernheim J. Sarcoidosis immunopathogenetic concepts. *Semin Respir Crit Care Med* 2007;28:3-14.
 78. Ho LP, Urban BC, Thickett DR, Davies RJ, McMichael AJ. Deficiency of a subset of T-cells with immunoregulatory properties in sarcoidosis. *Lancet* 2005;365:1062-1072.
 79. Mempel M, Flageul B, Suarez F, et al. Comparison of the T cell patterns in leprous and cutaneous sarcoid granulomas: presence of Valpha24-invariant natural killer T cells in T-cell-reactive leprosy together with a highly biased T cell receptor Valpha repertoire. *Am J Pathol* 2000;157:509-523.
 80. Miyara M, Amoura Z, Parizot C, et al. The immune paradox of sarcoidosis and regulatory T cells. *J Exp Med* 2006;203:359-370
Erratum, J Exp Med 2006;203:477.
 81. Doyle MK, Berggren R, Magnus JH. Interferon-induced sarcoidosis. *J Clin Rheumatol* 2006;12:241-248.
 82. Ramos-Casals M, Mana J, Nardi N, et al. Sarcoidosis in patients with chronic hepatitis C virus infection: analysis of 68 cases. *Medicine (Baltimore)* 2005;84:69-80.
 83. Kikawada M, Ichinose Y, Kunisawa A, et al. Sarcoidosis induced by interferon therapy for chronic myelogenous leukaemia. *Respirology* 1998;3:41-44.
 84. Henry MT, McMahan K, Mackarel AJ, et al. Matrix metalloproteinases and tissue inhibitor of metalloproteinase-1 in sarcoidosis and IPF. *Eur Respir J* 2002;20:1220-1227.
 85. Fireman E, Kraiem Z, Sade O, Greif J, Fireman Z. Induced sputum-retrieved matrix metalloproteinase 9 and tissue metalloproteinase inhibitor 1 in granulomatous diseases. *Clin Exp Immunol* 2002;130:331-337.
 86. Wahlstrom J, Katchar K, Wigzell H, Olerup O, Eklund A, Grunewald J. Analysis of intracellular cytokines in CD4+ and CD8+ lung and blood T cells in sarcoidosis. *Am J Respir Crit Care Med* 2001;163:115-121.
 87. Prasse A, Pechkovsky DV, Toews GB, et al. A vicious circle of alveolar macrophages and fibroblasts perpetuates pulmonary fibrosis via CCL18. *Am J Respir Crit Care Med* 2006;173:781-792.