

Материал поступил в редакцию: 29-11-2014

Материал принят к печати: 10-12-2014

УДК: 618.8-089

A case of thoracic psammomatous and meningotheial subtype meningioma presenting with atypical low back pain and sciatica

TUBA TULAY KOCA, AYDIN ARSLAN

Malatya State Hospital, Malatya, Turkey

Spinal meningioma is a benign tumor, with a slow but severe course of symptoms, demonstrating different neurological deficits according to the anatomic region. Diagnosis is generally made with magnetic resonance imaging (MRI). A 74-year-old female presented with chronic atypical low back pain spreading bilaterally to the thighs and progressive difficulties in walking with a history of onset after surgery for gallbladder stones. There was no neurological deficit in the physical examination. MRI revealed a spinal intramedullary mass at T8-9 level, 1.5 cm in size. Laminectomy and instrumentation were applied. Post-operative histopathological examination reported the case as 'psammomatous' and 'meningotheial' Grade I. The lower back pain and difficulty in walking improved rapidly postoperatively. The aim of this paper was to emphasise the importance of early investigation with MRI and differential diagnosis of spinal tumors in patients presenting with complaints of persistent atypical low back pain and sciatica.

Keywords: Atypical low back pain, meningioma, meningotheial, psammomatous, sciatica

J Clin Med Kaz 2014; 4(34): 61-65

Corresponding Author: Dr. Tuba Tülay Koca, Physical Medicine and Rehabilitation Clinic, Malatya State Hospital. mob.phone:05063819295, tuba_baglan@yahoo.com

БЕЛ АЙМАҒЫНДАҒЫ АТИПИЯЛЫҚ АУРУ СЕЗІМІ МЕН РАДИКУЛИТПЕН КӨРІНІС ТАПҚАН ПСАММОМАТОЗДЫ ЖӘНЕ И МЕНИНГОТЕЛИОМАТОЗДЫ ТҮРДЕГІ КЕУДЕ БӨЛІГІНІҢ ОМЫРТҚАСЫНЫҢ МЕНИНГИОМАСЫНЫҢ КЛИНИКАЛЫҚ ЖАҒДАЙЫ

Tuba Tulay Koca, Aydın Arslan

Малатья мемлекеттік ауруханасы, Малатья, Түркия

Бел менингиомасы – сәйкес анатомиялық аумақта әр түрлі неврологиялық симптоматика беретін, баяу әрі күрделі ағымды қатерсіз ісік. Әдетте диагноз магнитті-резонансты томография (МРТ) жасағаннан соң қойылады. Бел аумағындағы созылмалы атипиялық ауру сезімі мазалайтын 74 жастағы әйел кісінің клиникалық жағдайы берілді. Бұл шағымдар өт-тас ауруына жасалған хирургиялық емнен кейін пайда болған. Ауырсыну екі жақта да сан тұсына таралады және жүрген кезде күшейеді. Науқасты қарағанда неврологиялық симптоматика анықталған жоқ. МРТ жасағаннан соң Т8-9 деңгейінде диаметрі 1,5 см. интрамедуллярлы масса анықталды. Ламинэктомия жасалды. Операциядан кейінгі гистологиялық зерттеу нәтижесінде псаммоматозды және и менинготелиоматозды түрдегі кеуде бөлігінің омыртқасының менингиомасы анықталды.

Маңызды сөздер: бел аймағындағы атипиялық ауру сезімі, көрініс псаммоматозды түр, менинготелиоматозды түр, кеуде бөлігінің омыртқасының менингиомасы, бел-құйымшақ радикулиті.

КЛИНИЧЕСКИЙ СЛУЧАЙ МЕНИНГИОМЫ ГРУДНОГО ОТДЕЛА ПОЗВОНКА ПСАММОМАТОЗНОГО И МЕНИНГОТЕЛИОМАТОЗНОГО ПОДТИПОВ, СОПРОВОЖДАЮЩИЙСЯ С АТИПИЧНЫМ БОЛЕВЫМ СИНДРОМОМ В ПОЯСНИЧНОЙ ОБЛАСТИ И ПОЯСНИЧНО-КРЕСТЦОВЫМ РАДИКУЛИТОМ

Tuba Tulay Koca, Aydın Arslan

Малатьяская государственная больница, Малатья, Турция

Спинальные менингиомы – это доброкачественная опухоль, с медленным, но тяжелым клиническим течением, с различной неврологической симптоматикой в соответствующей анатомической области. Диагноз, как правило, выставляется после проведения магнитно-резонансной томографии (МРТ). Представлен клинический случай 74-летней женщины с хроническим атипичным болевым синдромом в поясничной области. Данные жалобы появились после перенесенной операции по поводу желчекаменной болезни. Отмечается иррадиация боли на бедра с обеих сторон и усиливается при ходьбе. При осмотре неврологической симптоматики не выявлено. При проведении МРТ выявлена интрамедуллярная масса на Т8-9 уровне, 1,5 см в диаметре. Была применена ламинэктомия. Послеоперационное гистопатологическое исследование показало менингиому грудного отдела псаммоматозного и менинготелиоматозного подтипов.

Ключевые слова: атипичная боль в пояснице, менингиомы, псаммоматозный подтип, менинготелиоматозный подтип, пояснично-крестцовый радикулит

INTRODUCTION

Meningioma, which originate from the meningeal covering of the brain and spinal cord, are the most frequently seen intracranial tumours in adults. The vast majority of meningioma are located in the intracranial, orbital and intravertebral cavities. Although rare, the development of meningioma has been reported in almost all other organs. Spinal meningioma are mostly found in the thoracic region. Although generally solitary tumours they can be multi-focal, which are observed particularly in neurofibromatosis Type 2 patients [1].

The notable biological property of meningioma is the inclusion of hormone receptors and they are more often observed in females. In particular the presence of progesterone receptor is of prognostic importance. It is accepted as one of the most important prognostic factors for meningioma in histopathological classification. In the 2007 World Health Organisation (WHO) classification, 9 subtypes of slow growth and low recurrence risk were defined as Grade I, 4 subtypes of higher risk as Grade II and 3 subtypes as Grade III. The subtypes found in Grade I are meningothelial, fibrous, transitional, psammomatous, angiomatous, microcystic, secretory, rich lymphoplasmocyte and

metaplastic. In Grade II are those showing brain invasion, cordoid, clear cell and anaplastic, while Grade III histological subtypes comprise papillary and rhabdoid [2,3].

According to the anatomic localization, spinal masses may cause findings such as pain, difficulty in walking, muscle weakness, sensory and sphincter defects. Spinal meningioma is a benign tumour which may be seen as single and/or multi focal, alone or together with cranial involvement. Early diagnosis may be made with magnetic resonance imaging (MRI) and treatment with complete resection and there are low rates of recurrence and re-growth [3]. In literature, differences can be seen between histopathological subtypes in terms of prognosis.

The case is here presented of a 74-year old female who presented 6 months after gallstone surgery with complaints of lower back pain spreading to both legs and progressive difficulties in walking. From MRI and postoperative histological examination, the patient was determined with an extramedullary 'psammomatous' meningothelial' Grade I meningioma at the T8-9 level.

CASE

A 74-year old female presented with complaints of lower back pain affecting both legs (sciatica), which was continuous and increased at rest and with movement. These complaints had started 6 months previously following gallstone surgery and were progressing with increasing difficulty in raising the foot and walking. There was nothing else remarkable in the patient history.

In the physical examination, the bilateral sciatic nerve tension tests were positive but no motor deficits

or sensory impairments were determined in the upper or lower extremities. In the laboratory tests, sedimentation rate was 88mm/hr and CRP and RF factor values were normal. There was no history of brucellosis or tuberculosis. The brucella agglutination test was negative. No focus of active infection or finding of inflammatory arthritis was determined. On the MRI, a 1.5cm mass was determined at T8-9 level, putting pressure on the T9 root (Figures 1a, 1b).

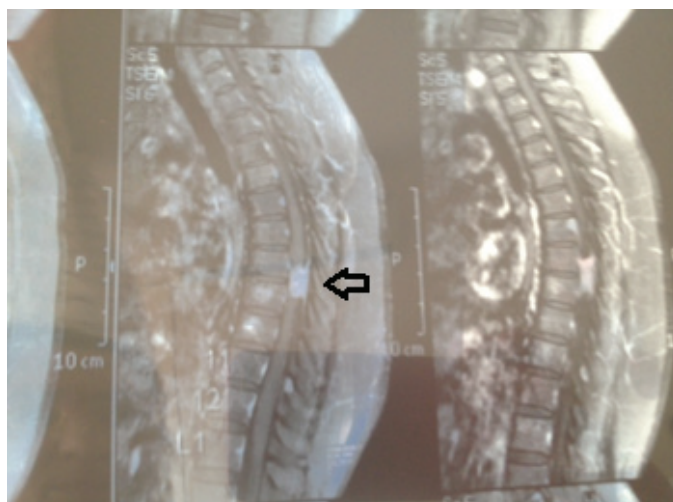


Figure 1a: Sagittal section image of intradural intramedullary location of the mass 1.5cm in size at T8-9 level

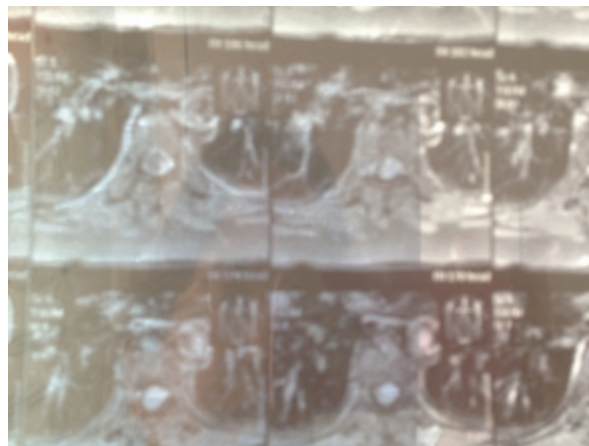


Figure 1b: Axial section image of the intramedullary mass extending to the spinal cavity and creating pressure on the left T9 root.

The patient underwent surgery and the mass was completely excised. Histopathological diagnosis determined the mass as a psammomatous and meningiotheliamatous type Grade I meningioma.

Postoperatively, the complaints of lower back pain and sciatica recovered. On the MRI sagittal section imagination, no residual mass was seen postoperatively (Figure 2).

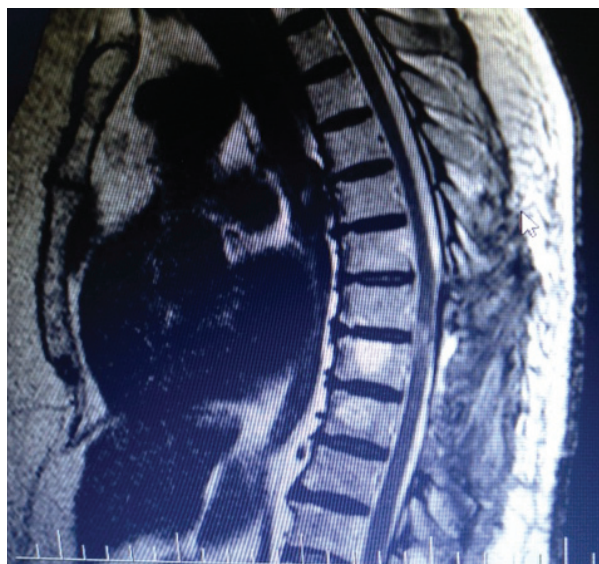

Figure 2: On MRI, sagittal section image of spinal canal there was seen no residual mass postoperatively

Spinal meningioma should be considered in the differential diagnosis of patients presenting with complaints of atypical lower back pain and sciatica. With advanced imaging techniques and microsurgery

methods, spinal meningioma, which are benign tumors, can be successfully treated with low rates of recurrence and morbidity.

DISCUSSION

Spinal meningioma is a benign tumour with a slow course [4], which comprises 14-25% of all spinal tumours. Of spinal tumours with intradural, extramedullary location, neurinoma and meningioma are the most frequently seen. These are generally benign tumours and total excision is possible. However, for ependimoma and astrocytoma, which are the most frequently seen of the intramedullary tumours, total excision is not possible [3].

In meningioma, spinal location has been reported at rates of 1.2-12%, with localisation often in the thoracic region. Although they can be seen at every age, incidence increases with increasing age. These tumours are seen more in those aged over 70 years

and when seen at a young age are related to a poor prognosis and genetic predisposition [5].

Intraspinal meningioma are benign tumours with slow growth and severe course which may cause neurological deficits. There are various histopathological types. Generally, 90-96% are Grade I, with histopathologically the most commonly seen type being ‘meningo-thelial’. There is a low incidence of malignant meningioma (1.0-5.0%) [6].

The age and thoracic location of the case presented here were consistent with textbook information. There was a 6-month history of continuous lower back pain which was unresponsive to medical treatment and physiotherapy. The patient was able to walk but was

experiencing difficulties, with the complaints showing a progressive course. The first impression was that it could be a lumbar degenerative disease and the lumbar MRI was partially clinically compatible. However, that did not explain the difficulties in raising the feet and walking. Medical treatment was started of 3x600mg/day gabapentin and 2x400mg/day etodolac. In the laboratory examination, raised sedimentation rate (88mm/hour) initiated an investigation into infection. There was nothing remarkable in the urine test or on the pulmonary radiograph. There was no history of brucellosis and agglutination tests were negative. There were no complaints to suggest tuberculosis. There were no findings of active arthritis or skin disease which would raise the sedimentation value. As the uric acid values were normal and there were no joint complaints, pseudogout was not considered. For differential diagnosis of the mass (whether tumoural or infectious) a full spinal MRI scan was requested and a mass was determined at the T8-9 level, so the patient was admitted for surgery.

As a result of the postoperative pathological report, the mass was reported as psammomatous, meningiothelial type Grade I. At one week postoperatively, the patient's pain had recovered. There was no neurological deficit in the physical examination. The patient was mobile with assistance under another person's supervision for a short time. The patient was seen to obtain great benefit from the surgery but in the postoperative period was clinically followed up for the disease course.

Meningioma show differences in a wide spectrum according to different histological subtypes. In spinal meningioma, it is unclear whether or not there is a relationship between histopathological parameters and postoperative neurological recovery. In a study by Schaller B [7] of the relationship between postoperative results and histopathological subtypes, more unwanted neurological results were observed in psammomatous type meningioma compared to other histopathological subtypes. In addition, a correlation was found between better postoperative results and a posterior or lateral position on the spinal canal, below C4, patient age below 60 years and preoperative symptoms of short duration.

Secretory meningioma are rarely seen Grade I histological subtypes characterised by focal epithelial and secretory transformation of meningiothelial cells. The most differentiating histopathological characteristic is the eosinophilic hyalin inclusion in the neoplastic cell, known as the 'pseudopsammoma bodies'. The combination of secretory meningioma

together with lipomatous meningioma characterised by lipomatous transformation of the meningiothelial cells can be seen very rarely. Primary meningiothelial cells demonstrate the characteristic of multipotent phenotypic transformation [8]. In young individuals, meningioma with clear cells which show satellite properties may be occasionally encountered in the lumbar and sacral spine. Meningioma with clear cells are generally seen as multifocal and with high recurrence rates [9]. Spinal intramedullary meningioma which are benign and rarely seen may be confused with other intramedullary meningioma (such as ependimoma and astrocytoma). The histological subtypes of meningioma should be well known for correct diagnosis to avoid unnecessary exposure to radiation and chemotherapy [10,11].

Spinal meningioma often progress slowly and may create neurological deficits depending on the anatomic localisation at the time of diagnosis. Diagnosis is often made with MRI. Total resection of the mass offers information about the growth characteristics and regional anatomy. Better results are obtained with developed imaging devices and microsurgery methods. Recurrence rates are low. Surgical treatment often gives pleasing results with low rates of morbidity and recurrence [3,4,12].

The majority of meningioma have a cranial location [1, 2]. Rare cases may be encountered of cranial and spinal meningioma together. It is very rare to see spinal meningioma at more than one level, which supports the 'multicentricity theory' of multiple meningioma originating from neuroaxial compartments [13].

In a study by Solero et al [14] of 174 patients operated on for spinal meningioma, although mortality was seen at 1%, tumour resection was successful in 96.5% and over a 15-year follow-up period recurrence was determined as 6% and regrowth as 17%.

For an initial diagnosis of spinal mass in patients presenting with complaints of atypical lower back pain and sciatica, visualisation of the spinal canal with MRI is necessary in the early stage. Although rare in literature, meningioma with primarily thoracic, lumbar or sacral location may be encountered in young or elderly individuals. In cases of chronic atypical lower back pain which are not responsive to treatment, meningioma in the spinal canal should always be considered in the differential diagnosis. Meningioma, most often in the thoracic region and in the cervical, lumbar and sacral regions may be single or multifocal [15]. With early diagnosis and microsurgery techniques it is possible to obtain successful results with surgical treatment of meningioma.

REFERENCES

1. Perry A, Louis DN, Scheithauer BW, Budka H. et al. Who Classifications of tumours of the central nervous system, Lyon: IARC Press, 2007, pp.164-172.
2. Söylemezoğlu F. Meningiom Sınıflaması ve Histopatolojik Özellikleri, Türk Nöroşirur Derg, 2011, No.21(2), pp.84-90.
3. Binatlı AÖ, Başkan F, Başarı M, Demirhan MF, Özdamar N. Spinal İntradural Tümörlerin Tedavisi, Türk Nöroşirur Derg, 2007, No.17(2):132-137.
4. Souweidane MM, Benjamin V. Spinal cord meningiomas, Neurosurg Clin N Am, 1994, No.5(2), pp.283-291.
5. Yurt A, Çobanoğulları O, Çakır Y, Bardakçı S ve ark. Spinal meningiomlar, Ege Tıp Derg, 1999, No.38(3), pp.145-148.
6. Louis DN, Scheithauer BW, Budka H, von Deiming A. et al. Pathology and Genetics Tumors of the Nervous System, WHO. Lyon. IARC Press, France, 2000, pp.176-84.

7. Schaller B. Spinal meningioma: relationship between histological subtypes and surgical outcome? *J Neurooncol*, 2005, No.75(2), pp.157-161.
8. Matya E, Naganska E, Zabek M, Jagielski J. Meningioma with the unique coexistence of secretory and lipomatous components: a case report with immunohistochemical and ultrastructural study. *Clin Neuropathol*, 2005, No.24(6), pp.257-261.
9. Lista-Martinez O, Santin-Amo JM, Facal-Varela S, Rossi-Mautone E, Rivas-Lopez LA, Amaro-Cendon S. Multifocal clear cell meningioma in the sacral and lumbar spine. Case report and literature review. *Neurocirugia (Astur)*, 2012, No.23(6), pp.259-263.
10. Jeong HS, Lee GK. Secretory meningioma: a case report with histopathological, immunohistochemical and ultrastructural analysis. *J Korean Med Sci*, 1996, No.11(4), pp.369-372.
11. Pant I, Chaturvedi S, Gautam VK, Kumari R. Intramedullary meningioma of spinal cord: case report of a rare tumor highlighting the differential diagnosis of spinal intramedullary neoplasms. *Indian J Pathol Microbiol*, 2014, No.57(2), pp.308-310.
12. Riad H, Knafo S, Segnarbieux F, Lonjon N. Spinal meningiomas: surgical outcome and literature review, *Neurochirurgie*, 2013, No.59(1), pp.30-34.
13. Gül S, Kalaycı M, Edebalı N, Yurdakan G, Açıkgöz B. A multilevel thoracolumbar meningioma in a young woman, *Acta Neurochir (Wien)*, 2008, No.150(8), pp.843-844.
14. Solero CL, Fornari M, Giombini S, Lasio G, Oliveri G, Cimio C et al. Spinal meningiomas: review of 174 operated cases. *Neurosurgery*, 1989, No.25(2), pp.153-160.
15. Duboureau J, Barbut JP, Bouzigues JY, Mansat C. Lumbar meningioma. A rare cause of chronic isolated lumbalgia. *Rev Rhum Mal Osteoartic*, 1987, No.54(10), pp.667-668.