


## Case Report

# A case of reversible Hyperpigmentation and Pancytopenia

**Rameshwar R<sup>1</sup>, Jagadeesan M<sup>2\*</sup>, Mariraj I<sup>3</sup>, Prasanna Karthik S<sup>4</sup>, Kannan R<sup>5</sup>, Magesh Kumar S<sup>6</sup>**

<sup>1</sup> Resident, <sup>2</sup>Assistant Professor, <sup>3</sup>Assistant Professor, <sup>4</sup>Associate Professor, <sup>5</sup>Professor, <sup>6</sup>Professor  
Department of General Medicine, Saveetha Medical College Hospital, Saveetha University, Chennai,  
Tamil Nadu, India

\*Corresponding author email: [drjagadeesan@gmail.com](mailto:drjagadeesan@gmail.com)

	International Archives of Integrated Medicine, Vol. 4, Issue 11, November, 2017. Copy right © 2017, IAIM, All Rights Reserved. Available online at <a href="http://iaimjournal.com/">http://iaimjournal.com/</a> ISSN: 2394-0026 (P) ISSN: 2394-0034 (O)
	Received on: 11-10-2017 Accepted on: 19-10-2017 Source of support: Nil Conflict of interest: None declared.
<b>How to cite this article:</b> Rameshwar R, Jagadeesan M, Mariraj I, Prasanna Karthik S, Kannan R, Magesh Kumar S. A case of reversible Hyperpigmentation and Pancytopenia. IAIM, 2017; 4(11): 285-288.	

## Abstract

Hyperpigmentation may be the presenting sign of several systemic disorders and may be an important clue in their diagnosis. In Vitamin B12 deficiency, hyperpigmentation is due to the increase in melanin synthesis. Vitamin B12 deficiency is rare cause for hyper pigmentation which is reversible. It can be associated with various cutaneous lesions. Low levels of Vitamin B12 are also associated with pancytopenia which is reversible on treatment. It is also a reversible cause of pancytopenia. We report a 58 year old male presenting with hyperpigmentation and pancytopenia and diagnosed to have vitamin B 12 deficiency.

## Key words

Vitamin B 12, Hyperpigmentation, Skin lesions, Pancytopenia, Reversible pancytopenia.

## Introduction

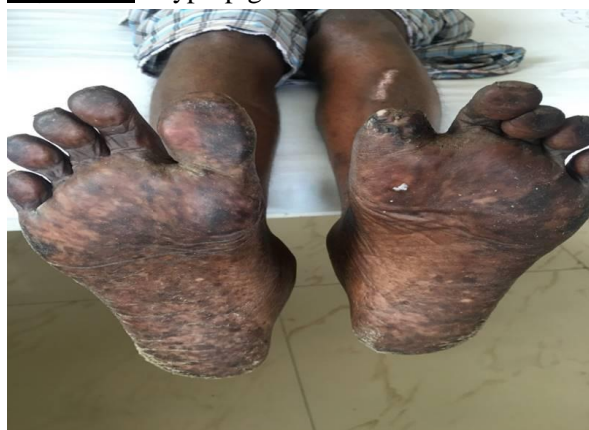In 1944, it was Dr. Bramwell Cook who first observed that hyperpigmentation of the skin was associated with a macrocytic anemia and that, both it and the anemia, responded to crude liver extract [1]. Vitamin B12 deficiency is a common cause of megaloblastic anemia and pancytopenia. Cutaneous manifestations associated with

vitamin B12 deficiency are skin hyperpigmentation, vitiligo, angular stomatitis, and hair changes [2]. We here report a patient having vitamin B12 deficiency presenting with skin lesions and pancytopenia.

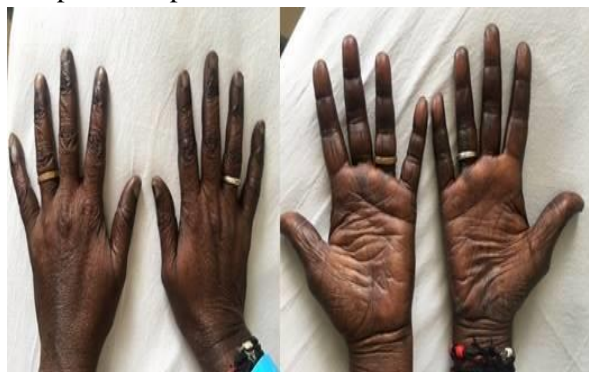## Case report

A 58 year old male presented with progressive worsening of breathlessness for the past 15 days. He had associated loss of appetite and loss of weight of 5 kg for 1 month. There was no history of fever, hematemesis or maelena or any other bleeding manifestations. He was a chronic alcoholic, consuming about 360 ml of alcohol every day for the past 10 years. He had no significant comorbidities. On examination; he was pale and had bilateral pitting pedal oedema. He also had hyperpigmentation over the soles of his feet, dorsum of hands and oral mucosa (Figures – 1, 2, 3).

**Figure – 1:** Hyperpigmentation of soles of feet.



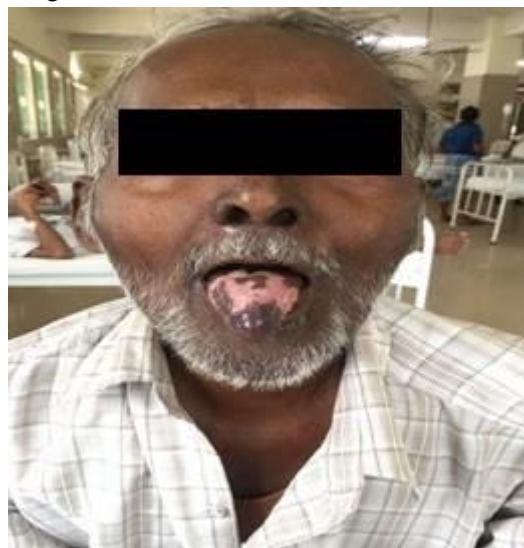**Figure – 2:** Hyperpigmentation of both dorsum and palmar aspect of hands.



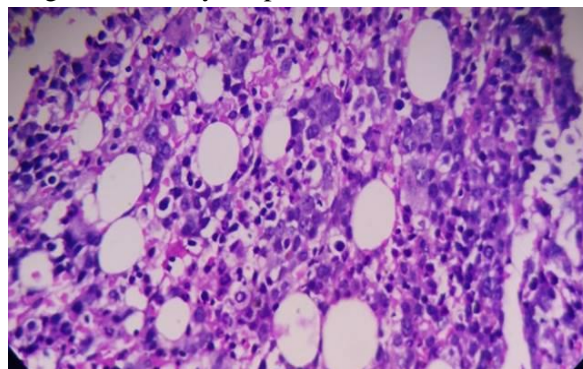
His vitals were stable except for an elevated JVP. Systemic examination revealed bilateral basal crepitations. He was provisionally diagnosed as anemia with failure and treated with anti-failure measures. Lab investigations showed haemoglobin – 4 mg/dL, PCV -11.7, MCV – 109.3 fL, MCH – 31.8 pg, ESR – 25 mm / hr, Total Count – 600 cells/ $\mu$ L, Differential Count

was within limits, Platelets – 31,000 cells/ $\mu$ L, serum albumin – 2.1 g/dL. Other parameters were found to be within normal limits. His Chest X – ray showed bilateral minimal pleural effusion with signs of pulmonary oedema. USG Abdomen revealed mild splenomegaly.

**Figure – 3:** Pallor and hyperpigmentation of tongue.



**Figure – 4:** Histopathology of the bone marrow showing hypercellular marrow with megaloblastic erythropoiesis.



Peripheral smear revealed macrocytic anemia with pancytopenia and no immature cells. Bone marrow study showed hyper cellular marrow with predominance of megaloblastic erythropoiesis and giant forms of myeloid precursors like myelocytes and metamyelocytes (Figure – 4). Direct and indirect Coombs test were negative. Serum LDH was 1276 IU/L (N: 115 – 220 IU/L). Vitamin B12 assay was < 100 pmol/L (N: 200 – 700 pmol/L). Serum Cortisol

(8am) was 6.8 µg/dL (N: 5 – 25 µg/dL). LDH was 1276.00.

He was treated with weekly intramuscular injection of 1000 µg of vitamin B12 for a period of 8 weeks followed by oral supplementation daily. He was also transfused 2 units of packed cells under the cover of diuretics. His repeat hemoglobin level was 8.6 mg/dl. The patient was then discharged with oral iron and B-complex supplementations. After 2 weeks, the total count and platelet levels improved and vitamin B12 level after 8 weeks of treatment was 190 pmol/L. Patient's condition gradually improved along with the regression of the hyperpigmented patches and he was asymptomatic at 3 months.

## **Discussion**

Vitamin B12 plays an important role in DNA synthesis, the deficiency of which is associated with myriad of hematologic, neurologic, psychiatric, gastrointestinal, dermatologic, and cardiovascular manifestations [3]. Hyperpigmentation of the extremities, especially over the dorsum of the hands and feet, with accentuation over the interphalangeal joints and terminal phalanges along with associated pigmentation of oral mucosa is seen in patients of vitamin B12 deficiency [2]. About 10% of vitamin B12 deficient patients show reversible melanin skin pigmentation mainly affecting the knuckle pads and oral mucosa. [4]

Baker, et al. reported a series of 21 patients with vitamin B12 deficiency who had hyperpigmentation of the skin [1]. The patient described above also had hyperpigmentation over the dorsum of all the toes, similar to the type of pigmentation described by Baker, et al. A similar case report of vitamin B 12 deficiency with cutaneous lesion was also published by Kannan, et al. [5].

Aaron, et al. reported that in a case series of 63 patients presenting with vitamin B12 deficiency, glossitis was the most common mucocutaneous manifestation, followed by skin hyper

pigmentation [2]. The probable mechanism of hyperpigmentation in vitamin B12 has not yet been clearly explained. One of the proposed mechanism is that the deficiency of vitamin B12 leading to a decrease in the levels of reduced glutathione, which in turn activates tyrosinase enzyme and thus leading to increased transfer to melanosomes [6]. Another hypothesis attributes the hyperpigmentation to the defect in the melanin transfer between melanocytes and keratinocytes, resulting in pigmentary incontinence [7].

Melanogenesis, which is the process of production and distribution of melanin, takes place in the epidermal unit which is made up of melanocytes (the pigment cells) surrounded by keratinocytes [8]. Melanogenesis, being a complex process when disturbed may result in various pigmentation disorders either hyper or hypo-pigmentation. These disorders may be congenital or acquired, reversible or irreversible and localized or diffuse. Metabolic causes may be porphyria cutanea tarda, hemochromatosis, B12 deficiency or folate deficiency. Autoimmune conditions like POEMS and Addison's disease can also lead to hyperpigmentation [8].

Patients with severe abnormalities are usually treated with injected cobalamin and show reversibility of the skin pigmentation [10-12]. The most commonly prescribed treatment regime involves six 1000 µg IM injections of hydroxycobalamin given at 3 to 7 days intervals to replenish the body stores followed by 3 monthly once injection for maintenance.

## **Conclusion**

A patient presenting with cutaneous lesions alone should make us highly suspicious of the possibility of vitamin B12 deficiency. We should be more aware that cutaneous lesions not responding to conventional therapy could very likely be an indication of vitamin B12 deficiency. These skin manifestations respond quickly to vitamin B12 therapy. Early treatment

with vitamin B12 will prevent the serious complications of vitamin B12 deficiency.

## References

1. Baker SJ, Ignatius M, Johnson S, Vaish SK. Hyperpigmentation of skin. A sign of vitamin-B12 deficiency. *Br Med J*, 1963; 1(5347): 1713-5.
2. Aaron S, Kumar S, Vijayan J, Jacob J, Alexander M, Gnanamuthu C. Clinical and laboratory features and response to treatment in patients presenting with vitamin B12 deficiency-related neurological syndromes. *Neurol India*, 2005; 53(1): 55-8.
3. Oh R, Brown DL. Vitamin B12 deficiency. *Am Fam Physician*, 2003; 67(5): 979-86.
4. Green R, Mitra AD. Megaloblastic anemias: nutritional and other causes. *Med Clin North Am.*, 2017; 101: 297–317.
5. Rajendran K, Ng MJM. Cutaneous lesions and vitamin B12 deficiency. *Canadian Family Physician*, 2008; 54: 529-32.
6. Normal L. *Pigmentation and Pigmentary Disorders*, 1<sup>st</sup> editoin, CRC Press, Florida, 1993, p. 48–9.
7. Marks VJ, Briggaman RA, Wheeler CEJ. Hyperpigmentation in megaloblastic anemia. *J Am Acad Dermatol.*, 1985; 12: 914–5.
8. Rojekar MV, Sawant SD. A Short Review of Pigmentation Disorders in Systemic Diseases. *Pigmentary Disorders*, 2015; 2: 174.
9. Ahuja SR, Sharma RA. Reversible cutaneous hyperpigmentation in vitamin B12 deficiency. *Indian Pediatr.*, 2003; 40: 170-1.
10. Srivastava N, Chand S, Bansal M, Srivastava K, Singh S. Reversible hyperpigmentation as the first manifestation of dietary vitamin B 12 deficiency. *Indian J Dermatol Venereol Leprol.*, 2006; 72: 389–90.
11. Demir N, Doğan M, Koç A, Kaba S, Bulan K, Ozkol HU, et al. Dermatological findings of vitamin B12 deficiency and resolving time of these symptoms. *Cutaneous and Ocular Toxicology*, 2014; 33(1): 70-3.