

Original Research Article


Morphological variations of soft palate and influence of age on it: A digital cephalometric study

C. Vani^{1*}, T. Vinila Lakshmi², V. Dheeraj Roy³

¹Professor, ²Post graduate student, ³Assistant Professor

Department of Oral Medicine and Radiology, Sri Sai College of Dental Surgery, Vikarabad, Telangana, India

*Corresponding author email: drvanichappidi@gmail.com

	International Archives of Integrated Medicine, Vol. 4, Issue 10, October, 2017. Copy right © 2017, IAIM, All Rights Reserved. Available online at http://iaimjournal.com/ ISSN: 2394-0026 (P) ISSN: 2394-0034 (O)
	Received on: 26-09-2017 Accepted on: 04-10-2017 Source of support: Nil Conflict of interest: None declared.
	How to cite this article: C. Vani, T. Vinila Lakshmi, V. Dheeraj Roy. Morphological variations of soft palate and influence of age on it: A digital cephalometric study. IAIM, 2017; 4(10): 72-76.

Abstract

Background: Digital Lateral Cephalograms are the most commonly used radiographs for evaluating morphological variations of soft palate. It is a relatively inexpensive method and provides a good assessment of the soft-tissue elements that define the soft palate and its surrounding structures. The present study was conducted to investigate the morphological variations of the soft palate and influence of age on it.

Materials and methods: The present study consisted of 150 digital cephalograms of subjects aged between 20 to 60 years taken from the department of oral medicine and radiology, Sri Sai College of Dental Surgery, Vikarabad. The subjects were categorized into five groups, group A: 20- 30 years, group B: 31- 40 years, group C: 41- 50 years, group D: 51- 60 years and group E: 61- 70 years. Digital lateral cephalograms were obtained and analyzed to categorize the soft palate into six morphological types, based on the classification by You, et al.

Results: Type 1: leaf shaped soft palate was the most common type, type 4 and 6 varieties were the least common among all age groups. Type 5: S-shaped soft palate was found in considerable proportions among all the age groups (6.7% - 25.8%). There was no significant correlation found between the different age groups and the type of soft palate.

Conclusion: Radiographic analysis of morphological variations of soft palate can help us better understand the velar morphology and may assist in success of surgical procedures aimed for correcting deformities of soft palate.

Key words

Soft palate, Digital cephalogram, Obstructive sleep apnea, Velopharyngeal closure.

Introduction

The part of the palate posterior to the hard palate made up of fibro- muscular tissue is termed as soft palate [1, 2]. During embryogenesis, the fronto- nasal process fuses with two palatine processes resulting in the formation of palate. Later, the mesodermal tissue of the palate undergoes intramembranous ossification in the anterior portion to form the hard palate and the posterior portion remains as a fibromuscular tissue to form the soft palate [2]. Soft palate plays an important role in velopharyngeal closure which is related to the normal functions of sucking, swallowing and phonation [2, 3]. The abnormalities of soft palate are commonly observed in patients with cleft lip and palate, enlarged adenoids, poorly retained maxillary denture and skeletal craniofacial malocclusion [4-6]. Soft palate dysfunction is a major predisposing factor for obstructive sleep apnea [7]. Velopharyngeal closure is obtained by normal apposition of the soft palate with the posterior and lateral pharyngeal walls, thus separating the oral cavity from the nasal cavity during deglutition and speech [7].

Radiographic techniques like lateral cephalography and computer tomography have been used for the study of morphological variations of soft palate [3, 7-10]. Studies on the dimensional analysis of soft palate and its surrounding structures have found variations in the morphology of soft palate [7, 10]. Based on radiographic analysis You, et al. [7], categorized the soft palate into six morphological types: type 1: leaf shaped, type 2: rat tail shaped, type 3: butt like, type 4: straight line shaped, type 5: S-shaped/distorted soft palate and type 6: crooked appearance. Pepin, et al. [7] reported that S-shaped or hook shaped soft palate is found to be a risk factor for obstructive sleep apnea. The present study was conducted to investigate the morphological variations of the soft palate and influence of age on it.

Materials and methods

The present study consisted of 150 digital cephalograms of subjects aged between 20 to 60 years taken from the department of oral medicine and radiology, Sri Sai College of Dental Surgery, Vikarabad. The subjects were categorized into five groups, group A : 20- 30 years, group B : 31- 40 years, group C : 41- 50 years, group D : 51- 60 years and group E: 61- 70 years. All the subjects had normal speech function and subjects with head and neck anomalies, intra-osseous pathologies, history of trauma/surgery were excluded from the study. Images with positioning errors, magnification or distortion were excluded from the study. Ethical clearance was obtained from the Institutional Ethics Committee, Sri Sai College of Dental Surgery. After obtaining an informed consent, digital lateral cephalograms were taken on each subject using Carestream Kodak 8000 Panoramic X ray Imaging system. The subjects were stabilized in the natural head position with the mandible in maximal inter cuspatation and tip of tongue behind the upper central incisors, thus allowing the soft palate to simply rest on the tongue. Digital lateral cephalograms were analyzed and the soft palate was categorized into six types, according to the classification given by You, et al. [7].

Type 1: Leaf shaped / lanceolate shaped—the middle portion of the soft palate elevated to both the naso- and the oro-side (**Figure - 1**).

Type 2: Rat-tail shaped—the soft palate which showed inflated anterior portion and free margin with an obvious coarctation (**Figure - 2**).

Type 3: Butt-like—soft palate which showed a shorter and fatter velum appearance with no distinct difference of width of the anterior portion to the free margin (**Figure - 3**).

Type 4: Straight line shaped (**Figure - 4**).

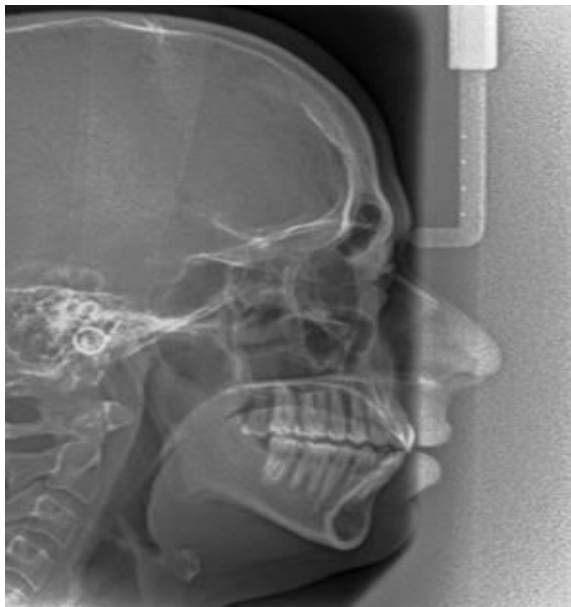
Type 5: S-shaped/distorted soft palate (**Figure - 5**).

Type 6: Crooked appearance - the soft palate in which the posterior portion of the soft palate crooks anterior superiorly (**Figure - 6**).

Figure - 1: leaf shaped soft palate.

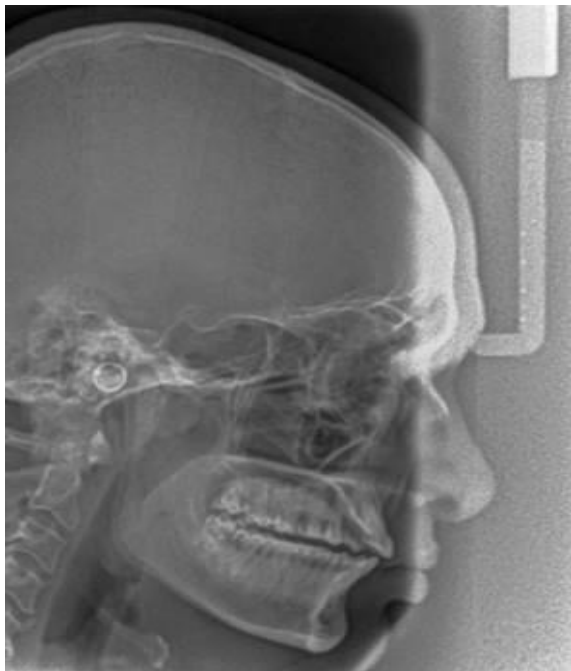

Figure - 2: Rat tail shaped soft palate.



The collected data was analyzed using SPSS software version 16. Chi-square test was done to evaluate the significant relation among the soft palate morphological variations and age groups. Significance level was based on p-value < 0.05.

Figure - 3: Butt like soft palate.

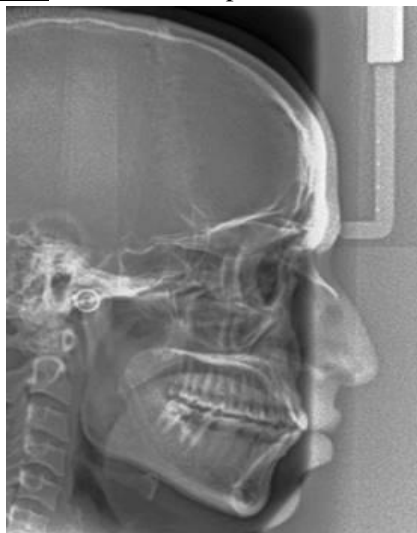

Figure - 4: Straight line shaped.

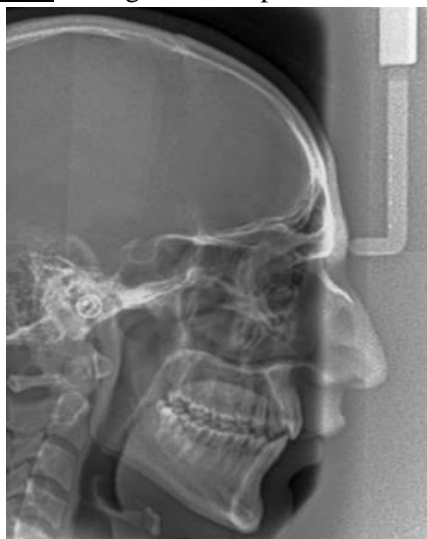

Figure - 5: S- shaped/distorted soft palate.

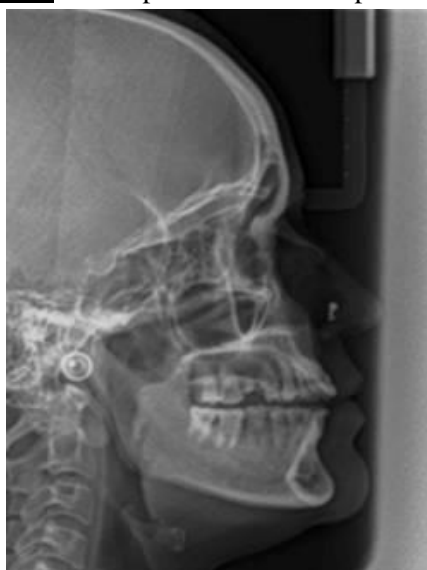
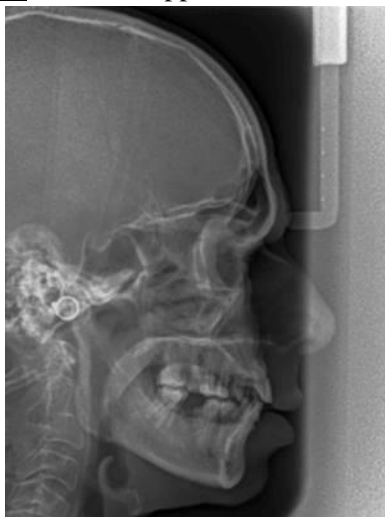
Figure - 6: Crooked appearance.



Results

The present study analyzed a total of 150 digital lateral cephalograms. The distribution of various morphological types of soft palate of study subjects are shown in **Table - 1**. There was no significant correlation found between the different age groups and the types of soft palate.

Table - 1: Distribution of morphological types of soft palate among different age groups

Age group		Type						Pearson Chi-Square value
		1	2	3	4	5	6	
20-30	N	17	4	6	1	2	0	27.902 P value -0.112 (NS)
	%	56.7%	13.3%	20.0%	3.3%	6.7%	.0%	
31-40	N	12	6	7	2	2	1	
	%	40.0%	20.0%	23.3%	6.7%	6.7%	3.3%	
41-50	N	15	2	6	0	4	3	
	%	50.0%	6.7%	20.0%	.0%	13.3%	10.0%	
51-60	N	16	1	2	0	8	3	
	%	54.8%	3.2%	6.5%	.0%	25.8%	9.7%	
61-70	N	16	3	1	1	8	1	
	%	53.3%	10.0%	3.3%	3.3%	25.8%	3.3%	

In the present study, type 5: S-shaped soft palate was found in considerable proportions among all the age groups (6.7% - 25.8%). Pepin, et al. [7] found that the 'hooked' appearance of the soft palate in awake patients indicated a high risk for obstructive sleep apnea syndrome. You M, et al. [10] found that the hooked appearance of the soft palate corresponded to S-shaped soft palate in their classification. Pepin, et al. [7] described hooking of soft palate as angulations of about 30° between the distal part of the uvula and the

Type 1 was the most commonly found morphology, type 4 and 6 were the least common types found among all age groups (**Table - 1**).

Discussion

Radiographic techniques have been widely used for the study of morphological variations of soft palate. Although advanced imaging techniques, like computed tomography (CT), magnetic resonance imaging (MRI) and fluoroscopy are the most effective methods for visualizing soft palate, lateral cephalogram remains the most commonly used method of analysis due to ease of availability and cost effectiveness [7, 8, 10]. Present study was found no significant difference between types of soft palate and age groups. In the present study, type I: leaf shaped soft palate was the most frequent type (55% of the cases). You, et al. [10] described leaf shaped soft palate to be the classic velar morphology.

longitudinal axis of the soft palate. They hypothesized that soft palate hooking results in a sudden and major reduction in oropharyngeal dimensions, thus increasing upper airway resistance and transpharyngeal pressure gradient resulting in pharyngeal collapse are leading to Obstructive sleep apnea (OSA).

It was found that pharyngeal morphology is not immutably established during childhood and adolescence, but changes throughout adult life.

There is a tendency towards longer and thicker soft palate and narrower oropharynx during adulthood, which may explain the possible increased incidence of OSA and related disorders occurring later in life [7].

Conclusion

Radiographic analysis of morphological variations of soft palate may help in success of surgical procedures aimed for correcting deformities of soft palate. In the present study, type 1: leaf shaped was the most common of all the soft palate variants. There was no significant correlation found between the different age groups and the types of soft palate.

References

1. Standring S. Gray's Anatomy - The Anatomical Basis for Clinical Practices. Chapter 33, 40th edition. London, UK: Elsevier Churchill Living Stone Publishing Company, 2008, p.564 – 75.
2. Moore KL, Agur AM. Essential clinical anatomy, 2nd edition, Philadelphia: Lippincott Williams & Wilkins; 2002.
3. Guttal K, Breh R, Bhat R, Burde K, Naikmasur V. Diverse morphologies of soft palate in normal individuals: a cephalometric perspective. Journal of Indian Academy of Oral Medicine and Radiology, 2012; 24(1): 15-19.
4. Johns DF, Rohrich RJ, Awada M. Velopharyngeal incompetence: a guide for clinical evaluation. *Plas Reconstr Surg.*, 2003; 112: 1890–8.
5. Stellzig-Eisenhauer A. The influence of cephalometric parameters on resonance of speech in cleft lip and palate patients. An interdisciplinary study. *J Orofac Orthop.*, 2001; 62: 202–223.
6. Akcam MO, Toygar TU, Wada T. Longitudinal investigation of soft palate and nasopharyngeal airway relations in different rotation types. *Angle Orthod.*, 2002; 72: 521–526.
7. Pepin JL, Veale D, Ferretti GR, Mayer P, Levy PA. Obstructive sleep apnea syndrome: hooked appearance of the soft palate in awake patients - cephalometric and CT findings. *Radiology*, 1999; 210: 163–170.
8. White S, Pharaoh M. Oral Radiology Principles and Interpretation, Chapter 13, 6th edition. Philadelphia, Mosby Elsevier, 2011. pp. 207-12.
9. Subtelny JD. A Cephalometric study of the growth of the soft palate. *Plas Reconstr Surg.*, 1957; 19: 49–62.
10. You M, Li X, Wang H, Zhang J, Wu H, Liu Y, et al. Morphological variety of the soft palate in normal individuals: a digital cephalometric study. *Dentomaxillofac Radiol.*, 2008; 37: 344–349.