

Original Research Article


Study of salivary gland neoplasms in pediatric age group in a tertiary care centre for head and neck diseases

N. Sreemani Kumari^{1*}, Seema Afroze², Madhavi Parigi²

¹Professor, ²Senior Resident

Department of Pathology, Government ENT Hospital, Osmania Medical College, Hyderabad, Telangana, India

*Corresponding author email: nsmk13959@gmail.com

	International Archives of Integrated Medicine, Vol. 4, Issue 8, August, 2017. Copy right © 2017, IAIM, All Rights Reserved. Available online at http://iaimjournal.com/
	ISSN: 2394-0026 (P) ISSN: 2394-0034 (O)
	Received on: 15-07-2017 Accepted on: 21-07-2017 Source of support: Nil Conflict of interest: None declared.
How to cite this article: N. Sreemani Kumari, Seema Afroze, Madhavi Parigi. Study of salivary gland neoplasms in pediatric age group in a tertiary care centre for head and neck diseases. IAIM, 2017; 4(8): 33-40.	

Abstract

Introduction: Salivary gland tumors are very rare in children and adolescents. We reported here 11 cases of paediatric salivary gland tumors in a study conducted from July 2015 to June 2017 at Government ENT Hospital, Koti, Hyderabad, Telangana, a tertiary care center.

Objective: The aim of this study was to analyze clinical and histopathological features of salivary gland tumours in paediatric age group (children and adolescents).

Materials and methods: A total of 11 cases of salivary gland tumors encountered in paediatric age group (0-18 years) were studied and analyzed for age, gender, site predilection and for histopathological types.

Results: Parotid and submandibular glands were the main site of tumor occurrence (8/11 in parotid gland, 2/11 in submandibular gland and 1/11 arising in minor salivary glands of hard palate). 4 cases were benign tumors (pleomorphic adenoma) and 7 were malignant tumors (constituted by 6 cases of low grade mucoepidermoid carcinomas and a single case of adenoid cystic carcinoma). Majority of the cases were above 10 years of age with an average of 12.3 years with female preponderance.

Conclusion: Present study showed that salivary gland tumors in paediatric age group are very rare and with majority of cases being Mucoepidermoid carcinoma with female preponderance seen in parotid gland. Other glands involved were submandibular salivary glands and minor salivary glands of hard palate. Pleomorphic adenoma was the most common benign tumor and Mucoepidermoid carcinoma was the most common malignant tumor, all of low grade type. One case of adenoid cystic carcinoma was noted in a 15 year old female.

Key words

Salivary gland tumors, Pediatric age group, Pleomorphic adenoma, Adenoid cystic carcinoma, Mucoepidermoid carcinoma.

Introduction

Salivary gland tumors are uncommon [1, 2], epithelial salivary gland neoplasms, relatively rare accounting for less than 2% of all tumors [1, 2] and 3-10% of all head and neck neoplasms [3-5]. Annual incidence of these tumors is 0.4 to 13.5 cases in 10000 population [6-10]. Benign and malignant neoplasms in salivary glands are diverse group of neoplasms with behavioural and histological diversity and proximity to vital structures of head and neck poses significant challenges in the management [11-14].

Salivary gland tumors vary in their age, sex and site prevalence in different geographical areas [12-14]. Eskimos have the highest incidence of salivary gland tumors [15, 16]. Other predisposing factors are race, occupation, diet and EB virus infection, however most of the salivary gland tumors are idiopathic with no correlation with the epidemiological differences in the world wide distribution [1, 2, 11, 17, 18].

The aim of this study was to analyze clinical, histopathological characteristics, tumour location, age and gender prevalence of salivary gland tumours in paediatric age group.

Materials and methods

Present study was a two year retrospective study of all the salivary gland tumours received in paediatric age group during the period July 2015 to June 2017 at tertiary centre, Government ENT Hospital, Hyderabad, Telangana State.

Details of the patients were obtained from the records pertaining to information regarding age, sex, investigations done and presenting complaints. Necessary investigations were done before surgery.

All biopsy specimens were fixed in 10% formalin, routinely processed into paraffin

embedded sections and stained them with hematoxylin and eosin stain. IHC was done where needed.

Results

The ages ranged from 9-18 years, with female preponderance. Involvement was unilateral in all cases. A total of 11 pediatric tumors were diagnosed out of which 4 were benign and 7 were malignant. The most common tumor was mucoepidermoid carcinoma. Site distribution was 7 cases in parotid gland (63.6%), 3 cases in the submandibular gland (27.3%) and a single case (9.1%) arising from minor salivary gland of the hard palate. Fine needle aspiration cytology was done in all the cases and received all the 11 surgical specimens for correlation with histopathology (**Table – 1 to 4** and **Figures A to F**).

Discussion

Primary salivary gland tumors comprise less than 2% of all the neoplasms in the western world [1, 2]. A total of 80 salivary gland tumours were received in the 2 year study period at Government ENT Hospital, Hyderabad from July 2015 to June 2017. Paediatric salivary gland tumors were 11 cases constituting 13.75%.

Salivary gland tumors were observed in all ages but were less common in the paediatric age group. A total of 11 pediatric cases were reported of which majority of the cases were above 10 years of age. Only one case was below 10 years of age, which was a female of 9 years with low grade Mucoepidermoid carcinoma arising in the left parotid gland.

Age of onset was late childhood in 10 cases, ranging from 9 to 16 years and mean age was 12.3 years. Incidence of benign salivary gland tumors was less compared to malignant tumors which is not in accordance with studies done by

shafkat, et al. [19], Ogata H [20], da Cruz Perez DE, et al. [21] and Laikul L [22]. Male to female ratio was 0.3:1 which is in correlation with other studies [15, 23, 24] excepting for one study by Shafkat, et al. [19] which had male preponderance.

Table - 1: Site distribution of salivary gland tumors.

Tumor type	Number	%	Parotid gland	Submandibular Salivary gland	Minor salivary glands
Pleomorphic adenoma	4	36%	1	3	0
Mucoepidermoid carcinoma	6	54%	5	0	1
Adenoid cystic carcinoma	1	10%	1	0	0

Table - 2: Age distribution of salivary gland tumors.

Tumor type	Age (0-9 years)	Age (10-18 years)
Pleomorphic adenoma	0	4
Mucoepidermoid carcinoma	1	5
Adenoid cystic carcinoma	0	1

Table - 3: Sex distribution of salivary gland tumors.

Tumor type	Male	%	Female	%
Pleomorphic adenoma	2	18%	2	18%
Mucoepidermoid carcinoma	1	9%	5	46%
Adenoid cystic carcinoma	0	0	1	9%

Table - 4: Salivary gland tumors based on site of involvement of salivary gland.

Tumor type	Pleomorphic adenoma	Mucoepidermoid carcinoma	Adenoid cystic carcinoma
Parotid	1	5	1
Submandibular	3	0	0
Minor salivary glands	0	1	0

The most common salivary gland tumor in our study was Mucoepidermoid carcinoma occurring predominantly in parotid gland which correlates with Foote and Frazell [25], Castro, et al. [26] and other studies [1, 2, 27-29]. All the tumors were of low grade type. One lesion was present in hard palate in a 12 year old girl of 1 cm size. One case was recurrent in 11 year old boy with a history of enucleation one year back, presently managed by superficial parotidectomy.

Majority of the tumors occurred in parotid glands (7 cases), 3 in submandibular gland and one case in minor salivary gland of hard palate.

Most common benign tumor in the present study was pleomorphic adenoma, incidence was low compared to studies done by Laikul L, et al. [22], da Cruz Perez [21], DE (IHC). Enucleation was done in all these cases. Adenoid cystic carcinoma (Grade –II) was present in one case in a 15 years old female seen in parotid gland. It is in correlation with Ogata H, et al. [20] study.

FIGURE A- FNAC IMAGES OF PLEOMORPHIC ADENOMA (Images 1-4)

1)4x View, 2)10x View, 3 & 4) 40x Views of H&E stained smears, showing abundant amount of fibromyxoid stroma along with epithelial cells arranged in islands, papillae & sheets admixed with singly scattered myoepithelial cells.

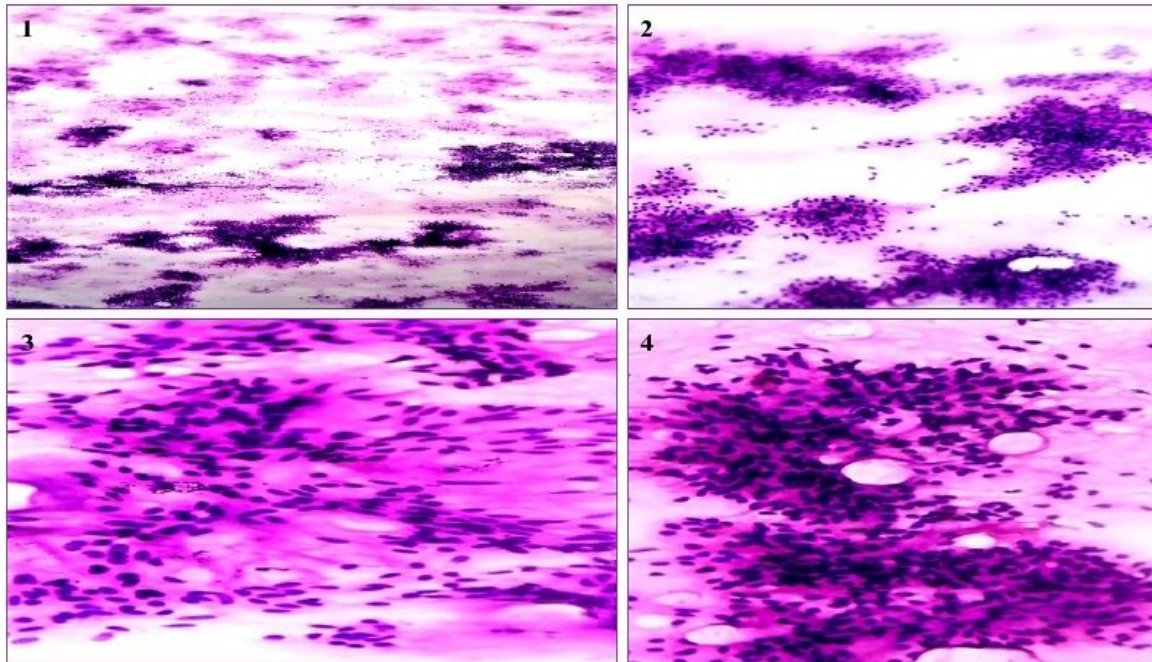


FIGURE B - GROSS PHOTOGRAPHS OF SALIVARY TUMOURS ON CUT SECTION (Images 5-8) :

5 & 6) : Showing fairly circumscribed tumour tissue with glistening, gelatinous myxoid to mucoid appearance with adjacent native salivary gland tissue suggestive of Pleomorphic adenoma. 7) : Showing solid tan grey tumor tissue with punctuate areas of haemorrhages with adjacent native salivary gland parenchyma suggestive of malignant tumour, possibly Adenoid cystic carcinoma. 8) : Showing ill defined mass lesion with mucoid, cystic and tan grey white areas, suggestive of Mucoepidermoid carcinoma.

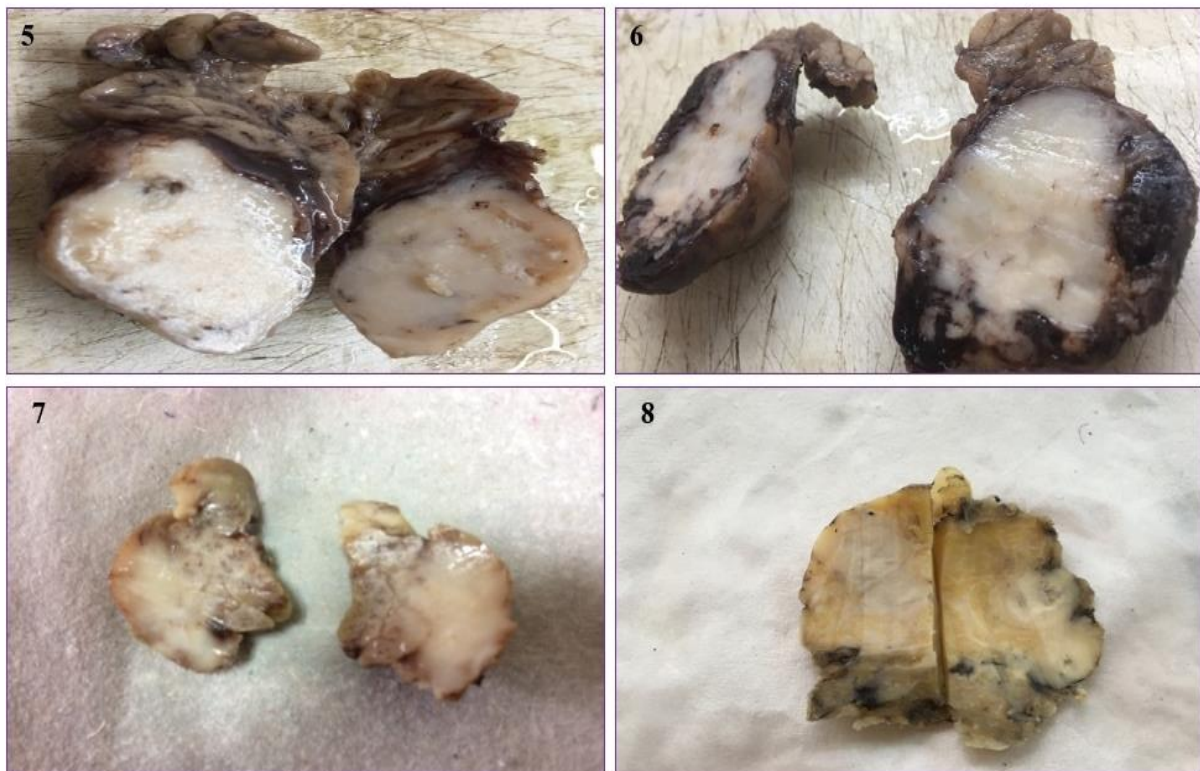


FIGURE : C-HISTOPATHOLOGICAL IMAGES OF PLEOMORPHIC ADENOMA (Images 9-12):
9 & 10) : 10x Views showing fairly circumscribed tumour tissue with adjacent native salivary gland parenchyma. Tumour proper is composed of chondromyxofibroid ground substance material in which the epithelial islands appear to be floating. No extra salivary gland extension noted. 11) 40x View : Highlighting the chondroid areas. 12) 40x View showing mucoid stroma and cellular epithelial component. No nuclear atypia/ pleomorphism/ necrosis or mitoses note

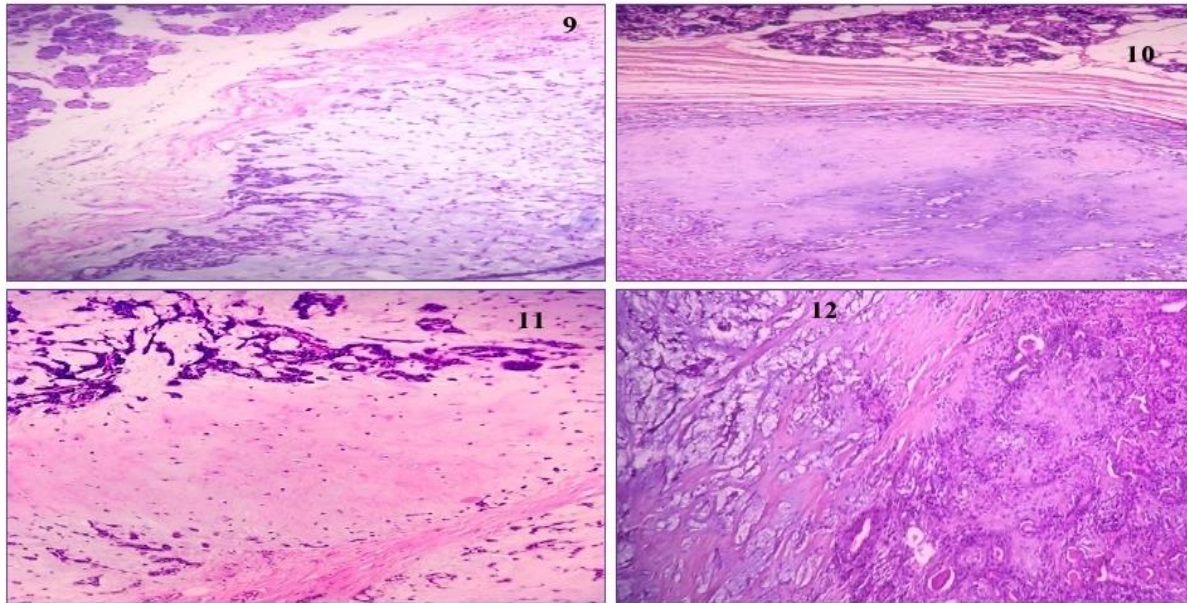


FIGURE: D -FNAC IMAGES OF ADENOID CYSTIC CARCINOMA (Images 13-16) :
13-16) : Showing variably sized clusters, sheets, tubules of basaloid, uniform cells with hyperchromatic nuclei admixed with intraluminal, extracellular and extraluminal, irregular blobs of eosinophilic homogenous depositions of ground substance.

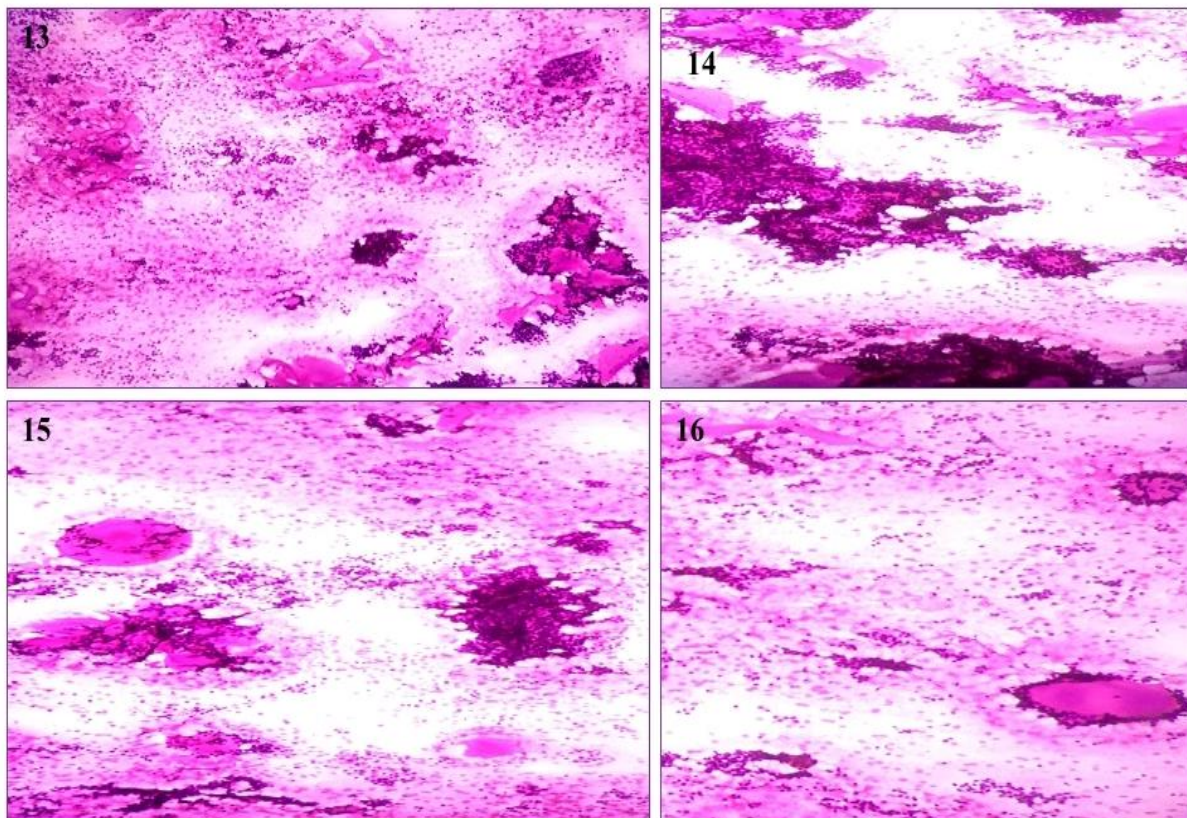


FIGURE: E -HISTOLOGY & IHC IMAGES OF ADENOID CYSTIC CARCINOMA (Images 17-20) :
7) 4x View showing unencapsulated tumour tissue with adjacent native salivary gland.
18 & 19) : 10x & 40x Views showing tumour arranged in tubules, cords, focal cribriform patterns lined by basoid cells with hyperchromasia and intraluminal mucinous secretions.
20) IHC image showing diffuse and intense positive staining for CD117.

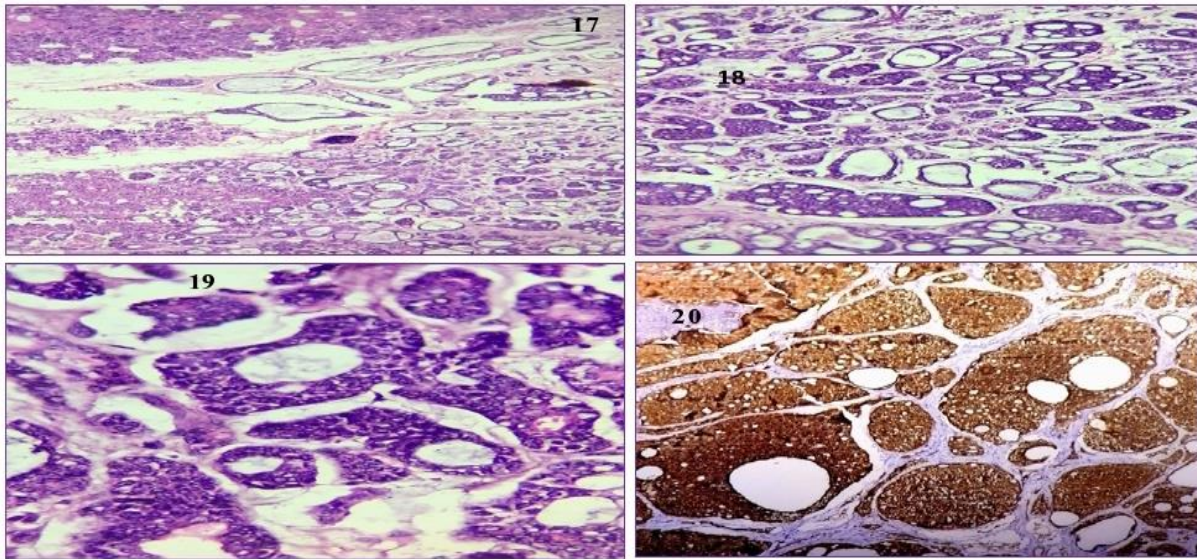
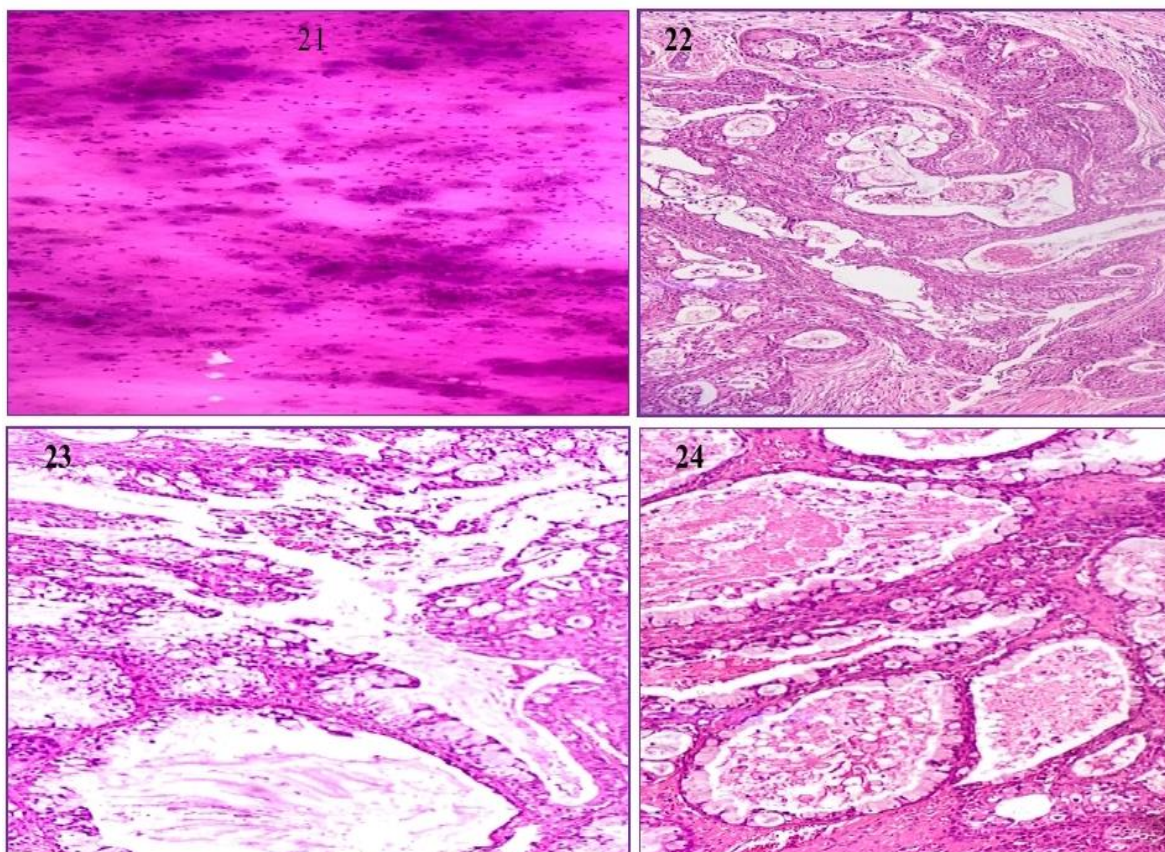


FIGURE: F -MICROSCOPIC IMAGES OF MUCOEPIDERMOID CARCINOMA(Images 21-24) :

21) : Cytology image showing predominantly muciphages and mucoid background, possibly suggesting mucoepidermoid carcinoma in correlation with ultrasound findings.
22) 40x View of H&E stained section showing mostly cystic areas filled with mucinous material, glandular pattern lined by cuboidal, columnar and goblet cells along with few areas of squamous differentiation.
23 & 24) : Showing predominantly mucinous, glandular and cystic areas with clear cell changes.



The common presenting symptom was a painless mass/ swelling in all the cases. Tumor size ranged from 1- 4.5 cm which is in correlation with study by Sharkey, et al. [30], Loke – Wallace, et al. [15]. Histopathological diagnosis given on light microscopy, correlated well with FNAC and Ultrasound findings in almost all cases.

Conclusion

Salivary gland tumors are very rare in children. The most common tumor in the present study was Mucoepidermoid carcinoma of low grade type and parotid gland was the most common site of involvement with female preponderance. Enucleation was done in all the benign neoplasms and parotidectomy in other cases. Only one case showed recurrence of tumor. There were no marked differences in the behavioural pattern of the tumors in children compared to adults.

References

1. Lingen MW, Kumar V. Salivary glands. In: Kuamr V, Abbas AK, Fausto N. Robbin, Cotran, editors. Pathologic basis of disease. 7th edition, Philadelphia: Elsevier Saunders; 2005, p.790-4.
2. Ellis GL, Ayclair PL. Tumours of the salivary glands: Atlas of tumour pathology, 3rd series, fascicle 17, Washington DC: AFIP; 1996, p. 3-10.
3. Pons - Vicente O, Almendros-Marques N, Berini-Aytes L, Gay Escoda C. Minor salivary gland tumors: A clinicopathological study of 18 cases. *Med Oral Pathol Oral Cir Bucal.*, 2008; 13: 582-8.
4. Ethmundan M, Davies B, Pratt CA, Puxeddu R, Brennan PA. Primary epithelial submandibular salivary gland tumors - Review of management in a district general hospital setting. *Oral Oncol.*, 2009; 45: 173-6.
5. Vargas PA, Gerhard R, Araujo Filho VJ, de Castro IV. Salivary gland tumors in a Brazilian population: A retrospective study of 124 cases. *Rev Hosp Clin Fac Med Sao Paulo.*, 2002; 57: 271-6.
6. Li LJ, Li Y, Wen YM, LIU h, Zhao HW. Clinical analysis of salivary gland tumor cases in west china in past 50 years. *Oral Oncol.*, 2008; 44: 187-92.
7. Tilakaratne WM, Jyasooriya PR, Tennakoon TM, Saku T. Epithelial salivary tumors in Sri Lanka: A retrospective study of 713 cases. *Oral Surg Oral Med Oral Pathol Oral Radiol Endod.*, 2009; 108: 90-8.
8. Przewozny T, Stankiewicz C. Neoplasms of the parotid gland in northern Poland, 1991-2000: An epidemiologic study. *Eur Arch Otorhinolaryngol.*, 2004; 261: 369-75.
9. Speight PM, Barrett AW. Salivary gland tumors. *Oral Dis.*, 2002; 8: 229-40.
10. Ito FA, Ito K, Vargas PA, de Almeida OP, Lopes MA. Salivary gland tumors in Brazilian population: A retrospective study of 496 cases. *Int J Oral Maxillofac Surg.*, 2005; 34: 533-6.
11. Speight PM, Barret AW. Salivary Gland Tumours. *ORAL Diseases*, 2002; 8: 229-40.
12. Ma'aaita JK, Al-Kaisi N, Al-Tamimi S, Wraikat A. Salivary gland tumors in Jordan: A retrospective study of 221 patients. *Croat Med J.*, 1999; 40: 539-42.
13. Jaber MA. Intraoral minor salivary gland tumors: A review of 75 cases in a Libyan population. *Int J Oral Maxillofac Surg.*, 2006; 35: 150-4.
14. Eveson JW, Cawson RA. Salivary gland tumours. A review of 2410 cases with particular reference to histological types, site, age and sex distribution. *J Pathol.*, 1985; 146: 51-8.
15. A.C. Waalace, LT. Mac Dougall, J.A. Hides, J.M. Lederman. Salivary gland tumours in Canadian Eskimos. *Cancer*, 1963; 16(10): 1338-52.
16. Young James, Edwad M, Archicibald Stuart D, Sheir Karl J. Needle aspiration

- biopsy in neck and head masses. The American Journal Of Surgery, 1981; 142: 484-489.
17. Pinkston JA, Cole P. Cigarette smoking and Wargthins Tumour. Am J Epidemiol., 1999; 144: 183-7.
 18. El-Ghazayerli MM, Abdel Aziz AS. Salivary Gland Tumours in Egypt and non-Western countries. Br J Cancer, 1964; 18: 649-54.
 19. Shafkat Ahmed, Mohainmad Lateef, Rouf Ahmad. JK-Practitioner, 2002; 9(4): 231-233.
 20. Ogata H, Ebihara S, Mukai K. Salivary gland neoplasms in children. Jpn J Clin Oncol., 1994; 24(2): 88-93.
 21. da Cruz Perez DE, Pires FR, Alves FA, Almeida OP, Kowalski LP. Salivary gland tumors in children and adolescents: a clinicopathologic and immunohistochemical study of fifty-three cases. Int J Pediatr Otorhinolaryngol., 2004; 68(7): 895-902.
 22. Laikui L, Hongwei L, Hongbing J, Zhixiu H. Epithelial salivary gland tumors of children and adolescents in west China population: a clinicopathologic study of 79 cases. J Oral Pathol Med., 2008; 37(4): 201-5.
 23. J.N.P. Davies, O.G. Dodge, D.P. Burkitt. Salivary gland tumours in UGANDA. Cancer, 1963; 17(10): 13338-52.
 24. Narinder Singh, K.S. Mehdratta, Satyanand. Study of salivary gland tumours. Indian Journal of Surgery, 1968; 193-206.
 25. Foote F W Jr, Frazell E L. Tumors of the major salivary glands. In Atlas of Tumor Pathology, sect 4, fasc 11 .Washington D C Armed Forces Institute of Pathology, 1954, p. 8.
 26. Castro E. B., Huvos A. G., Strong E. W., Foote F. W. Tumors of the major salivary glands in children. Cancer, 1972; 29: 312-317.
 27. Pinkston JA, Cole P. Incidence rates of salivary gland tumours - A population based study. Otolaryngol Head Neck Surg., 1999; 120: 834-40.
 28. Poomsawat S, Punyasingh J, Weerapradist W. A retrospective study of 60 cases salivary gland tumours in Thai population. Quintessence Int., 2004; 35: 577-81.
 29. Ito FA, Ito K, Vargas PA, de Almeida OP, Lopes MA. Salivary gland tumours in a Brazilian population. A retrospective study of 496 cases. Int J Oral Maxillofac Surg., 2005; 34: 533-6.
 30. Francis E. Sharkey. Systemic evaluation of the WHO-Classification of salivary gland tumors. A.J.C.P., 1977; 67(3): 272-278.