

Case Report


Sertoli cell nodule of the testis: An incidental finding

Bhardwaj Manisha^{1*}, Joshi Narayani², Nag B.P.³, Yadav M. L.³

¹3rd year PG Resident, ²Professor and Head, ³Professor

Department of Pathology, Mahatma Gandhi University of Medical Sciences and Technology, Sitapura, Jaipur, Rajasthan, India

*Corresponding author email: manishabhardwaj007@gmail.com

	International Archives of Integrated Medicine, Vol. 4, Issue 2, February, 2017. Copy right © 2017, IAIM, All Rights Reserved. Available online at http://iaimjournal.com/ ISSN: 2394-0026 (P) ISSN: 2394-0034 (O)
	Received on: 07-02-2017 Accepted on: 14-02-2017 Source of support: Nil Conflict of interest: None declared.
How to cite this article: Bhardwaj Manisha, Joshi Narayani, Nag B.P., Yadav M. L. Sertoli cell nodule of the testis: An incidental finding. IAIM, 2017; 4(2): 64-67.	

Abstract

The case of a 21year old man with complaints of pain in the lower abdomen reported in the surgery OPD. USG showed a case of undescended testis. A radical Orchidectomy was performed and the specimen was received in the department of pathology. Grossly the testis was normal. Microscopic examination showed the encapsulated nodule composed of tubules lined by immature Sertoli cells interspersed with tubules and Spermatogonia and an interwoven network of hyalinised basement membrane having foci of calcification. The findings were identical to those of a Sertoli cell nodule-A typically microscopic encapsulated lesion commonly detected in crypt orchid testes. Here we present a case of undescended testis where incidentally we found all the features of sertoli cell nodule.

Key words

Sertoli cell nodule, Testis, Orchidectomy.

Introduction

Sertoli cell tumor represents only about 1% of testicular neoplasm and is almost by definition, sex cord tumor that form defined tubular structure [1-4]. A minority of cases is malignant and can be prospectively recognized by well-defined criteria [4]. On the other hand sertoli cell nodules consist of coiled tubules lined by “immature sertoli cell “and are commonly

encountered in undescended testes (cryptorchidism) [5], it is also known as PICK’S Adenoma, testicular tubular adenoma and tubular adenoma of the testis [5]. It is not composed of a clonal cell population i.e. not neoplastic; thus technically should not be called an Adenoma [6]. We presented here a case of undescended testis where incidentally we found all the features of a Sertoli cell nodule.

Case report

A 21 year old male reported to general surgery OPD with history of pain in lower left abdomen for past 10 months. He met with a small accident and since then he started feeling dragging pain in the left lower abdomen. On USG, there was a homogenously hypo echoic ovoid structure seen in left iliac fossa. There was a lack of testicle in the scrotal sac. An Orchidectomy was performed.

Result

We received an Orchidectomy specimen in our department of Pathology consisting of a bisected testis measuring 3.5x2.5x1.7 cm with attached Epididymis and Spermatic cord. Outer surface was smooth and grey white. Cut surface was grey white to grey brown. Spermatic cord was 4 cm in length. Microscopic examination showed seminiferous tubules and ducts of Epididymis. The tubules were dilated and were lined with Sertoli cells and Germ cells. Few small nodules of immature seminiferous tubules (hyperplastic sertoli cell nodules) were also seen. These tubules were containing three elements.

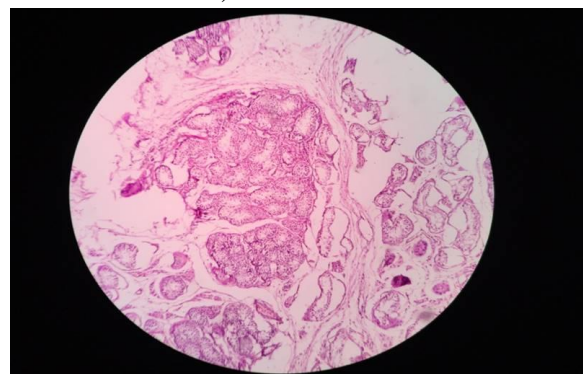
- Elongated immature appearing Sertoli cells with round to oval nuclei and indistinct cytoplasm.
- Interspersed spermatogonia with clear cytoplasm, distinct borders and large round nuclei having slightly granular chromatin
- Interspersed deposit of eosinophilic basement membrane matrix. These nodules were separated from the surrounding parenchyma by a mostly thin fibrovascular capsule (**Figure – 1**).

Discussion

Sertoli cell lesion in this case has all the expected microscopical findings of sertoli cell nodules. Most common age group is 4 to 35 years (median 22 years) [7]. It is common in undescended testis but also present in otherwise normally descended testis. As in our case they are composed of small, often compressed tubules lined by immature fetal type sertoli cells with scant cytoplasm with the

tubules also typically containing scattered non neoplastic spermatogonia. Tubules have thickened basement membrane, which invaginates with in lumen so that basement membrane like material appears to be in the lumen and may be mistaken for a Call-Exner body. Adjacent testis commonly show atrophy with hypo segmented or total absence of spermatogonia.

Figure - 1: H & E stain showing small nodules of immature seminiferous tubules (Hyperplastic sertoli cell nodule).



It may be associated with Mc Cune Albright syndrome [8], peutz jegher [9] and androgen insensitivity syndrome [10] but no molecular cause has been identified.

It is usually an incidental finding in enlarged testis excised for suspicion of malignancy or Orchidectomy performed in patients with Androgen insensitivity syndrome or cryptorchidism. Sertoli cell nodule is usually microscopic but larger nodules may be identified grossly. Rarely Sertoli cell hyperplasia replaces entire testis. Most cases are non-neoplastic with no potential for malignant transformation or metastasis.

Laboratory diagnosis shows elevated serum Estradiol level and low Androgen levels. Serum levels of Anti-Mullerian hormones and Inhibin B may be elevated in some cases and can be used to monitor the evolution of this lesion. Serums AFP, B-HCG, LDH are not elevated and are useful biomarkers to rule out Germ cell tumor which are more common.

Immunohistochemical studies verifies the fetal phenotype of the Sertoli cells and the non-neoplastic nature of the germ cell component .positive markers are Anti-Mullerian hormone, Inhibin A, CK8, CK18 (immature Sertoli cells only). Useful negative markers include alpha Fetoprotein,B-HCG,p53.

Several neoplastic Sertoli cell lesions merit consideration in the differential diagnosis. Sertoli cell tumours of the testis mostly belong in the “Not Otherwise Specified” category [4]. Their cells do not have a fetal phenotype, and they do not have a prominent internalized basement membrane component. When they contain germ cells, it is secondary to incorporation of non-neoplastic elements into the tumor, typically representing a focal finding at the periphery and occurring in clusters that usually lack a perceptible intratubular location [5]. The tubular distribution of regularly occurring, residual germ cells in our case is a strong argument against a Sertoli cell tumour. The sclerosing variant is characterised by a prominent collagenous background [11]. It may contain focal entrapped non-neoplastic tubules, lined by immature Sertoli cells and germ cells, but a mixture of immature Sertoli cells and non-neoplastic germ cells throughout the lesion is not seen. Furthermore, the stroma is sclerotic and not an accumulation of basal membrane substance. The large-cell calcifying Sertoli cell tumor, on the other hand, is characterized by polygonal cells with abundant eosinophilic cytoplasm and relatively large nuclei with prominent nucleoli. The myxoid to fibrous stroma often has scattered, large, irregularly shaped islands of calcification [12]. Gonadoblastoma, another neoplasm considered in the differential diagnosis, has a nested arrangement of large atypical germ cells, similar to seminoma cells, and small cells resembling immature Sertoli cells and granulosa cells [13]. Furthermore, it is most commonly seen in mixed gonadal dysgenesis. Our patient, however, was phenotypically male, with no evidence of mixed gonadal dysgenesis or an inherited syndrome, and the Sertoli cell lesion contained only non-neoplastic germ cells.

Prognosis is based on associated condition. Isolated case reports of development of intratubular large cell Sertoli cell neoplasia with in otherwise classical ISCP, or an associated invasive Sertoli cell tumor, but no reports of progression for up to 10 years, even without Orchidectomy. Treatment is not required since nonneoplastic, and usually an incidental finding.

Conclusion

In conclusion we described a case showing an incidental finding of Sertoli cell nodule in a case of Cryptorchidism in 21 year old man.

References

1. Young R H, Scully R E. Testicular tumors. Chicago: ASCP Press, 1990.
2. Ulbright T M, Amin M B, Young R H. Tumors of the testis, adnexa, spermatic cord, and scrotum. In: Rosai J, ed. Atlas of tumor pathology. Washington, DC: Armed Forces Institute of Pathology, 1999.
3. Sesterhenn I A, Jacobsen G K, Chevillat J., et al. Sex cord/gonadal stromal tumours. In: Eble JN, Sauter G, Epstein JI, Sesterhenn IA, eds. World Health Organization classification of tumours: tumours of the urinary system and male genital organs. Lyon: IARC Press, 2004; 250–258.
4. Young R H, Koelliker D D, Scully R E. Sertoli cell tumors of the testis, not otherwise specified: a clinicopathologic analysis of 60 cases. *Am J Surg Pathol.*, 1998; 22: 709–721.
5. Mostofi F K, Sesterhenn I A. World Health Organization international histological classification of tumours: histological typing of testis tumours. Berlin: Springer-Verlag, 1998.
6. Tadrous, Paul.J. Diagnostic Criteria Handbook in Histopathology: A Surgical Pathology Vade Mecum (1st edition), Wiley, p. 227.
7. Govender D, Sing Y, Chetty R. Sertoli cell nodules in the undescended testis: a

- histochemical, immunohistochemical, and ultrastructural study of hyaline deposits. *J Clin Pathol.*, 2004; 57(8): 802-6.
8. Coutant R, Lumbroso S, Rey R, Lahlou N, Venara M, Rouleau S, Sultan C, Limal JM. Macroorchidism due to autonomous hyperfunction of Sertoli cells and G(s)alpha gene mutation: an unusual expression of McCune-Albright syndrome in a prepubertal boy. *J Clin Endocrinol Metab.*, 2001; 86(4): 1778-81.
 9. Venara M, Rey R, Bergadá I, Mendilaharsu H, Campo S, Chemes H. Sertoli cell proliferations of the infantile testis: an intratubular form of Sertoli cell tumor? *Am J Surg Pathol.*, 2001; 25(10): 1237-44.
 10. Baksu A, Kabukcuoglu F, Baksu B, Goker N. Bilateral sertoli cell adenoma and serous cyst in a patient with androgen insensitivity syndrome. *Eur J Obstet Gynecol Reprod Biol.*, 2004; 114(1): 104-7.
 11. Zukerberg L R, Young R H, Scully R E. Sclerosing Sertoli cell tumor of the testis. A report of 10 cases. *Am J Surg Pathol.*, 1991; 15: 829–834.
 12. Kratzer S S, Ulbright T M, Talerman A., et al. Large cell calcifying Sertoli cell tumor of the testis: contrasting features of six malignant and six benign tumors and a review of the literature. *Am J Surg Pathol.*, 1997; 21: 1271–1280.
 13. Ulbright T M. Tumours containing both germ cell and sex cord/gonadal stromal elements. In: Eble JN, Sauter G, Epstein JI, Sesterhenn IA, eds. *World Health Organization classification of tumours: tumours of the urinary system and male genital organs*. Lyon: IARC Press, 2004; 259–260.