


## Case Report

# Laparoscopically Assisted Pancreaticoduodenectomy – First Sri Lankan Experience

Anthonypillai Ravikaran<sup>1\*</sup>, Galketiya KB<sup>2</sup>, Shaminda RAA<sup>3</sup>,  
Pinto V<sup>4</sup>

<sup>1</sup>Registrar in Surgery, <sup>2</sup>Consultant Surgeon, <sup>3</sup>Senior Registrar in Surgery, <sup>4</sup>Consultant Anaesthetist,  
<sup>1, 2, 3, 4</sup>University Surgical Unit, Teaching Hospital, Peradeniya, Kandy, Sri Lanka

\*Corresponding author email: [scienceuravi@gmail.com](mailto:scienceuravi@gmail.com)

	International Archives of Integrated Medicine, Vol. 4, Issue 1, January, 2017. Copy right © 2017, IAIM, All Rights Reserved. Available online at <a href="http://iaimjournal.com/">http://iaimjournal.com/</a> ISSN: 2394-0026 (P) ISSN: 2394-0034 (O)	
	Received on: 12-12-2016 Source of support: Nil	Accepted on: 20-12-2016 Conflict of interest: None declared.
<b>How to cite this article:</b> Anthonypillai Ravikaran, Galketiya KB, Shaminda RAA, Pinto V. Laparoscopically Assisted Pancreaticoduodenectomy – First Sri Lankan Experience. IAIM, 2017; 4(1): 134-136.		

## Abstract

Pancreaticoduodenectomy (PD) is the curative surgical option for periampullary tumors. Minimally invasive pancreaticoduodenectomy (MIPD) is gaining popularity as the open PD has considerable morbidity and mortality. MIPD was first described in 1994 by Gagner and Pomp. Since then the literature is flourishing with case reports and systematic reviews and are rapidly increasing in recent past. The first Sri Lankan report of laparoscopic pancreatico-duodenectomy with all anastomosis done by mini-laparotomy is in 2015. The patient presented in this report underwent pancreatico-duodenectomy and the hepatico-jejunostomy laparoscopically followed by mini-laparotomy for the other two anastomoses.

## Key words

Laparoscopically, Pancreaticoduodenectomy, Sri Lankan experience.

## Introduction

Pancreaticoduodenectomy (PD) is the curative surgical option for periampullary tumors. Minimally invasive pancreaticoduodenectomy (MIPD) is gaining popularity as the open PD has considerable morbidity and mortality. MIPD was

first described in 1994 by Gagner and Pomp [1]. Since then the literature is flourishing with case reports and systematic reviews and are rapidly increasing in recent past [2-3].

The first Sri Lankan report of laparoscopic pancreatico-duodenectomy with all anastomosis done by mini-laparotomy is in 2015. The patient presented in this report underwent pancreatico-duodenectomy and the hepatico-jejunostomy laparoscopically followed by mini-laparotomy for the other two anastomoses [4].

### **Case report**

A 54 years old male presented with obstructed jaundice. On examination he was deeply icteric, with a palpable gall bladder.

Imaging with ultrasound scan and contrast enhanced CT showed distal CBD obstruction, possibly due to distal CBD stricture or ampullary mass. ERCP was performed and CBD was stented. Laparoscopic pancreaticoduodenectomy was planned. The operation was performed under GA with invasive monitoring. The patient was positioned in 30° reverse Trendelenburg position with both legs abducted to 60°. The optic port was placed above and just right of the umbilicus. Four working ports were inserted, one in epigastrium (5 mm), two in left hypochondrium (10 mm) and one in right lumbar (5 mm). The peritoneal survey revealed normal liver and other viscera.

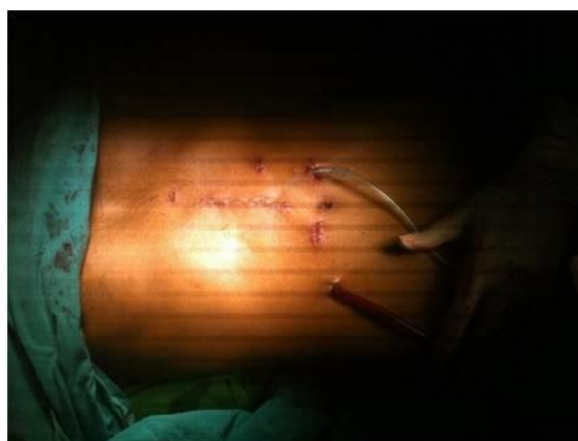
The dissection was performed, using harmonic scalpel and bipolar diathermy. The gastro-colic omentum was divided and mobilization of colon continued up to caecum. Then the duodenum kocherized exposing inferior vena cava and distal part of left renal vein. The portal vein was dissected up to the upper border of the pancreas. Subsequently the common hepatic, hepatic and gastroduodenal arteries were dissected and the gastroduodenal divided between clips. The stomach at antrum and jejunum were divided using endostaplers. The pancreas was divided at neck using harmonic scalpel. The specimen was separated after division of CBD and dissection of uncinate process.

The jejunal loop brought up, enterotomy made and hepaticojejunostomy done laparoscopically.

Through an upper midline mini laparotomy the specimen was retrieved and pancreatico-gastrostomy and gastro-jejunostomy were done through the mini-laparotomy.

Abdomen was closed with two tube drains in sub hepatic and left sub diaphragmatic space through the port sites. Skin was closed with subcuticular PGA. The incision was 5 cm (**Figure - 1**).

**Figure - 1:** Appearance of abdomen after closure.



The operation took 480 minutes with a blood loss of 250 ml. Post-operatively the patient was managed in ICU and he was extubated postoperative day 1. Pain was managed with epidural. Sips of oral fluid was started on day 2 and gradually escalated.

### **Discussion**

Although the MIPD is beneficial in terms of blood loss and minimal handling, the operative time is considerably high, compared to open procedure. The oncological safety is being proven worldwide in well selected patients but yet to be accepted widely [3].

The initial laparoscopic assisted pancreatico-duodenectomies performed in our unit used a mid-line laparotomy to perform anastomoses. This patient had the hepatico-jejunostomy performed laparoscopically which allowed the mini-laparotomy to be limited to 5cm. Having a smaller incision reduces pain allowing early mobilization.

## **Conclusion**

---

The MIPD with laparoscopic assistance is an acceptable technique and it is feasible in our (Sri Lankan) setup.

## **References**

---

1. Gagner M, Pomp A. Laparoscopic pylorus-preserving pancreatoduodenectomy (Abstract). *Surgical Endoscopy*, 1994; 8: 408–410.
2. Boggi U, et al. Laparoscopic pancreaticoduodenectomy: a systematic literature review. *Surg Endosc* [Internet]. 2014 Aug. DOI: 10.1007/s00464-014-3670-z. [cited 2016 May 15];
3. Liao CH, Wu YT, Liu YY, Wang SY, Kang SC, Yeh CN et al. Systemic Review of the Feasibility and Advantage of Minimally Invasive Pancreaticoduodenectomy (Abstract). *World J Surg.*, 2016 May; 40(5): 1218-25.
4. Galketiya KB, Pinto V, Rohankumar R, Jayawickrama BG, Herath A. Laparoscopic resection with minilaparotomy anastomosis for pancreatico-duodenectomy. *The Sri Lanka Journal of Surgery*, 2015; 33(1): 33-34.