


Original Research Article

# Patterns of respiratory tract lesions - A cytohistopathological analysis

Shyamala Srujana<sup>1\*</sup>, K. Bhramaramba<sup>2</sup>, S.S.S. Quadri<sup>1</sup>, KRK Prasad<sup>3</sup>, O. Shravan Kumar<sup>4</sup>

<sup>1</sup>Assistant Professor, <sup>2</sup>Associate Professor, <sup>3</sup>Professor, <sup>4</sup>Professor and HOD  
Department of Pathology, Gandhi Medical College, Secunderabad, India

\*Corresponding author email: [pvsrujana@gmail.com](mailto:pvsrujana@gmail.com)

	International Archives of Integrated Medicine, Vol. 4, Issue 1, January, 2017. Copy right © 2017, IAIM, All Rights Reserved. Available online at <a href="http://iaimjournal.com/">http://iaimjournal.com/</a> ISSN: 2394-0026 (P)                      ISSN: 2394-0034 (O)	
	Received on: 18-09-2016 Source of support: Nil	Accepted on: 07-01-2017 Conflict of interest: None declared.
<b>How to cite this article:</b> Shyamala Srujana, K. Bhramaramba, S.S.S. Quadri, KRK Prasad, O. Shravan Kumar. Patterns of respiratory tract lesions - A cytohistopathological analysis. IAIM, 2017; 4(1): 96-103.		

## Abstract

**Background:** Respiratory tract lesions are commonest for which patients attend the chest clinics. The lesions may be inflammatory or neoplastic.

**Materials and methods:** 594 patients attending to chest clinics and admitted in Government General and Chest Hospital Hyderabad during the period of 2 years from September 2006 to August 2008 were included. All of the patients with clear cut evidence of tuberculosis and pneumonia were excluded from the study.

**Results:** Majority of patients were in the age group of 41-60 years. Youngest patient was 20 years. Males were 443 (74.57%) and females were 151 (25.43%). Commonest presentation was cough with expectoration 567 (94.45%) followed by fever 101 (17.0%), chest pain 84 (14.14%), hemoptysis 57 (9.59%), Shortness of breath 51 (8.58%) and weight loss 34 (5.72%).

**Conclusion:** In the present study even though malignancy was proved with positive cytologic examination by identifying the malignant nature of the cells, the typing of cell was difficult in some cases, but was excellent with squamous cell carcinoma and small cell carcinoma.

## Key words

Pattern, Respiratory tract lesions, Cytohistopathological analysis.

## Introduction

Respiratory tract lesions are commonest for which patients attend the chest clinics. The

lesions may be inflammatory or neoplastic. The types of lesions that are more common are inflammatory ever since the lesions have been

recognized while the tuberculosis and pneumonic lesions used to be the common up to the 19<sup>th</sup> century [1, 2]. The early part of 20<sup>th</sup> century has witnessed massive reduction of pneumonic lung lesions due to tuberculous etiology and also reduction of tuberculosis in developed and developing countries. The resurgence of HIV infection brought tuberculosis back into the commonest infection and also made the fungal infection more common which used to be rate till 20<sup>th</sup> century [3].

The neoplastic lesions more so the lung cancer has increased in its incidence in 20<sup>th</sup> century. The newer investigative techniques such as Sonography, CT scan, endoscopy have not only helped in the early diagnosis of cancer but also in estimating the extent and depth of lesions enabling early and curative treatment. The early symptoms such as cough, dyspnoea are usually neglected by the patient. Hence, the need arose for a simple but sensitive procedure for early diagnosis of respiratory tract lesions. Bronchoscopy is the primary non-surgical technique used to biopsy the pulmonary lesions. As the newer investigative modalities and latest technology is available a study is conducted to understand the patterns of respiratory tract lesions by cytologic and histopathological analysis [4-8].

### **Aim and objectives**

- To evaluate the patterns of respiratory tract lesions.
- To analyze the cytological and histological features of various respiratory tract lesions.
- To understand the etiology of different respiratory tract lesions.
- To evaluate efficacy of various diagnostic techniques used in detection of respiratory tract lesions.

### **Materials and methods**

594 patients attending to chest clinics and admitted in Government General and Chest Hospital Hyderabad during the period of 2 years

from September 2006 to August 2008 were included. All of the patients with clear cut evidence of tuberculosis and pneumonia were excluded from the study.

Materials obtained are sputum, pleural fluid, bronchial wash; bronchial brushings, trans bronchial fine needle aspiration cytology, bronchoalveolar lavage and bronchial biopsy were studied. The materials received as smear are immediately fixed in 95% ethyl alcohol and stained. Materials recovered from bronchial wash, bronchial brushing, BAL is centrifuged and smears are made from sediment also fixed in 95% ethanol and stained. Bronchial biopsy is processed by formalin fixation, paraffin embedding technique and stained.

Cytologic examination of specimens obtained from the respiratory tract is a primary and frequently the initial diagnostic technique performed in patients with respiratory symptoms.

#### **Sputum cytology**

Sputum cytology has been traditional cytologic method for several decades. It has been used routinely in patients with known chest lesions and also for screening a population at risk.

#### **Pleural fluid**

Pleural fluid aspirated should be examined grossly. Smears made by centrifuging the sample and stained. Technical aspects of bronchoscopic procedure have been well summarized by Walloch.

#### **Bronchial washings**

Washings are obtained by repetitive instillation of 3-5 ml of sterile balanced salt solution through the bronchoscope and reaspiration of fluid. The aspirated washing material is centrifuged and smears prepared from the centrifuge and stained.

#### **Bronchial brushings**

Bronchial brushings are obtained by the use of a small circular stiff-bristle brush. Brushings are done before biopsies to avoid excessive and obscuring blood.

### Branchoalveolar lavage

This is most widely and effectively used in immunocompromised patients with pulmonary infiltration for the diagnosis of opportunistic infection. The bronchoscope is advanced into sub segmental bronchii and lavage is performed with warm saline, using a total volume of 60-100 ml. Several sequential fluid instillations are performed with 20 ml aliquots. This fluid floods the air space distal to bronchoscope and is then reaspirated by the bronchoscopist. The BAL sample is processed by cytocentrifugation. Smears are prepared and fix in 95% of ethyl alcohol.

### Fine needle aspiration

FNAC is a widely used technique for the diagnosis of localized pulmonary pathology and is the most effective technique for establishing a definitive diagnosis of lung cancer. The procedure is used less frequently because it is relatively time consuming and requires a skilled bronchoscopist.

### Bronchial biopsy

It was done with regular fenestrated forceps (FB – 35C) or Alligator forceps (FB 35 C). The forceps is placed on the mass and pressed firmly into it before closing the cups and after closing, forceps was withdrawn into scope. Biopsies were obtained from the lesions from different sites. The site was washed between biopsy with normal saline to avoid the biopsy of overlying clotted blood. The specimens were presented in 10% formalin and processed for Histopathological examination using Hematoxylin Eosin stain. Special stain such as PAS was done wherever necessary.

### Results

A total number of 594 cases were evaluated from Gandhi Hospital, Government General and Chest Hospital Hyderabad during the period of two years from October 2006 to September 2008.

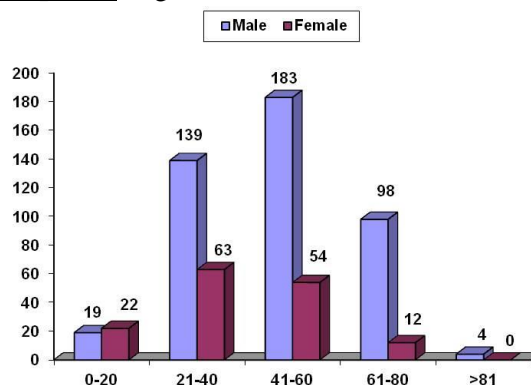
All the cases after clinical examination were subjected to routine basic investigations and

those cases with clinical (or) radiological suspicious of malignancy were subjected to bronchoscopic examination.

Cytological evaluation was done on sputum, pleural fluid and material obtained by bronchoscope such as bronchial wash, bronchial brushings, bronchio alveolar lavage, transbronchial FNAC. Histopathological examination was done on material obtained by forceps biopsy.

Majority of patients were in the age group of 41-60 years. Youngest patient was 20 years. Males were 443 (74.57%) and females were 151 (25.43%) as per **Graph - 1**.

**Graph – 1:** Age and sex distribution.



Commonest presentation was cough with expectoration 567 (94.45%) followed by fever 101 (17.0%), chest pain 84 (14.14%), hemoptysis 57 (9.59%), Shortness of breath 51 (8.58%) and weight loss 34 (5.72%) as per **Table - 1**.

**Table – 1:** Presenting symptoms.

Symptoms	Cases	%
Cough and Expectoration	567	94.45
Fever	101	17.00
Chest Pain	84	14.14
Hemoptysis	57	9.59
Shortness of Breath	51	8.58
Weight Loss	34	5.72

Radiological findings were as per **Table – 2**. Sputum examination has shown the non-specific inflammatory lesion detected in 97.4% of cases

and tuberculosis in 2.6% of cases (**Graph – 2, Table – 3**).

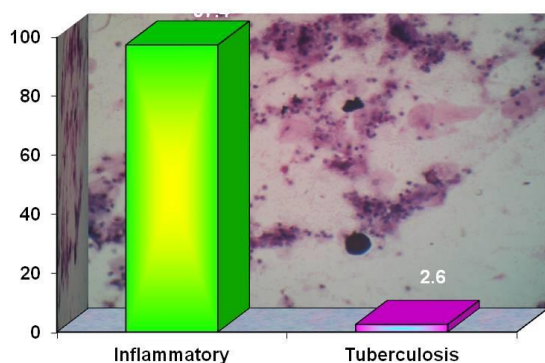
**Table – 2:** Radiological findings.

Radiological findings	Cases	%
Pleural effusion	89	21.65
Homogeneous opacity	176	42.83
Mass lesion	68	16.54
Collapse of lung	52	12.65
Hilar adenopathy	26	6.33
<b>Total</b>	<b>411</b>	<b>100.00</b>

**Table - 3:** Cytological features sputum examination.

Sputum examination	Cases	%
Inflammatory	580	97.6
Tuberculosis	14	2.4
<b>Total</b>	<b>594</b>	<b>100.00</b>

**Graph – 2:** Sputum examination.



Pleural fluid analysis showed predominantly inflammatory pathology in 92% cases, atypical in 2.4% cases and malignancy in 5.6% cases (**Table – 4, Graph – 3**).

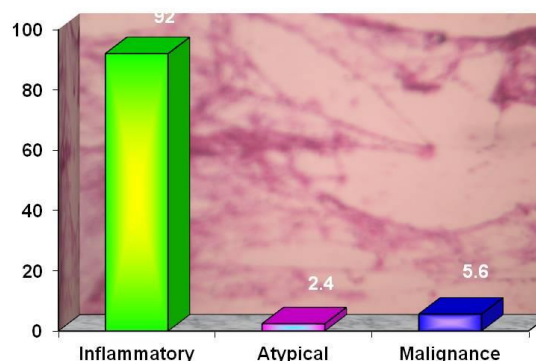
**Table - 4:** Pleural fluid cytology.

Pleural fluid cytology	Cases	%
Inflammatory	82	92.00
Atypical	02	2.40
Malignancy	05	5.60
<b>Total</b>	<b>89</b>	<b>100.00</b>

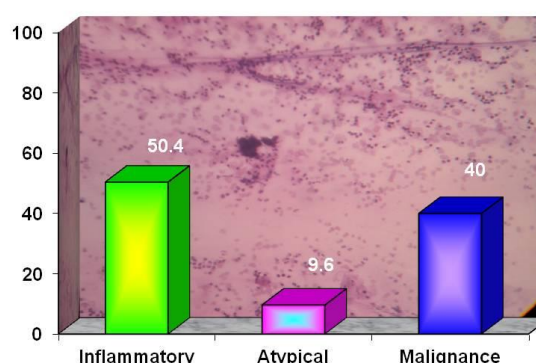
Bronchial brush smears showed predominantly inflammatory pathology in 50.4% cases, atypical

in 9.6% cases and malignancy in 40.0% of cases in a total of 115 cases examined (**Table – 5, Graph – 4, Photo - 1**).

**Graph - 3:** Pleural fluid cytology.



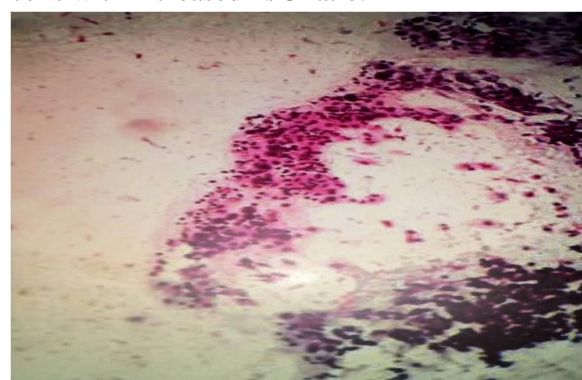
**Graph – 4:** Bronchial brush.



**Table – 5:** Bronchial brush.

Bronchial brush	Cases	%
Inflammatory	58	50.40
Atypical	10	9.60
Malignancy	47	40.00
<b>Total</b>	<b>115</b>	<b>100.00</b>

**Photo – 1:** Bronchial brush smears showing bronchial epithelial cells and clusters of large cells with increased N/C ratio.



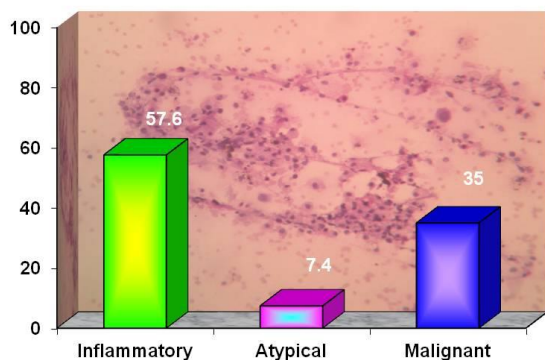


Smears prepared from Bronchial wash showed predominantly inflammatory pathology in 57.6% cases, atypical in 7.4% cases and malignancy in 35.0% of cases in a total of 215 cases examined (**Table – 6, Graph – 5, Photo – 2, 3**).

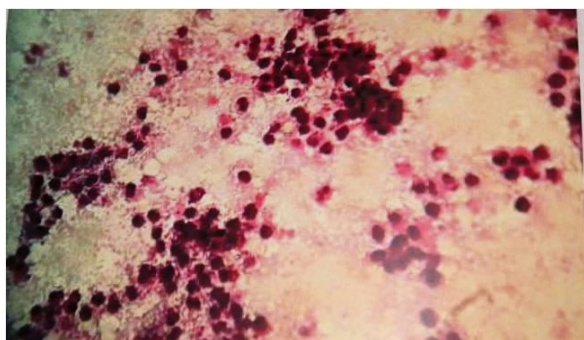
**Table - 6:** Bronchial wash.

Bronchial wash	Cases	%
Inflammatory	124	57.60
Atypical	16	7.40
Malignancy	75	35.00
<b>Total</b>	<b>215</b>	<b>100.00</b>

**Graph – 5:** Bronchial wash.



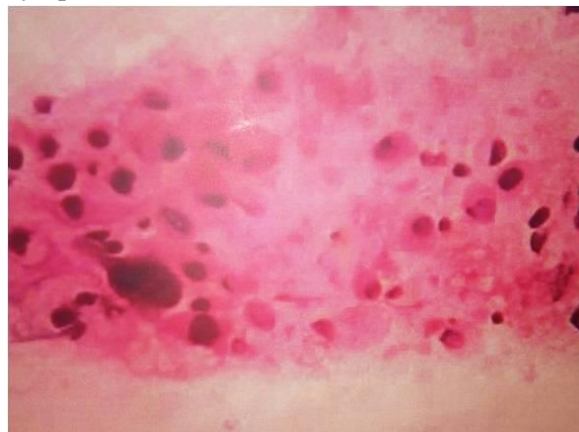**Photo – 2:** Bronchial wash smear showing few endobronchial cells and clusters of inflammatory cells.



Broncho alveolar lavage smears showed predominantly inflammatory pathology in 95.0% cases, atypical in 3.5% cases and malignancy in 1.5% cases (**Table – 7, Graph – 6**). Bronchial biopsy sections showed predominantly malignancy in 56.0% cases and inflammatory in 44.0% cases (**Table – 8, Graph – 7**). In the present study, non-specific inflammation is

predominant in (67%) cases followed by malignancy in (25%) of cases (**Graph – 8**).

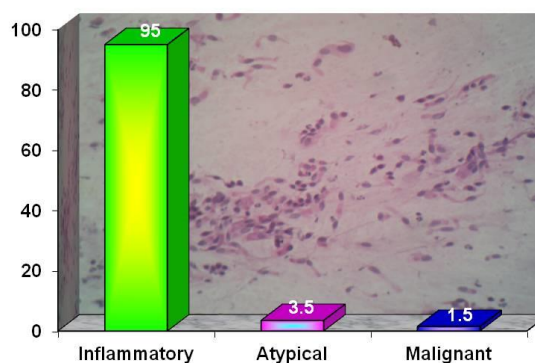
**Photo – 3:** Bronchial wash smears showing inflammatory cells and cells with vacuolated cytoplasm.



**Table – 7:** Broncho alveolar lavage.

Broncho alveolar lavage	Cases	%
Inflammatory	57	95.00
Atypical	02	3.50
Malignancy	01	1.50
<b>Total</b>	<b>60</b>	<b>100.00</b>

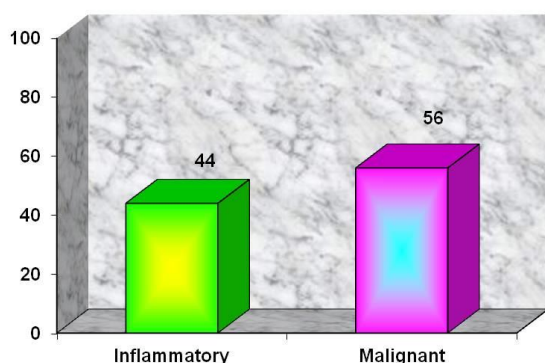
**Graph – 6:** Broncho alveolar lavage.



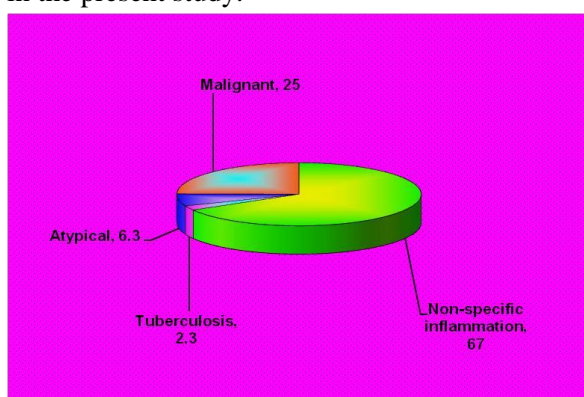
**Table – 8:** Bronchial biopsy.

Bronchial biopsy	Cases	%
Inflammatory	15	44.00
Malignancy	27	56.00
<b>Total</b>	<b>42</b>	<b>100.00</b>

**Graph – 7:** Bronchial biopsy.



**Graph – 8:** Patterns of respiratory tract lesions in the present study.



## Discussion

Respiratory tract lesions are more common for which public seek medical advice. The increasing incidence of HIV and environmental pollution also raised the incidence of respiratory tract lesions [9].

Cough with expectoration is the earliest symptom in patients with debilitating diseases of lung which is highly neglected by the patients. Patients seek medical attention only when severity arises in the form of dysnoea [10].

Laboratory examination of the samples plays a key role in early identification of the respiratory tract lesions.

In India so much so at a PHC/district level no diagnostic tool is available. Hence, the need arises for a simple but sensitive procedure in early diagnosis of respiratory tract lesions. Sputum examination has been the commonest

and easy laboratory test available in rural areas from more than a century. It is also the commonest investigation advocated in booking the cases of Tuberculosis lung for treatment [11].

Bronchoscopy has an important role in the diagnosis of respiratory tract lesions and also diagnosing lung cancers. It is the most useful investigation in the diagnosis of respiratory tract lesions which provide tissue for pathological examination.

Analysis of patterns of respiratory tract lesions by all types of investigations used in our study revealed predominantly inflammatory pathology, in 411 patients accounting up to 67% followed by malignancy in 136 patients accounting up to 23%. In 47 patients' analysis of different specimens showed presence of atypical cells suspicious of malignancy accounting for 6.3%. This category included cases in which abnormal cells are scarce to permit a definitive diagnosis of malignancy and cells with atypical features that may progress to high grade lesions [12-15].

All the studies were showing predominantly non-neoplastic inflammatory lesions followed by malignancy. Results of present study are also similar dominated by 69.3% of inflammatory and 23% of malignant cases.

In the present study among the male patients diagnosed as carcinoma lung, cigarette smoking was the most important predominant risk factor identified. Contrary to the western studies none of the females were smokers. Similar observations were reported by one study [13]. In their study of squamous cell carcinoma most of the patients were males and smokers. One study showed the relationship of bronchial cancer with smoking and found more male smokers in squamous and small cell type of carcinoma than in adeno carcinoma. In their study 40% of women with bronchial cancer were non-smokers and their predominant cell type being adeno carcinoma [12].

In the present study combined results of bronchial brushing and washings are similar to other studies [14, 15]. One of the reasons for the increase in the diagnostic yield with brushing followed by washing could be related to cells dislodged by brush will lie in the lumen, picked by immediate wash technique.

## Conclusion

Clinical data of 594 patients attending the respiratory clinics and admitted in hospital have been analyzed.

- Male to female ratio was 3: 1 (Male – 325; Female – 169).
- Age ranging from 20-90 years.
- 90% of men were smokers; none of the females were smokers.
- Cough with expectoration and fever were the commonest symptoms (90%)
- The commonest radiographic finding was homogeneous opacity in lung.
- Endoscopically gross appearance of the lesion did not correlate with any specific histologic type.
- Bronchial brush followed by wash is more efficient technique in detecting respiratory tract malignancies on cytology.
- Predominant lesion was inflammatory type other than tuberculosis accounting up to 67% followed by malignancy accounting up to 23%
- About 6.3 % cases were suspected of malignancy in cytology.
- Among the malignant lesions commonest is squamous cell carcinoma followed by adeno carcinoma and adeno squamous carcinoma.
- Cytology is a reliable method in the diagnosis of respiratory tract lesions. However, confirmation by biopsy is considered to be gold standard.

In the present study even though malignancy was proved with positive cytologic examination by identifying the malignant nature of the cells, the typing of cell was difficult in some cases, but

was excellent with squamous cell carcinoma and small cell carcinoma. When confirmation of malignancy was obtained by only cytologic examination, other procedures were resorted to like percutaneous needle biopsy, pleural biopsy, CT guided biopsy to confirm the cell type.

## References

1. Grunze H. A critical review and evaluation of cytodiagnosis in chest disease. *Acta Cytol.*, 1990; 14: 175 -198.
2. Kenneth C, Seven MD, Fadi Abdul Kareem. Guidelines of the Papanicolaou society of Cytopathology for the examination of cytologic specimens obtained from the respiratory tract. *Diagnostic Cyto pathology*, 21: 90-98.
3. Koss LG. *Diagnostic cytology and its histopathological basis.* 3<sup>rd</sup> edition, Philadelphia JB, Lippin Cott, 1979.
4. Choudhary BA, Kochichi Yonea, Nausherway K. Burki. Fibreoptic bronchoscopy – Comparison of procedures used in the diagnosis of lung lesions. *The Journal of Thoracic and Cardiovascular Surgery*, 1978; 76: 33-37.
5. Ahmed M, Afzal S, Sared W. Efficacy of bronchial wash cytology and its correlation with biopsy in lung lesions. *Journal of Pak. Med. Assoc.*, 2006; 54(1): 13-16.
6. Bedrossian CW, Rybka DL. Bronchial brushing during fibreoptic bronchoscopy for cyto diagnosis of lung diseases- Comparison with sputum and bronchial washings. *Acta cytological.*, 1976; 20(5): 446-53.
7. Dr. Alberto Fernandez Villar. Comparison between bronchial wash done prior or after brushings. *Acta cytol.*, 1970; 44: 243-250.
8. Linder J, Radio STJ, Robbins RA. BAL in the cytological diagnosis of the lung lesions, *Acta Cytol.*, 1987; 3: 796-801.
9. Park IA, Ham EK. Evaluation of cytopathological diagnosis of lung

- lesions. Korean J. Cytopathology, 1991; 2: 20-27.
10. Marluce Bibbo. Comprehensive cytopathology. 3<sup>rd</sup> edition, 1997; p. 331-334.
  11. Mak VH, Jonston ID, Huzel MR. Value of washings and brushings at fiberoptic bronchoscopy in the diagnosis of lung lesions. Thorax, 1990; 45: 373.
  12. Stocker JT. The respiratory tract. 2<sup>nd</sup> edition, Lippin Cott Williams & Williams, 2001; p. 446-517.
  13. Rosenthal DL. Cytology of inflammatory disease of the lung in diagnostic cytology. Tutorial of cytology, Chicago, 1998.
  14. Reichenburger F, Weber J, Tamm M. The value of transbronchial needle aspiration in the diagnosis of peripheral pulmonary lesions. Chest, 1999; 116: 704-8.
  15. Erozan YS. Cytopathologic diagnosis of pulmonary neoplasm in sputum and bronchoscopic specimen. Diagnostic Pathology, 1986; 3: 188-195.