



CODEN [USA]: IAJPBB

ISSN: 2349-7750

**INDO AMERICAN JOURNAL OF  
PHARMACEUTICAL SCIENCES**<http://doi.org/10.5281/zenodo.816201>Available online at: <http://www.iajps.com>**Case Study****THE BRAIN TUMOR WITH THE ONSET OF SYMPTOMS  
SIMILAR TO THOSE OF FUNCTIONAL NEUROLOGICAL  
SYMPTOM DISORDER, A CASE REPORT****Reza Valizadeh<sup>1</sup>, Majid Rezaei-Tavirani<sup>2</sup>, Foruzan Kavarizadeh<sup>3\*</sup>**<sup>1</sup>Department of Psychiatry, School of Medicine, Ilam University of Medical Sciences, Ilam, Iran.<sup>2</sup>Department of Surgery, School of Medicine, Ilam University of Medical Sciences, Ilam, Iran.<sup>3</sup>School of Medicine, Ilam University of Medical Sciences, Ilam, Iran.**Abstract:**

*Brain tumor with post-stress symptoms is considered as a rare case. The diagnostic methods of brain tumor are clinical examinations, CT scan, and MRI, and if it is not treated, it will lead to the patient's death. The best treatment method of brain tumor is brain surgery. In the present research, the brain tumor was studied when the post-stress symptoms in a special case started to appear. The patient is a 48-year-old man suffering from spasm in the left side limbs after an argument. In the patient's brain CT scan, a lesion was observed in the right frontal lobe, and in the patient's brain MRI, it was seen in the right frontal. Having been diagnosed with tumor, the patient was referred to a surgeon. Given the findings of the present study, one can assert that the specialists must not overlook patients referring to them with functional neurologic symptoms, and all the symptoms need to be studied thoroughly; if brain tumors are diagnosed early enough, they can be treated through surgery, and their widespread complications can be prevented.*

**Key Words:** *Brain Tumor, Functional Neurological, Symptom Disorder.***Corresponding author:****Foruzan Kavarizadeh,**

School of Medicine,

Ilam University of Medical Sciences,

Ilam, Iran. Email: [pubmedp@gmail.com](mailto:pubmedp@gmail.com);Tel: [+989189127926703](tel:+989189127926703)

QR code



Please cite this article in press as Foruzan Kavarizadeh et al, *The Brain Tumor with the Onset of Symptoms Similar To Those of Functional Neurological Symptom Disorder, a Case Report*, Indo Am. J. P. Sci, 2017; 4(06).

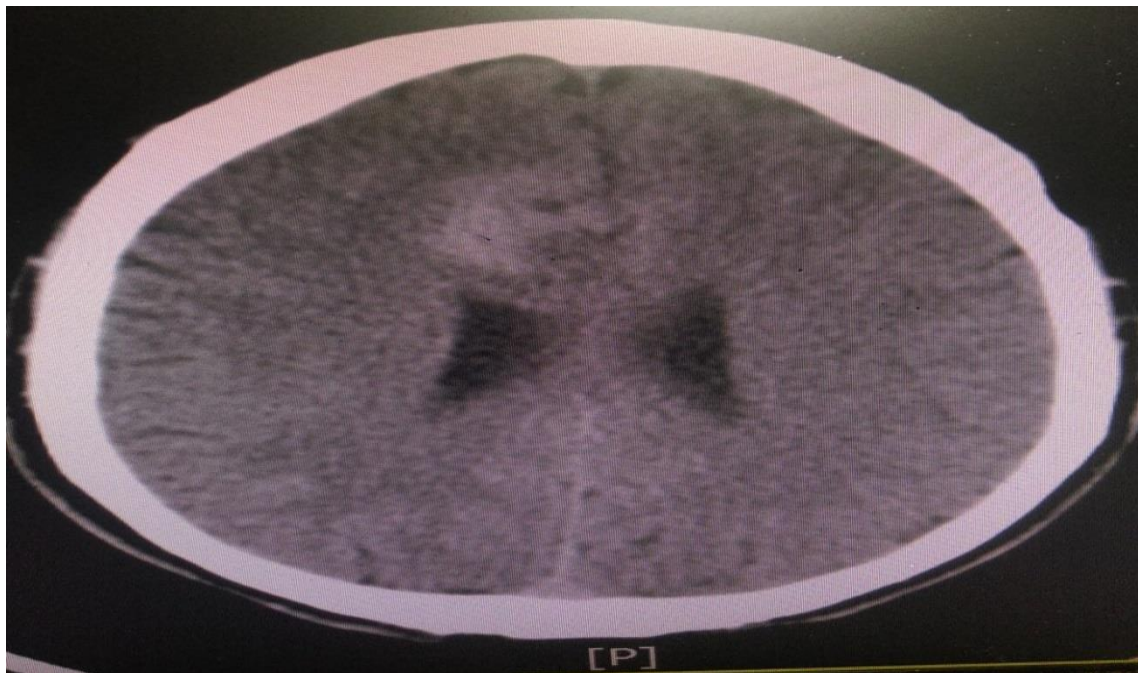**INTRODUCTION:**

Acute and chronic immobilization is considered as stress in different creature. Like other kinds of stress, it can have different effects on the physiology in different areas. Despite this, the exact mechanisms of the effects of stress on human body's physiopathology are still unknown [1]. However, recent studies have indicated that some kinds of stresses have an important role in tumorigenesis and development of the tumor malignancy [2]. Stress brings about disorder and disturbance in the individual's performance, and if it is not controlled and treated, it will lead to disorder. In patients suffering from underlying problems, severe stress in rare case will cause brain tumor [3, 4]. The diagnostic methods of brain tumor include clinical examination, CT scan, and MRI. If brain tumors are not treated, they will lead to the patient's death, and the best treatment method of brain tumor is brain surgery [5, 6]. In the present research, the brain tumor was studied when the post-stress symptoms in a special case started to appear.

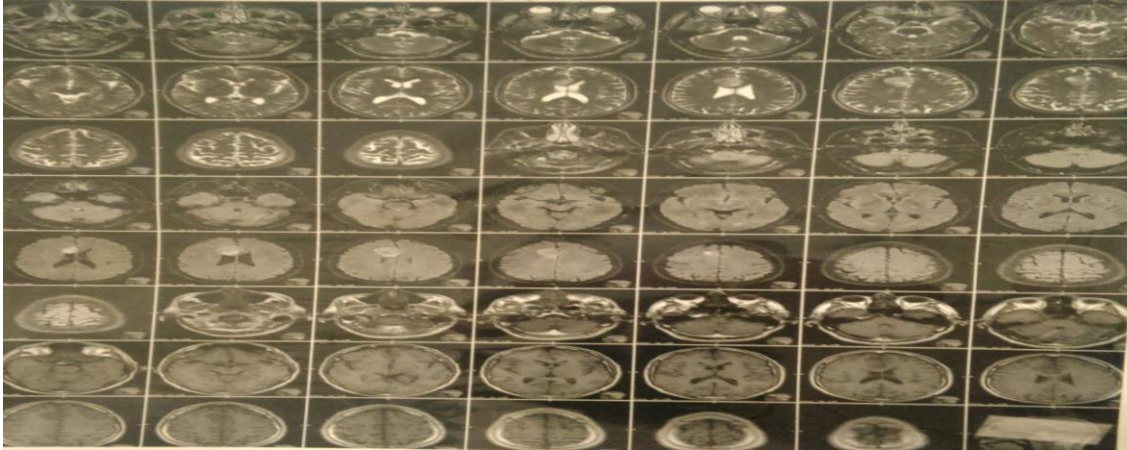
**CASE PRESENTATION:**

A 48-year-old male patient has experienced spasm in the left-side organs of his body, which takes long for a few seconds; nonetheless, the collateral symptoms include headache, balance disorder, dizziness, visual

impairment and dysarthria. The eye examination unravels that the pupils are soft and reactive to the light and the conjunctiva is not pale. Moreover, scleral icterus and JVP are prominent, LAP and mucus are dry, and the lips are cyanotic. Force appears to be normal in the organs. The analyses have indicated that the problems the patient is having such as stiffness of the organs in the left side of the body are followed by an argument and ostensibly disappeared after the transfer to hospital. It was not but in the following day, however, that the symptoms reappeared again. Consequently, upon the decision of his psychiatrist, he came under treatment. Next, a Brain CT Scan was deemed necessary with which a lesion was revealed in the right frontal lobe. After a neurology consultation and running a Brain MRI, a tumor was revealed in the right frontal lobe. Hence, after the diagnosis of the tumor, the patient was introduced to a surgeon. As it is displayed in, the ST Scan image of the patient shows that there is a lesion in the right frontal lobe (Figure 1). For further scrutiny, a neurology consultation was made; the neurology specialist requested a Brain MRI for more accurate conclusions. The Brain MRI reveals a tumor in the right frontal lobe. After the tumor diagnosis, the patient was referred to a neurology surgeon for its removal (Figure 2).



**Fig 1:** The CT scan is done, which, as it can be seen, there is a lesion in the right frontal lobe.



**Fig 2: The Brain MRI was performed which shows a tumor in the right frontal lobe.**

### DISCUSSION:

The functional neurological symptom disorder includes some signs and symptoms that are initiated following stress and therefore appear as motor/sensory neurological symptoms. Moreover, it is worthy of mentioning that it could be long lasting and 30 percent of individuals might suffer from conversion symptoms [3, 7]. The therapist is normally able to find a relationship between the neurological symptoms and the psychological factors; nevertheless, the medical neurologic disorders have a high incidence rate amongst patients with conversion disorder and shall not be overlooked [4, 8]. Approximately 25 to 50 percent of the people who were diagnosed with the conversion disorder were observed to wind up having other medical disorders in the complementary examinations. Although medical examinations such as neurological scrutiny are most of the time helpful, sometimes, like in the current patient, they seem to exhibit no abnormality whatsoever during the examination. Most importantly, the patient seemed to have experienced complications following a severe stress. At any rate, unlike this patient who came to display the tumor symptoms following a severe stress, the symptoms of the tumor are expected to begin appearing gradually. Therefore, in a nutshell, in the patients with conversion-disorder symptoms, apart from common examinations, thorough and comprehensive check-ups are absolutely essential.

### CONCLUSION:

Given the findings of the present study, one can assert that the specialists must not overlook patients referring to them with functional neurologic symptoms, and all the symptoms need to be studied thoroughly; if brain tumors are diagnosed early enough, they can be treated through surgery, and their widespread complications can be prevented.

### REFERENCES:

1. Teague CR, Dhabhar FS, Barton RH, Beckwith-Hall B, Powell J, Cobain M, et al. Metabonomic Studies on the Physiological Effects of Acute and Chronic Psychological Stress in Sprague-Dawley Rats. *J Proteome Res* 2007; 6(6): 2080-93.
2. Ben-Eliyahu S. The promotion of tumor metastasis by surgery and stress: immunological basis and implications for psychoneuroimmunology. *Brain, behavior, and immunity* 2003; 17(1): 27-36.
3. Kaneko S, Nomura K, Yoshimura T, Yamaguchi N. Trend of brain tumor incidence by histological subtypes in Japan: estimation from the Brain Tumor Registry of Japan, 1973–1993. *J Neurooncol* 2002; 60(1): 61–9.
4. Hoffman S, Propp JM, McCarthy BJ. Temporal trends in incidence of primary brain tumors in the United States, 1985–1999. *Neuro Oncol* 2006; 8(1): 27–37.
5. Wigertz A, Lönn S, Mathiesen T, Ahlbom A, Hall P, Feychting M. Swedish Interphone Study Group: Risk of brain tumors associated with exposure to exogenous female sex hormones. *Am J Epidemiology* 2006; 164(7): 629–36.
6. Lönn S, Klæboe L, Hall P, Mathiesen T, Auvinen A, Christensen HC, Johansen C, Salminen T, Tynes T, Feychting M. Incidence trends of adult primary Intracerebral tumors in four Nordic countries. *Int J Cancer* 2004; 108(3): 450–55.
7. Schellinger KA, Propp JM, Villano JL, McCarthy BJ. Descriptive epidemiology of primary spinal cord tumors. *J Neuro-Oncol* 2008; 87(2): 173-9.
8. Kutluk T, Varan A, Kafalı C, Hayran M, Söylemezoğlu F, Zorlu F, et al. Pediatric intramedullary spinal cord tumors: A single center experience. *Eur J Paediatr Neurol* 2015; 19(1): 41-7.