

RESEARCH ARTICLE

Alleviation of Ibuprofen induced Nephrotoxicity by vitamin supplementations

Kalaivani B^{1*}, Thangapandiyan K² and Vanithakumari G²

¹Department of Zoology, Sri Sarada College for Women (Autonomous), Salem – 636 016, Tamil Nadu, India.

²Department of Zoology, Bharathiyar University, Coimbatore - 641 046.

*Corresponding author Email: kalai03win@yahoo.co.in

Manuscript details:

Received: 02.05.2016
Accepted: 15.06.2016
Published : 23.07.2016

Editor: Dr. Arvind Chavhan

Cite this article as:

Kalaivani B, Thangapandiyan K and Vanithakumari G (2016) Alleviation of Ibuprofen induced Nephrotoxicity by vitamin supplementations, *International J. of Life Sciences*, 4(2): 203-206.

Acknowledgement

With the sense of high resolve, the authors wish to express grateful thanks to the great advisor Dr. K. M. Kulkarni (Former DE, Higher Education, Pune), the bird watcher and local expert M. H. Deshmukh who helped and supported for completion of this research paper during this study. Also the authors very much thanks to the forest and irrigation departments, Gondia to grant the permission for this research.

Copyright: © 2016 | Author(s), This is an open access article under the terms of the Creative Commons Attribution-Non-Commercial - No Derivs License, which permits use and distribution in any medium, provided the original work is properly cited, the use is non-commercial and no modifications or adaptations are made.

ABSTRACT

The aim of the present study was to investigate the impact of the combined administration of vitamin B complex and 'C' on ibuprofen induced nephrotoxicity. Male albino rats were subdivided into five groups: the first was a control group, the second and third received Ibuprofen at a low and high dose of 1.5 mg and 3 mg/ 100g body weight / day respectively for 7 days, the fourth group received high dose and vitamin supplementation (B complex and C) at a dosage of ml /100g body weight, the fifth group rats received high dose (3 mg) of ibuprofen for seven days followed by withdrawal of drug for a further seven days. No significant changes were observed in the histopathology of kidney tissues in the control rats. The Ibuprofen treatment affects the histopathology of kidney. Low dose treatment group, minor glomerular abnormality (increase in size). In high dose also increase in size of glomerulus was observed. Many proximal convoluted tubules showed hydropic changes, coagulation necrosis and degeneration with inflammation treated group showed normalcy of the histoarchitecture of the kidney. Regeneration was started in the withdrawal group.

Key words : Ibuprophen, nephrotoxicity, B complex, Vitamin C.

INTRODUCTION

Non-steroidal anti-inflammatory drugs (NSAIDs) which are often used for the relief of non specific fever (Radwan, 2000), continue to be important for the palliation of pain (Simon, 1994). They are the most frequently used medications for the treatment of a variety of common chronic and acute inflammatory conditions (Manoukian *et al.*, 1996). Ibuprofen is a new generation of non-steroidal anti-inflammatory drug, which is classified under non-narcotic analgesic (Kleincknecht, 1985). It is sought as a safer, more effective alternative to either corticoids or aspirin for the use with rheumatoid arthritis and osteoarthritis.

Several studies have indicated that NSAIDs can generally prevent prostaglandin synthesis from arachidonic acid by inhibiting the activity

of the prostaglandin synthesis enzyme cyclooxygenase. The inhibition of cyclooxygenase activity removes the influence of cyclooxygenase products on cellular events (Brune, 1984). Prostaglandins are formed from dietary essential fatty acids (principally arachidonic acid) esterified to phospholipids and in some instances to triglycerides. These products have some potent biological activities affecting cell function in every organ. The high levels of NSAIDs also inhibit the activities of various enzymes, the proteoglycan synthesis from chondrocytes, the ionic exchange rate and the processes depend on prostaglandins (Rubatelli et al., 1979; Skoutakis et al., 1988 and Kayaalp, 1998). It will be worthwhile to study its effect on the histology of the kidney which contributes for excretion and metabolism.

MATERIALS AND METHODS

Mature adult albino rats of wistar strain weighing 150gm – 250gm were procured from Tamil Nadu Agricultural University, Coimbatore, India. The animals were maintained in an animal house with standard facilities having CPCSA approval (722/02a/CPCSEA). They were kept under uniform conditions at light and water ad libitum. They were fed with rat feed. The animals were randomly divided into following five groups of 5 each; Group I: normal control group, Group II : low dose of Ibuprofen (1.5mg), group III: High dose of Ibuprofen (3mg) / 100g body weight / day for seven days, , Group IV: High dose + vitamin supplementation (B complex and Vitamin C (0.05mg, Group V: High dose for seven days followed by withdrawal period of further seven days.

The animals were weighed before and after treatment schedule. Twenty four hours after the last treatment schedule the animals were sacrificed by decapitation method. The kidney was dissected out and cleaned off adhering connective tissues and blood strains, washed in cold physiological saline thrice, blotted on a filter paper and weighed using electronic balance. Small piece of kidney was fixed in formaldehyde (10%) for histological sections.

RESULTS AND DISCUSSION

The kidney is a vital organ concerned with metabolism and excretion of drugs (Passmore and Roboson, 1973). It is therefore important to study the effect of any

pharmaceutical agent on this organ, if it is intended to be used for human use. The effects of NSAIDs in therapeutic doses on oxidative stress have been established (Kappus, 1986), but there is little knowledge on the effects of high doses of these drugs (Akdogan and Akkus, 1997). The kidney is another organ affected by the toxic effects of NSAIDs (Cliver and Stoff, 1984; Palmer, 1995). It is known to be important target organ for the unwanted effects of NSAID, which can produce acute, reversible permanent effects (Brune and Linder, 1992). The NSAIDs adversely change the kidney function (Goodman and Gilman, 1995) and may play a role in the induction of membranous nephropathy (Radford et al., 1996). During Ibuprofen metabolism the number of reactive oxygen species (ROS) can be increased. These products induced peroxidative damage in renal tissue. The increase in SOD levels and MDA activity in renal tissue may indicate peroxidative damage. Gokcimen et al., (2000) and (2001) reported that, in the renal tissue structural changes including reduction in GSH-PX and GR activities in the kidney and increased MDA levels in serum. The decrease in GSH-PX activity possibly destroys the process of H₂O₂ conversion into H₂O. Thus, in the present study also cell damage in kidney tissue was induced by increased levels of H₂O₂.

Histological examination of the kidney tissues in the control group (fig 1) revealed no significant deviation from the normal histological structures. The changes in the histological structure of the kidney was significantly affected by the second, third, fourth and fifth Ibuprofen treatments. In the low dose drug treatment (fig - 2), kidney tissue showed minor glomerular abnormality. The glomerulus was slightly increased in size, and showed minor degree of increase in Mesangial cells. A few proximal convoluted tubules (PCT) showed hydropic changes and few were degenerated. In the high dose Ibuprofen treated group (fig - 3), thickening of basement membrane of the glomerulus, and increase in glomerular size and cellularity. Many proximal convoluted tubules showed changes with narrowed lumen. Many tubules revealed coagulation necrosis and degeneration with inflammation and infiltration of lymphocytes.

Vitamin B complex and vitamin C supplementation (fig 4 & 5) along with Ibuprofen showed reduced hydropic changes in proximal convoluted tubules. There was rather a diffuse glomerulonephritis brought about by a

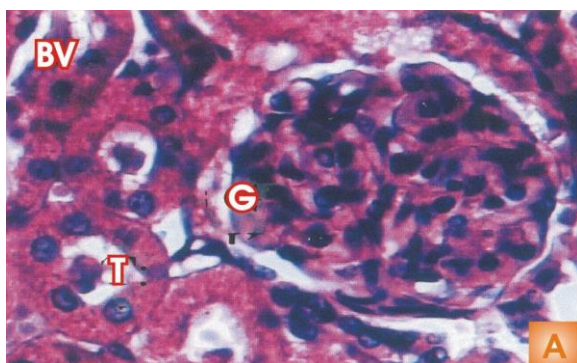


Fig. 1: Control group (400X)

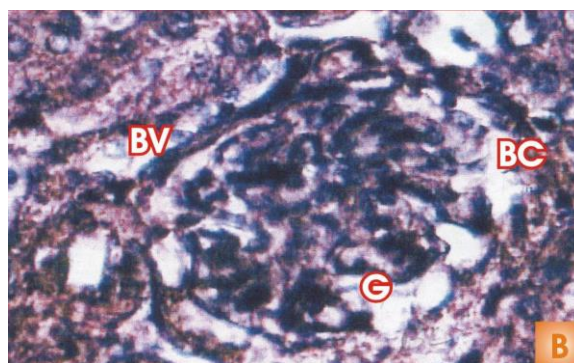


Fig.2: Ibuprofen low dose treatment group (400X)

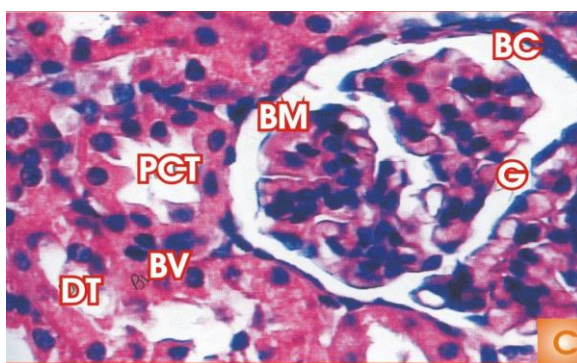


Fig 3: Ibuprofen high dose treatment group (1000X)

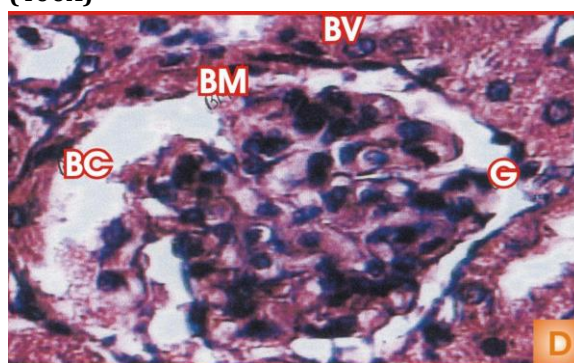


Fig. 4: Ibuprofen high dose + vitamin B complex treatment group (400X)

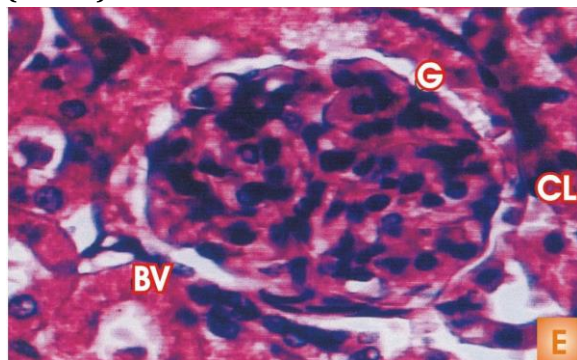


Fig 5:High dose + vitamin C treatment group (400X)

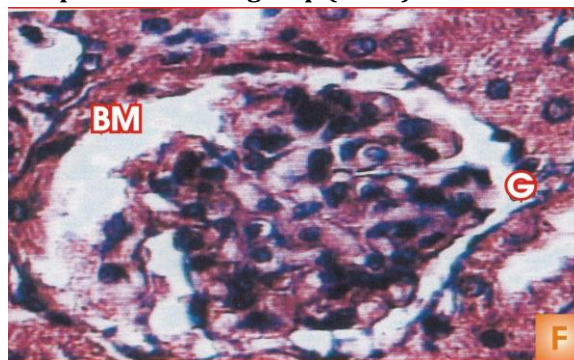


Fig 6: High dose + withdrawal group (400X)

T -Tubule	BV - Blood Vessel	G - Glomerulus
PCT - Proximal Convolved Tubules	DT -Distal Tubules	CT -Collecting Tubules
BC -Bowman's capsule		

high dose Ibuprofen treatment was withdrawn, the kidney histology showed considerable changes. There was a uniform thickening of the basement membrane of the glomerulus. In many proximal convoluted tubules, the diameter was reduced. Infiltration of glomerular tuft was also observed.

In the present study, degeneration in proximal convoluted tubules and hydropic changes was induced by Ibuprofen treatment especially very prominent in the high dose drug treated group suggesting an altered

fluid homeostasis and cell injury. In the kidney, cellular swelling appears whenever cells are incapable of maintaining ionic and fluid homeostasis (Cotron *et al.*, 1989). This effect of the drug appears to be permanent, since drug withdrawal (fig- 6) was not effective in restoring the histoarchitecture. The given dose of vitamin B complex could not restore the histoarchitecture of the tissue, since the diffuse glomerular nephritic condition was observed. Thus, in the present study, severe necrosis, glomerulo nephritis and segmental necrosis was brought about

by Ibuprofen treatment suggesting nephrotoxicity of the drug. Similar nephrotoxicity has been induced by other NSAIDs like diclofenac in rats as humans in the form of nephritic syndrome, interstitial nephritis and renal failure (Robinson *et al.*, 1990; Calvo Allen *et al.*, 1994; Kulling *et al.*, 1995 and Veena, 1996).

REFERENCES

- Akdogan M and Akkus S (1997) Investigation of erythrocyte antioxidant enzyme activities in high dose diclofenac sodium applied rats. *Biomed res.*, 12; 53 – 57.
- Brune K (1984) The concept of inflammatory mediators. In: Discoveries in Pharmacology. Vol. 2., Haemodynamics. Hormones and inflammation. Parnhan., 94; 467 – 521.
- Brune K and Lindner J (1992) Side effects of anti-inflammatory drugs. In: Inflammation and Drug Therapy series. 5; 198 – 203.
- Calvo – Alen J, Decoss MA, Rodriquez – Valverde V, Escallado R, Flouuz J and Arias M (1994) Subclinical renal toxicity to rheumatoid patients receiving long term treatment with non – steroidal anti- inflammatory drug. *J Rheumatol.*, 21 (9); 1742 – 1747.
- Clover DM and Stoff JS (1984) Renal syndromes associated with non-steroidal anti-inflammatory drugs. *N Eng J Med Bio.*, 563 – 572.
- Cotron RS, Vinaykumar and Robbins SL (1989) Cellular injury and absorption. The kidney. In: Robbins pathologic basis of diseases (eds). 4th edn., W.B. Saunders Company, Tokyo, pp. 1 – 38 and 1011 – 1083.
- Gokcimen A, Akdogan M and Karaoz E (2000) Structural and biochemical changes in liver and renal tissues induced by an acute high dose of diclofenac sodium in rats. *Bio Med Res.*, 11; 293 – 302.
- Gokcimen A, Aydin G, Karaoz E, Malas MA and Oncu M (2001) Effect of Diclofenac sodium administration during pregnancy in the postnatal blood. *Fetal Diagn Ther.*, 16; 417 – 422.
- Goodman and Gilman S (1995) Diclofenac sodium. The pharmacologic basis of therapeutics. Ninth Edition. New York, p. 637.
- Kappus H (1986) Overview of enzyme systems involved in bioreduction of drugs and redox cycling. *Biochem Pharmacol.*, 35; 1 – 6.
- Kayaalp SO (1998) Rasonel tedavi yonunden tibbi farmakoloji. *Medicine pharmacology.*, 8; Baski Ankara.
- Kleinknecht D (1985) Interstitial nephritis, the nephritic syndrome and chronic renal failure to non-steroidal anti-inflammatory drugs.
- Kulling EJ, Beckman EA and Skagive AS (1995) Renal impairment after acute diclofenac, naproxen and sulidac over doses. *J Toxicol clin Toxicol.*, 33 (2), 173 – 177.
- Manoukian AV and Carson L (1996) Non steroidal anti-inflammatory drug induced hepatic disorders. Incidence and Prevention. *Drug Safe.*, 15; 64-71.
- Palmer BF (1995) Renal complications associated with use of non-steroidal anti-inflammatory agents. *J Invest Med.*, 43; 516 – 553.
- Passmore R and Roboson JS (1973) A Companion to medical sciences, Blackwell scientific Publications, Oxford, pp 473.
- Radwan MA and Zidovudine (2000) Diclofenac and ketoprofen pharmacokinetic interations in rats. *J Pharm Pharmacol.*, 52; 665-669.
- Robinson J, Malleson P, Linenman D and Carter J (1990) Nephrotic syndrome associated with non-steroidal anti-inflammatory drug use in two children. *Pediatrics.*, 85(5); 844 – 847.
- Rubatelli FF, Chiozza ML, Zanardo V and Cantrutti F (1979) Effect of maternal treatment with indomethicin. *J Pediatr.*, 94; 161 – 165.
- Simon LS (1994) Actions and toxic effects of the non-steroidal anti-inflammatory drugs. *Curr Opin Rheumatol.*, 6; 238 – 251.
- Skoutakis VA, Carter CA, Mickle TR, Smith VH, Arkin CR, Alissandratos J and Petty DE (1988) Review of diclofenac and evaluation of its place in therapy as a non – steroidal anti- inflammatory agent. *Drug Intell Clin Pharm.*, 22; 850-859.
- Veena Somnathabhath (1996) Effect of voverol (2,2,6 – Dichlorophenyl amino benzene acetic acid Monosodium salt) on the haematology, histochemical and biochemical profile of liver, kidney and pancreas of adult albino rats. M.Phil., dissertation submitted to the Bharathiar University, Coimbatore, India.