

Contents lists available at [ScienceDirect](http://www.sciencedirect.com)

## Asian Pacific Journal of Reproduction

journal homepage: [www.apjr.net](http://www.apjr.net)

<http://dx.doi.org/10.1016/j.apjr.2016.03.001>

### A rare cause of infertility: A late complication of female genital mutilation

Ferjaoui Mohamed Aimen\*, François Monneins, Gharrad Majed, Belaiba Amine

*Le service de gynécologie et obstétrique, Le centre hospitalier de Gonesse, 95500 Gonesse, France*

#### ARTICLE INFO

##### Article history:

Received 14 Mar 2016

Accepted 15 Mar 2016

Available online 5 Apr 2016

##### Keywords:

Female genital mutilation

Epidermal inclusion cyst

Clitoral reconstruction

Vulvoplasty

#### ABSTRACT

Female genital mutilation is a cultural practice in many African and Asian societies based usually on religious beliefs. This practice made by a non medical and traditional practitioner with non sterile instruments is a source of many complications such as infection, acute and chronic pain, life-threatening hemorrhage, sexual dysfunction, and rarely epidermal inclusion cysts. We report a case of a large epidermal inclusion cyst in a 36-year-old patient, 30 years after a female genital mutilation (FGM). The patient complains of a two-year-secondary infertility with a self-imaging alteration and a sexual dysfunction. The management of this complication was based on surgery with a psychological support and sexual therapies.

## 1. Introduction

Female genital mutilation (FGM) or excision is an old cultural practice in many African and Asian societies. The most common reason to practice genital mutilation is religious beliefs. The consequences of this practice on the women health are well known specially psychologic impact, self-imaging alteration, sexual dysfunction and organic or physical impact as obstetrical complications, dyspareunia and chronic pelvic pain. Complications may occurs immediately or in several years later.

We report a case of a rare long-term complications of FGM and how to manage it.

## 2. Case report

A 36-year-old Malian women, gravida 1 para 1, presents a two-year-secondary infertility. Her medical history is marked by a genital excision at the age of 5 years, she has no memory about this incident and she avoids to talk about. She had a vaginal

delivery 2 years ago without complications. Since two years, the patient feels embarrassed to do sexual intercourse because of a vulvar tumor which increases in size gradually. She had no pelvic pain neither dyspareunia but she describes recently a hypoactive sexual desire.

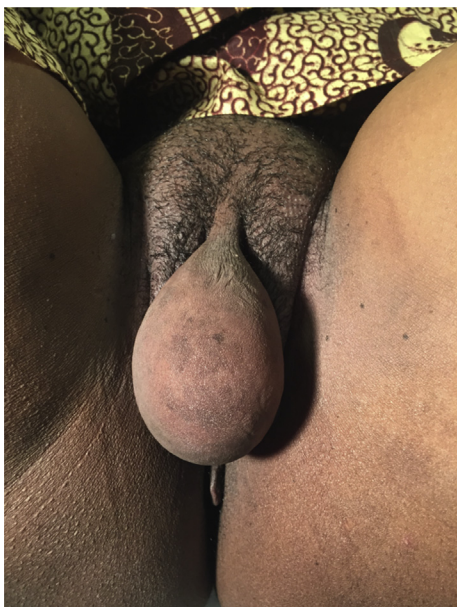The clinical examination showed a vulvar tumor covered by a regular skin depending on the clitoral area measuring 7 cm. This tumor had a soft consistence (Figure 1) without adhesion to the deep planes. The urinary meatus is individualized and uncompressed. All vulva elements appeared normal (labia majora, labia minora, vestibule and vaginal orifice) except clitoral area marked by the vulvar tumor located in the scar of the mutilation (Figure 2). Talking about the vulvar lesion, the patient recognize psychological discomfort specially during sexual intercourse. An ultrasound imaging was performed, it showed a multi-locular cystic tumor measuring 4 cm × 7 cm with heterogeneously dense contained (Figure 3).

The decision was to perform a cystectomy and a vulvar plastic procedure under spinal anesthesia. Through a vertical incision we proceed to a dissection of the cyst. Cystectomy was performed after ligation of the cyst pedicle. The root of the glans clitoris was individualized. Finally a clitoral reconstruction and vulvoplasty were performed (Figure 4). The histologic examination showed an epidermic cyst containing abundant laminated keratin.

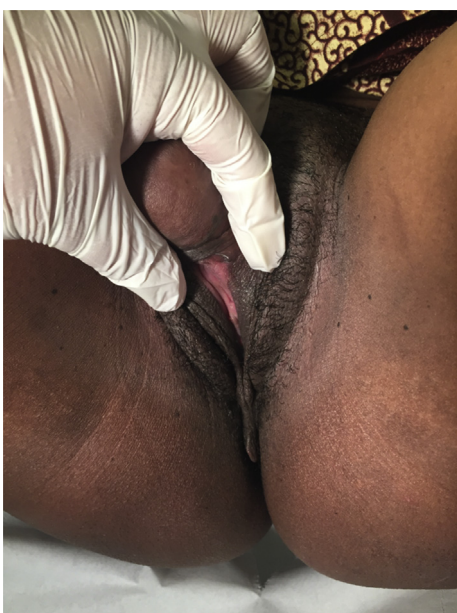\*Corresponding author: Ferjaoui Mohamed Aimen, Le service de gynécologie et obstétrique, Le centre hospitalier de Gonesse, 95500 Gonesse, France

E-mail: [ferjaoui16@yahoo.fr](mailto:ferjaoui16@yahoo.fr)

Peer review under responsibility of Hainan Medical College.



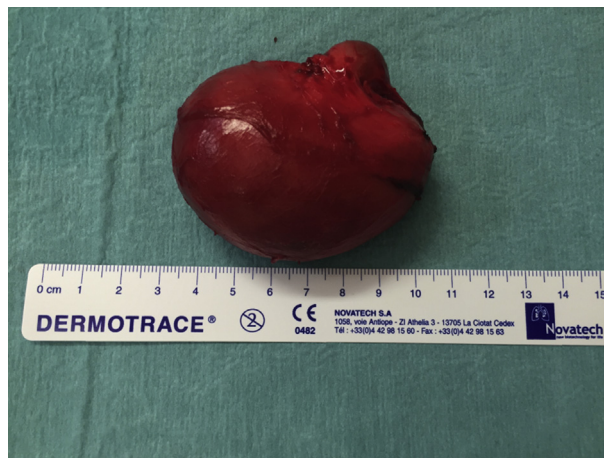**Figure 1.** A large vulvar tumor, with a soft consistence.



**Figure 2.** The vulvar elements are normal except the clitoral area. The urinary meatus is individualized and uncompressed.

### 3. Discussion

Female genital mutilation is a cultural practice characterizing a lot of African and Asian societies. This clinical entity can be seen in occidental countries among immigrant communities [1]. According to the World Health Organization (WHO) guidelines, the classification of female genital mutilation is based on four types: Type I (clitoridectomy) a partial or total removal of the clitoris and, rarely, the prepuce as well; type II (excision) is the partial or total removal of the clitoris and the labia minora, with or without excision of the labia majora;



**Figure 3.** The cyst measuring 7 cm.

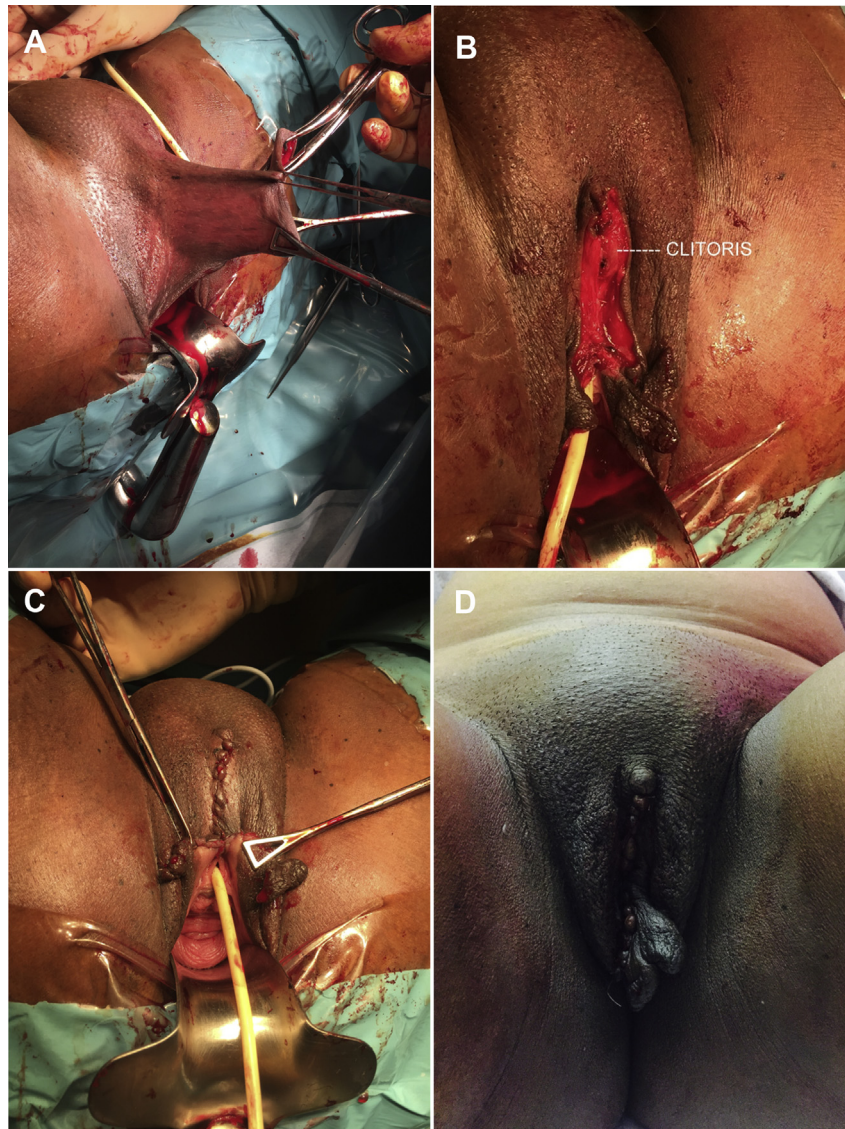
type III (infibulation) is the most severe form and involves partial or total removal of the labia minora and majora with or without clitoridectomy. Type IV FGM refers to all other harmful procedures to the female genitalia for nonmedical purposes, e.g., pricking, piercing, incising, scraping, and cauterizing the genital area. Type I and II constitute about 80% of FGM. Our patient is from an African country (Mali) and she had a type I FGM (circumcision).

This procedure is made by a nonmedical traditional practitioner commonly an old women. Non sterile instruments are used without any hemostasis. That's why FGM is a common source of complications such as life-threatening hemorrhage, infection, acute and chronic pelvic pain, dysmenorrhoea, sexual dysfunction [2], obstetrics complications, psychological complication and infertility [3].

The epidermal inclusion cyst is a frequent complication of FGM [3], and it arises from the development of epidermal cells in the FGM scar within a circumscribed space, the sebaceous gland secretion and epidermic cells peeling allow the cyst to grow up [4]. The delay from circumcision to development of the inclusion cyst is variable. In the case of our patient the cyst appeared after pregnancy, probably because of the hormonal environment during pregnancy stimulating secretion of sebaceous glands and epidermal cells of the embedded tissue in the FGM scar. This hypothesis was discussed in the medical literature [5].

Clinically, the epidermal inclusion cyst is painless and can be associated with other urogenital symptoms, such as dyspareunia, micturition disturbances, and vulval pain [6,7]. Usually, epidermal inclusion cysts are small sized but huge cysts are reported in a few cases [8]. In the present case, the cyst measured 7 cm. The management of this FGM complication is surgery: enucleation of the cyst in case of small cysts [9] and a clitoral reconstruction with vulvoplasty in larger cysts [10]. No post operative recurrence are reported [9].

In France, the UNICEF estimate that 53 000 adult women were victims of FGM [11]. In the study of Ndiaye *et al.* [12] the management of FGM and their complications is not based only on surgery, which can be badly lived, but requires a medical, psychological and sexological management.



**Figure 4.** After the cystectomy, we proceed on a resection of the excess skin (A and B) and observed the immediate post operative aspect (C) and 3-day post operative aspect (D).

### Conflict of interest statement

The authors declare no conflict of interests.

### References

- [1] World Health Organization (WHO). *Female genital mutilation*. Fact sheet no. 241. Geneva, Switzerland: World Health Organization (WHO) Media Center; 2008.
- [2] Alsibiani SA, Rouzi AA. Sexual function in women with female genital mutilation. *Fertil Steril* 2010; **93**: 722-724.
- [3] Abdulrahim AR. Epidermal clitoral inclusion cysts: not a rare complication of female genital mutilation. *Hum Reprod* 2010; **25**(7): 1672-1674.
- [4] Larsen U, Okonofua FE. Female circumcision and obstetric complications. *Int J Gynaecol Obstet* 2002; **77**: 255-265.
- [5] Rizk DE. A large clitoral epidermoid inclusion cyst first presenting in adulthood following childhood circumcision. *J Obstet Gynaecol* 2007; **27**: 445-448.
- [6] Rouzi AA, Sindi O, Radhan B, Ba'aqeel H. Epidermal clitoral inclusion cyst after type I female genital mutilation. *Am J Obstet Gynecol* 2001; **185**: 569-571.
- [7] World Health Organization (WHO). *Female genital mutilation: prevalence and distribution*. Fact sheet no. 153. Geneva, Switzerland: World Health Organization (WHO) Media Center; 1997.
- [8] Ofodile FA, Oluwasanmi JO. Post-circumcision epidermoid inclusion cysts of the clitoris. *Plast Reconstr Surg* 1979; **63**: 485-486.
- [9] Asante A, Omurtag K, Roberts C. Epidermal inclusion cyst of the clitoris 30 years after female genital mutilation. *Fertil Steril* 2010; **94**(3): 1097. e1-3.
- [10] Abdulcadir J, Rodriguez MI, Say L. A systematic review of the evidence on clitoral reconstruction after female genital mutilation/cutting. *Int J Gynaecol Obstet* 2015; **129**(2): 93-97.
- [11] UNICEF. *Female genital mutilation/cutting: a statistical overview and exploration of the dynamics of change*. *Library J* 2013; **21**(42): 184-190.
- [12] Antonetti Ndiaye E, Fall S, Beltran L. Benefits of multidisciplinary care for excised women. *Gynecol Obstet Biol Reprod* 2015; **44**: 862-869.