



Contents lists available at ScienceDirect

Asian Pacific Journal of Reproduction

Journal homepage: www.elsevier.com/locate/apjr



Document heading 10.1016/S2305-0500(13)60067-6

Primary infertility associated with neuroendocrine tumor (Carcinoid) of the appendix

Brad B Swelstad^{1,2}, Paul R Brezina^{3*}, Clark T Johnson³, Nina Resetkova³, Irene Woo³, Lisa Kolp³

¹Reproductive Care Center, 1725 East 1450 South, Suite 300, Clearfield, Utah, 84015, United States

²Reproductive Care Center, 10150 Petunia Way (10150 S. 1405 E), Sandy, Utah, 84092, United States

³Johns Hopkins University, School of Medicine, Department of Gynecology and Obstetrics, Division of Reproductive Endocrinology and Infertility, Phipps 264, 600 N. Wolfe Street, Baltimore, MD 21287, United States

ARTICLE INFO

Article history:

Received 8 May 2012

Received in revised form 15 May 2012

Accepted 15 June 2012

Available online 20 June 2012

Keywords:

Appendiceal

Appendiceal carcinoid

Carcinoid

Infertility

ABSTRACT

Neuroendocrine tumors of the appendix (NET-A), formerly called appendiceal carcinoids, are rare tumors of the gastrointestinal tract. Appendiceal tumors have also been associated with infertility. However, in many of these cases, significant abdominal pathology, specifically pseudomyxoma peritonei, was identified during definitive surgical intervention. A 34-year-old nulligravid woman undergoing infertility evaluation presented to an academic tertiary care fertility center. An abnormal mass was identified on hysterosalpingogram and CT confirmed appendiceal mass. Surgical removal of the mass was performed and histopathology was consistent with an NET-A with negative margins extending to the serosa. Two months after surgical intervention, the patient spontaneously conceived pregnancy and subsequently delivered a normal infant. This case exemplifies the importance of careful inspection of radiologic films by the gynecologic physician. Of added interest, this case describes an asymptomatic NET-A associated with primary infertility. To our knowledge, this is the first report of an incidentally identified NET-A that resulted in primary infertility.

1. Introduction

Neuroendocrine tumors of the appendix (NET-A), formerly called appendiceal carcinoids, are rare tumors of the gastrointestinal tract[1]. NET-A have been reported rarely in women who achieve pregnancy spontaneously[2–6]. However, infertility has been associated with NET-A tumors that present with significant abdominal pathology such as pseudomyxoma peritonei[7–9]. A literature search did not identify a case of NET-A without significant pathology that was associated with infertility. To our knowledge, this is the first report of an incidentally identified NET-A, without other identified anatomic changes, that was associated with primary infertility.

2. Case report

A 34 year old married nulligravida was evaluated for primary infertility of unknown etiology for 2 years duration. She reported a good state of health without any known health problems. Her past medical, surgical, gynecological, family, and social history and review of systems are noncontributory. During this interview, she specifically denied any history of thyroid dysfunction including feeling unusually warm (flushed), abdominal discomfort, or abnormalities of the genitourinary or gastrointestinal tract (diarrhea, etc.).

Physical examination and transvaginal pelvic ultrasound were both normal. Initial evaluation included menstrual cycle day 2 labs (FSH, estradiol, TSH, free T4, and prolactin), a hysterosalpingogram, and a semen analysis. All laboratory levels for both partners were within acceptable ranges. Hysterosalpingogram (HSG) revealed a normal uterine cavity with bilateral tubal patency and a 3 cm laminated

*Corresponding author: Paul R. Brezina, Johns Hopkins University, School of Medicine, Department of Gynecology and Obstetrics, Division of Reproductive Endocrinology and Infertility, Phipps 264, 600 N. Wolfe Street, Baltimore, MD 21287, United States.

Tel: 410-583-2750

E-mail: pbrezin1@jhmi.edu

calcified density in the right pelvis, well above the level of other pelvic structures (Figure 1). At the time of the study, obvious sources of artifact, such as loose jewelry, were ruled out by evaluating the drapes, radiologic equipment, etc. used during the procedure. Based on the location of this calcification, pathology originating from the ovary, such as a dermoid cyst, or the uterus, such as a calcified myoma, was not likely. In addition, the mass was larger than would be expected for a gallstone or renal calculus. After consultation with a radiologist, the pelvic density was felt to be a large appendicolith or foreign body in the gastrointestinal tract and follow up radiologic evaluation was recommended.

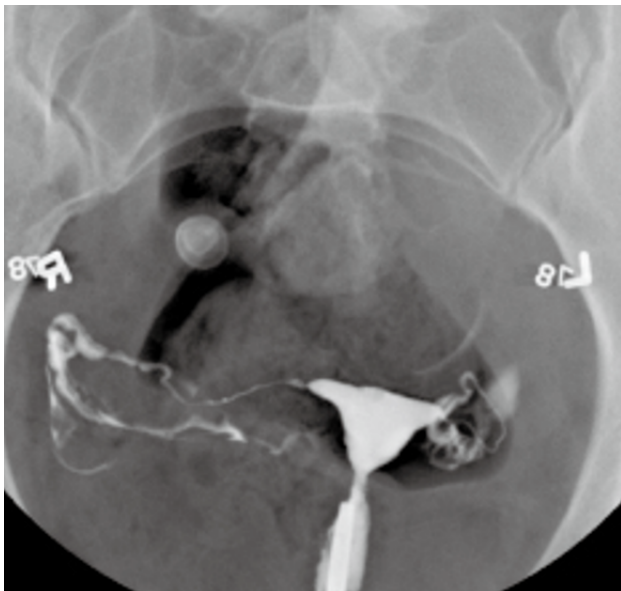


Figure 1. HSG showing 3 cm calcified pelvic density. This figure shows, on hysterosalpingogram (HSG), a normal uterus and fallopian tubes along with a calcified density in the right abdomen.

Computed tomography (CT) of the pelvis with bone window enhancement revealed two large calcifications in the lower right pelvis, the smaller one in the more distal aspect of the appendix measuring 0.9 cm × 0.8 cm and the larger in the more proximal aspect of the appendix measuring 1.7 cm × 1.2 cm (Figure 2). No significant appendiceal inflammation was noted to suggest acute appendicitis. No significant intrapelvic adenopathy, free fluid, or suspicious bony lesions were visualized.

An operative laparoscopic appendectomy was performed to remove the mass, which was not associated with surrounding normal female pelvic anatomy. Histopathology was consistent with an NET-A with negative margins extending to the serosa. The patient's postoperative course was unremarkable. Two months following her appendectomy, the patient conceived spontaneously and subsequently delivered a health infant at term.

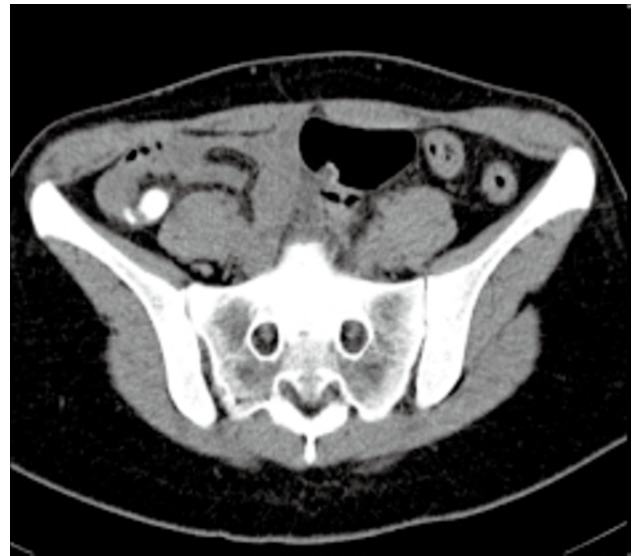

Figure 2. Pelvic CT with two calcified masses in enlarged non-inflamed appendix. This figure shows, on computed tomography (CT), a calcified density in the right abdomen.

3. Discussion

This case highlights the importance of understanding the differential diagnosis for pelvic masses detected by HSG in reproductive age women. Appendiceal abnormalities often result in a mucocele, a term describing a dilated appendix with retention of mucus secondary to either hypersecretion or obstruction, as with a neoplasia^[10]. Calcifications, as were seen on HSG in this case, are seen in many different types of appendiceal tumors^[11]. Of appendiceal neoplasms, NET-A are the most common^[11]. Appendectomy alone is considered optimal treatment in the vast majority of small tumors with overall 5-year survival rates approaching 99%^[12]. In the patient described in this case, close monitoring without further interventions are recommended.

The apparent relationship between an asymptomatic NET-A and infertility in this patient is intriguing. The impact of NET-A on fertility is not well defined. NET-A and NET tumors in other organs, such as the ovary, are found in women who achieve pregnancy spontaneously^[2–5,13]. However, the fact that women do conceive spontaneously while harboring a NET-A does not necessarily mean that these tumors do not significantly impact fecundity.

Appendiceal tumors that result in significant anatomical changes have been shown to negatively impact fertility potential due to impaired function of the fallopian tubes^[7–9]. However, an endocrinologic rationale exists for infertility in NET-A. NET-A are known to secrete significant amounts of serotonin that may manifest clinically as carcinoid syndrome^[1,12].

It has been postulated that NET–A negatively impacts human reproductive potential through the secretion of serotonin^[14]. Indeed, serotonin administered to pregnant mice has been shown to cause fetal termination in all stages of pregnancy^[15]. In humans, some studies have suggested that women without NET–A with habitual abortion may have higher than average levels of serotonin^[14,16]. The patient described in this report did not have any evidence of anatomic abnormality aside from her isolated appendiceal tumor.

Classically obtaining serotonin levels were an integral part of the workup for NET–A. Recently other markers, such as chromagranin A, have become the test of choice^[17]. Consequently a serotonin level was not followed in this case. The patient in this case did not have symptomatic carcinoid syndrome. However, such symptoms are present in just 10% of patients with NET–A while 76% have documented elevations in blood serotonin^[1,12,17]. Therefore the patient in this case likely did have significant elevations in her blood serotonin levels prior to surgery that could have negatively impacted her fecundity.

In conclusion, this case exemplifies the importance of careful inspection of radiologic films by the gynecologic physician. Perhaps more interestingly, however, this case presents an example in which an asymptomatic NET–A was associated with primary infertility. Mechanisms for how NET–A may be associated with infertility have been proposed in the past. To our knowledge this is the first case showing an association between an asymptomatic NET–A and primary infertility, an association which warrants further investigation.

Conflict of interest statement

We declare that we have no conflict of interest.

References

- [1] Connor SJ, Hanna GB, Frizelle FA. Appendiceal tumors: retrospective clinicopathologic analysis of appendiceal tumors from 7,970 appendectomies. *Dis Colon Rectum* 1998; **41**(1): 75–80.
- [2] Louzi A, Nargis Y, Belaabidia B, Alatawna H, Benelkhaiat R, Finech B, et al. Appendicular mucocele caused by carcinoid tumor during pregnancy. *Gynecol Obstet Fertil* 2006; **34**(11): 1051–1054.
- [3] Pitiakoudis M, Kirmanidis M, Tsaroucha A, Christianakis E, Filippou D, Sivridis E, et al. Carcinoid tumor of the appendix during pregnancy. A rare case and a review of the literature. *J BUON* 2008; **13**(2): 271–275.
- [4] Smaldone GM, Richard SD, Krivak TC, Kelley JL 3rd, Edwards RP. Pregnancy after tumor debulking and intraperitoneal cisplatin for appendiceal carcinoid tumor. *Obstet Gynecol* 2007; **110**(2 Pt 2): 477–479.
- [5] Korkontzelos I, Papanicolaou S, Tsimoyiannis I, Kitsiou E, Stefanos T, Tsanadis G, et al. Large carcinoid tumor of the appendix during pregnancy. *Eur J Obstet Gynecol Reprod Biol* 2005; **118**(2): 255–257.
- [6] Szczurowicz A, Wszelaki–Lass E, Debniak J, Wydra D. Carcinoid syndrome in a pregnant woman: Case report. *Ginekol Pol* 1995; **66**(1): 59–60.
- [7] Bocca SM, Perry R, Oehninger S. Pseudomyxoma peritonei: a rare differential diagnosis of hydrosalpinx. *Fertil Steril* 2005; **84**(4): 1017.
- [8] Hales HA, Peterson CM, Jolles CJ, Varner MW, Keye WR. Pseudomyxoma peritonei associated with secondary infertility. *Fertil Steril* 1992; **58**(2): 425–426.
- [9] Traub ML, Lee DS, Paty PB, Lieman H. Mucocele of the appendix causing tubal factor infertility. *Fertil Steril* 2009; **91**(5): 1957. e17–20.
- [10] Malave C, Wynn G, Nussbaum MS, Kaunitz AM. Incidental diagnosis of appendiceal mucocele with vaginal ultrasonography and computed tomography. *Obstet Gynecol* 2011; **117**(2 Pt 2): 479–481.
- [11] Pickhardt PJ, Levy AD, Rohrmann CA Jr, Kende AI. Primary neoplasms of the appendix: radiologic spectrum of disease with pathologic correlation. *Radiographics* 2003; **23**(3): 645–462.
- [12] Gökaslan H, Şişmanoğlu A, Kaya H, Durmuşoğlu F. Incidental carcinoid of appendix in cesarean section. *Eur J Obstet Gynecol Reprod Biol* 2002; **104**(1): 76–78.
- [13] Basham KL, Hajdu SI, Teichberg S, Menzin A. Adenocarcinoid tumor of the ovary diagnosed during pregnancy: A case report. *J Reprod Med* 2000; **45**(9): 758–761.
- [14] Durkin JW Jr. Carcinoid tumor and pregnancy. *Am J Obstet Gynecol* 1983; **145**(6): 757–761.
- [15] Robson JM, Sullivan FM. Mechanism of lethal action of 5–hydroxytryptamine on the foetus. *J Endocrinol* 1963; **25**: 553–554.
- [16] Sadowsky A, Pfeifer Y, Sadowsky E, Tsur C, Sulman FG. Serotonin metabolism in habitual abortion. *Obstet Gynecol* 1963; **22**: 778–780.
- [17] Modlin IM, Kidd M, Latich I, Zikusoka MN, Shapiro MD. Current status of gastrointestinal carcinoids. *Gastroenterology* 2005; **128**(6): 1717–1751.