




Contents lists available at ScienceDirect

Asian Pacific Journal of Tropical Disease

journal homepage: www.elsevier.com/locate/apjtd

Parasitological research

doi: 10.1016/S2222-1808(16)61098-8

©2016 by the Asian Pacific Journal of Tropical Disease. All rights reserved.

Incidence of *Dirofilaria immitis* in dogs presented at University of Nigeria, Nsukka Veterinary Teaching Hospital using wet smear and buffy coat techniquesChukwuebuka Iniobong Ikenna Ugochukwu^{1*}, Nebolisah Omekam², Emmanuel Ikenna Ugochukwu²¹Department of Veterinary Pathology and Microbiology, University of Nigeria, Nsukka, Nigeria²Department of Veterinary Medicine, University of Nigeria, Nsukka, Nigeria

ARTICLE INFO

Article history:

Received 22 Apr 2016

Received in revised form 9 May, 2nd revised form 5 Jul, 3rd revised form 6 Jul 2016

Accepted 12 Jul 2016

Available online 15 Jul 2016

Keywords:

Dirofilaria immitis

Heartworm infections

Incidence

Wet smear

Buffy coat

ABSTRACT

Objective: To determine the incidence of *Dirofilaria immitis* (*D. immitis*) in dogs using the wet mount and buffy coat techniques for rapid detection of microfilaria in blood samples collected from dogs, to compare the two techniques for quick detection, to find if there is age susceptibility in the incidence of dirofilariasis in dogs presented at the Veterinary Teaching Hospital, University of Nigeria, Nsukka and to find out if there are breed and sex variations in the incidence of dirofilariasis in dogs presented at Veterinary Teaching Hospital, University of Nigeria, Nsukka.

Methods: Blood samples were collected from the cephalic vein of 119 dogs. The blood samples were aseptically collected via cephalic venepuncture of each dog, collected into a tube containing ethylene diamine tetraacetic acid as anticoagulant, stored in an ice pack box at 5 °C and processed and examined for microfilaria using wet mount and buffy coat techniques.

Results: A total of 4 dogs were positive for *D. immitis* microfilaria giving a prevalence of 3.36%, more male (4.83%) than female (1.75%) dogs were affected in this study. Although there was no significant difference between both groups, the prevalence was the highest in cross breeds (6.66%), moderate in local breeds (3.63%) and absent in exotic breeds (0.00%). Although there was no significant ($P < 0.05$) difference amongst the 3 groups, only adult dogs were found positive for *D. immitis* microfilaria.

Conclusions: Based on the results of this present study, both the wet mount and buffy coat techniques can be used at the discretion of the clinician and in the absence of modified Knott's filter test, ELISA test and other diagnostic imaging techniques, in the rapid detection of microfilaria in blood samples from suspected cases of dirofilariasis.

1. Introduction

Heartworm disease is of considerable economic importance affecting canine populations around the globe[1]. Canine dirofilariasis also called heartworm disease, is a major veterinary health problem in tropical, sub-tropical and temperate regions of the globe[2]. Heartworm disease is a non-contagious parasitic disease, caused by a filarial nematode *Dirofilaria immitis* (*D. immitis*) which is one of the most pathogenic nematode parasites of dogs. Dogs are considered the definitive host for *D. immitis*, however, it may infect more than 30 animal species (*e.g.*, coyotes, foxes, wolves and other wild canids, domestic cats and wild felids, ferrets, *etc.*) and humans as well, it is a zoonosis transmitted by

mosquitos bite (*Aedes*, *Anopheles* and *Culex*)[3-6]. Adult worms dwell in the right ventricle and pulmonary artery, but occasionally could be found in the epidural space[7], brain[8], anterior chamber of the eye[9], lungs[4] or systemic arterial system[10]. Even as immature adults, the worms mate and the females release their offspring (microfilariae) into the blood stream[11,12]. The relatively large size (25–35 cm in length) of the female, together with the number of worms infestation after a long incubation period, the adult nematodes migrate to the cardiac cavities and blood vessel lumen causing various cardiovascular problems such as pulmonary embolism, pulmonary infarctions, cavity formation, spontaneous pneumothorax, emboli migration, chronic circulatory disorder and finally result in congestive heart failure which will ultimately cause death. Apart from dogs, several vertebrate animals, cats and humans can be infected[13-15]. Heartworm infections are a significant health risk to dogs as even light infections are capable of producing profound pulmonary vascular and parenchymal disease[16]. *D. immitis* has also been associated with human dirofilariasis, as a result of accidental infection[6,17]. Cases of human pulmonary dirofilariasis have been increasingly reported worldwide[6,18,19].

*Corresponding author: Chukwuebuka Iniobong Ikenna Ugochukwu, Department of Veterinary Pathology and Microbiology, University of Nigeria, Nsukka, Nigeria.

Tel: +2348037322220

E-mail: iniobongugochukwu@gmail.com

All experimental procedures involving animals were conducted in accordance to experimental protocol and approved by University of Nigeria, Nsukka Senate Committee on Medical and Research Ethics.

The journal implements double-blind peer review practiced by specially invited international editorial board members.

A case of human subcutaneous dirofilariasis has also been reported in Greece[20]. Extensive movement of dogs across countries and continents has contributed to the spreading of filariae to new areas with availability of vectors and favourable climatic conditions[21]. This work was designed to fill in the knowledge gap in Nsukka and South Eastern Nigeria where little or no work has been done in this regard and to detect microfilaria in the blood of dogs in the University of Nigeria, Nsukka and neighbouring communities, so as to determine the incidence, ascertain the best and reliable techniques for rapid detection of microfilaria in blood, comparing the buffy coat and wet mount techniques, age susceptibility in dogs presented at the Veterinary Teaching Hospital, University of Nigeria, Nsukka (VTH, UNN) and finally to compare the mean packed cell volume values of positive and negative cases of microfilaria.

2. Materials and methods

2.1. Study area

This study was conducted in Nsukka, a town in Nsukka local government area of Enugu State, Nigeria. Nsukka is situated at latitude 6°51'24" N and longitude 7°23'45" E. It has a total landmass of 45.38 km² and an elevation of 550 m above sea level.

2.2. Animals

A total of 119 male and female dogs, both local, cross and exotic breeds were randomly selected. The dogs were presented for treatment and routine check-up at the VTH, UNN. They were clinically examined. The age range was from 6 months to three years. Considering the life cycle of *D. immitis*, dogs less than 6 months of age were excluded from this study. Dogs aged 6–12 months were grouped as young while dogs more than a year were grouped as adults.

2.3. Blood samples

Animals were properly restrained and blood was aseptically collected via cephalic venepuncture of each dog. The blood samples were collected in a tube containing ethylene diamine tetraacetic acid as anticoagulant, stored in an ice pack box at 5 °C and processed within 24 h.

2.4. Detection of *D. immitis* infection

Blood samples were taken from the dogs, centrifuged in a micro centrifuge tube, then a buffy coat smear was examined for microfilaria as described by Levine and Wardlaw[22]. A drop of blood was placed in the centre of a clean microscope slide using an applicator stick and a wet smear technique was done according to standard procedures as described by Byeon *et al.*[23].

2.5. Autopsy

Autopsies were conducted on 2 of the confirmed and heavily infested dogs, after obtaining a dog-owner's approval. Infections were definitively confirmed, and the morphology and the number of worms were determined.

2.6. Statistical analysis

Differences in infection rates between dogs according to sex, breeds and age were analysed for statistical significance using the

Chi-square tests and significance was accepted at $P < 0.05$.

3. Results

3.1. General characteristics of dogs

Of the 119 privately owned dogs that were presented at the VTH, UNN, 62 were males and 57 were females. Four of the dogs were positive for the *D. immitis* microfilaria. This was shown in Figure 1.

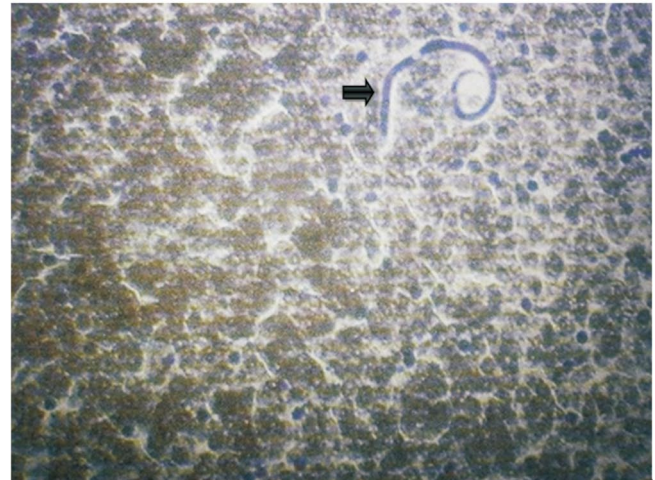


Figure 1. Giemsa stained sample of *D. immitis* (40×).

3.2. Clinical signs

Clinical signs observed were mainly those of exercise intolerance, coughing, pale mucous membrane, dyspnoea, anorexia and weight loss in all the dogs from which *D. immitis* infection was diagnosed.

3.3. Prevalence by age and sex of dogs

The prevalence of microfilaria was 1.75% in females and 4.83% in males. Table 1 shows the number of positive cases with respect to sex distribution. There was no significant association ($P > 0.05$) between the sex differences and the incidence of *D. immitis* microfilaria in dogs presented at the VTH, UNN. The prevalence of microfilariae was 12.50% in adult dogs aged 1 year 6 months–4 years but 0.00% for young dogs. Table 1 shows the number of positive cases with respect to age distribution. There was no significant association ($P > 0.05$) between the age differences and the incidence of *D. immitis* microfilaria in dogs presented at the VTH, UNN.

Table 1

The sex, age and breed distribution of positive *D. immitis* microfilaria dogs presented at the VTH, UNN.

Items	Number of examined	Microfilaria positive prevalence rate <i>n</i> (%)
Sex	Male	62 (4.83)
	Female	57 (1.75)
	Total	119 (3.36)
Age	Adults	50 (12.50)
	Young	69 (0.00) ^a
	Total	119 (3.36)
Breed	Local	55 (3.63)
	Cross	30 (6.66)
	Exotic	34 (0.00) ^a
	Total	119 (3.36)

^a: No detection of adult worms or microfilariae.

3.4. Prevalence according to breeds

The prevalence of microfilaria was 3.63% in local dog breeds (mongrel dogs), 6.66% in cross breeds and 0.00% in exotic breeds respectively. Table 1 shows the number of positive cases with respect to breed distribution. There was no significant association ($P > 0.05$) between the breed differences and the incidence of *D. immitis* microfilaria in dogs presented at the VTH, UNN.

3.5. Packed cell volume of the positive dogs

The mean packed cell volume of the *D. immitis* microfilaria positive dogs expressed with standard deviation was (38.67 ± 1.76) while that of the negative cases was (39.14 ± 0.53). The decrease in packed cell volume in the positive cases compared to the negative cases were not significantly different ($P > 0.05$).

3.6. Autopsy results

Post mortem examinations were conducted on 2 of the buffy coat and wet smear techniques positive dogs, and all of them were confirmed to be infected with the heartworms (Figure 2). A mean average of 2.6 male and 4.5 female adult worms were retrieved per dog.

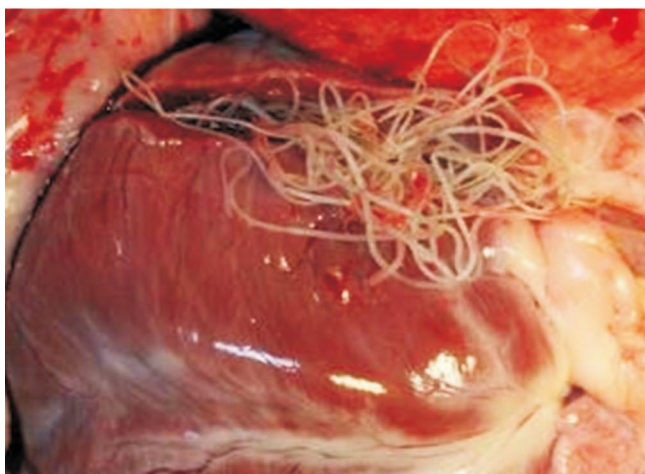


Figure 2. *D. immitis* (heartworm) arrowed observed at post-mortem.

4. Discussion

It is interesting to note that this is the first time *D. immitis* has been diagnosed and reported in the Nsukka area, South Eastern Nigeria.

The 4 positive cases recorded in this present out of 119 screened blood samples were all detected using both the wet mount and buffy coat techniques which could be easily done in the field where there are no ELISA, PCR or diagnostic imaging techniques especially in a developing country like Nigeria. The prevalence rate (3.36%) in this study was lower than the prevalence rates of 5.33%, 8.75%, 18.48%, and 15.7% in the works done by previous researchers[23-26]. But it was higher than the prevalence reported by Ng *et al.*[1] and Byeon *et al.*[23]. This low prevalence recorded in this present study was attributed to the time limiting factor and the time of year, that was in the dry season when the bulk of the work was carried out. The low prevalence rate in this case controlled study may also be attributed to the methods used, since buffy coat

and wet smear techniques may not be as sensitive as other methods of identification of *D. immitis*.

The prevalence of microfilaria was 3.63% in local dog breeds, 6.66% in cross breeds and 0.00% in exotic breeds respectively, this was attributed to the fact that the owners of the exotic breeds ensured the administration of heartworm chemoprophylaxis compared to the owners of the cross breeds and local breeds who knew little or nothing about heartworm chemoprophylactics. Due to the living conditions of the examined dogs, the rate of infection with adult worms and microfilaria in outdoor dogs was higher than that of indoor dogs. It is generally assumed that outdoor dogs are more frequently bitten by mosquitoes than indoor dogs, and this agreeing with previous work carried out by Byeon *et al.*[23]. There are some factors that contribute to a high rate of *D. immitis* infection, these include high annual temperatures, suitable mosquito reproduction environment, and frequent migration of mosquitoes from other areas[16,27]. Dogs are susceptible to various diseases, ailments, and poisons, some of which affect humans in the same way, others of which are unique to dogs. Dogs, like all mammals, are also susceptible to heat exhaustion when dealing with high levels of humidity and/or extreme temperatures[24]. The bulk of this work was carried out during the dry season, with only one of the 4 positive cases observed in the dry season, this agrees with the findings of Greeve *et al.*[28] who stated that dirofilariasis is usually associated with rainy season, largely due to preponderance of mosquitoes in the rainy season.

Clinical signs observed were mainly those of exercise intolerance, coughing, pale mucous membrane, dyspnoea, anorexia and weight loss, this agrees with the findings of previous researchers[29-31].

The findings of this study also suggested that there are no statistical significant ($P < 0.05$) association between the breeds examined, age and sex disposition with the prevalence of dirofilariasis in Nsukka area within the period this work was carried out. There was no significant difference ($P < 0.05$) between the mean packed cell volume of the positive and negative cases. This could have been due to few positive cases recorded as against the 115 negative cases analysed for packed cell volume.

In terms of the efficacy of the techniques used in detecting microfilaria in blood samples, this is not consistent with the findings of Jackson[32] who stated that the concentration method was far more efficient in detecting microfilariae than the wet mount especially in mild infection. Direct wet smear technique has also been used by previous researchers in the diagnosis of microfilaria[23,24,31] and the buffy coat technique has also been used by other researchers[24,33]. Both methods used in this study appear to be comparatively effective in the detection of *D. immitis* infection in dogs.

Apart from the rapid diagnostic techniques used in this work there are other techniques that could be used with great accuracy in the diagnosis of dirofilariasis include, the modified Knott's filter test which has been used in succession by previous researchers[24,31,34]. ELISA testing based on detection of *D. immitis* uterine antigen is available from most clinical diagnostic laboratories, and is specific and sensitive except in single sex infections[5,25,29,30]. Echocardiography may allow visualisation of the adult worms and is the diagnostic method of choice in caval syndrome[29,30].

In conclusion, based on the results of this present study, both the wet mount and buffy coat techniques can be used at the discretion of the clinician in the absence of modified Knott's filter test, ELISA test and other diagnostic imaging techniques, in the detection of

microfilaria in blood samples from suspected cases of dirofilariasis. Further work in the detection of *D. immitis* is suggested using more sensitive techniques like ELISA, modified Knott's test and alternative imaging techniques.

Conflict of interest statement

We declare that we have no conflict of interest.

Acknowledgments

The authors' special appreciation goes to Mr. Anyaoha of the Veterinary Clinical Pathology Laboratory of the Veterinary Teaching Hospital, University of Nigeria, Nsukka for his immense technical assistance.

References

- [1] Ng KL, Lee EL, Sani RA. Low prevalence of *Dirofilaria immitis* in dogs in Johor Bahru, Malaysia as a reflection of vector availability? *Trop Biomed* 2012; **29**(1): 187-90.
- [2] Simón F, Siles-Lucas M, Morchón R, González-Miguel J, Mellado I, Carretón E, et al. Human and animal dirofilariasis: the emergence of a zoonotic mosaic. *Clin Microbiol Rev* 2012; **25**: 507-44.
- [3] Anyanwu IN, Agbede RI, Ajanusi OJ, Umoh JU, Ibrahim ND. The incrimination of *Aedes (stegomyia) aegypti* as the vector of dirofilaria repens in Nigeria. *Vet Parasitol* 2000; **92**: 319-27.
- [4] McCall JW, Genchi C, Kramer LH, Guerrero J, Venco L. Heartworm disease in animals and humans. *Adv Parasitol* 2008; **66**: 193-285.
- [5] Maia C, Ramos C, Coimbra M, Cardoso L, Campino L. Prevalence of *Dirofilaria immitis* antigen and antibodies to *Leishmania infantum* in cats from southern Portugal. *Parasitol Int* 2015; **64**: 154-6.
- [6] Malik D, Amaraneni A, Singh S, Roach R. Man's best friend: How humans can develop *Dirofilaria immitis* infections. *IDCases* 2016; **4**: 43-5.
- [7] Blass CE, Holmes RA, Neer TM. Recurring tetraparesis attributable to a heartworm in the epidural space of a dog. *J Am Vet Med Assoc* 1989; **194**: 787-8.
- [8] Hamir AN. Heartworm (*Dirofilaria immitis*) in the brain of a dog. *Vet Rec* 1987; **120**: 207-8.
- [9] Brightman AH, Helper LC, Todd KS Jr. 1977. Heartworm in the anterior chamber of a dog's eye. *Vet Med Small Anim Clin* 1977; **72**: 1021-3.
- [10] Frank JR, Nutter FB, Kyles AE, Atkins CE, Sellon RK. Systemic arterial dirofilariasis in five dogs. *J Vet Int Med* 1997; **11**: 189-94.
- [11] Wong MM, Suter PF, Rhode EA, Guest MF. Dirofilariasis without circulating microfilariae: a problem in diagnosis. *J Am Vet Med Assoc* 1973; **163**: 133-9.
- [12] Svobodova V, Svobodova Z, Beladicova V, Valentova D. First cases of canine dirofilariosis in Slovakia: a case report. *Vet Med* 2005; **50**(11): 510-2.
- [13] Mupanomunda M, Williams JF, Mackenzie CD, Kaiser L. *Dirofilaria immitis*: heartworm infection alters pulmonary artery endothelial cell behavior. *J Appl Physiol (1985)* 1997; **82**: 389-98.
- [14] Jung J, Chang J, Oh S, Yoon J, Choi M. Computed tomography angiography for evaluation of pulmonary embolism in an experimental model and heartworm infested dogs. *Vet Radiol Ultrasound* 2010; **51**: 288-93.
- [15] Montoya-Alonso JA, Carretón E, Simón L, González-Miguel J, García-Guasch L, Morchón R, et al. Prevalence of *Dirofilaria immitis* in dogs from Barcelona: validation of a geospatial prediction model. *Vet Parasitol* 2015; **212**: 456-9.
- [16] Brown HE, Harrington LC, Kaufman PE, McKay T, Bowman DD, Nelson CT, et al. Key factors influencing canine heartworm, *Dirofilaria immitis*, in the United States. *Parasit Vectors* 2012; **5**: 245.
- [17] Bravo-Barriga D, Parreira R, Almeida AP, Calado M, Blanco-Ciudad J, Serrano-Aguilera FJ, et al. *Culex pipiens* as a potential vector for transmission of *Dirofilaria immitis* and other unclassified Filarioidea in Southwest Spain. *Vet Parasitol* 2016; **223**: 173-80.
- [18] Echeverri A, Long RF, Check W, Burnett CM. Pulmonary dirofilariosis. *Ann Thorac Surg* 1999; **67**: 201-2.
- [19] Foroulis CN, Khaldi L, Desimonas N, Kalafati G. Pulmonary dirofilariosis mimicking lung tumor with chest wall and mediastinal invasion. *J Thorac Cardiovasc Surg* 2005; **53**: 173-5.
- [20] Falidas E, Gourgiotis S, Ivopoulou O, Koutsogiannis I, Oikonomou C, Vlachos K, et al. Human subcutaneous dirofilariosis caused by *Dirofilaria immitis* in a Greek adult. *J Infect Public Health* 2016; **9**: 102-4.
- [21] Schrey C, Trautvetter G. Canine and feline heartworm disease-diagnosis and therapy. *Waltham Focus* 1998; **8**: 23-30.
- [22] Levine RA, Wardlaw SC. A new technique for examining blood. *Am Sci* 1988; **76**: 592-8.
- [23] Byeon KH, Kim BJ, Kim SM, Yu HS, Jeong HJ, Ock MS. A serological survey of *Dirofilaria immitis* infection in pet dogs of Busan, Korea, and effects of chemoprophylaxis. *Korean J Parasitol* 2007; **45**(1): 27-32.
- [24] Gadahi JA, Arijo AG, Abubakar M, Javaid SB, Arshed MJ. Prevalence of blood parasites in stray and pet dogs in Hyderabad area: comparative sensitivity of different diagnostic techniques for the detection of microfilaria. *Vet World* 2008; **1**(8): 229-32.
- [25] Meriem-Hind BM, Madani M. Prevalence of canine *Dirofilaria immitis* infection in the city of Algiers, Algeria. *Afr J Agric Res* 2009; **4**(10): 1097-100.
- [26] Montoya-Alonso JA, Carretón E, Morchón R, Silveira-Viera L, Falcón Y, Simón F. The impact of the climate on the epidemiology of *Dirofilaria immitis* in the pet population of the Canary Islands. *Vet Parasitol* 2016; **216**: 66-71.
- [27] Ahid SM, Lourenco-de-Oliveira R, Saraiva LQ. [Canine heartworm on Sao Luis Island, Northeastern Brazil: a potential zoonosis]. *Cad Saude Publica* 1999; **15**: 405-12. Portuguese.
- [28] Greeve RB, Lok JB, Glickman LT. Epidemiology of canine heartworm infection. *Epidemiol Rev* 1983; **5**: 220-46.
- [29] Meyer HP, Wolvekamp P, van Maanen C, Stokhof AA. Seven cases of heartworm disease (dirofilariosis) in dogs in the Netherlands. *Vet Q* 1994; **16**(3): 169-74.
- [30] Goodfellow M, Shaw S. Exotic diseases of dogs and cats at risk of importation to Ireland. *Ir Vet J* 2005; **58**: 271-7.
- [31] Ilie MS, Dărăbus GH, Ciocan R, Hotea I, Imre K, Morariu S, et al. Dirofilariosis in dog case report. *Lucrări Stiințifice Med Vet* 2009; **42**(1): 59-63.
- [32] Jackson RF. Studies on the filter techniques for the detection and identification of canine microfilariae. Proceedings of the heartworm symposium 77. Bonner Springs: Veterinary Medicine Publishing Company; 1978, p. 38-44.
- [33] Boonyapakorn C, Srikijjakarn L, Morakote N, Hoerchner F. The epidemiology of *Dirofilaria immitis* infection in outpatient dogs at Chiang Mai University Small Animal Hospital, Thailand. *Southeast Asian J Trop Med Public Health* 2008; **39**(1): 33-8.
- [34] Roth L, Brown L, Brum S, Foster L, Nelson M, Reczeck D, von Schantz D. Comparison of three diagnostic tests for *Dirofilaria immitis* in a low-incidence area. *J Vet Diagn Invest* 1993; **5**: 647-8.