



Contents lists available at ScienceDirect

Asian Pacific Journal of Tropical Disease

journal homepage: www.elsevier.com/locate/apjtd

Document heading doi:10.1016/S2222-1808(11)60076-5

Pulmonary scedosporiosis—A rare entity

Sushant H Meshram, Gyanshankar P Mishra*

Department of Respiratory Medicine, TB Ward premises, Government Medical College, Nagpur, Maharashtra Pin: 440003

ARTICLE INFO

Article history:

Received 4 September 2011

Received in revised form 29 September 2011

Accepted 25 October 2011

Available online 28 December 2011

Keywords:

Pulmonary scedosporiosis
Allescheria boydii
Monosporium apiosporium
 Cow dung exposure

ABSTRACT

Pulmonary scedosporiosis is a rare opportunistic fungal infection of the lungs in humans and mostly it occurs in previously diseased lungs or in immunocompromised patients. We report here a case of 30-year-old female who presented with complaints of cough with expectoration, breathlessness, chest pain and fever since one year ago and was subsequently diagnosed to be suffering from pulmonary scedosporiosis whose causative organism was *Allescheria boydii*. The patient responded to medical line of management. This is the first case of pulmonary scedosporiosis being reported in an immunocompetent host in association with a long term history of occupational exposure to cow dung.

1. Introduction

Pulmonary scedosporiosis is a rare opportunistic fungal infection of the lungs in humans and mostly it occurs in previously diseased lungs or in immunocompromised patients^[1,2]. However, it must be detected because of its frequent resistance to medical treatment^[3]. We report here a case of pulmonary scedosporiosis [causative organism: *Allescheria boydii* (*A. boydii*)] which responded to medical line of management. This is the first case of pulmonary scedosporiosis being reported in an immunocompetent host in association with a long term history of occupational exposure to cow dung.

2. Case report

A 30-year-old female presented in OPD with complaints of cough with expectoration, breathlessness, right sided chest pain and fever since one year ago. The expectoration was two to three teaspoonfuls per day, white to yellow coloured and non foul smelling. There was neither associated hemoptysis nor any diurnal or postural variation. The breathlessness was gradually progressive and exertional.

The right sided chest pain was localized to mammary area and it increased on respiration and coughing. The patient had low grade intermittent fever on and off. There was no any other significant complaint contributing to the history. The patient was not a known diabetic, hypertensive or asthmatic. The patient had received a four month course of anti-tuberculosis treatment from private practitioner without any clinico-radiological improvement in the preceding one year. She had also received a prolonged course (six weeks) of broad spectrum antibiotics but with no clinico-radiological response.

The patient used to do the work cow dung layering daily in rural households since fifteen years ago. She did not use any preventive measures during work (e.g. use of masks, covering nose / mouth during work). Patient apparently felt better on non working days. The patient also had a history of exposure to biomass fuel (Chulha smoke) for ten years.

On general examination she had a resting pulse of 80/minute and a blood pressure of 118/76 mm Hg. The rest of the findings on general examination were unremarkable except for presence of pallor. The examination of her respiratory system revealed a few mid and late inspiratory crepitations in her right mammary and interscapular area on auscultation.

Her hemoglobin was 9.2 gm%; total leucocyte count was 8400/cmm with differential leucocyte count of granulocytes (62.7%), lymphocytes (28.1%), monocytes (9.2%); RBC count was $5.44 \times 10^6 / \mu\text{L}$; and platelet count was 295 000/mL. Her random blood sugar was 98 mg/dL. Her renal function and

*Corresponding author: Dr. Gyanshankar P Mishra, Department of Respiratory Medicine, TB Ward premises, Government Medical College, Nagpur, Maharashtra Pin: 440003.

Tel: 91-9850349074, 0712-2750368

E-mail: gyanshankarmishra@rediffmail.com

liver function tests were normal. Her HIV test was negative. Six samples for sputum AFB smear (including 2 induced samples) were negative. Sputum gram stain and culture were negative. Her Mantoux test showed 8 mm induration at 48 hours. Her ultrasonography of abdomen was within normal limit. Her chest radiograph (Figure 1) showed nodular shadows predominantly in the right mid zone and lower zone along with homogenous radio opacity in the right lower zone and upper zone suggestive of consolidation. HRCT thorax (Figure 2) was done which revealed: 1) multiple enhancing parenchymal as well as pleural wall nodular densities with irregular margins and central cavitation involving both lung fields; 2) tiny centrilobular nodular opacities involving both lung fields with some of them giving tree in bud appearance; 3) consolidatory changes noted involving apical and posterior segment of right upper lobe, medial segment of right middle lobe with mediastinal lymphadenopathy. Thus the imaging features favoured the possibility of an infective etiology.

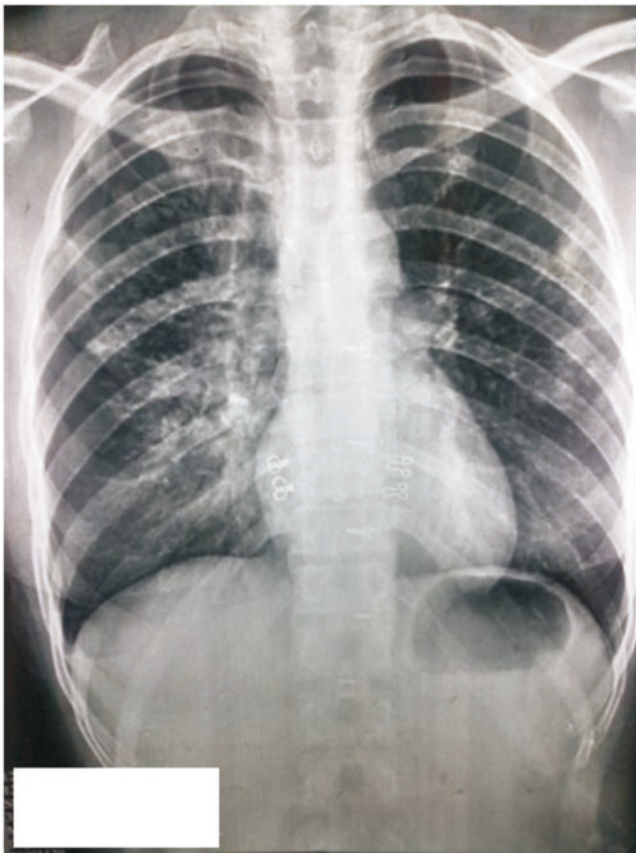


Figure 1. Chest radiograph posterior view at presentation (baseline).

Her further investigations were as follows: serum ANA: 0.48–negative; serum RA factor–negative; serum ACE levels: 52 U/L (8–65); serum calcium: 9 mg/dL; serum IgE levels: 98 KIU/mL (normal up to 190 KIU/mL) and PFT: normal. Finally a fiberoptic bronchoscopy was done and there was no obvious gross abnormality on bronchoscopy. Bronchoalveolar lavage samples for AFB stain and culture were negative and gram stain and culture were also negative. The bronchoalveolar lavage samples for fungus showed no fungal elements at KOH mount; however, the fungal culture showed growth of

Monosporium apiosporium (*A. boydii*) on Sabouraud's agar.

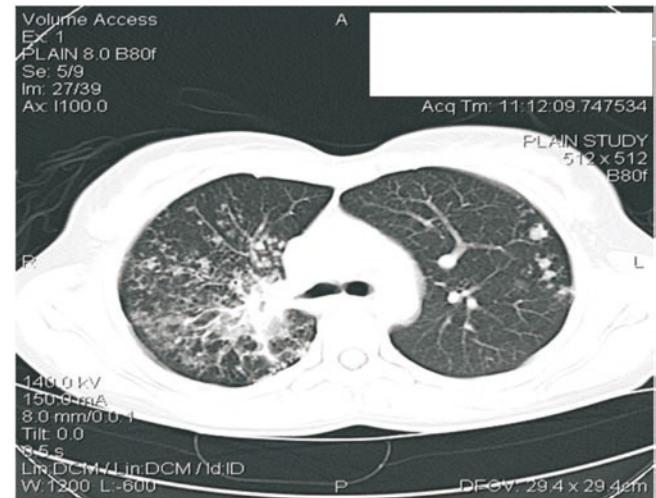


Figure 2. HRCT thorax at presentation (baseline).

A diagnosis of fungal lung disease (*A. boydii*) was made and the patient was initiated on oral itraconazole 200 mg bid for 6 months with close clinico–radiological monitoring. She was also given advice of cessation of exposure to cow dung, change of work and use of preventive measures. Unfortunately, the patient had not yet changed her work profile. There was significant clinico–radiological improvement at four months of therapy. She has gained weight, and improved appetite with improvement of symptoms along with decrement in radiological shadows (Figure 3).

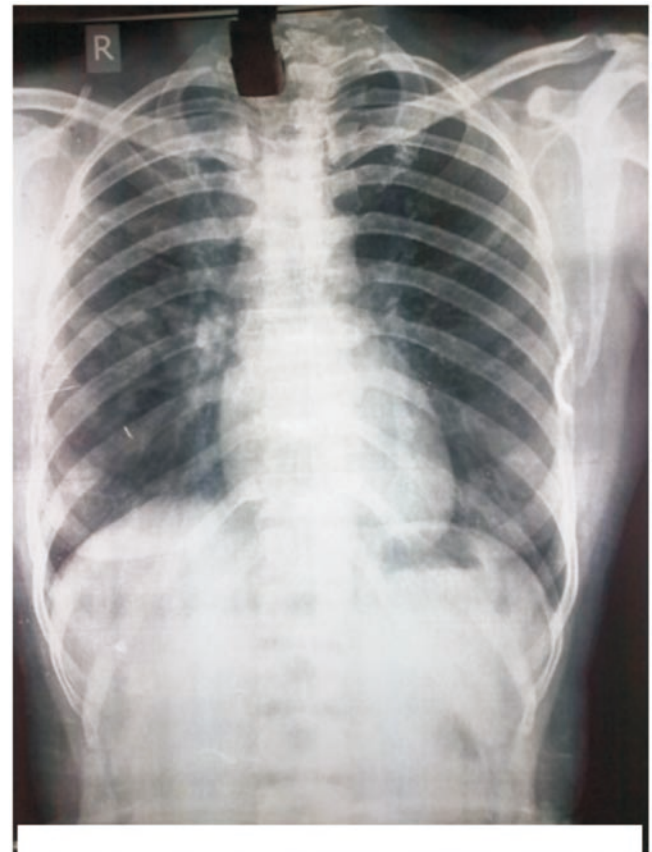

Figure 3. Chest radiograph posterior view after 4 months of itraconazole therapy (significant radiological resolution).

3. Discussion

The points in favour of diagnosis of fungal lung disease in our patient were: 1) history of exposure to cow dung since fifteen years ago with no preventive measures; 2) radiological picture consistent with diagnosis of an infective etiology; 3) patient had received a trial of anti-tubercular treatment and broad spectrum antibiotics but with no clinico-radiological response; 4) bacteriological confirmation of the diagnosis on bronchoalveolar lavage fungal culture; and 5) clinical and radiological response while on antifungal therapy.

The fungus *A. boydii* belongs to the genus *Scedosporium*-class Ascomycetae. In contrast to most pathogenic fungi, it exists in tissue in its teleomorphic (sexual) form. *Scedosporium apiospermum* is the asexual phase and *Pseudallescheria boydii* (*P. boydii*) is the sexual phase. *P. boydii* was previously known as *A. boydii* (*Monosporium apiosporium*) and *Petriellidium boydii*. These fungi are ubiquitous saprophytic moulds found in the soil and decaying vegetation. The mould grows rapidly on isolation medium (Sabouraud's agar), producing a fluffy colony, which develops a brownish gray to dark gray ('mousy') color after incubation for several days[1].

Although it affects mostly immunocompromised patients, pulmonary and disseminated scedosporiosis have also been reported in immunocompetent subjects[2].

The *Scedosporium* genus consists of filamentous fungi that inhabit soil, sewage, manure, and polluted waters. Scedosporiosis is caused by inhalation or traumatic subcutaneous implantation of the organism, and may have varied clinical presentations. A variety of pulmonary manifestations can occur[3].

Scedosporium spp. can also cause a wide spectrum of conditions, including mycetoma, saprobic involvement and colonization of the airways, sinopulmonary infections, extrapulmonary localized infections, and disseminated infections. The most common sites of invasive infection are the lungs, sinuses, bones, joints, eyes, and brain[4].

Respiratory tract illnesses attributed to *P. boydii* have included pneumonitis caused by inhalation of contaminated material and fungus balls in lung cavities and paranasal sinuses. These also present as non resolving/slowly resolving consolidation. *P. boydii* is often resistant to amphotericin B and its therapeutic use in these infections has been associated with poor clinical response and recurrence following seemingly effective therapy[5].

These fungal pathogens are distinctively difficult to treat given their inherent resistance to available antifungal agents. Most *in vitro* studies showed significant antifungal activity for all azoles except fluconazole and ketoconazole[4]. Voriconazole has been recently reported to be effective in treating pulmonary scedosporiosis[6].

The optimal duration of antifungal therapy has not been established and must be individualized. In

immunocompetent hosts, antifungal treatment may be discontinued after 3 to 6 months[5]. However, in localized infections, surgical resection is generally mandatory to cure, because of the frequent resistance of the fungi to medical therapy[7].

Thus, isolation, proper identification, and susceptibility testing of the fungal isolates are important steps in the optimal treatment of these infections.

To our knowledge this is the first case of pulmonary scedosporiosis to be reported in an immunocompetent host in association with long term history of occupational exposure to cow dung. The occupational exposure to cow dung is still prevalent among the rural population and hence this association could be of significant importance in such a scenario. It also needs to be emphasized that microbiological confirmation in today's era of evidence based medicine needs to be followed before treating things empirically as far as possible.

Conflict of interest statement

We declare that we have no conflict of interest.

References

- [1] Iwen PC. Aspergillosis, fusariosis, and other mycoses caused by hyaline fungi. *McPherson & Pincus: Henry's clinical diagnosis and management by laboratory methods*. In: McPherson RA, Pincus MR. (eds.) 21st ed. Portland: W.B. Saunders Company; 2006.
- [2] Caggiano G, Cantisani P, Rolli M, Gianfreda CD, Pizzolante M, Montagna MT. The importance of a proper aetiological diagnosis in the management of patients with invasive mycoses: a case report of a brain abscess by *Scedosporium apiospermum*. *Mycopathologia* 2011; **172**(4): 317–322.
- [3] Mazumder SA, Cleveland KO, Norwood J. *Scedosporium apiospermum* infection presenting as a pneumothorax and cavitary lung lesions in a patient with acquired immune deficiency syndrome. *South Med J* 2010; **103**(9): 960–962.
- [4] Cortez KJ, Roilides E, Quiroz-Telles F, Meletiadis J, Antachopoulos C, Knudsen T, et al. Infections caused by *Scedosporium* spp. *Clin Microbiol Rev* 2008; **21**(1): 157–197.
- [5] Kleiman MB, Cox E. Agents of eumycotic mycetoma: *Pseudallescheria boydii* (anamorph *Scedosporium apiospermum*). *Long: principles and practice of pediatric infectious diseases*. In: Long SS, Pickering LK, Prober CG. 3rd ed. New York: Churchill Livingstone; 2009.
- [6] Ogata R, Hagiwara E, Shiihara J, Ogura T, Takahashi H, Kamei K. A case of lung scedosporiosis successfully treated with monitoring of plasma voriconazole concentration level. *Nihon Kokyuki Gakkai Zasshi* 2011; **49**(5): 388–392.
- [7] Jung JY, Salas R, Almond CH, Saab S, Reyna R. The role of surgery in the management of pulmonary monosporosis: a collective review. *J Thorac Cardiovasc Surg* 1977; **73**: 139–144.