



Contents lists available at ScienceDirect

Asian Pacific Journal of Tropical Disease

journal homepage: [www.elsevier.com/locate/apjtd](http://www.elsevier.com/locate/apjtd)

Document heading doi:10.1016/S2222-1808(12)60028-0

# Hypoglycemic effect of *Costus pictus* D. Don on alloxan induced type 2 diabetes mellitus in albino rats

S Suganya, R Narmadha, VK Gopalakrishnan, K Devaki\*

Department of Biochemistry, Karpagam University, Coimbatore-641 021, India

## ARTICLE INFO

## Article history:

Received 15 October 2011

Received in revised form 27 December 2011

Accepted 28 February 2012

Available online 28 April 2012

## Keywords:

*Costus pictus*

Antidiabetic

Antioxidant

Hypoglycemia

Alloxan mono hydrate

Oxidative stress

## ABSTRACT

**Objective:** To demonstrate the effect of aqueous extract of *Costus pictus* (*C. pictus*) leaves on blood glucose, lipid profile and liver antioxidant enzymes and lipid peroxidation in alloxan induced diabetic rats. **Methods:** Aqueous extract of *C. pictus* (AECF) leaves was administered orally for 30 days and its effect on blood glucose, lipid profile, hepatic marker enzymes such as serum glutamate oxaloacetate transaminase (SGOT), serum glutamate pyruvate transaminase (SGPT), serum urea, creatinine, protein and albumin content and liver antioxidant enzymes such as catalase, peroxidase, superoxide dismutase and lipid peroxidation in alloxan induced diabetic rats were examined. **Results:** Oral administration of aqueous extract of *C. pictus* leaves to diabetic rats for 30 days significantly reduced the levels of blood glucose, lipid profile, lipid peroxidation, liver marker enzymes, urea, creatinine and increased the levels of antioxidant enzymes. **Conclusions:** The aqueous extract of *C. pictus* leaves controls the blood glucose level, improves lipid metabolism and prevents diabetic complications associated with lipid peroxidation and also maintains the antioxidant enzymes in experimental diabetic rats. Therefore, it can be recommended for the prevention of diabetes mellitus.

## 1. Introduction

Diabetes mellitus, an endocrine disorder is associated with depleted insulin secretions with altered carbohydrate, lipid and protein metabolism. Complications such as renal failure, coronary artery disorder, cerebro-vascular disease, neurological complications, blindness, limb amputation, long term damage, dysfunctions, failure of various organs and eventually premature death are associated with chronic hyperglycemia[1]. It has been estimated that Indian people are more genetically susceptible to diabetes accounting about 30 to 33 millions and would go up to 40 millions by the end of 2010 which further will reach to maximum of 74 millions by 2025. It has been suggested that diabetes is the third leading cause of death due to high incidence of morbidity and mortality after cancer and cardiovascular disorders. For centuries, plants have been used to treat human diseases. Herbal drugs have lesser or no side effects and are less expensive as compared to synthetic drugs.

After the recommendations made by WHO on diabetes mellitus, investigations on hypoglycemic agents from medicinal plants has become more important. Therefore, the search for more effective and safer hypoglycemic agents has continued to be an important area of active research[2]. The

plants and herbs are being used as decoctions or in other extracted forms for their blood sugar lowering properties. Many useful herbs introduced in pharmacological and clinical trials have confirmed their blood sugar lowering effect. Herbal medicines are used world wide even without documentation of their curative effect and there is only little knowledge available about their mode of action. So it is essential to know about the pharmacological evaluation of various plants used in the traditional system of medicine[3].

One such plant is *Costus pictus* D. Don (*C. pictus*) commonly known as 'spiral ginger'. It is a member of Zingiberaceae family of which diverse biological properties like antidiabetic, anti-inflammatory, antitumour, antihepatotoxic and antidepressant have been reported from the rhizomes[4,5]. In this study an attempt was made in *C. pictus* leaves in view of its alleged hypoglycemic effect on alloxan induced diabetic in rats.

## 2. Materials and methods

### 2.1. Collection of the plant

The leaves of *C. pictus* were procured from a field at Pollachi, Tamil Nadu, India. The plant was authenticated by Dr. R Gopalan (Rtd, Botanical Survey of India, Coimbatore), Department of Biotechnology, Karpagam University, Coimbatore, India.

\*Corresponding author: Dr. K Devaki, Department of Biochemistry Karpagam University, Pollachi Main Road Eachanari (PO), Coimbatore, Tamilnadu, India-641021.

Tel: +91 0422 2611146

Fax: +91 0422 26111043

E-mail: [devakirajasekar@gmail.com](mailto:devakirajasekar@gmail.com)

## 2.2. Preparation of plant extract

*C. pictus* leaves were washed well with water, air dried at 25 °C for 5 days in the absence of sunlight and powdered. Twenty five grams of powdered plant material was extracted in 500 mL of boiling water for 2 h and concentrated to half of the volume by boiling in a water bath. The resulting dark-green extract was cooled and filtered using Whatmann No. 1 filter paper. It was stored in tightly capped brown bottle and kept in refrigerator and used for the study.

## 2.3. Experimental animals

Adult female Wistar albino rats weighing about 160 g –180 g were obtained from Animal House, Karpagam University, Coimbatore and used for the study. Rats were housed properly and fed on pellets with free access to tap water. Room temperature was controlled at 22 °C with a 12-hour light, 12-hour dark cycle. For experimental purpose, the animals were kept fasting overnight but were allowed free access to water. All the experiments were carried out according to the guidelines recommended by the Committee for the Purpose of Control and Supervision of Experiments on Animals (CPCSEA), Government of India.

## 2.4. Induction of diabetes

Alloxan monohydrate (Sigma, Co, St-Louis, USA) was dissolved in sterile normal saline immediately before use and injected intraperitoneally at a dose of 150 mg/kg bw. After 2 weeks, rats with moderate diabetes having glycosuria indicated by Benedict's qualitative test were selected for the experiment.

## 2.5. Experimental design

In the experiment, a total of 30 (18 diabetic surviving rats, 12 normal rats) were used. The rats were divided into five groups of six animals each. Group 1 served as control rats; Group 2 were diabetic rats; Group 3 were diabetic rats given AECP (200 mg/kg bw) in 1 mL of aqueous solution using an intragastric tube for 30 days; Group 4 were diabetic rats given glibenclamide (500 µg/kg bw) in 1 mL of aqueous solution using an intragastric tube for 30 days; Group 5 are control rats given AECP (200 mg/kg bw) in 1 mL of aqueous solution using an intragastric tube for 30 days.

The animals were weighed and treated with prepared drugs through oral intragastric tube everyday under controlled room temperature and photoperiod. Standard food in form of pellets, and water were provided *ad libitum*. The duration of the treatment was 30 days. After then the animals were sacrificed under light chloroform anesthesia.

## 2.6. Blood collection and histopathological study

Blood was drawn from the ventricles and centrifuged. The serum was immediately used for various biochemical estimations. Liver and pancreas were excised immediately, washed with ice cold saline and stored in 10% formalin and used for histopathological studies and liver in 0.9% saline was used for biochemical studies.

## 2.7. Biochemical assays

Blood glucose level was estimated colorimetrically using

commercial diagnostic kits (Sigma Diagnostics Pvt Ltd, Baroda, India). Protein levels was estimated by the method of Lowry *et al*[6]. Serum lipid profile, serum glutamate oxaloacetate transaminase (SGOT), serum glutamate pyruvate transaminase (SGPT), serum urea, creatinine, protein and albumin content were determined by standard procedures in an auto analyzer using Ecoline kits (E. Merck, Mumbai, India). Liver glycogen was estimated[7]. Superoxide dismutases (SOD), catalase (CAT), peroxidase (Px) and lipid peroxidations (LPO) were also estimated[8–11].

## 2.8. Statistical analysis

The data were expressed as the Mean ± SD. The results obtained were then analysed using Student's *t*-test. Values were considered statistically significant at  $P < 0.05$ ,  $P < 0.01$  level.

# 3. Results

## 3.1. Changes in body weight

Changes in body weight of control and experimental groups are shown in Table 1. The body weight of rats increased significantly in group I, group III, IV and V rats. But in diabetic group II rats the weight reduced significantly.

**Table 1**

Changes in body weight (g) of control and experimental animals.

	Initial weight	Final weight
Control	180.40 ± 1.26	196.70 ± 2.00**
Diabetic control	175.20 ± 3.60	163.50 ± 1.41*
Diabetic + plant extract	179.20 ± 4.73	194.40 ± 1.41**
Plant extract alone	197.70 ± 2.81	200.40 ± 1.48**

\*  $P < 0.01$ , \*\* $P < 0.05$  compared with initial weight in respective group.

## 3.2. Changes in level of glucose, triglycerides and cholesterol

Table 2 shows the concentration of glucose, cholesterol and triglycerides in serum of each groups. Glucose, cholesterol and triglycerides were found to be significantly increased in diabetic rats (Group II) when compared with normal rats (Group I). Group III and IV rats administered with *C. pictus* extract and glibenclamide respectively showed a significant decrease ( $P < 0.01$ ) in the level of glucose. Glucose, cholesterol and triglycerides levels in *C. pictus* extract alone treated rats (Group V) showed no significant change when compared with control rats (Group I).

## 3.3. Changes in level of total protein, albumin and globulin

Table 3 shows the concentration of total protein, albumin, globulin and A/G ratio in serum of control and experimental groups. The level of total protein and albumin and A/G ratio showed a significant decrease in alloxan treated diabetic rats, but globulin showed no significant change. A significant increase in the level of all the protein parameters were observed in *C. pictus* extract treated rats (Group III), when compared with alloxan treated Group II rats. The level of protein profile was not significantly changed when the plant extract alone treated rats (Group V) were compared with Group I rats.

## 3.4. Changes in the non-protein nitrogen compounds and transaminases

**Table 2**The concentration of glucose, cholesterol, triglycerides in serum of control and experimental rats. (mg/dL) (Mean  $\pm$  SD, n=6)

Group	Glucose	Cholesterol	Triglycerides
Control (Group I)	88.70 $\pm$ 3.38	119.10 $\pm$ 2.60	74.20 $\pm$ 2.28
Diabetic control (Group II)	250.10 $\pm$ 8.02 <sup>a</sup>	260.20 $\pm$ 2.01 <sup>a</sup>	210.80 $\pm$ 2.02 <sup>a</sup>
Diabetic+plant extract treated (Group III)	102.30 $\pm$ 2.82 <sup>b</sup>	103.70 $\pm$ 2.82 <sup>b</sup>	71.90 $\pm$ 4.24 <sup>b</sup>
Diabetic + glibenclamide treated (Group IV)	100.20 $\pm$ 1.78 <sup>b</sup>	102.20 $\pm$ 2.40 <sup>b</sup>	70.10 $\pm$ 3.68 <sup>b</sup>
Plant extract treated (Group V)	87.70 $\pm$ 1.95	110.10 $\pm$ 2.00	72.70 $\pm$ 3.28

a.  $P < 0.01$  when compared with Group I; b.  $P < 0.01$  when compared with Group II.**Table 3**The concentration of total proteins, albumin and globulin in serum of control and experimental rats. (Mean  $\pm$  SD, n=6)

Group	Total Protein (g/dL)	Albumin (g/dL)	Globulin (g/dL)	A/G Ratio
Control (Group I)	7.160 $\pm$ 0.006	3.150 $\pm$ 1.002	4.010 $\pm$ 0.420	0.780 $\pm$ 0.031
Diabetic control (Group II)	5.890 $\pm$ 0.038 <sup>a</sup>	2.360 $\pm$ 0.960 <sup>a</sup>	3.530 $\pm$ 1.030 <sup>a</sup>	0.660 $\pm$ 0.006 <sup>a</sup>
Diabetic+plant extract treated (Group III)	7.010 $\pm$ 0.316 <sup>b</sup>	3.150 $\pm$ 0.600 <sup>b</sup>	3.860 $\pm$ 0.500 <sup>b</sup>	0.820 $\pm$ 0.159 <sup>b</sup>
Diabetic + Glibenclamide treated (Group IV)	7.020 $\pm$ 0.981 <sup>b</sup>	3.110 $\pm$ 0.780 <sup>b</sup>	3.890 $\pm$ 0.630 <sup>b</sup>	0.810 $\pm$ 0.153 <sup>b</sup>
Plant extract treated (Group V)	7.140 $\pm$ 0.194	3.100 $\pm$ 0.940	3.900 $\pm$ 1.080	0.821 $\pm$ 1.020

a.  $P < 0.01$  when compared with Group I; b.  $P < 0.01$  when compared with Group II.**Table 4**The concentration of urea, creatinine, SGOT and SGPT in serum of control and experimental groups. (Mean  $\pm$  SD, n=6)

Group	Urea (g/dL)	Creatinine (g/dL)	SGOT (U/L)	SGPT (U/L)
Control (Group I)	40.40 $\pm$ 3.40	0.81 $\pm$ 0.03	40.01 $\pm$ 1.89	35.08 $\pm$ 2.96
Diabetic control (Group II)	55.50 $\pm$ 2.64 <sup>a</sup>	1.14 $\pm$ 0.08 <sup>a</sup>	63.61 $\pm$ 2.00 <sup>a</sup>	53.25 $\pm$ 2.51 <sup>a</sup>
Diabetic+plant extract treated (Group III)	42.30 $\pm$ 1.65 <sup>b</sup>	1.09 $\pm$ 0.08 <sup>b</sup>	41.83 $\pm$ 2.02 <sup>b</sup>	33.51 $\pm$ 2.10 <sup>b</sup>
Diabetic + Glibenclamide treated (Group IV)	41.20 $\pm$ 0.65 <sup>b</sup>	0.99 $\pm$ 0.05 <sup>b</sup>	40.81 $\pm$ 1.02 <sup>b</sup>	32.53 $\pm$ 1.90 <sup>b</sup>
Plant extract treated (Group V)	41.70 $\pm$ 3.75	0.80 $\pm$ 0.03	39.23 $\pm$ 2.01	34.31 $\pm$ 1.73

a.  $P < 0.01$  when compared with Group I; b.  $P < 0.01$  when compared with Group II.**Table 5**Lipid peroxidation and antioxidant enzymes in liver of control and experimental groups. (Mean  $\pm$  SD, n=6)

Group	Inhibition of lipid peroxidation (nmoles of malondialdehyde formed / g tissue)	Peroxidase (change in absorbance / min / g fresh weight)	Superoxide dismutase (Units / g liver tissue)	Catalase ( $\mu$ moles of H <sub>2</sub> O <sub>2</sub> utilized / min / mg / protein)
Control (Group I)	30.15 $\pm$ 1.40	5.17 $\pm$ 1.20	20.31 $\pm$ 1.80	75.21 $\pm$ 1.70
Diabetic control (Group II)	62.21 $\pm$ 3.16 <sup>a</sup>	3.55 $\pm$ 0.64 <sup>a</sup>	9.52 $\pm$ 1.89 <sup>a</sup>	50.27 $\pm$ 1.41 <sup>a</sup>
Diabetic+plant extract treated (Group III)	28.27 $\pm$ 2.09 <sup>b</sup>	4.05 $\pm$ 1.02 <sup>b</sup>	18.35 $\pm$ 1.67 <sup>b</sup>	72.22 $\pm$ 0.09 <sup>b</sup>
Diabetic + Glibenclamide treated (Group IV)	26.31 $\pm$ 1.05 <sup>b</sup>	4.95 $\pm$ 2.00 <sup>b</sup>	19.52 $\pm$ 1.99 <sup>b</sup>	74.15 $\pm$ 0.20 <sup>b</sup>
Plant extract treated (Group V)	29.56 $\pm$ 1.86	5.15 $\pm$ 1.50	19.61 $\pm$ 1.17	74.85 $\pm$ 1.49

a.  $P < 0.01$  when compared with Group I; b.  $P < 0.01$  when compared with Group II.**Table 6**The concentration of glycogen, protein in liver of control and experimental groups. (Mean  $\pm$  SD, n=6)

Group	Glycogen (mg/g of fresh tissue)	Protein (mg/g of fresh tissue)
Control (Group I)	0.035 $\pm$ 0.002	1.770 $\pm$ 0.090
Diabetic control (Group II)	0.010 $\pm$ 0.140 <sup>a</sup>	0.970 $\pm$ 0.090 <sup>a</sup>
Diabetic+plant extract treated (Group III)	0.040 $\pm$ 0.080 <sup>b</sup>	1.200 $\pm$ 0.159 <sup>b</sup>
Diabetic + Glibenclamide treated (Group IV)	0.030 $\pm$ 0.060 <sup>b</sup>	1.250 $\pm$ 0.550 <sup>b</sup>
Plant extract treated (Group V)	0.030 $\pm$ 0.002	1.800 $\pm$ 0.240

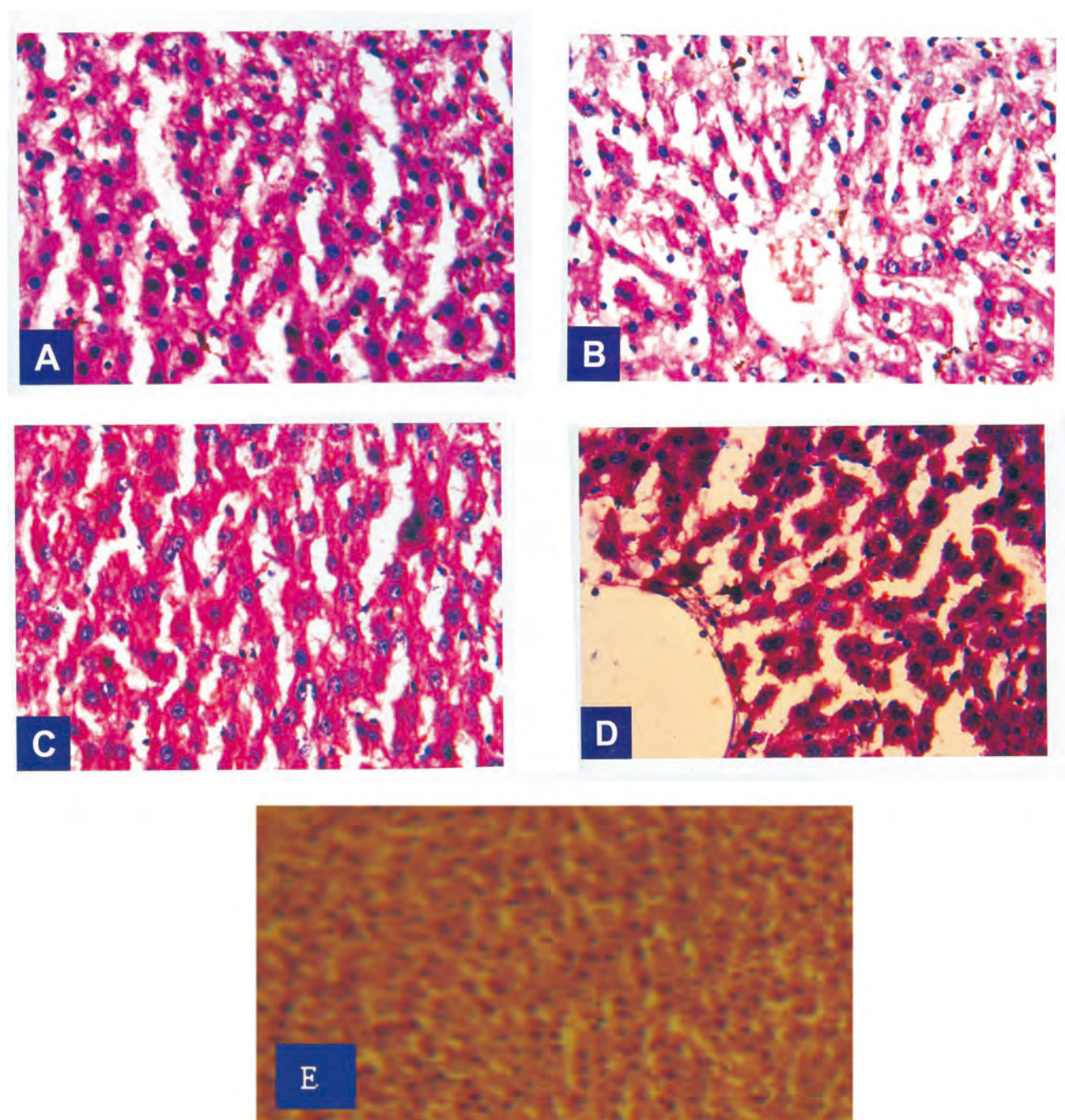
a.  $P < 0.01$  when compared with Group I; b.  $P < 0.01$  when compared with Group II.

Table 4 shows the concentration of non-protein nitrogen compounds like urea, creatinine and the liver marker enzymes SGOT, SGPT in serum of control and experimental groups. The non-protein nitrogen compounds, urea creatinine and the liver marker enzymes SGOT and SGPT were found to be significantly increased ( $P < 0.01$ ) in diabetic rats, when compared with control rats. In Group

III and IV rats administered with the *C. pictus* extract and glibenclamide respectively, the urea, creatinine levels and the liver marker enzymes showed a significant decrease when compared with diabetic rats. The plant extract alone treated Group V rats showed no significant change in all the above parameters when compared with Group I rats.

### 3.5. Changes in enzymic antioxidants and lipid peroxidation





**Figure 1.** Histopathology of rat liver.

A: Normal control liver section showing normal cords of hepatocytes; B: Diabetic control rats showing shrunken nuclei with granular cytoplasm; C: Plant extract treated diabetic rat liver section showing normal lobules with mild atrophy of hepatocytes; D: Plant extract alone treated rats with normal morphology; E: Glibenclamide treated rats with normal hepatocytes.

Table 5 shows the activities of enzymic antioxidants CAT, Px, and SOD in liver of control and experimental rats. The above mentioned antioxidant enzymes showed a significant decrease in diabetic rats when compared with control rats, but the lipid peroxidation level was significantly increased ( $P < 0.01$ ). The *C. pictus* extract treated and glibenclamide treated rats proved a significant increase ( $P < 0.01$ ) in CAT, Px and SOD when compared with diabetic rats, whereas lipid peroxidation showed a significant decrease.

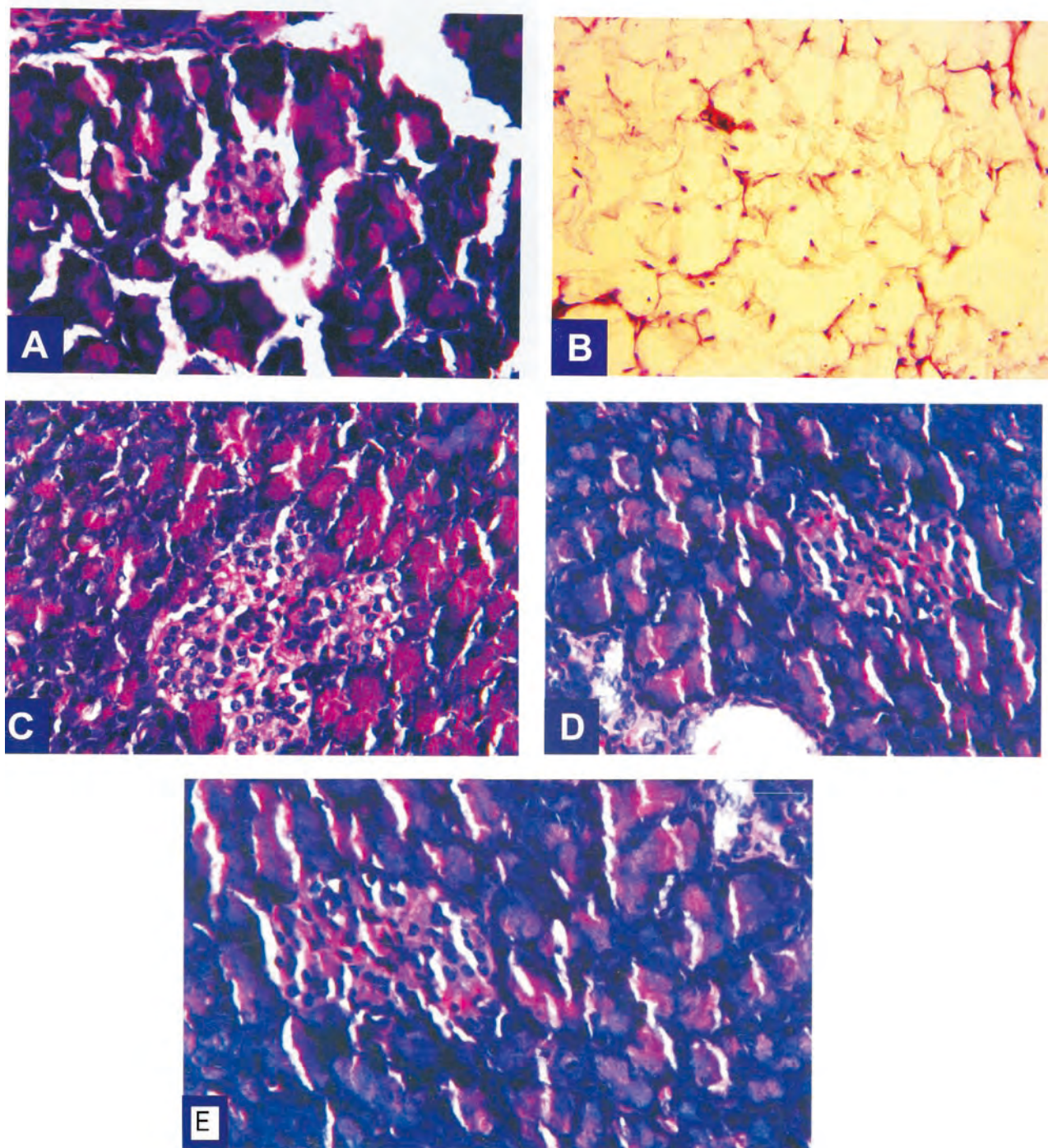
The antioxidants like CAT, Px, SOD and lipid peroxidation proved no significant change when the *C. pictus* extract alone treated rats and glibenclamide treated rats were

compared with control rats.

### 3.6. Changes in glycogen and protein

Table 6 reports the effect of aqueous extract of *C. pictus* on glycogen and protein concentration in the liver of control and experimental rats. The level of glycogen and protein was found to be significantly decreased in diabetic rats when compared with control rats. The *C. pictus* extract and glibenclamide treated rats showed a significant increase when compared with diabetic rats. The *C. pictus* extract alone treated rats showed no significant change in glycogen and protein concentration when compared with control rats.





**Figure 2.** Histopathology of rat pancreas.

A: Normal control pancreas section showing normal morphology of islets; B: Diabetic control rats with damaged islets and shrunken in size; C: Plant extract treated diabetic rat pancreas section showing structural intactness with their nucleus; D: Plant extract alone treated rats with regenerated islet cells; E: Glibenclamide treated rats with most recovered islet cells.

### 3.7. The histopathology studies of liver and pancreas

Histopathology of liver in control rats showed normal hepatic cells with well preserved cytoplasm, nucleus and nucleolus and central vein, whereas in diabetic control severe fatty changes, sinusoidal congestion and feathery degeneration of hepatocytes. The administration of aqueous extract of *C. pictus* and glibenclamide reverse all these changes induced by alloxan monohydrate in the treated groups. The aqueous extract of *C. pictus* alone treated Group V rats showed normal hepatic cell morphology thereby indicating that the plant has no toxicity effect on liver

(Figure 1).

Histopathological studies of pancreas in control animals showed normal pancreatic parenchymal cells and islet cells. In diabetic control, the section showed moderate hyperplasia of islet cell with mild infiltration of inflammatory cells. In animals treated with aqueous extract of *C. pictus* and glibenclamide only mild hyperplasia of islet cells was seen. In *C. pictus* alone treated rats (Group V) the pancreatic section showed normal pancreatic architecture (Figure 2).

## 4. Discussion

The increase in body weight was observed in normal rats throughout the study. The diabetic and *C. pictus* treated diabetic rats reduced in their body weight however the *C. pictus* treated rats maintained their body weight during the course of study. Weight loss in alloxan-treated animals is due to the degeneration of the adipocytes and muscle tissues. This compensate the energy lose from the body due to frequent urination and over-conversion of glycogen to glucose supporting our results. Increase in the body weight in Group III proves that the *C. pictus* has beneficial effect on body weight<sup>[12]</sup>.

In our study, significant increase in blood glucose was observed in alloxan induced diabetic rats. Alloxan causes a massive reduction in insulin release by the destruction of beta cells of the islets of langerhans, thereby inducing hyperglycaemia. In the absense of insulin, the peripheral tissues like adipose tissue and skeletal muscle are unable to take up glucose. So glucose conversion to fat and glycogen is blocked in the adipose tissue and skeletal muscle respectively resulting in increase of blood glucose level. In addition, glucagon stimulates gluconeogenesis and glycogenolysis in the liver, which contributes to increase in blood glucose<sup>[13]</sup>.

Diabetic rats treated with *C. pictus* extract and the reference drug glibenclamide resulting in significant decrease in the glucose level proves that the *C. pictus* extract may act by stimulating utilization of glucose by peripheral tissue or the involvement of hepatic factors like activation of glycogen synthetase or release of somatomedin having insulin like activity or inhibition of glucagons release.

Deaths in 65% of diabetic peoples are due to cardiovascular abnormalities. So a drug that maintains the lipid profile will be of much benefit for the prevention of coronary heart disease in diabetes. A marked increase in the level of cholesterol and triglycerides were observed in untreated diabetic rats. Insulin deficiency stimulates the lipolysis in the adipose tissue and gives rise to hyperlipidemia and fatty liver. Recent studies dictated that triglycerides itself is strongly related to coronary heart disease. The diabetic treated rats in group III and IV showed a reduction in the level of cholesterol and triglycerides when compared with untreated diabetic rats explains the beneficiary effect of the extract. Reports stated that insulin administration brings back the lipid levels to near normal values thereby inferring that the blood lipid level is regulated by blood sugar level or by circulating insulin level or by both<sup>[14]</sup>.

In diabetic rats a sharp fall in total protein, slight decline in albumin, globulin and a significant change in A/G ratio was observed. Insulin deficiency in diabetes causes excessive catabolism of protein and the aminoacids produced are utilized for gluconeogenesis. Hypoalbuminemia is a common problem in diabetic animals and is generally due to microproteinuria and albuminuria and this serves as the important clinical markers for the diabetic nephropathy. This study demonstrated that all the parameters of protein profile were normalised after the *C. pictus* treatment. This results are in consistant with studies on *Annona squamosa*<sup>[15]</sup>.

Liver and kidney damages were the prominent side effects in severe diabetic patients as well as in severe alloxan induced diabetes. Multisystem diseases like diabetic nephropathy that end up with nephrotic syndrome is characterised by a progressive damage to renal vein leading to thrombosis and fibrin degradation. Destruction of glomeruli in these progressive disorders causes significant decrease in glomerular filtration rate (GFR) and increase in blood urea and creatinine which are all the indicators of chronic renal failure<sup>[16]</sup>. The *C. pictus* extract treated rats and glibenclamide treated rats exhibited a decreased level of urea and creatinine. The restoration of urea and creatinine to

their normal level indicated the revival of insulin secretion and the prevention against renal damage. When the *C. pictus* extract alone treated rats were compared with control rats it did not show any significant change in the level of urea and creatinine thereby indicating that *C. pictus* does not alter the kidney functions.

Increased level of SGPT and SGOT were observed in the diabetic induced rats. The increase in AST and ALT will increase the incidence of heart and liver diseases. AST is an enzyme found primarily in the cells of the liver, heart, skeletal muscles, kidneys, pancreas, and to a lesser extent, in red blood cells. Its plasma concentration is in proportion to the amount of cellular leakage or damage. It is released into plasma in larger quantities when any one of these tissues is damaged. Its increased levels are usually associated with cardiac arrest or liver disease<sup>[17]</sup>. In *C. pictus* treated and glibenclamide treated rats the level of SGPT and SGOT were restored to normal level. Since SGPT and SGOT levels are markers of liver function, thereby restoration of their normal levels indicate normal functioning of liver. The plant extract alone treated rats showed no significant change when compared with control rats thereby proving the non-toxicity of the plant.

A possible mechanism for oxidative stress in diabetes is autooxidation of sugar and unsaturated lipid that leads to the production of free radicals, which damage the macromolecules. The involvement of oxidative stress in the causation of diabetes mellitus was well documented and the importance of antioxidants in the curation of diabetes mellitus was also reported. The major organ involved in diabetic complications is liver. To combat these oxidative stress induced damage, the liver has a very high concentration of oxidative free radical (OFR) scavenging enzymes, like SOD, Px, CAT, which are very low in islet cells. Increased production of OFR with inadequate defence, makes the islet  $\beta$  cells more susceptible to alloxan. In these cells alloxan induces membrane lipid peroxidation and extensive DNA strand breakage<sup>[18]</sup>. In the present study increased lipid peroxidation was found with alloxan diabetic rats due to the generation of free radicals.

Antioxidants scavenge a number of highly reactive oxygen free radicals rapidly. They have a great potential role in inhibiting the fibrotic process which is induced during the cell damage. Medicinal plants are used as source of antioxidants in traditional medicine and their therapeutic properties may be due to their capacity for scavenging oxygen free radicals. It is well known that CAT, SOD and glutathione Px play an important role as protective enzymes against free radical formation in tissues<sup>[19]</sup>. Administration of antioxidants might actually stimulate cell survival by strengthening the defence systems and also exerted the scavenging effect on the generated free radicals thereby sparing the cells<sup>[20]</sup>.

In present study the enzymic antioxidants in liver of control and experimental groups were decreased in alloxan-induced diabetes rats. Super oxide radicals produced during diabetes mellitus damage the essential components like extra cellular matrix, lipoproteins and DNA. The enzymatic antioxidant defense system including SOD and catalases can decompose superoxide and hydrogen peroxide in the cells, which are the main defence against oxidative injuries. SOD catalyses the rapid removal of superoxide radical. Because the SOD enzyme generates  $H_2O_2$ , it works in collaboration with  $H_2O_2$  removing enzymes. CAT present in the peroxisomes of nearly all aerobic cells, serves to protect the cell from the toxic effects of hydrogen peroxide by catalysing its decomposition into molecular oxygen and water without the production of free radicals.

The activity of this enzyme is decreased significantly



in the liver of alloxan induced diabetic animals due to increased oxidative stress. Increase in SOD activity was noticed in treated Group III and Group IV rats indicating that the antidiabetic treatments neutralized oxidative stress and increased liver SOD activity.

Increased oxidative stress has been proposed to be one of the major causes of hyperglycaemia induced diabetic complication, and hyperglycaemia in an organism stimulates reactive oxygen species (ROS) formation from variety of sources. The present study represents the increased activity of lipid peroxidation in alloxan induced diabetic rats. Free radicals are formed disproportionately in diabetes mellitus by glucose degradation, non-enzymatic glycation of proteins, and the subsequent oxidative degradation. The generation of free radicals may lead to lipid peroxidation and associated complications in diabetes mellitus. Administration of *C. pictus* extract to diabetic rats significantly decreased the levels of lipid peroxidation. It is probable that ROS may induce LPO and modify SOD, CAT and treatment with plant extract mitigate this action. It is suggested that the *C. pictus* extract may function as an antidiabetic agent and lower alloxan induced lipid peroxidation damage and oxidative stress in diabetes. Increased activities of these denovo antioxidant enzymes might be responsible for the scavenging effect, with subsequent protection of cells against lipid peroxidation<sup>[21]</sup>.

It showed a significant decrease in liver glycogen and protein level in diabetic rats when compared to control animals. The decrease in glycogen content of liver observed in the present study is probably due to the lack of insulin in diabetic rats. This prevention of glycogen depletion in the liver is possibly due to stimulation of insulin release from pancreas. In the *C. pictus* extract treated rats and glibenclamide treated rats, the protein and glycogen concentration in the liver was significantly increased. The increase glycogen in liver may be brought about by an increase in glycogenesis and a decrease in glycogenolysis<sup>[22]</sup>.

Under severe oxidative stress the free radicals produced damage to the proteins which could be the possible cause for the reduction of protein content in the alloxan diabetic rats. Treatment with the plant drug removes the free radicals and so there is an increase in the protein content of *C. pictus* treated diabetic rats<sup>[23]</sup>. Present study provide experimental support for the use of *C. pictus* D.Don in the treatment of diabetes mellitus.

### Conflict of interest statement

We declare that we have no conflict of interest.

### Acknowledgements

The authors are thankful to the chairman and chancellor, chief executive officer, vice chancellor and registrar of Karpagam University, Coimbatore, India for providing facilities for our study.

### References

- [1] Lanjhiyana S, Garabadu D, Ahirwar D, Bigoniya P, Rana AC. Antidiabetic activity of methanolic extract of stem bark of *elaodendron glaucum* Pers. in alloxanized rat model. *Adv Appl Sci Res* 2011; **2**: 47–62.
- [2] Renuka C, Ramesh N, Saravanan K. Evaluation of the antidiabetic effect of *Trigonella foenum-graecum* seed powder on alloxaninduced diabetic albino rats. *Int J PharmTech Res* 2009; **1**: 1580–1584.
- [3] Gupta R, Bajpai KG, Johri S, Saxena AM. An overview of indian novel traditional medicinal plants with anti-diabetic potentials. *African J Tradit Compliment Altern Med* 2008; **5**: 1–17.
- [4] Jayasri MA, Mathew L, Radha A. A report on the antioxidant activity of leaves and rhizomes of *Costus pictus* D.Don. *Int J Integr Biol* 2009; **5**: 1–20.
- [5] Nadumane VK, Rajashekar S, Narayana P, Adinarayana S, Vijayan S. Evaluation of the anticancer potential of *Costus pictus* on fibrosarcoma (HT-1080) cell line. *J Net Pham* 2011; **2**: 72–76.
- [6] Lowry OH, Rosebrough NJ, Farr AL, Randall RJ. Protein measurement with folins phenol reagent. *J Biol Chem* 1951; **193**: 265.
- [7] Morales MA, Jabbagy AJ, Terenizi HR. Mutations affecting accumulation of glycogen. *Neurospora News Lett* 1973; **30**: 24–25.
- [8] Misra HP, Fridovich I. The role of superoxide anion in the autooxidation of epinephrine and a simple assay or superoxide dismutase. *J Biol Chem* 1972; **247**: 3170–3175.
- [9] Sinha A. Catalase– An extra ordinary enzyme. *Science* 1972; **210**: 71–82.
- [10] McGowan MV, Artiss JD, Strandbergh DR, Zak B. A peroxidase-coupled method for the colorimetric determination of serum triglycerides. *Clin Chem* 1983; **29**: 538–542.
- [11] Hogberg J, Larson RE, Kristoferson A, Orrhenices IS. NADPH dependent reductase solubilised from microsomes by peroxidation and its activity. *Biochem Biophys Res Commun* 1974; **56**: 836–842.
- [12] Ramadan G, Nadia M, Beih E, Eman A, Ghffar AE. Modulatory effects of black vs. green tea aqueous extract on hyperglycaemia, hyperlipidaemia and liver dysfunction in diabetic and obese rat models. *British J Nutr* 2009; **102**: 1611–1619.
- [13] Sharma VK, Kumar S, Patel HJ, Hugar S. Hypoglycemic activity of *Ficus glomerata* in alloxan induced diabetic rats. *Int J Pharmaceutical Sci Rev Res* 2010; **1**: 17–22.
- [14] Karthik D, Ravikumar S. A Study on the protective effect of *Cynodon dactylon* leaves extract in diabetic rats. *Biomed Environ Sci* 2011; **24**: 190–199.
- [15] Kaleem M, Medha P, Ahmed QU, Asif M, Bano B. Beneficial effects of *Annona squamosa* extract in streptozotocin-induced diabetic rats. *Singapore Med J* 2008; **49**: 800–804.
- [16] Gupta R, Katariya P, Mathur M, Bajaj VK, Yadav S. Antidiabetic and renoprotective activity of *Momordica dioica* in diabetic rats. *Diabetologia Croatica* 2011; **40**: 81–88.
- [17] Daryoush M, Bahram AT, Yousef D, Mehrdad N. Protective effect of turnip root (*Brassica rapa*. L) ethanolic extract on early hepatic injury in alloxanized diabetic rats. *Australian J Basic Appl Sci* 2011; **5**: 748–756.
- [18] Burade KB, Kuchekar BS. Antidiabetic activity of madhunashini (md-19) in alloxan induced diabetes mellitus. *J Cell Tissue Res* 2011; **11**: 2515–2520.
- [19] Maruthupandian A, Mohan VR. Antidiabetic, antihyperlipidaemic and antioxidant activity of *Pterocarpus marsupium* Roxb. In alloxan induced diabetic rats. *Int J PharmTech Res* 2011; **3**: 1681–1687.
- [20] Dallatu MK, Anaja PO, Bilbis LS, Mojiminiyi FBO. Antioxidant micronutrient potentials in strengthening the antioxidant defense in alloxan-induced diabetic rats. *Nig J Pharm Sci* 2009; **8**: 89–94.
- [21] Dallak M, Bin-Jaliah I. Antioxidant activity of *Citrullus colocynthis* pulp extract in the RBC's of alloxan-induced diabetic rats. *Pak J Physiol* 2010; **6**: 1–5.
- [22] Daisy P, Santosh K, Rajathi M. Antihyperglycemic and antihyperlipidemic effects of *Clitoria ternatea* Linn. In alloxan-induced diabetic rats. *African J Microbiol Res* 2009; **3**: 287–291.
- [23] Chitra V, Varma P, Raju M, Prakash KJ. Study of antidiabetic and free radical scavenging activity of the seed extract of *Strychnos nuxvomica*. *Int J Pharm Pharmaceutical Sci* 2010; **Suppl 1**: 106–110.