

Contents lists available at [ScienceDirect](#)

Asian Pacific Journal of Tropical Medicine

journal homepage: www.elsevier.com/locate/apjtm

Document heading doi:

Correlation between MMP-2 and NF- κ B expression of intracranial aneurysm

Wei-Tao Cheng, Ning Wang*

Department of Neurosurgery, Xuanwu Capital University, Beijing 100053, China

ARTICLE INFO

Article history:

Received 10 March 2013

Received in revised form 15 April 2013

Accepted 15 May 2013

Available online 20 July 2013

Keywords:

Intracranial aneurysms

Nuclear factor- κ B

Matrix metalloproteinase-2

Reverse transcription-polymerase

Chain reaction

Immunohistochemistry

ABSTRACT

Objective: To investigate the correlation between expressions of MMP-2 and NF- κ B in the intracranial aneurysm wall, and explore their role in the mechanism of the occurrence, growth and rupture of intracranial aneurysms. **Methods:** RT-PCR was used to detect the expression of MMP-2 and NF- κ B mRNA of 30 cases of intracranial aneurysm tissue and 10 cases of normal intracranial arterial tissue; Immunohistochemical method was used to detect the expression of MMP-2 and NF- κ B protein. **Results:** The semi-quantitative analysis of MMP-2 and NF- κ B in aneurysms tissues and normal tissues were statistically significant different from each other ($P < 0.05$). Immunohistochemical staining results showed NF- κ B was expressed in different layers. The expression of them were positive in intimal and medial, and the expression sites were located in the nucleus. MMP-2 were expressed in different layers of the aneurysm wall, and the expressions were positive in media and extima. The MMP-2 and NF- κ B-positive expression of aneurysm wall were significantly higher than in normal cerebral arteries ($P < 0.05$). MMP-2 and NF- κ B mRNA expression showed positive correlation in the aneurysm wall tissue ($r = 0.689$, $P = 0.005$). **Conclusions:** The expressions of MMP-2 and NF- κ B in the intracranial aneurysm wall tissue were significantly higher than in the normal intracranial arterial tissues. They have a synergistic effect on the formation of intracranial aneurysms.

1. Introduction

Intracranial aneurysm (IA) refers to a pathological localized expansion caused by intracranial local vascular variation, which is the most severe one of the common clinical cerebrovascular disease. The disabled rate and mortality were very high, and has seriously impact on people's health^[1]. Although a large number of scholars have studied the IAs, the pathogenesis is yet not well clarified. We think that it may be caused by a congenital vascular wall hypoplasia or intracranial arteries degenerative change. More and more studies suggest that chronic inflammation

of the arteries is an important factor which can lead to intracranial arterial degeneration^[2]. Nuclear factor κ (NF- κ B) plays an important role in the inflammatory response. Matrix metalloproteinase -2 (MMP-2) plays an important role in vascular remodeling. Therefore, the expressions of NF- κ B and MMP-2 in IAs were investigated to provide a theoretical basis for the pathogenesis of the disease.

2. Materials and methods

2.1. Materials

All specimens of patients in the experimental group were taken from 30 cases with neurosurgical IAs after surgical resection in our hospital from January 2011 to June 2012,

*Corresponding author: Ning Wang, Department of Neurosurgery, Xuanwu Capital University, Beijing 100053, China.
Tel: 13522955190
E-mail: ningjing.wd@sohu.com

including 18 male cases, 12 female cases, aged from 26 months to 56 years (mean 42 years). There were 7 cases in small size, 18 in middle size and 5 were giant.

All patients in the control group were taken from 10 cases of hospital at the same period, thus the cortical arteries tissue from non-vascular lesions in patients with traumatic brain injury after resection. There were 7 males and 3 females aged from 23–48 years with mean age 36 years old.

2.2. Reagents and instruments

Agarose, ethidium bromide, chloroform, isoamyl alcohol, ethanol, isopropyl alcohol were provided by the laboratory; Trizol, DEPC, RT-PCR kits were purchased from Bioasis Biological Technology Co.; NF- κ B, MMP-2 and β -actin were purchased from Wuhan Boster Biological; Mouse anti-human NF- κ B monoclonal antibody-mouse anti-human MMP-2 monoclonal antibody, goat serum blocking solution, second antibody PV-6000 general type, DAB chromogenic reagent were purchased from Beijing Zhongshan Golden Bridge Biotechnology Co., Ltd. PCR amplification cycler type (Bio-Rad; USA); America Bio-Rad Gel doc 2000 gel image analysis system. (Bio-Rad; USA)

2.3. RT-PCR detection of the NF- κ B and MMP-2 expression in mRNA level

Some tissues were immediately obtained after surgical resection and stored in liquid nitrogen, then detected by laboratory examination. RNA was extracted by Trizol method, then underwent cDNA synthesis and PCR. The primers were shown in Table 1. The PCR products were examined by electrophoresis with agarose gel, and analyzed by Doc 2000 gel image analysis system.

Table 1
NF- κ B, MMP-2 and β -actin primer sequences.

Primer name	Primer sequences	Fragment length	Reaction conditions
MMP-2	5'-agatcttcttctcaaggaccgggtt-3'	225 bp	63 °C
	5'-ggctggtcagtggttgggta-3'		
NF- κ B	5'-gaggtgtatttcacgggacc-3'	954 bp	51 °C
	5'-gaagtcacatgtccgcaatgg-3'		
β -actin	5'-cagccatgtacgttctctac-3'	626 bp	59 °C
	5'-ggagtacttgcgctcaggag-3'		

2.4. HE staining and immunohistochemistry detection of NF- κ B and MMP-2 protein expression

The paraffin sections were deparaffinized by normal method, and then underwent routine HE staining. Histological features of the specimen were observed.

The immunohistochemical EnVision method was used, with mouse anti-NF- κ B monoclonal antibody (working concentration 1:100), mouse anti-MMP-2 monoclonal antibody (working concentration 1:100) and ready-to-use second antibody. It was stained in accordance with the instructions, with PBS instead of primary antibody as a negative control.

2.5. Determination of results

RT-PCR test results were automatically read by computer and the grayscale integral value of each stripe were recorded, statistical analysis was performed by sample integral value/internal reference ratio. Double blind method was adopted to observe the results, and the buffy cell plasm was taken as the positive expression. Results were determined in accordance with the following standard: Negative (-): positive cells <10%; weakly positive (+): positive cells were 10%–25%; positive (+ +): the number of positive cells were 25%–50%; strongly positive (+ + +): positive cells number > 50%.

2.6. Statistical analysis

SPSS 13.0 statistical software were used for statistical analysis, and the data were expressed by mean \pm standard error, *t* test and χ^2 test and Spearman rank correlation analysis were used to analyze. *P* < 0.05 was considered as statistical significance.

3. Results

3.1. Comparison of NF- κ B and MMP-2

Specimens of the experimental group and the control group were analyzed by RT-PCR, the positive expression rates of NF- κ B and MMP-2 of 30 patients with IAs were 27/30 and 28/30, respectively. Semi-quantitatively showed that the expression of NF- κ B and MMP-2 in the experimental group (1.26 ± 0.17 , 1.39 ± 0.27 , respectively) were significantly higher than that in the control group (0.23 ± 0.05 , 0.61 ± 0.18 , respectively), the difference was statistically significant ($t = 2.456$, 2.262 ; both *P* < 0.05) (Figure 1).

3.2. HE staining, NF- κ B and MMP-2 protein levels

The arterial structures were normal in the control group, with normal intimals and regular muscular layer in media,

lining up in cocentric circle, and with no inflammatory cell infiltration. The intima, media and extima structure of the IA specimens were abnormal in experimental group. Endothelial cells were reduced or even disappeared, discontinuous, and the collagen fibers increased. The muscular layer of media was reduced or even disappear, with a large number of fibroblasts and inflammatory cell infiltration, and concentric structure disappeared. There was lipid deposition in extima, with a large number of inflammatory cell infiltrations. Immunohistochemistry results showed positive expressions in the intima, media and extima in MMP-2 experimental groups, especially in the media and extima. Specimens in the control group showed no MMP-2 positive expression. There were NF- κ B positive expression in the intima, media and extima of the experimental group, especially in the intima and media. The positive expression of the control group was 30% in the cytoplasm. The expression of NF- κ B and MMP-2 of the aneurysm specimens were significantly higher than the control group, with statistically significance ($P < 0.05$) (Table 2).

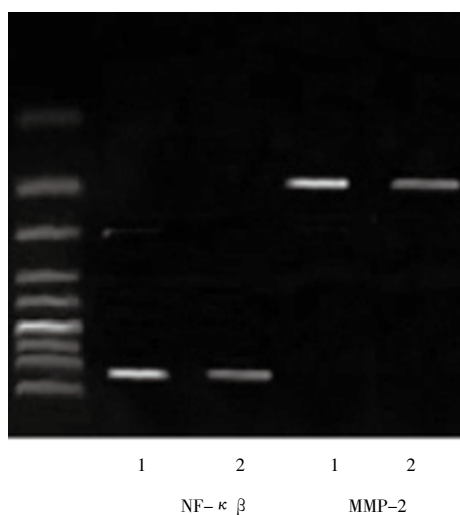


Figure 1. NF- κ B and MMP-2 expression.

1 Experimental group; 2 control group.

Table 2

NF- κ B and MMP-2 expression at protein level.

Groups	NF- κ B		MMP-2	
	-	+~+++	-	+~+++
Experimental group	2	28	2	28
Control group	7	3	10	0
χ^2	17.25		31.11	
<i>P</i> values	< 0.05		< 0.05	

3.3. Correlation analysis between NF- κ B and MMP-2 expression in the aneurysmal tissues

In the aneurysm tissues, the mRNA expressions of NF- κ

B and MMP-2 were evaluated by Spearman rank correlation. The result showed that there was a significant correlation between the expression of them in IA wall ($r=0.689$, $P=0.005$).

4. Discussion

Arterial wall contains several layers of structure such as elastic collagen and smooth muscle fibers which can increase the elastic, thus can fully adapt to the changes of the arterial blood pressure. But the intracranial artery, also known as cerebral artery, was unlike other arteries. Due to its special location, its histological features including long and thin, large degree of curve, and the arterial wall is thin with inelasticity[3]. Once the arterial wall get thinning for any reason, the fragility pathological change may occur, that will cause arterial wall lesions and aneurysm formation, and when blood pressure rising, there will be rupture and bleeding. However, the occurrence and development mechanism of IA is not clear. At present, the aneurysms and atherosclerosis usually coexist, atherosclerosis makes arterial wall degraded and weak, which is one of the important factors for the formation of aneurysm. It is confirmed that the IAs is closely related to the atherosclerotic disease, and a large number of studies suggest that atherosclerosis is related to arterial wall chronic inflammatory response and vascular remodeling[4]. Some biologically active enzyme plays an important role in the pathologic process of the arterial wall. In this study, we researched NF- κ B and MMP-2 in order to find their role in the pathologic process of IAs.

In this study, we observed the histological features of the specimens, the result showed the intima, media and extima structure of the IA specimens were abnormal. Endothelial cells reduce or even disappear, discontinuous, and the collagen fibers increases. The muscular layer of media reduce or even disappear, with a large number of fibroblasts and inflammatory cell infiltration, concentric structure disappeared. There are lipid deposition in extima, with a large number of inflammatory cell infiltrations, which proved that atherosclerosis is an important factor involved in the development and progression of IAs.

Since early atherosclerotic, vascular remodeling occurs. Inflammatory cells increased significantly, and the expression of NF- κ B and MMP-2 can be changed. Studies have shown that NF- κ B can be activated in atherosclerotic tissue, which considered to be one of the key factors regulating the inflammatory response gene transcription and participate in the endothelial cells damage of the artery

wall^[5]. Experimental studies of mice model also confirmed the expressions of aneurysm tissue related gene NF- κ B were significantly increased^[6]. In this study, we detected the NF- κ B mRNA protein expression in the aneurysmal tissue and the control tissue, and found that the NF- κ B expression was significantly increased in the aneurysmal tissue. Its main expression was in the intima and media of the arterial, located in the nucleus. The result was in agreement with that reported in the literature, there are also studies suggest that NF- κ B belongs to a shear stress induced response element, the local hemodynamic changes of the intracranial arterial can cause the expression of NF- κ B and its downstream target genes, and then participate in the vascular remodeling of the aneurysmal wall^[7].

MMPs are a kind of proteolytic enzyme that can destroy the extracellular matrix, which can be divided into five categories according to their substrate specificity. The most important gelatinase which involved in regulating the homeostasis of extracellular matrix is MMP-2, and also collagen IV, V, VIII, IX, laminin, elastin and fibronectin, which considered to be the lytic enzyme with most destructive effect on the ECM^[8]. In this study, we detected the MMP-2 mRNA and protein expression in the aneurysmal tissues and the control tissues, and the result showed the MMP-2 expression in the aneurysm tissues was significantly higher. Its main expression was in the media and extima of the arterial, located in the cytoplasm. Animal experiments have found that a large number of inflammatory cells infiltrated into the aneurysm lesions, release a large number of MMP-2 and other protease, thus causing the degradation and fracture of the extracellular matrix, collagen and elastin, which forcing the formation of aneurysms^[9]. The NF- κ B and MMP-2 expression were positively correlated of the IA wall, its mechanism may be the atherosclerosis of the intracranial artery wall which can cause increased expression of NF- κ B, then promote a chronic inflammatory response of the arterial wall. By intervention of a large number of inflammatory cytokines, it can promote the increasing expression of MMP-2, and involved in vascular remodeling^[10]. This study suggests that both of them may play a key role in vascular remodeling in the aneurysm wall.

In summary, a variety of factors are widely involved in the pathogenic role of NF- κ B in IAs, which play an important role in the vascular remodeling process by promoting the

expression of MMP-2.

Conflict of interest statement

We declare that we have no conflict of interest.

References

- [1] Komotar RJ, Moceo J, Solomon RA. Guidelines for the surgical treatment of unruptured intracranial aneurysms: the first annual J. Lawrence poolmemorial research symposium—controversies in the management of cerebral aneurysms. *Neurosurgery* 2008; **62**(1): 183–193.
- [2] Liu XJ, Zou AQ, Hu CC, Zhou XB, Zhao YY. Expression and significance of MMP-2, MMP-9, TIMP-1 in intracranial aneurysms. *Jiangxi Med J* 2011; **46**(3): 220–222.
- [3] Liao XX, Ma LT, Li J. The significance of the express MMP 2, MMP-9 and VEGF in intracranial cystic artery aneurysms. *Guangdong Med J* 2009; **30**(8): 1094–1097.
- [4] Wu G, Xu BN. The effects of artery damages in intracranial aneurysm and intracranial arteriosclerosis. *Medical Recapitulate* 2007; **13**(2): 91–92.
- [5] Han L, Wang ZG, Qu CC. Expression and correlation of NF-KAPPA B and vascular endothelial growth factor in intracranial aneurysm and bascular. *Chinese J Neural Mental Illness* 2008; **34**(2): 91–94.
- [6] Aoki T, Kataoka H, Ishibashi R, Nakagami H, Nozaki K, Morishita R, et al. Pitavastatin suppresses formation and progression of cerebral aneurysms through inhibition of the nuclear factor kappa B pathway. *Neurosurgery* 2009; **64**(2): 357–365.
- [7] Liu L, Xu BN. Hemodynamic and pathological factors role in the pathogenesis of intracranial aneurysms. *Chin J Senile Cardio-cerebrovascular Dis* 2008; **10**(5): 391–392.
- [8] He ZZ. Matrix metalloproteinases and intracranial aneurysm. *Pract J Clin Med* 2011; **8**(5): 185–188.
- [9] Dong JQ, Cuo BJ, Jiao DR. Matrix metalloproteinases and intracranial aneurysm. *Int J Neurol Neurosurg* 2009; **36**(1): 56–58.
- [10] Sun XF, Qiao GR, Lan HT. The relationship between the expression of the NF- κ B and MMPs in hypertension induced cerebral aneurysm in rats. *Chin J Neurosurg* 2006; **22**(10): 628–631.