

HOSTED BY



ELSEVIER

Contents lists available at ScienceDirect

Asian Pacific Journal of Tropical Medicine

journal homepage: <http://ees.elsevier.com/apjtm>Original research <http://dx.doi.org/10.1016/j.apjtm.2016.01.038>Antihydatic and immunomodulatory effects of *Punica granatum* peel aqueous extract in a murine model of echinococcosis

Moussa Labsi, Lila Khelifi, Dalila Mezioug, Imene Soufli, Chafia Touil-Boukoffa*

Laboratory of Cellular and Molecular Biology, Department of Biology, University of Sciences and Technology Houari Boumediene, Algiers, Algeria

ARTICLE INFO

Article history:

Received 15 Dec 2015

Received in revised form 20 Dec 2015

Accepted 30 Dec 2015

Available online 13 Jan 2016

Keywords:

PGE

Tumor necrosis factor- α

iNOS

Nuclear factor- κ B

ABSTRACT

Objective: To investigate the effect of pomegranate peel aqueous extract (PGE) on the development of secondary experimental echinococcosis and on the viability of *Echinococcus granulosus* protoscoleces, and the immunomodulatory properties of PGE.

Methods: Swiss mice were inoculated intraperitoneally with viable protoscoleces. Then, PGE was orally administered daily during cystic echinococcosis development. Cyst development and hepatic damage were macroscopically and histologically analyzed. The production of nitric oxide and TNF- α was assessed in plasma and the hepatic expression of iNOS, TNF- α , NF- κ B and CD68 was examined. Moreover, protoscoleces were cultured and treated with different concentrations of PGE.

Results: It was observed that *in vitro* treatment of protoscoleces caused a significant decrease in viability in a PGE-dose-dependent manner. *In vivo*, after treatment of cystic echinococcosis infected mice with PGE, a significant decrease in nitric oxide levels ($P < 0.0001$) and TNF- α levels ($P < 0.001$) was observed. This decline was strongly related to the inhibition of cyst development (rate of hydatid cyst growth inhibition = 63.08%) and a decrease in CD68 expression in both the pericystic layer of hepatic hydatid cysts and liver tissue ($P < 0.0001$). A significant diminution of iNOS, TNF- α and NF- κ B expression was also observed in liver tissue of treated mice ($P < 0.0001$).

Conclusions: Our results indicate an antihydatic scolicidal effect and immunomodulatory properties of PGE, suggesting its potential therapeutic role against *Echinococcus granulosus* infection.

1. Introduction

Cystic echinococcosis (CE) is a chronic zoonosis affecting humans as well as domestic animals, caused in humans by infection with the larval stage of a parasitic cestode, *Echinococcus granulosus* (*E. granulosus*). CE is one of the most important and widespread parasitic disease in the Mediterranean basin, especially in North Africa (Maghreb) [1]. CE is characterized by primary cyst development in the liver and lungs and other viscera of the intermediate host. *E. granulosus* infection is characterized by a prolonged coexistence of the parasite and the host with no effective rejection reaction. The variability and severity of the clinical expression of this

parasitosis are associated with the duration and intensity of infection [2].

Our current experimental model of secondary echinococcosis is based on the development of hydatid cysts in the mouse peritoneal cavity after inoculation with viable protoscoleces (PSCs) [3,4]. During *E. granulosus* infection in mice, protoscoleces differentiate into the metacestode 34 d post-inoculation [4]. The initial stage of experimental echinococcosis (a month) is characterized by a Th1 type immune response with an increase in interferon (IFN)- γ levels and reduced levels of interleukin (IL)-4 and IL-10 [5]. The second phase occurs once the hydatid cyst is fully formed and is characterized by a more Th2-type response, with elevated IL-4, IL-5 and IL-10 and a decrease in IFN- γ and TNF- α [5,6]. In humans, elevated levels of nitric oxide (NO) and IFN- γ have been observed in sera from some patients with *E. granulosus* infections [7].

Currently, treatment modalities for CE include surgery and chemotherapy. However, surgery remains the main therapeutic

*Corresponding author: Chafia Touil-Boukoffa, Laboratory of Cellular and Molecular Biology, Department of Biology, University of Sciences and Technology Houari Boumediene, Algiers, Algeria.

Tel: +213 550819857

E-mail: touilboukoffa@yahoo.fr

Peer review under responsibility of Hainan Medical College.

approach throughout the world [8]. Therefore, it is imperative to develop alternative therapeutic approaches. Therapies using medicinal plants have emerged as potential new strategies [9–12].

Punica granatum (*P. granatum*) L. (common name pomegranate; subfamily Punicaceae) is a small tree originating from Asia and now widely cultivated in the Mediterranean basin, particularly in Algeria. Dried pomegranate peel is used to treat disorders such as colitis, dysentery and ulcers [13]. Pomegranate peel extract has anti-coccidial, anthelmintic and antibacterial activities [14,15]. Moreover, the root and stem barks are reported to have astringent and anthelmintic activity [13]. Several studies have demonstrated the therapeutic antioxidant, antimicrobial and anti-inflammatory effects of *P. granatum* fruit, peel, and juice. These effects are mainly exerted by molecules like polyphenols and tannins [16–18].

In this study, we investigate the antihydatic and immunomodulatory effects of *P. granatum* peel aqueous extract (PGE) using a murine model of echinococcosis. In this context, we evaluated the effect of PGE on the development of murine echinococcosis and on the viability of PSCs *in vitro*. Furthermore, systemic levels of NO and TNF- α secretion were assessed during the experimental CE. In addition, hepatic expression of iNOS, NF- κ B, TNF- α , and CD68 and histological changes were analyzed in histopathological and immune-histopathological studies.

2. Materials and methods

2.1. *E. granulosus* protoscoleces

E. granulosus PSC was collected as described by Amri *et al* [19]. Briefly, the hydatid fluid was removed by aseptic puncture of fertile human pulmonary hydatid cysts. The fluid was centrifuged at 3000 rpm for 10 min at 4 °C. The pellet containing PSCs was washed several times in sterile PBS supplemented with 30 μ g/mL gentamicin. PSC viability was assessed prior to inoculation and determined by body movement observed under inverted microscopy and vital staining with 0.1% eosin. All samples had viability >98% at the time of experiment. Swiss mice were inoculated intraperitoneally (*ip.*) with 2000 viable PSCs resuspended in 500 μ L of sterile PBS [4].

2.2. Mice

Female Swiss Albino mice (four to six weeks old) were purchased from the Pasteur Institute (Algiers, Algeria). These mice were acclimated for a week before the start of experiments and kept under normal conditions with a 12 h dark/light cycle

with *ad libitum* access to food and water. Mice ranging in weight from 21 g to 23 g were divided into three groups ($n = 9$ mice per group) as per Figure 1. This study was approved by the ethics committee of the national agency of research development in health. The control group (Ctrl) received no treatment. The CE and PGE/CE groups received intraperitoneal injection with a suspension of 2000 viable PSCs in 500 μ L of sterile PBS. The PGE/CE group was treated by daily intragastric administration of 500 μ L of PGE at a concentration of 0.65 g/kg for two months, from two days following infection. The PBS group received intraperitoneal injection with 500 μ L of sterile PBS instead of PSCs. The PGE group, which was not infected with PSCs, received a daily intragastric administration of 500 μ L of PGE at a concentration of 0.65 g/kg for two months. All mice were euthanized three months post-PSC inoculation.

2.3. Assessment of cyst development

All mice were euthanized three months post-PSC inoculation, peritoneal cysts were isolated and their weight and diameter measured. Then, the larval growth and the inhibition rate were calculated as described by Moreno *et al* [20].

2.4. Preparation of PGE

Pomegranate was collected during November 2012 in eastern Algeria (Beni Ourtilane). The peels were separated from fruits, dried at room temperature for 12 d, and powdered using an electric mill. The extract was prepared by aqueous maceration and filtered through Whatman filter paper.

2.5. Plasma collection

Mice were anesthetized with chloroform, and blood was collected via cardiac puncture. Blood was centrifuged to isolate plasma, which was kept at -20 °C until use.

2.6. Nitrite measurement

The Griess reaction was used to determine nitrite levels in plasma as an indicator of NO production, as described previously [7]. Briefly, 100 μ L of each sample was mixed with 50 μ L of Griess reagent (5% sulfanilamide, 0.5% naphthylethylenediamine dihydrochloride, 20% HCl). Samples were incubated at room temperature for 20 min and the absorbance read at 543 nm by spectrophotometer. The nitrite concentration was determined using a standard curve constructed with sodium nitrite [NaNO_2 ; (0–200) μ mol/mL].

2.7. Measurement of systemic TNF- α level

The systemic level of TNF- α was determined in the plasma of mice using commercial enzyme-linked immunosorbent assay kits, according to the manufacturer's instructions (Invitrogen, Camarillo, USA).

2.8. Histopathological analysis

For histological examination, small sections of liver (according to cyst localization) were excised, fixed in 10% buffered formalin, mounted in paraffin blocks and cut into 2- μ m-thick

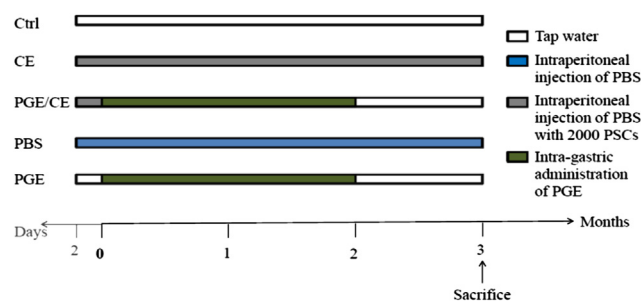


Figure 1. Experimental plan.

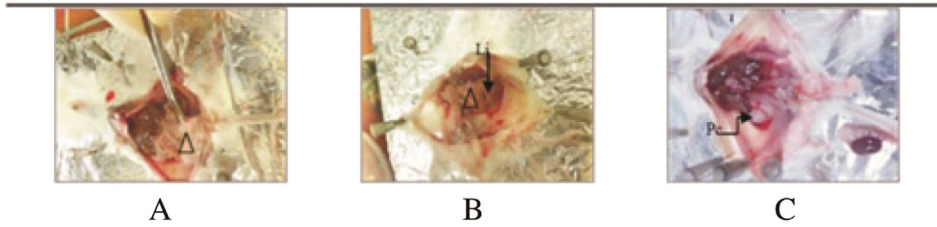


Figure 2. Intraperitoneal localization of hydatid cysts in infected mice.

A: mice infected with hydatid cyst in peritoneal cavity; B: mice infected with hydatid cyst in liver; C: mice infected with polycyst in peritoneal cavity. (Δ) Cyst; (Li): liver; (Pe): polycyst.

sections. The sections were stained with hematoxylin and eosin to study histological changes, Masson's trichrome stain to evaluate fibrosis, Perls' stain for iron, and metachromatic toluidine blue stain for quantification of cell infiltration.

Histological criteria were based on the degree of architectural tissue changes and cellular infiltration. Images were captured from each slide with a digital camera (Casio) on a light microscope (Motic) with 10×, 40× and 100× objectives. Morphometry was performed using FIJI image processing software after calibration with a graduated slide. The percentage of tissue fibrosis and the number of inflammatory cells in the pericystic layer of hepatic hydatid cysts were calculated using area measurement and point selection, respectively. A total of 30 photomicrographs were analyzed and quantified for each liver sample.

Necroinflammatory activity was scored according to the histological activity index (HAI) described by Mekonnen *et al* [21]. Venous congestion was included in the HAI: 0, absence; 1, weak; 2, moderate; 3, severe. The HAI was also assigned according to the extent of fibrosis: 0, absence; 1, mild portal fibrosis; 2, moderate fibrosis; 3, severe fibrosis; and 4, cirrhosis. Steatosis was graded as follows: 0, absent; 1, 1%–10% of hepatocytes affected; 2, 11%–30% of hepatocytes affected; 3, 31%–60% of hepatocytes affected; and 4, >60% of hepatocytes affected [22]. Hepatic iron deposits were evaluated by Perls' stain and were scored according to Brissot *et al* [22,23]. Histopathological diagnoses were performed in double blinded fashion by anatomopathologists (Pr. Z-CA and Mr. M-AL).

2.9. Immunohistochemical procedures

Immunohistochemical study of CD68, NF-κB, TNF-α and iNOS expression was performed on formalin-fixed, paraffin-embedded samples. Indirect immunoperoxidase staining was performed as described in the manufacturer's instructions (DAKO, Denmark A/S). Sections of 2-μm-thick tissue were deparaffinized using xylene, and rehydrated through a graded series of ethanol. The sections were then subjected to antigen retrieval in EnVision™ FLEX target retrieval solution [low pH (K8005) for iNOS, TNF-α and NF-κB detection and high pH

(K8004) for CD68 detection] at 95 °C for 45 min. All subsequent steps were performed at room temperature in a humidified chamber. Endogenous peroxide was blocked with EnVision™ FLEX peroxidase-blocking reagent (DM821) for 5 min. Monoclonal mouse anti-CD68 (clone PG-M1, DAKO, Denmark A/S) was used as primary antibody for studying the percentage of macrophages infiltrating in pericyclic layer of hepatic hydatid cyst. We also incubated liver sections with rabbit monoclonal antibodies against mouse NF-κB/p65 subunit, TNF-α and iNOS (Santa Cruz Biotechnology, Dallas, TX, USA; diluted 1:100, 1:100, and 1:500 respectively) overnight at 4 °C. The detection of primary mouse antibodies was performed with EnVision™ FLEX. The chromagen solution 3, 3'-diaminobenzidine was added. The sections were counterstained with hematoxylin. Slides were covered with Faramount Mounting Medium (S3025, DAKO, Denmark A/S) and color development was observed using a standard microscope (Motic). Pictures were taken using a digital camera (Casio) at 40× resolution.

The percentage of cells positively stained for iNOS, TNF-α, NF-κB and CD68 was scored semiquantitatively. The positive cells were identified by brown staining (peroxidase). For NF-κB expression, we quantified by determination of the intensity of the brown staining. The quantification was carried out on 30 high-power fields in each liver sample by two observers (ML, M-AL). iNOS and TNF-α expression was evaluated on the basis of a four-point scale: '-': negative staining; '+': low expression, less than 10% positive cells; '++': moderate expression, 10%–50% positive cells; '+++': diffuse expression, more than 50% positive cells. The intensity of NF-κB/p65 immunostaining was evaluated as weak, moderate or intense on a subjective basis.

2.10. Protoscoleces culture

After viability assessment of PSCs, they were cultured in 48-well tissue culture plates at a density of 2500 PSCs/mL in RPMI 1640 medium supplemented with 2 mM glutamine and 10% fetal calf serum, at 37 °C in humidified atmosphere of 5% CO₂. After 24 h of PSC culture, PGE or albendazole was added at 2, 4, 8 or 16 mg/mL, or 0.02 mg/mL, respectively. All experiments were conducted in triplicate.

Table 1

Intraperitoneal inoculation of Swiss mice with *E. granulosus* protoscoleces from human pulmonary hydatid cysts and study of herbal treatment with *P. granatum*.

Experimental group	Diameter of cysts (mm)	Weight of cysts (mg)	Percentage of infected mice (%)	Hepatic localization of cysts	Rate of hydatid cyst growth inhibition (%)
Ctrl group	–	–	–	–	–
CE group	1.59 ± 0.22	8.55 ± 1.24	100 (9/9 mice)	6/9 mice	–
PGE/CE group	1.01 ± 0.21	3.16 ± 0.66**	100 (9/9 mice)	6/9 mice	63.08

Compared with CE group, **P < 0.005.

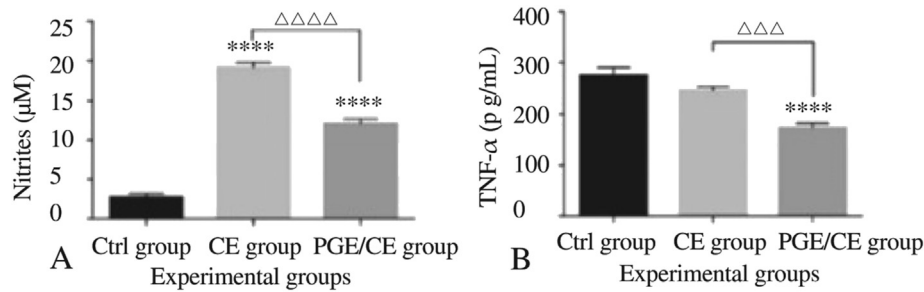


Figure 3. Oral administration of pomegranate peel aqueous extract reduced the systemic production of nitrite (A) and TNF- α (B) *in vivo*. Compared with ctrl group, **** $P < 0.0001$, compared with CE group, $\Delta\Delta\Delta P < 0.001$, $\Delta\Delta\Delta\Delta P < 0.0001$.

After 6, 12, 24, 48, 72, 96 and 120 h of PSC culture, PSC viability was assayed by microscopy/eosin exclusion. The mortality rate was determined by counting a minimum of 100 PSCs (as the ratio of the number of dead PSCs/total number of PSCs). Assessment was based on PSC vital staining, motility, and morphological criteria, as described by Amri *et al* [19].

2.11. Statistical analysis

All data are expressed as means \pm SEM. Statistical analysis was performed by one-way ANOVA to compare all groups. *t*-tests were performed to analyze both time (CE induction) and treatment effects. Two-way ANOVA was performed for the study of protoscolicidal activity of PGE. The Kruskal–Wallis test was used for iNOS, TNF- α , NF- κ B and CD68 quantification in liver sections. The Mann–Whitney U test was used for fibrosis, infiltrating cells, and CD68 quantification in the pericystic layer of hepatic hydatid cysts. Probability values of $P < 0.05$ were considered to be statistically significant.

3. Results

3.1. Effect of PGE on clinical parameters of secondary experimental echinococcosis

Three months post-infection, animals developed CE in the liver and other intraperitoneal areas (Figure 2) with an

infectivity of 100% in both the CE group and PGE/CE group (Table 1). The diameter and the weight of developed cysts were measured to evaluate the effect of PGE treatment at doses of 0.65 g of the extract per kg body weight (Table 1). The diameter ($P > 0.05$) and the weight ($P < 0.005$) of hydatid cysts were decreased in the PGE/CE group. PGE treatment inhibited cyst growth by 63.08% in the PGE/CE group. Thus, PGE treatment induced a significant reduction of the clinical symptoms during CE.

3.2. PGE treatment reduced systemic levels of NO

We investigated the effect of PGE on NO production in secondary echinococcosis. NO measurement in plasma of mice showed a significant increase in the CE group compared to the Ctrl group [(19.17 \pm 0.58) μ M vs. (2.74 \pm 0.42) μ M, $P < 0.0001$; Figure 3A]. Administration of PGE to mice with CE caused a significant decrease in systemic NO level in comparison with the untreated-CE group ($P < 0.0001$; Figure 3A).

3.3. Decrease in TNF- α level *in vivo*

To analyze the effect of PGE on proinflammatory cytokine TNF- α production *in vivo* during CE development, we measured the level of TNF- α in plasma (Figure 3B). The systemic TNF- α level was decreased in the CE group in comparison with the Ctrl group ($P > 0.05$ Figure 3B). PGE treatment attenuated TNF- α

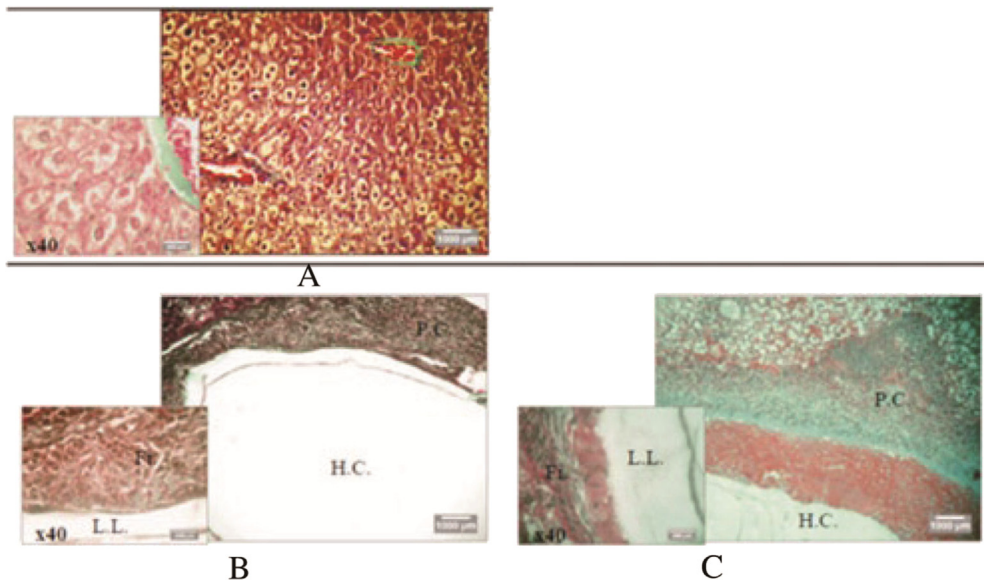


Figure 4. Representative photomicrographs ($\times 10$ and $\times 40$) of Masson's trichrome stained liver sections from the Control group (A), CE group (B), and PGE/CE group (C).

(H. C.): hydatid cyst; (P. C.): Pericyst; (L. L.): laminated layer; (Fi.): Fibrosis localized.

expression compared with untreated infected mice ($P < 0.001$) and control mice ($P < 0.0001$).

3.4. Liver architecture was improved in mice treated with PGE

Hepatic echinococcosis comprises cystic forms, associated with the establishment of a periparasitic granuloma in the liver and an irreversible fibrosis in the pericyst [24]. The fibrotic area was evaluated using Masson's trichrome stain (Figure 4).

Histological analysis of liver from the CE group showing proliferation of kupffer cells, congestion of vein blood, infiltration of inflammation cells with portal area, degeneration of hepatocytes with fatty vacuoles (Figure 5B), associated with an intense inflammatory cell (lymphocytes, neutrophil and macrophage) extending throughout the pericystic layer of hydatid cysts (Figure 5D). This result was correlated with what Baqer *et al* found [25]. This observation was accompanied by fibrosis (Figure 4B) and in some cases necrotic hepatocytes (Figure 5C). These observations contrast with the Ctrl group, which exhibited normal hepatic tissue (Figure 5A,B).

The administration of PGE to mice with CE caused an improvement in the histological structure in liver sections relative to untreated CE mice. It was accompanied by less fibrosis (Figure 4C compared with B). Nonetheless, cellular infiltration was still observed and a homogeneous mass formed around the cyst (Figure 5E). The pericystic layer of hepatic hydatid cysts in the CE group is characterized by a more extensive fibrotic reaction than that in the pericyst of the PGE/CE group (Figure 4B compared with C). The fibrotic reaction was quantified with a significant difference between the pericyst of the CE group and

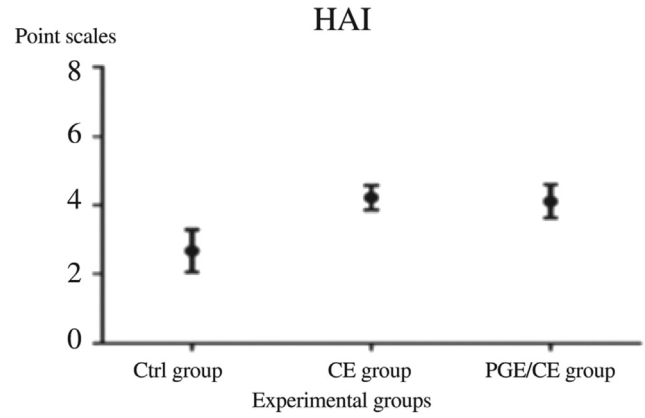


Figure 6. Improvement of the histological structure by administration of PGE in mice infected with PSCs.

of the PGE/CE group ($43.75\% \pm 0.92\%$ vs. $70.73\% \pm 1.12\%$, $P < 0.0001$).

The oral administration of PGE to Swiss mice did not cause any toxic or secondary effects. No toxic effects were observed in the PGE/CE group, which was confirmed via histopathological analysis of mouse liver (Figure 5F). A decrease in the histology damage score (HAI) was shown in the PGE/CE group compared with the CE group (Figure 6).

Toluidine blue staining was applied for identification of cells infiltrate (macrophages and plasma cells) in pericystic layer of hydatid cyst. An intense immune response against hydatid cyst development was involved in pericystic layer of CE group by severe cells infiltrate (macrophages, lymphocytes and polynuclear cells) with a significant difference compared with PGE/CE group [36.38 ± 1.32] cells

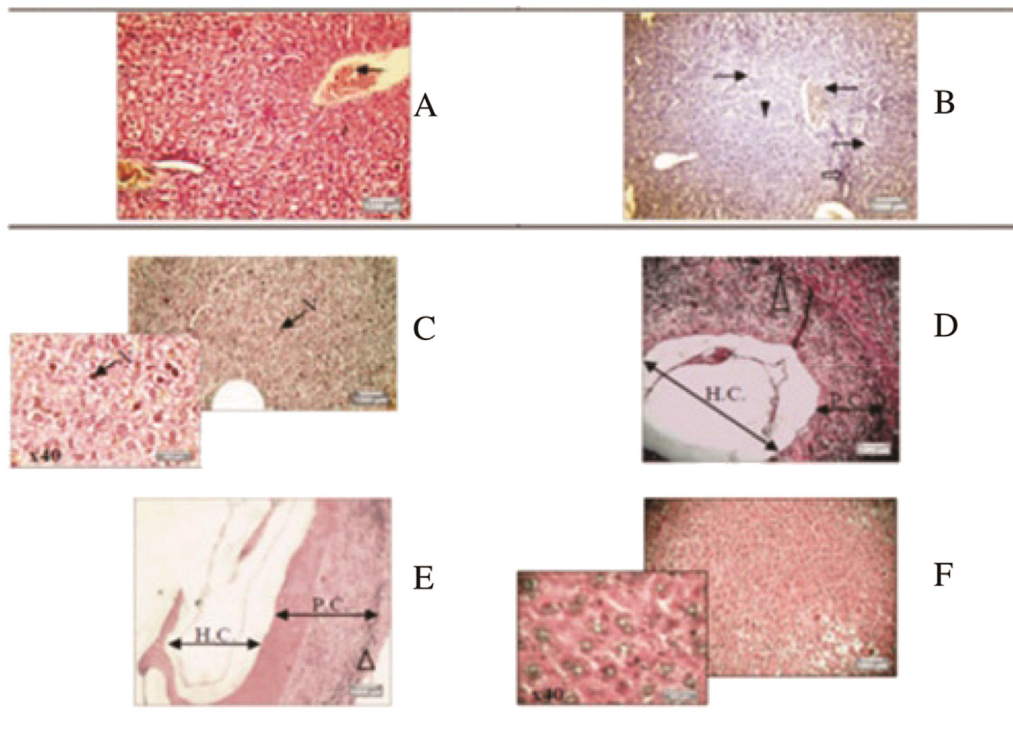


Figure 5. Representative photomicrographs (x10 and x40) of H&E stained liver tissue from Control group, CE group, and PGE/CE group. A: Control group; B: Liver section damaged in CE group; C: Necrosis in CE group; D: Uniloculaire cyst in CE group; E: Uniloculaire cyst in PGE/CE group; F: Liver sections ameliorated in PGE/CE group. (H.C.): hydatid cyst; (P.C.): Pericyst; (N): necrotic hepatocytes; (Δ): inflammatory cells. (⇒): infiltration of inflammation cells with portal area; (▼): proliferation of kupffer cell; (≡): congestion of vein blood; (↗): degeneration of hepatocytes with fatty vacuoles.

infiltrating/mm² vs. (47.05 ± 1.70) cells infiltrating/mm², $P < 0.0001$; Figure 7B].

Histopathological analysis of hepatic hydatid cysts from the PGE/CE group demonstrated a moderate immune response to the infection, characterized by a fibrotic reaction and inflammatory cells. Interestingly, this observation correlated with a significant decrease in the growth of cysts in the liver.

3.5. Down regulation of iNOS, TNF- α and NF- κ B expression in liver sections of the PGE/CE group

The expression of iNOS, TNF- α and NF- κ B was shown in hepatocytes and Kupffer cells (Figure 8). The expression was significantly increased in the CE group compared with the untreated Ctrl group ($P < 0.0001$; Table 2). This increase in expression in liver sections was significantly attenuated by PGE treatment ($P < 0.0001$; Table 2). In liver biopsies of the PGE/CE group and Ctrl group, there was, strikingly, no significant difference in NF- κ B expression.

3.6. Decrease of CD68 expression in liver sections of the PGE/CE group

Interest a positive reaction was observed for CD68 in infected mice (Figure 9 and Table 2). A significant decrease in cells that express CD68 (Kupffer cells) in the liver sections of mice treated with PGE was clearly demonstrated in comparison with the CE group (CD68: 1.56% ± 0.06% vs. 4.60% ± 0.21%, $P < 0.0001$). A similar result was also observed in the pericystic layer of hepatic hydatid cysts of the PGE/CE group in comparison with the CE group for CD68 macrophage infiltrating cells (0.30% ± 0.02% vs. 0.96% ± 0.08%, $P < 0.0001$). The fibrotic tissue revealed the presence of macrophages (CD68 positive), although other inflammatory cells were also present in both infected and treated mice.

Brown-staining indicates specific CD68 detection in all hepatic sections. Pericystic sections of infected mice show the

CD68 expression was enhanced in comparison with the non-cystic liver sections (Figure 9 and Table 2).

3.7. In vitro scolicidal activity of PGE

In this study, the anthelmintic effect of PGE was demonstrated *in vitro* in culture of protoscolecemes from human pulmonary hydatid cysts. The viability of PSCs was assessed by the 0.1% aqueous eosin red stain method (Figure 10). The mortality of PSCs after exposure to different concentrations of PGE for various time periods is reported in Table 3. PSCs were treated with 2, 4, 8 or 16 mg/mL PGE or 0.02 mg/mL albendazole after 24 h of culture. Albendazole has been shown to have potent scolicidal effects against protoscolecemes of hydatid cysts [26]. Thus, protoscolecemes were treated with 0.02 mg/mL of albendazole as positive control. The mortality of PSCs was determined at 6, 12, 24, 48, 72, 96 and 120 h post-treatment. Drug was added 24 h after culture of viable protoscolecemes at a density of 2500 PSCs/mL.

The scolicidal activity of PGE was observed from 6 h post-treatment at the lowest concentration (2 mg/mL). In fact, the mortality of PSCs at this time point and at the lowest PGE concentration was higher than on albendazole treatment (9.10% ± 0.36% vs. 8.07% ± 0.56%).

PSC treatment with PGE induced a significantly higher mortality that increased with dose and treatment period, reaching 100% when PGE was given at 16 mg/mL for only 2 d. The efficacy at the lowest dose from 48 h post-treatment was better than that of albendazole administered alone (22.54% ± 0.61% vs. 14.39% ± 0.91%; Figure 10). However, after a longer period (5 d), untreated PSCs showed mortality (20.36% ± 0.63%). Our results indicate that the scolicidal activity of PGE is both dose- and time-dependent.

4. Discussion

The liver is the major site of hydatid disease. The goals of hepatic hydatid cyst treatment are a complete elimination of

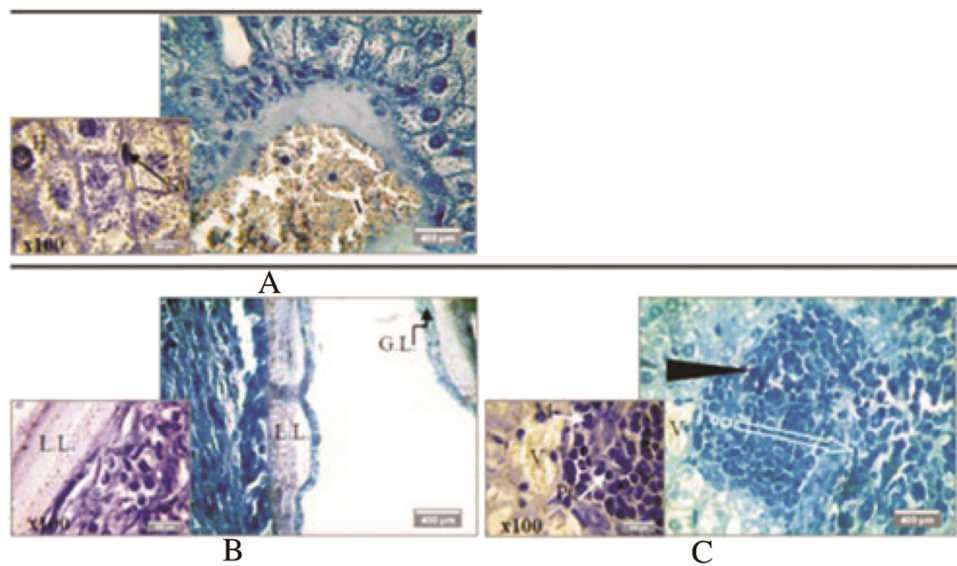


Figure 7. Representative photomicrographs (×40, ×100) of toluidine blue stained liver sections with Lison's method from the Control group (A), CE group (B), and PGE/CE group (C).

(H): hepatocytes; (K): Kupffer cells; (V): hepatic vein; (►) inflammatory cells; (M): macrophages; (PC): plasma cells; (L, L): Laminated layer; (G, L): germinal layer.

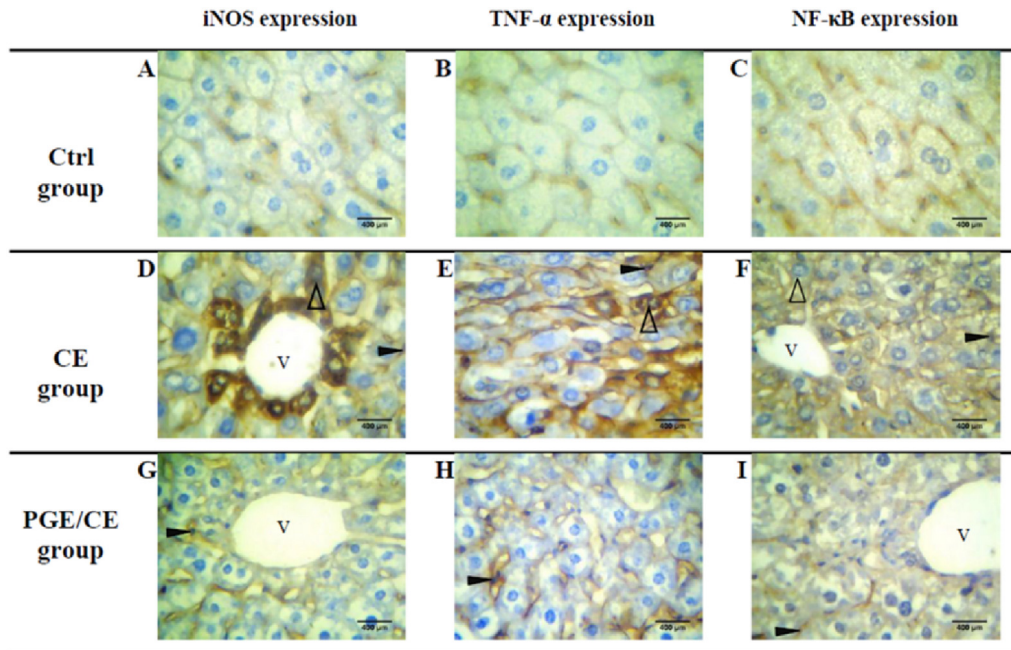


Figure 8. Representative images (×40) of immunohistochemical analysis for iNOS, TNF- α and NF- κ B expression in liver with hepatic hydatid cysts. (A, B) Liver sections of Ctrl group with low expression of iNOS and TNF- α , scored as ‘+’. (C) Intensity of NF- κ B in liver sections of Ctrl group was evaluated as weak. (D, E) Liver sections of the CE group showed moderate expression of iNOS, graded as ‘++’, and diffuse expression of TNF- α , scored as ‘+++’. (F) Intensity of NF- κ B in liver tissue of the CE group was evaluated as intense. (G, H) Liver sections of PGE/CE group with low expression of iNOS and TNF- α , both graded as ‘+’. (I) Liver sections of the PGE/CE group with weak intensity of NF- κ B. (Δ): hepatocytes with positive staining; (\blacktriangleright): Kupffer cells with positive staining; (V): hepatic vein.

metacestodes and prevention of recurrence, minimizing mortality and morbidity risk. In order to achieve these aims, it is essential to choose the most appropriate treatment to the clinical aspect of cysts [27]. Currently, the basic approaches for treatment of hydatid cyst are surgery and chemotherapy [8,27]. However, operative leakage may lead to dissemination of viable protoscolices to adjacent tissues and thus to develop secondary infection [28]. Furthermore, antiparasitic drugs treatments such as benzimidazole analogs are potentially toxic in many subjects [29]. In this regard, our investigations based on the use of a medicinal plant (*P. granatum*) were conducted to evaluate both an alternative natural drug with no toxic effects and its protective abilities.

Studies of pomegranate constituents on animals at concentrations and levels commonly used in folk and traditional medicines note no toxic effects. *P. granatum* peel extract is a rich source of phytochemicals that can produce toxic effects at higher consumption rates or from long-term administration [30]. Patel et al [31] reported that the oral lethal dose 50 of PGE in Wistar rats and Swiss albino mice was >5 g/kg body weight. In our study, the oral lethal dose 50 of PGE in Swiss mice ($n = 10$) was (6.53 ± 0.12) g/kg. Repeated oral administration to Swiss mice during two months of treatment once a day at doses of 0.65 g/kg body weight produced no toxic effects in terms of food intake, weight gain, behavioral parameters, or histopathological results.

Intragastric administration of PGE in Swiss mice showed a significant inhibitory effect on hydatid cyst development. Actually, our data showed a decrease in hydatid cyst weight and diameter in PGE/CE group. Those observations correlate with a less fibrotic reaction in the pericystic layer of hepatic hydatid cysts. Histological study of liver confirmed irreversible fibrosis on CE infection. In fact, the percentage of fibrosis was significantly lower in the PGE/CE group than in the CE group.

The antioxidant activity and hepatoprotective effect of pomegranate peel and vinegar was evaluated in Wistar rats by Ashoush et al [32] and Bouazza et al [33] using various biochemical parameters and histopathological studies. Other studies have shown a hepatoprotective capacity of pomegranate peel extract against t-BOOH and CCl₄, cytotoxic agents studied as liver toxicants [34,35]. These effects might be correlated with a radical scavenging effect [35]. Based on the results of our histopathological study and on NO measurement in plasma, PGE exhibited a potential antioxidant effect. The literature indicates that the antioxidant effect of pomegranate may be related to its phenolic content, which is higher in peels and flowers than in leaves and seeds [36].

Many studies have investigated the antioxidant and anti-inflammatory effects of pomegranate peel *in vivo* and *in vitro*. Hou et al [37] showed the inhibition of NO production by proanthocyanidins and anthocyanidins, compounds of pomegranate peel and juice. Ellagitannins (punicalin and punicalagin) extracted from pomegranate peel have antioxidant activities and downregulate UV-B mediated activation of NF- κ B [38]. In addition, Rosillo et al [39] demonstrated that ellagic acid-enriched pomegranate extract attenuates chronic colonic inflammation in rats by both reduction of pro-inflammatory TNF- α production and inhibition of pro-inflammatory cyclooxygenase-2 and iNOS protein expression in colon tissue from TNBS-induced colitis rats.

In our study, the immunochemical marker CD68 was used for assessment of the inflammatory reaction in the pericystic layer of hepatic hydatid cysts and the non-cystic liver sections (macrophage infiltrate and kupffer cells detection, respectively). CD68 expression in the CE group was higher in the pericystic layer of hepatic hydatid cysts compared with liver tissue sections. In the PGE/CE group, we showed a significant decrease of CD68 expression in the liver sections and in the pericystic layer

Table 2

Percentages of iNOS, TNF- α , NF- κ B, and CD68 expression in hepatic sections of Ctrl group, CE group, and PGE/CE group.

Antibody expression	Ctrl group	CE group	PGE/CE group
iNOS in liver sections	2.70 \pm 0.72	37.50 \pm 2.62 [#]	7.28 \pm 0.46 [*]
TNF- α in liver sections	3.11 \pm 0.16	43.68 \pm 2.53 [#]	7.37 \pm 1.24 [*]
NF- κ B in liver sections	3.67 \pm 0.23	11.57 \pm 1.16 [#]	3.75 \pm 0.47 [*]
CD68 in liver	0.23 \pm 0.01	4.60 \pm 0.21 [#]	1.56 \pm 0.06 [*]
CD68 in pericyst sections	–	0.96 \pm 0.08	0.30 \pm 0.02 [‡]

[#]*P* < 0.0001 vs. Ctrl group, ^{*}*P* < 0.0001 vs. liver sections of the CE group, [‡]*P* < 0.0001 vs. pericyst of the CE group.

of hepatic hydatid cysts. Using CD68 detection, we identified the involvement of macrophages against CE. We observed with interest that PGE administration reduced both the levels of CD68 Kupffer cells and CD68 macrophages in liver tissues and

in pericytic areas. The anti-inflammatory and hepatoprotective effects of pomegranate was also demonstrated by a localized attenuation of NF- κ B, iNOS, TNF- α expression and systemic decrease in NO and TNF α levels in PGE/CE group. Concomitantly, PGE treatment caused an important decrease of HAI score and inflammatory cells infiltration.

Many studies reported that NO produced by the monocyte/macrophage system has toxic activities against *E. granulosus* infection [7,40]. These toxic effects induced by NO on hepatic hydatid cysts were previously investigated by Ait Aissa *et al* [40]. In our current study, we focused our attention on the effect of PGE treatment on NO production and TNF- α secretion knowing that this cytokine is a hallmark of inflammatory response and is involved in the expression of inducible NO synthase. In fact, massive NO production is a result of iNOS induction in response to lipopolysaccharides and pro-inflammatory cytokines, including TNF- α [41]. Many

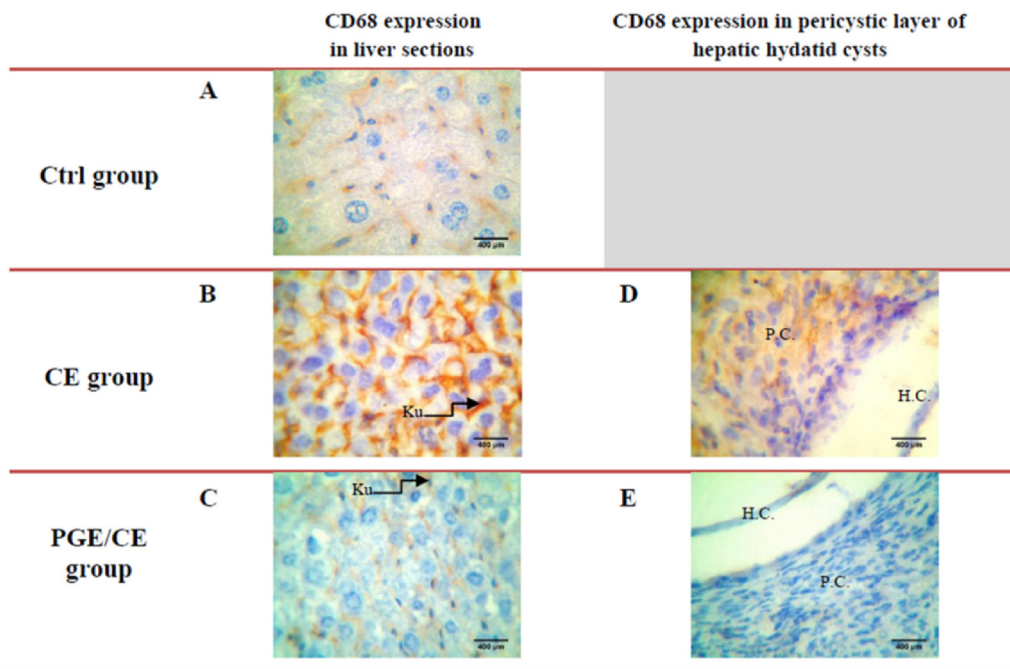


Figure 9. Immunohistochemical analysis of liver biopsies associated with cystic localization in representative images ($\times 40$) for marker CD68. (A) Liver sections of the Ctrl group showed no positive reaction for CD68. (B) Liver sections of the CE group showed an intense positive reaction in Kupffer cells for CD68 expression. (C) Treatment with PGE reduced the intensity of CD68 expression compared with untreated infected mice. (D) In the pericytic layer of hepatic hydatid cysts in the CE group a positive reaction was found for marker CD68 macrophages. (E) In the PGE/CE group a decrease of brown staining in fibrotic tissue was observed in comparison with untreated infected mice. (P. C) pericytic layer of hepatic hydatid cyst; (H. C.) hydatid cyst. (Ku) Kupffer cells with CD68 positive staining.

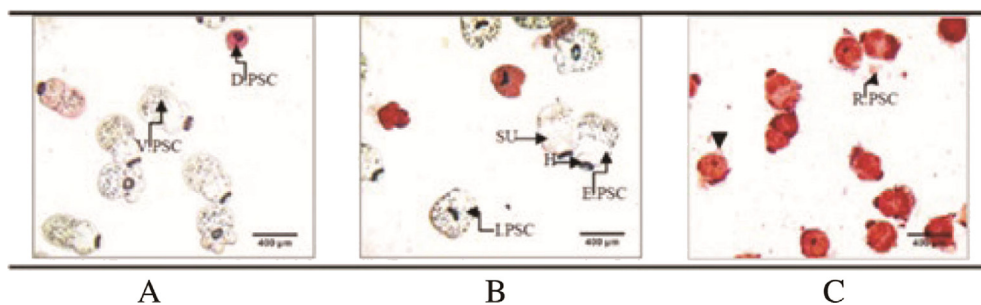


Figure 10. Morphological aspects of cultured PSCs in the presence of PGE or albendazole ($\times 40$). (A) Viable and dead protoscoleces after 48 h of exposure to 0.02 mg/mL albendazole. (B) Viable and dead protoscoleces after 48 h of exposure to 2 mg/mL PGE. (C) Dead protoscoleces after 48 h of exposure to 16 mg/mL PGE with absorbed dye. (D. PSC): dead protoscoleces; (V. PSC): viable protoscoleces; (I. PSC): invaginated protoscoleces; (E. PSC): evaginated protoscoleces; (H): hooks; (SU): suckers; (R. PSC): retracted protoscoleces; (\blacktriangledown): Alteration of tegument; (Res): Residues of dead protoscoleces.

Table 3

Effect of *P. granatum* on protoscolex viability.

Drug dose	Mortality of protoscolexes (%)						
	6 h	12 h	24 h	48 h	72 h	96 h	120 h
Untreated control	3.44 ± 0.17	5.59 ± 0.48	9.51 ± 0.69	12.38 ± 0.92	16.51 ± 0.23	20.36 ± 0.63	26.70 ± 0.90
PGE (2 mg/mL)	9.10 ± 0.36 ^{*‡}	12.64 ± 0.46 ^{*‡}	14.52 ± 0.59 ^{*‡}	22.54 ± 0.61 ^{*‡}	28.17 ± 2.04 ^{*‡}	54.53 ± 1.83 ^{*‡}	100.0 ± 0.00 ^{*‡}
PGE (4 mg/mL)	14.27 ± 0.37 ^{*‡#}	16.12 ± 1.21 ^{*‡#}	20.68 ± 1.84 ^{*‡#}	40.34 ± 3.92 ^{*‡#}	61.66 ± 3.44 ^{*‡#}	100.0 ± 0.00 ^{*‡#}	100.0 ± 0.00 ^{*‡}
23.64 ± 1.56							
PGE (8 mg/mL)	23.64 ± 1.56 ^{*‡#}	58.52 ± 2.84 ^{*‡#}	71.02 ± 0.39 ^{*‡#}	96.35 ± 1.01 ^{*‡#}	100.0 ± 0.00 ^{*‡#}	100.0 ± 0.00 ^{*‡#}	100.0 ± 0.00 ^{*‡#}
PGE (16 mg/mL) ^{*‡}	47.40 ± 3.84 ^{*‡#}	85.50 ± 0.28 ^{*‡#}	93.89 ± 0.80 ^{*‡#}	100.0 ± 0.00 ^{*‡#}	100.0 ± 0.00 ^{*‡#}	100.0 ± 0.00 ^{*‡#}	100.0 ± 0.00 ^{*‡#}
Albendazole (0.02 mg/mL)	8.07 ± 0.56 [*]	9.79 ± 0.50 [*]	12.68 ± 1.03 [*]	14.39 ± 0.91 [*]	22.25 ± 1.54 [*]	33.77 ± 0.99 [*]	49.41 ± 0.63 [*]

**P* < 0.0001 vs. untreated control, [‡]*P* < 0.0001 vs. Albendazole, [#]*P* < 0.0001 vs. PGE (2 mg/mL).

authors have reported the effect of TNF-α on iNOS expression through NF-κB activation [42]. In our work, we report the presence of inducible NO synthase in liver biopsies of the CE and PGE/CE groups by an immunohistochemical method using monoclonal antibodies against mouse iNOS. The cytoplasmic expression of iNOS was related to the presence of NF-κB and TNF-α in hepatocytes of hepatic hydatid cysts and also in Kupffer cells. Remarkably, we noticed a significant decrease of iNOS, NF-κB and TNF-α expression after treatment with PGE. The anti-inflammatory properties of PGE are marked by a systemic decrease in NO level and TNF-α level in the PGE/CE group in comparison with the CE group. These results are associated with the reduction of CE development.

Moreover, the scolicidal effect of PGE in various concentrations and over different time periods was reported here. In our study, the viability of PSCs was affected following the addition of ascending concentrations of PGE (2, 4, 8, 16 mg/mL). The death rate of protoscolexes reached 100% at the lowest concentration after 120 h. It is notable that increasing exposure time resulted in greater protoscolicidal activity. It has been suggested that the dose-dependent protoscolicidal effects of medicinal plant extracts such as *Nigella Sativa* are due to their ability to inhibit DNA synthesis by inhibiting histone deacetylase enzyme interacting with the chromosomes or in breaking down biological activities of protoscolexes through interference with metabolism [43]. The extracts may have target sites such as inhibitors of protein or DNA synthesis [12]. Moreover, most of the antimicrobial activity in medicinal plants appears to be derived from phenolic compounds [10]. The exact mechanism of the antiparasitic effect of PGE is not clear and further studies must be conducted to identify the bioactive compounds of pomegranate and to elucidate their mechanisms against cystic echinococcosis. Thus, according to these data, we can conclude that the PGE could be considered as a safe and potent scolicidal agent.

In conclusion, our data support the hypothesis that PGE treatment has both anthelmintic and immunomodulatory effects against the development of experimental echinococcosis. PGE administration effectively promoted an antihydatic effect and improved anti-inflammatory and protective responses. Our results suggest that PGE affords therapeutic advantages and may be a good candidate in the treatment of human hydatidosis.

Conflict of interest statement

The author reports no competing interests.

Acknowledgements

The author would like to thank Pr. Zine-Charaf Amir for his important contribution in histological study, Mohamed-Amine Lazourgui for his important contribution in histological and immunohistological study and for his technical help.

References

- [1] Dakkak A. Echinococcosis/hydatidosis: a severe threat in Mediterranean countries. *Vet Parasitol* 2010; **174**(1–2): 2–11.
- [2] Mezioug D, Touil-Boukoffa C. Interleukin-17A correlates with interleukin-6 production in human cystic echinococcosis: a possible involvement of IL-17A in immunoprotection against *Echinococcus granulosus* infection. *Eur Cytokine Netw* 2012; **23**(3): 112–119.
- [3] Dematteis S, Rottenberg M, Baz A. Cytokine response and outcome of infection depends on the infective dose of parasites in experimental infection by *Echinococcus granulosus*. *Parasite Immunol* 2003; **25**(4): 189–197.
- [4] Urrea-Paris MA, Moreno MJ, Casado N, Rodriguez-Caabeiro F. Relationship between the efficacy of praziquantel treatment and the cystic differentiation *in vivo* of *Echinococcus granulosus* metacystode. *Parasitol Res* 2002; **88**(1): 26–31.
- [5] Rogan MT. T-cell activity associated with secondary infections and implant cysts of *Echinococcus granulosus* in BALB/c mice. *Parasite Immunol* 1998; **20**(11): 527–533.
- [6] Haralabidis S, Karagouni E, Frydas S, Dotsika E. Immunoglobulin and cytokine profile in murine secondary hydatidosis. *Parasite Immunol* 1995; **17**(12): 625–630.
- [7] Touil-Boukoffa C, Bauvois B, Sanceau J, Hamrioui B, Weitzerbin J. Production of nitric oxide (NO) in human hydatidosis: relationship between nitrite production and interferon-gamma levels. *Biochimie* 1998; **80**(8–9): 738–744.
- [8] Brunetti E, Kern P, Vuitton DA. Expert consensus for the diagnosis and treatment of cystic and alveolar echinococcosis in humans. *Acta Trop* 2010; **114**(1): 1–16.
- [9] Pensel PE, Maggiore MA, Gende LB, Eguaras MJ, Denegri MG, Elisondo MC. Efficacy of essential oils of *Thymus vulgaris* and *Origanum vulgare* on *Echinococcus granulosus*. *Interdiscip Persp Infect Dis* 2014; <http://dx.doi.org/10.1155/2014/693289>. 693289.
- [10] Moazeni M, Roozitalab A. High scolicidal effect of *Zataria multiflora* on protoscolexes of hydatid cyst: an *in vitro* study. *Comp Clin Pathol* 2012; **21**(1): 99–104.
- [11] Zibaei M, Sarlak A, Delfan B, Ezatpour B, Azargoon A. Scolicidal effects of *Olea europaea* and *Satureja khuzestanica* extracts on protoscolexes of hydatid cysts. *Korean J Parasitol* 2012; **50**(1): 53–56.
- [12] Yones DA, Taher GA, Ibrahim ZZ. *In vitro* effects of some herbs used in Egyptian traditional medicine on viability of protoscolexes of hydatid cysts. *Korean J Parasitol* 2011; **49**(3): 255–263.
- [13] Braga LC, Shupp JW, Cumings C, Jett M, Takahashi JA, Carmo I, et al. Pomegranate extract inhibits *Staphylococcus aureus* growth

- and subsequent enterotoxin production. *J Ethnopharmacol* 2005; **96**(1–2): 335-339.
- [14] Dkhil MA. Anti-coccidial, anthelmintic and antioxidant activities of pomegranate (*Punica granatum*) peel extract. *Parasitol Res* 2013; **112**(7): 2639-2646.
- [15] Khan AJ, Hanees S. Antibacterial properties of *Punica granatum* peels. *Int J Appl Biol Pharm Technol* 2011; **2**(3): 23-27.
- [16] Kadi H, Moussaoui A, Benmehdi H, Lazouni HA, Benayahia A, Nahal boudberba N. Antibacterial activity of ethanolic and aqueous extracts of *Punica granatum* L. bark. *J Appl Pharm Sci* 2011; **01**(10): 180-182.
- [17] Cerda B, Llorach R, Ceron J, Espin JC, Tomas-Barberan FA. Evaluation of the bioavailability and metabolism in the rat of punicalagin, an antioxidant polyphenol from pomegranate juice. *Eur J Nutr* 2003; **42**(1): 18-28.
- [18] Gracious RR, Selvasubramanian S, Jayasundar S. Immunomodulatory activity of *Punica granatum* in rabbits—a preliminary study. *J Ethnopharmacol* 2001; **78**(1): 85-87.
- [19] Amri M, Ait Aissa S, Belguendouz H, Mezioug D, Touil-Boukoffa C. *In vitro* antihydatic action of IFN- γ is dependent on the nitric oxide pathway. *J Interf cytok Res* 2007; **27**(9): 781-787.
- [20] Moreno MJ, Urrea-Paris MA, Casado N, Rodriguez-Cabeiro F. Praziquantel and albendazole in the combined treatment of experimental hydatid disease. *Parasitol Res* 2001; **87**(3): 235-238.
- [21] Adinolfi LE, Utili R, Andreana A, Tripodi M-F, Marracino M, Gambardella M, et al. Serum HCV RNA levels correlate with histological liver damage and concur with steatosis in progression of chronic hepatitis C. *Dig Dis Sci* 2001; **46**(8): 1677-1683.
- [22] Mekonnen GA, Ijzer J, Nederbragt H. Tenascin-C in chronic canine hepatitis: immunohistochemical localization and correlation with necro-inflammatory activity, fibrotic stage, and expression of alpha-smooth muscle actin, cytokeratin 7, and CD3⁺ cells. *Vet Pathol* 2007; **44**(6): 803-813.
- [23] Brissot P, Bourel M, Herry D, Verger JP, Messner M, Beaumont C, et al. Assessment of liver iron content in 271 patients: a re-evaluation of direct and indirect methods. *Gastroenterol* 1981; **80**(3): 557-565.
- [24] Beschin A, De Baetselier P, Van Ginderachter JA. Contribution of myeloid cell subsets to liver fibrosis in parasite infection. *J Pathol* 2013; **229**(2): 186-197.
- [25] Baqer NN, Khuder MH, Amer N. Antiprotoscolices effects of ethanolic extract of *Zingiber officinale* against *Echinococcus granulosus* *in vitro* and *in vivo*. *Int J Adv Res* 2014; **2**(10): 59-68.
- [26] Paksoy Y, Odev K, Sahin M, Arslan A, Koç O. Percutaneous treatment of hydatid cysts: comparison of direct injection of albendazole and hypertonic saline solution. *AJR Am J Roentgenol* 2005; **185**(3): 727-734.
- [27] Nunnari G, Pinzone MR, Gruttadauria S, Celesia MB, Madeddu G, Malaguarbera G, et al. Hepatic echinococcosis: clinical and therapeutic aspects. *World J Gastroenterol* 2012; **18**(13): 1448-1458.
- [28] Moazeni M, Nacer A. *In vitro* effectiveness of garlic (*Allium sativum*) extract on scolices of hydatid cyst. *World J Surg* 2010; **34**(11): 2677-2681.
- [29] Whittaker SG, Faustman EM. Effects of benzimidazole analogs on cultures of differentiating rodent embryonic cells. *Toxicol Appl Pharmacol* 1992; **113**(1): 144-151.
- [30] Vidal A, Fallarero A, Pena BR, Medina ME, Gra B, Rivera F, et al. Studies on the toxicity of *Punica granatum* L. (Punicaceae) whole fruit extracts. *J Ethnopharmacol* 2003; **89**(2–3): 295-300.
- [31] Patel C, Dadhaniya P, Hingorani L, Soni MG. Safety assessment of pomegranate fruit extract: acute and subchronic toxicity studies. *Food Chem Toxicol* 2008; **46**(8): 2728-2735.
- [32] Ashoush IS, El-Batawy OI, El-Shourbagy GA. Antioxidant activity and hepatoprotective effect of pomegranate peel and whey powders in rats. *Ann Agr Sci* 2012; **58**(1): 27-32.
- [33] Bouazza A, Bitam A, Amiali M, Bounihi A, Yargui L, Koceir EA. Effect of fruit vinegars on liver damage and oxidative stress in high-fat-fed rats. *Pharm Biol* 2015; **8**: 1-6.
- [34] Hiraganahalli BD, Chinampuder VC, Dethe S, Mundkinaieddu D, Pandre MK, Blachandran J, et al. Hepatoprotective and antioxidant activity of standardized herbal extracts. *Pharmacogn Mag* 2012; **8**(30): 116-123.
- [35] Murthy KNC, Jayaprakasha GK, Singh RP. Studies on antioxidant activity of pomegranate (*Punica granatum*) peel extract using *in vivo* models. *J Agric Food Chem* 2002; **50**(17): 4791-4795.
- [36] Elfalleh W, Hannachi H, Tlili N, Yahia Y, Nasri N, Ferchichi A. Total phenolic contents and antioxidant activities of pomegranate peel, seed, leaf and flower. *J Med Plants Res* 2012; **6**(32): 4724-4730.
- [37] Hou DX, Ose T, Lin S, Harazoro K, Imamura I, Kubo M, et al. Anthocyanidins induce apoptosis in human promyelocytic leukemia cells: structure-activity relationship and mechanisms involved. *Int J Oncol* 2003; **23**(3): 705-712.
- [38] Afaq F, Malik A, Syed D, Maes D, Matsui MS, Mukhtar H. Pomegranate fruit extract modulates UV-B-mediated phosphorylation of mitogen-activated protein kinases and activation of nuclear factor kappa B in normal human epidermal keratinocytes paragon sign. *Photochem Photobiol* 2005; **81**(1): 38-45.
- [39] Rosillo MA, Sánchez-Hidalgo M, Cárdeno A, Aparicio-Soto M, Sánchez-Fidalgo S, Villegas I, et al. Dietary supplementation of an ellagic acid-enriched pomegranate extract attenuates chronic colonic inflammation in rats. *Pharmacol Res* 2012; **66**(3): 235-242.
- [40] Ait Aissa S, Amri M, Bouteldja R, Weitzerbin J, Touil-Boukoffa C. Alterations in interferon-gamma and nitric oxide levels in human echinococcosis. *Cell Mol Biol* 2006; **52**(1): 65-70.
- [41] Bogdan C. Nitric oxide and the immune response. *Nat Immunol* 2001; **2**(10): 907-916.
- [42] Cheshire JL, Baldwin AS. Synergistic activation of NF-kappa B by tumor necrosis factor alpha and gamma interferon via enhanced kappa B alpha degradation and de novo I kappa B beta degradation. *Mol Cell Biol* 1997; **17**(11): 6746-6754.
- [43] Mahmoudvand H, Asadi A, Harandi MF, Sharififar F, Jahanbakhsh S, Dezaki ES. *In vitro* lethal effects of various extracts of *Nigella sativa* seed on hydatid cyst protoscolices. *Iran J Basic Med Sci* 2014; **1**(4): 1-6.