



Contents lists available at ScienceDirect

Asian Pacific Journal of Tropical Medicine

journal homepage: www.elsevier.com/locate/apjtm



Document heading doi: 10.1016/S1995-7645(14)60023-7

## Hepatic cystic echinococcosis: Percutaneous treatment as an outpatient procedure

Mert Köroğlu<sup>1,\*</sup>, Bekir Erol<sup>1</sup>, Cemil Gürses<sup>1</sup>, Barış Türkbey<sup>2</sup>, Cem Yunus Baş<sup>1</sup>, Ahmet Şükrü Alparslan<sup>1</sup>, Banu Kale Köroğlu<sup>3</sup>, İclal Erdem Toslak<sup>1</sup>, Bülent Çekiç<sup>1</sup>, Okan Akhan<sup>2</sup>

<sup>1</sup>Clinic of Radiology, Antalya Education and Research Hospital, Antalya, Turkey

<sup>2</sup>Hacettepe University Faculty of Medicine, Department of Radiology, Ankara, Turkey

<sup>3</sup>Süleyman Demirel University Faculty of Medicine, Department of Internal Medicine, Isparta, Turkey

### ARTICLE INFO

#### Article history:

Received 10 September 2013

Received in revised form 15 October 2013

Accepted 15 December 2013

Available online 20 March 2014

#### Keywords:

Liver

Hydatid cyst

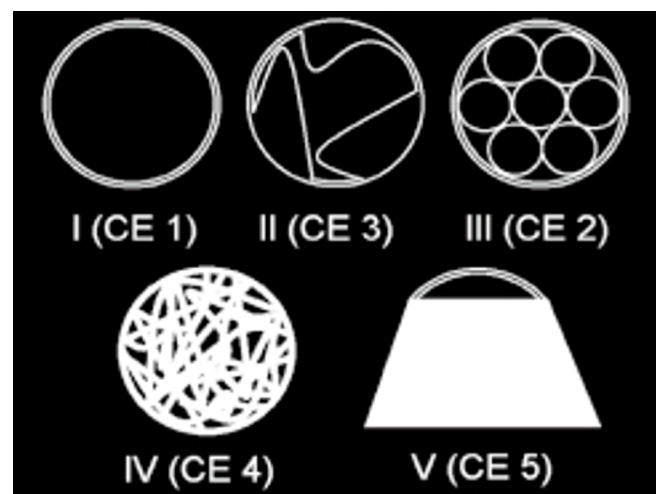
Percutaneous treatment

### ABSTRACT

**Objective:** To demonstrate utility and safety of the puncture aspiration injection and reaspiration (PAIR) technique for outpatients. **Methods:** Percutaneous treatment with US guidance was applied to 33 patients for 44 cysts. Patients treated with the PAIR technique, were outpatients. PAIR and catheterization technique were evaluated for efficacy and safety of procedure and complication rates. **Results:** Thirty-five of 44 cysts were treated with the PAIR and 9 of 44 were treated with the catheterization technique. The success rate of the cysts Gharbi type 1 (CE1) and type 2 (CE3a) treated with the PAIR technique was 100%. In the follow up of 9 cysts treated with the catheterization technique, 2 of them (22%) developed cyst infection and 1 (11%) developed a biliary fistula. **Conclusions:** The PAIR technique was found to be an effective and safe approach in order to treat Gharbi type 1 and type 2 cysts percutaneously for outpatients. It has a very low complication rate in comparison with the catheterization technique. So every effort should be made to finish the treatment with PAIR technique.

## 1. Introduction

Hepatic hydatid disease is a parasitic infection caused by *Echinococcus granulosus* (Figure 1). It is a public health problem in developing countries. The most common location of infection in human is the liver [1,2]. The manifestation of the disease can range from totally asymptomatic to anaphylaxis due to cyst rupture. The percutaneous approach in the treatment became a promising method to avoid complications caused by surgery and longer hospitalisation times [3,4]. Our purpose is to demonstrate the utility and the safety of the PAIR technique in hydatid disease patients at an outpatient basis.



**Figure 1.** Classification of hydatid cysts according to Gharbi and The World Health Organization. 59 mm×47 mm (300×300 DPI).

\*Corresponding author: Mert Köroğlu, MD, Antalya Eğitim ve Araştırma Hastanesi, Radyoloji Kliniği, Varlık Mah. Kazım Karabekir Cad., 07100 Antalya, Turkey.  
Tel.: +90 545 413 10 73  
Fax: +90 242 249 44 62.  
E-mail: mertkoroglu@hotmail.com

## 2. Material and methods

### 2.1. Patient information

Within a 5 year period, between 2005 and 2010, 33 consecutive patients (26 female and 7 male) were included in our study. The mean age was 41.8 (13–77) years old. In 6 patients there were multiple cysts in the pre-interventional ultrasonography examination. Forty-four cysts were planned for the intervention in 33 patients.

### 2.2. Treatment procedures

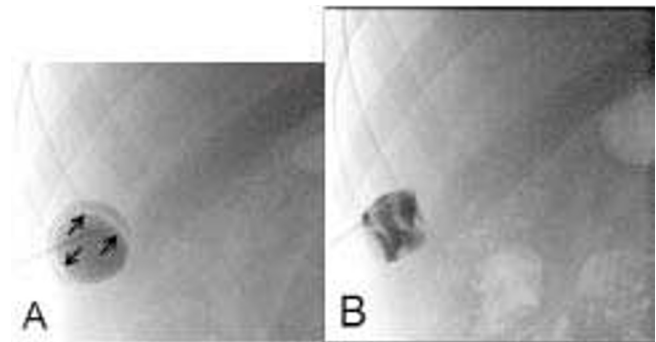
Puncture, aspiration injection re-aspiration (PAIR) technique and the catheterization techniques were performed percutaneously. In the PAIR technique, the cyst was punctured with 18 G Seldinger needle under US guidance. Using the color Doppler US the vessels in the entry side for the intervention were carefully detected in order to avoid them. In the first entry, 90% of the cyst content was aspirated with the needle. Then radiopaque material (ionic, meglumine and sodium–ioxytalamate, 350 mg/mL; Telebrix–35®, Guerbet, Cedex, France) as much as 10%–20% of the cyst volume was given. Then 30% hypertonic saline infusion with an amount of the 60%–70% of the former cyst volume was given. After 15 min the cyst liquid was re-aspirated (Figure 2). Then again with fluoroscopy guidance the radiopaque material as much as 10%–20% of the cyst volume was given to make sure that there was no leakage outside from the cyst to the peritoneum and to the biliary tract. This is followed by injection of 96% ethanol with a volume of 60%–70% of the cyst volume for sclerosing and scolicedal purposes. Ethanol was aspirated after 15 min. All hypertonic saline and ethanol injections were done under fluoroscopic control. The most important disadvantage of the PAIR technique is that the injected hypertonic saline and alcohol cannot be aspirated due to the separating membranes in some patients. In these patients, when necessary, with real-time US guidance the rest fluid was completely aspirated. One important point was that the separating membranes of the cyst could plug the 18 G Seldinger needle in a check valve manner and to overcome this problem the 20 G needle was advanced into cyst through 18 G needle coaxially and the liquid was aspirated under US guidance. Sometimes the first needle was connected to a line for free drainage, this also can help to overcome check valve manner blockage of the needle. If needed second or third needle (mostly 21 G) was inserted into the cyst cavity with another puncture. While performing these manures the first needle was always kept in place to avoid leakage. Therefore almost all cysts were aspirated fully or almost fully with success.

If a cysto–biliary fistula is detected or if the cyst fluid could not be evacuated despite all these measures,

catheterization technique is used. In the catheterization technique, 30% hypertonic saline injection was made in to the cyst cavity under US and fluoroscopic guidance. After waiting for 15 min and aspiration, a 8 French pigtail catheter (Flexima, Boston Scientific, USA) was inserted into the cyst cavity and this stayed there for 24 h for the drainage (Figure 3). Then cystography was performed in order to detect a possible fistula between the cyst cavity and biliary tract. In the patients with no fistula 95% ethanol with an amount of the half of the former cyst volume was given into the cyst cavity. To maximize the sclerosing and scolicedal effect of the ethanol, it was applied for 15 min. In patients with fistula between the biliary tract and the cyst cavity, the ethanol was not used in order to avoid the risk of sclerosing the bile ducts.

Samples from the cyst content were used for the cytological and microbiological tests. In all patients the diagnosis of the hydatid disease was confirmed by the direct microscopic analysis, high pressure content coming during the intervention, double layer in the ultrasonography, presence of separating membranes or daughter cysts.

The prophylactic albendazol therapy (Andazol 200 mg tb 2 ×2) minimum 10 d before and 30 d after the in intervention was given to all patients.



**Figure 2.** 29 year old man with percutaneously treated Gharbi type 1 hepatic hydatid cyst.

Cystogram obtained 4–5 min after injection of hypertonic saline solution reveals endocyst separated (arrows) from pericyst (A). After 15 minutes the cyst liquid was re-aspirated (B). 40 mm×36 mm (300×300 DPI).

After 15 min the cyst liquid was re-aspirated (B). 43 mm×43 mm (300×300 DPI).

## 3. Results

Forty-four cysts in 33 patients were treated. Thirty-five of 44 cysts were treated with the PAIR technique while remaining 9 of them were treated with the catheterization technique. The PAIR and the catheterization technique were applied in all the patients with a technical success rate of 100%. According to the Gharbi classification 22

cysts were Gharbi type 1 (CE1), 16 cysts were Gharbi type 2 (CE3a) and 6 cysts were Gharbi type 3 (CE2). Twenty Gharbi type 1 (CE1) cysts were treated with the PAIR technique, whereas remaining 2 Gharbi type 1 cysts were treated with the catheterization technique. Four Gharbi type 2 (CE3a) cysts were treated with the catheterization technique and 12 Gharbi type 2 (CE3a) cysts were treated with the PAIR technique. Three Gharbi type 3 (CE2) cysts were treated with the catheterization and the remaining 3 Gharbi type 3 (CE2) cysts were treated with the PAIR technique. The need for the catheterization increased as we go further from the type 1 to type 3 because of the problems such as the relation of the cysts with the biliary tract and since sometimes the given liquids could not be aspirated.

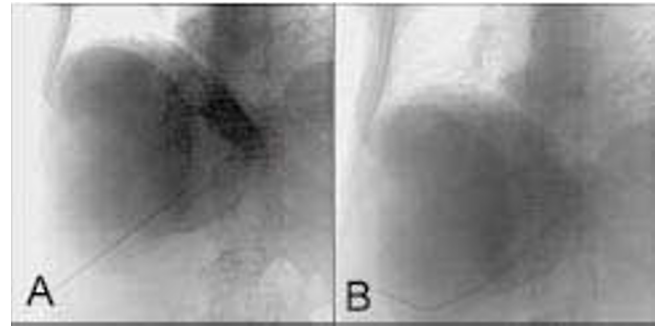The mean cyst volume before the intervention was 413.7 (10–3 300) mL. It became 59.2 (2–500) mL after intervention. Mean volumes of the cysts treated with the catheterization technique were 1 501.6 (450–3 300) mL and 226.6 (40–500) mL before and after intervention, respectively. Mean volumes of cysts treated with the PAIR technique were 113.9 (10–528) mL and 16.1 (2–60) mL before and after intervention, respectively. The mean volume of cysts was reduced to 14%–15% of their initial volume. These percentages were 11%–12% and 15%–16% for cysts treated with the PAIR technique and the catheterization technique, respectively.

The mean follow up time was 48.1 (9–104) month. The patients who were treated with the PAIR technique needed no hospitalization at all. The hospitalization period for the patients treated with the catheterization technique was 27.3 (12–48) days at average. In one patient treated with catheterization technique we found a growing cyst and this patient was treated with re-catheterization.

The success rate of the patients with the cysts of Gharbi type 1(CE1) and 2 (CE3a) treated with the PAIR technique was 100%. One of the 3 Gharbi type 3 cysts (CE2) treated with the PAIR technique had a recurrence. In all patients treated with the PAIR technique there was no other major complications such as abdominal dissemination, cyst infection, abscess or bleeding in the cyst. Nine patients with cysts type of 1, 2 and 3 were treated with the catheterization technique. In 3 of them (33.3%) there were complications. Two patients (22.0%) had cyst infections and in one patient (11.0%) biliary fistula developed. Among 2 patients with cyst infections one patient had type 1 (CE1) and the other had type 3 (CE2) cysts. One patient with the biliary fistula had Gharbi type 3 cyst (CE2). Only one patient (2.8%) from the PAIR group with 35 cysts had the recurrence. In this patient with the recurrence, cyst was Gharbi type 3 (CE 2). There was no other complication.

Ultrasonography was used pre and post interventionaly to assess and to follow up the patients. No MRI or CT was

needed.



**Figure 3.** 82 year old women with percutaneously treated giant hepatic hydatid cyst (A). This patient was treated with catheterization (B). 43 mm×43 mm (300×300 DPI). This patient was treated with catheterization (B). 43 mm×43 mm (300 ×300 DPI).

#### 4. Discussion

The main goal of the hydatid disease treatment is to relieve the symptoms and to avoid the complications such as infections, obstructive jaundice and anaphylactic shock all of which can be caused by the cyst rupture. The most commonly affected organ in the hydatid disease is the liver but many other organs can also be affected. Nowadays the treatment approaches of hydatid disease can be surgical, percutaneous or medical[5,6].

The surgical approach has been the gold standard therapy for the hydatid disease for long years[5]. However, the location and smaller volumes of some cysts make the surgical approach unfeasible. Moreover, cysto–biliary fistula is the most common complication of the hydatid disease affecting the liver[7] and formerly the surgical approach was preferred in the presence of a fistula which is a result of a cyst rupture to the biliary tree. But nowadays the percutaneous approach is possible for such conditions[6]. The medical therapy is not effective in most cases. However it is used in pre–and post surgically and interventionaly, for theoretical risk of the abdominal dissemination in order to keep them under the secondary prophylaxis[8–10].

Developing minimal invasive techniques has ensured the percutaneous treatment of the hydatid disease without need for surgery. The PAIR and catheterization techniques were used for the percutaneous therapy[11,12]. The percutaneous therapy has low complication rates of 13.3% for minor and 5% for major complications. Especially in the cysts of type 1 (CE1) and 2 (CE3a) the PAIR technique was found effective and safe in long term in the treatment for the hydatid cyst disease. In the cysts of type 3 (CE2) the success rate was somewhat lower (39%) (13). In our study, especially in the cysts of type 1 (CE1) and 2 (CE3a) the success rate with the PAIR technique was 100%. On the other hand there was only one case (2.8%) of recurrence in a cyst of Gharbi type 3 (CE2). In a study investigating the Double Puncture–

Aspiration–Injection technique, the morbidity rate was 8.6% and the mortality rate was 0.9%. One patient in that study had anaphylactic shock. As major complication (2.5%) one patient had intra–cystic bleeding and in two cysts liver abscess developed. In one patient a biliary fistula was found. The average hospitalization time in that study was 2.9 days (2–7 days)[4]. In our study the PAIR approach was performed for outpatients and there was neither intra–cyst bleeding nor infection or biliary fistula. Only one patient had recurrence and this patient was treated successfully eventually.

In the type 3 (CE2) cysts and with the catheterization technique the irrigation was made with saline and betadine (10% povidone iodine; 1% free iodine) on daily basis. There was no recurrence[14]. In our study there was no recurrence with the catheterization technique. However the complication rate of the catheterization technique (33.3%) was more than that of the PAIR technique. In comparison with the catheterization technique, the PAIR technique has the advantage of no need for hospitalization and having the patients treated as outpatients. Moreover, it is less invasive than the catheterization technique. When the duration of the catheterization gets longer, the risks of catheter tract and the cyst infection increase. Additionally, during and after such an intervention, risk of developing hematoma and bleeding is higher and the duration of the hospitalization increases if the catheter is used. All these reasons make us to conclude that the overall comfort of the patients treated with the PAIR technique is better than those treated with the catheterization technique. In our study in one patient (2.8%) treated with the PAIR technique there was a recurrence in the follow up. Two patients (22.0%) treated with the catheterization technique had cyst infection and one patient (11.0%) treated with the catheterization technique got biliary fistula. The most important disadvantage of the PAIR technique was that the hypertonic saline infusion and the injected alcohol cannot be aspirated due to separating membranes. This may result in a change to the catheterization technique. But before changing into catheterization technique every effort should be made to finish the treatment with PAIR technique.

Our study had few limitations worth to mention. First, we had a relatively small patient population and the patient populations for PAIR and catheterization groups were not matching one to one. However, it is quite difficult to run a one to one matching trial in such a clinical entity. Secondly, our follow up time is not long, but our group is trying to accumulate more patients with longer follow up duration.

As a conclusion, to the best of our knowledge, this is the first study confirming that the hydatid disease can be treated minimal invasively with the PAIR technique without need for hospitalization. The PAIR technique is effective and safe with lower complication rates. So every effort should be made to finish the treatment with PAIR technique. Especially in Gharbi type 1 (CE1) and type 2 (CE3a) cysts the success rate is higher with the PAIR technique and such patients can be treated as outpatients.

## Conflict of interest statement

We wish to confirm that there are no known conflicts of interest associated with this publication and there has been no significant financial support for this work that could have influenced its outcome.

## References

- [1] Rozanes I, Güven K, Acunaş B, Emre A. Cystic echinococcal liver disease: new insights into an old disease and an algorithm for therapy planning. *Cardiovasc Intervent Radiol* 2007; **30**: 1112–1116.
- [2] Brunetti E, Kern P, Vuitton DA. Writing Panel for the WHO–IWGE. Expert consensus for the diagnosis and treatment of cystic and alveolar echinococcosis in humans. *Acta Trop* 2010; **114**: 1–16.
- [3] Sinha R, Sharma N. Abdominal hydatids: a minimally invasive approach. *JLS* 2001; (5): 237–240.
- [4] Giorgio A, de Stefano G, Esposito V, Liorre G, Di Sarno A, Giorgio V, et al. Long–term results of percutaneous treatment of hydatid liver cysts: a single center 17 years experience. *Infection* 2008; **36**: 256–261.
- [5] Yageci G, Ustunsoz B, Kaymakcioglu N, Bozlar U, Gorgulu S, Simsek A, et al. Results of surgical, laparoscopic, and percutaneous treatment for hydatid disease of the liver: 10 years experience with 355 patients. *World J Surg* 2005; **29**: 1670–1679.
- [6] Canyigit M, Gumus M, Cay N, Erol B, Karaoglanoglu M, Akhan O. Refractory cystobiliary fistula secondary to percutaneous treatment of hydatid cyst: treatment with N–butyl 2–cyanoacrylate embolization. *Cardiovasc Intervent Radiol* 2011; **34**(Suppl 2): 266–270.
- [7] Manouras A, Genetzakis M, Antonakis PT, Lagoudianakis E, Pattas M, Papadima A, et al. Endoscopic management of a relapsing hepatic hydatid cyst with intrabiliary rupture: a case report and review of the literature. *Can J Gastroenterol* 2007; **21**: 249–253.
- [8] Akhan O, Ozmen MN. Percutaneous treatment of liver hydatid cysts. *Eur J Radiol* 1999; **32**: 76–85.
- [9] Akhan O, Ozmen MN, Dinçer A, Sayek I, Göçmen A. Liver hydatid disease: long–term results of percutaneous treatment. *Radiology* 1996; **198**: 259–264.
- [10] Akhan O, Dincer A, Gököz A, Sayek I, Havlioglu S, Abbasoglu O, et al. Percutaneous treatment of abdominal hydatid cysts with hypertonic saline and alcohol. An experimental study in sheep. *Invest Radiol* 1993; **28**: 121–127.
- [11] Akhan O, Gumus B, Akinci D, Karcaaltincaba M, Ozmen M. Diagnosis and percutaneous treatment of soft–tissue hydatid cysts. *Cardiovasc Intervent Radiol* 2007; **30**: 419–425.
- [12] Giorgio A, Di Sarno A, de Stefano G, Liorre G, Farella N, Scognamiglio U, et al. Percutaneous treatment of hydatid liver cyst. *Recent Pat Antiinfect Drug Discov* 2009; **4**: 29–36.
- [13] Kabaalioglu A, Ceken K, Alimoglu E, Apaydin A. Percutaneous imaging–guided treatment of hydatid liver cysts: do long–term results make it a first choice? *Eur J Radiol* 2006; **59**: 65–73.
- [14] Bosanac ZB, Lisanin L. Percutaneous drainage of hydatid cyst in the liver as a primary treatment: review of 52 consecutive cases with long–term follow–up. *Clin Radiol* 2000; **55**: 839–848.