




Contents lists available at ScienceDirect

Asian Pacific Journal of Tropical Medicine

journal homepage: www.elsevier.com/locate/apjtm



Document heading doi:

Anti–arthritis activity of roots of *Hemidesmus indicus* R.Br. (Anantmul) in rats

Alka Mehta^{1*}, Neeraj K Sethiya¹, Chetan Mehta², GB Shah³¹Pharmacy Department, Faculty of Technology and Engineering Kalabhavan, The M. S. University of Baroda, Vadodara 390002 (Gujarat), India²Radiology Department, SSG Hospital and Medical College, Vadodara–390001 (Gujarat), India³KBIPER, Gandhinagar– 382023 (Gujarat), India

ARTICLE INFO

Article history:

Received 23 July 2011

Received in revised form 15 September 2011

Accepted 15 November 2011

Available online 20 February 2012

Keywords:

Arthritic Index

Hemidesmus indicus

Anti–inflammatory

Phenolic

Terpenoids

ABSTRACT

Objective: To investigate the protective effects of hydroalcoholic and its fractions from roots of *Hemidesmus indicus* on arthritis in *in vitro* models of rodents. **Methods:** Preliminary phytochemical analysis and thin–layer chromatography were performed to analyze constituents of hydroalcoholic extract and its three fraction namely ethyl acetate fraction, chloroform fraction and residual fraction of root of *Hemidesmus indicus*. Arthritis rats models were established by Complete Freund's Adjuvant. The parameters including paw edema, body weight, arthritic index, erythrocyte sedimentation rate, serum rheumatoid factor, serum C–reactive protein, serum nitrite level, and histopathology of synovial joints were observed. Methotrexate was taken as positive control. **Results:** Rats treated with hydroalcoholic extract (450 mg/kg, *p.o.*), ethyl acetate (75 mg/kg, *p.o.*), chloroform (60 mg/kg, *p.o.*) and residual fractions (270 mg/kg, *p.o.*), showed significant decrease in physical and biochemical parameters compared with arthritic model rats. Hydroalcoholic extract and its ethyl acetate fraction of *Hemidesmus indicus* showed significantly higher anti–arthritic activity than chloroform and residual fraction. Histopathological analysis demonstrated that both of hydroalcoholic extract and its ethyl acetate fraction had comparable anti–arthritic activity with methotrexates. **Conclusions:** The present study suggests that *Hemidesmus indicus* has protective activity against arthritis and the activity might be attributed to presence of terpenoid in hydroalcoholic extract, as well as in ethyl acetate fraction.

1. Introduction

Indian Sarsaparilla or Anantmula (*Hemidesmus indicus*; family–Asclepiadaceae) is a species of plant in South Asia^[1]. The word “Sarsi” is derived from the name of this herb and synonymous with root beer. *Hemidesmus indicus* is widely used in Indian medicine systems and also an official drug in Indian pharmacopoeia and British pharmacopoeia. It is a slender, laticiferous, twining, sometimes prostrate or semi–erect shrub. The plant is regarded as tonic, alternative, demulcent, diaphoretic, diuretic and blood purifier. It is employed in nutritional disorders, syphilis, chronic rheumatism, gravel and other urinary diseases and skin infection. It is administered in the form of powder

and infusion or decoction. It is also a component of several medicinal preparations^[1]. Various activities of *Hemidesmus indicus*, such as hypoglycemic, hypolipidemic, antioxidant, antithrombotic, antiinflammatory, antiulcerogenic, hepatoprotective, renoprotective and neutralization of viper venom have been reported. It was reported to contain saponins, tannins, hemidesmine, hemidesmol, hemidesterol, stearoptin, pregnane glycosides, β –sitosterol, indicusin, coumarin, volatile oils, triterpenes, flavonoids, and so forth^[2–10].

Rheumatoid arthritis is a systemic autoimmune disease that causes chronic inflammation of connective tissue primarily in the joints that involves synovial proliferation and cartilage destruction. The first joint tissue to be affected is synovial membrane which lays the joint cavity^[11]. Researchers have found many new mediators *viz.*, TNF– α , IL–1 and enzymes which take part directly or indirectly in perpetuation of RA^[12–14]. Previous reports indicated that hydroalcoholic extract of root of *Hemidesmus indicus* R.Br. inhibits the *in vitro* interaction between NF– κ B & DNA^[15]. The present study investigated the protective effect of

*Corresponding author: Alka Mehta, Teaching Assistant, Pharmacy Department, Faculty of Technology and Engineering, Kalabhavan, The Maharaja Sayajirao University of Baroda, Vadodara –390001, Gujarat, India.

Tel: +91–265–2794051

Fax: +91–265–2423898

E–mail: alkamehta5555@yahoo.com; nscognoy2006@gmail.com

hydroalcoholic extract and three fractions *viz*, ethyl acetate fraction, chloroform fraction and residual fraction of *Hemidesmus indicus*, on *in vitro* arthritis models of rodents.

2. Materials and methods

2.1. Plant material and preparation of extract

Roots of plant *Hemidesmus indicus* was collected from the botanical garden, Botany Department, in January, 2009. This was identified by the respective department, MS University of Baroda, India. A voucher specimen has been deposited in the herbarium of the institute (Voucher specimen no. PH/509/007). Roots were shade dried and ground into a coarse powder. A total of 100 g powdered material was extracted with mixture of 80% ethanol:20% water by cold maceration (yield 8% w/w). The extract was suspended in tween-80 (0.1% v/v) to get the suspension for administration to rats^[16].

2.2. Drugs and chemicals

Methotrexate was obtained as gift sample from Intas Pharmaceuticals, India and Complete Freund's adjuvant (CFA) was purchased from Sigma Aldrich, St.Louis, USA.

2.3. Animal

Female Wistar rats weighing 200 to 300 g were selected for the present study. The animals were housed in 7 groups in polypropylene cages, consisting of 6 in each, under standard laboratory conditions, temperature (25±2)°C, lighting 08:00–20:00 and relative humidity (50±5)%. The animals had free access to standard pellet chow (Brooke Bond–Lipton, India) and water. The animals were acclimatized for a period of minimum 7 days and daily observed between 09:00 and 14:00. All the experiments have been carried out after 7 days of acclimatization and were conducted between 09:00 and 14:00^[17]. Animal experimentation procedures were approved by Institutional Animal Ethics Committee and care of laboratory animals was taken as per CPCSEA guidelines (Reg. No. KBIPER/08/124).

2.4. Bioguided fractionation

A total of 100 g powdered material was extracted with mixture of 80% ethanol:20% water by cold maceration (yield 8% w/w) for the preparation of hydroalcoholic extract (8% w/w). This was further fractionated to get the chloroform fraction (16.66% w/w). The marc obtained was again fractionated with ethyl acetate to get the ethyl acetate fraction and residual marc. These were further used in the studies based on chemical distribution to achieve bioactivity.

2.5. Characterization of extract and chromatographic analysis

The hydroalcoholic extract of *Hemidesmus indicus* showed positive results in Salkowski and Liebermann Burchard tests

for presence of triterpene and sterol. It was also positive in FeCl₃ test for presence of phenolic and tannin. Precoated and preactivated thin-layer chromatography plates (E. Merck No. 5548) of silica gel 60 F₂₅₄₊₃₆₆ with the support of aluminium sheets 0.1 mm thick and 10 cm ×10 cm were used for the chromatographic characterizations of the extract and its various fractions. A total of 10 mg of extract was weighed accurately and dissolved with 10 mL of methanol^[18]. The mobile phase used was ethyl acetate:formic acid:acetic acid:ethyl methyl ketone:water=50:7:3:30:10. Fractions I–III (10 mg) was also dissolved in methanol (10 mL). These were analyzed in the same manner as described above. FBS reagent (for flavanoids/phenolic) and anisaldehyde in sulfuric acid (for steroidal) was used as detecting agent.

2.6. Toxicity studies of the plant extract

Evaluation of acute oral toxicity of *Hemidesmus indicus* was carried out according to the OECD guidelines for testing of chemicals. A limit test (2 000 mg/kg) was performed using 5 male Wistar rats (150–180 g). All the animals were observed for behavioral changes and mortality till 14 days after administration of the extract^[17].

2.7. CFA induced arthritis

Adjuvant arthritis in rats exhibited many similarities to human rheumatoid arthritis^[19]. Injections of CFA into the rat paw induced inflammation as primary lesion maximum after 3 to 5 days. Secondary lesions occurred after a delay of approximately 11 to 12 days, characterized by inflammation of non-injected sites (hind leg, forepaws, ears, nose and tail), a decrease of weight and immune responses^[20]. On day 0, female wistar rats (200 to 300 g) had injection on the sub plantar region of the left hind paw with 0.2 mL of CFA. This consists of 10 mg *Mycobacterium butyricum* suspended in heavy paraffin oil by thoroughly grinding with mortar and pestle to give a concentration of 1 mg/mL. The animals were divided into 7 groups containing 6 animals in each group. Group I – normal control groups were given only the vehicle (0.2% v/v Tween 80 solution) in volume equivalent to that of the plant extracts/fractions. Group II – model control groups received 0.2 mL of CFA (1 mg/mL, sub-plantar), Group III – standard control received 0.2 mL CFA and a dose of methotrexate (0.25 mg/kg, *p.o.*, *o.i.d.*), Group IV – received hydroalcoholic extract of *Hemidesmus indicus* (450 mg/kg, *p.o.*, *o.i.d.*), Group V – received chloroform fraction of *Hemidesmus indicus* (75 mg/kg, *p.o.*, *o.i.d.*), Group VI – received ethyl acetate fraction of *Hemidesmus indicus* (60 mg/kg, *p.o.*, *o.i.d.*) and lastly Group VII – received residue fraction of *Hemidesmus indicus* (270 mg/kg, *p.o.*, *o.i.d.*). Administration of extracts or the standard started on the same day and continued for 12 days. From day 13 to 21, the administration was stopped. On day 21, the severity of the secondary lesions was evaluated by the following parameters, *viz*. paw edema, body weight, arthritic index (AI), erythrocyte sedimentation rate (ESR), serum rheumatoid factor (SRF), serum C-reactive protein (SCRp), serum nitrite level and histopathology of synovial joints. The percent inhibition of

paw volume of vehicle control rats was measured at day 5 for primary lesions and at day 21 for secondary lesions[21].

Paw volumes of both hind limbs were recorded before injection of CFA, using mercury plethysmometer. The paw volume of the both the hind limbs were again measured on 5th, 12th, and 21st day[21,22]. Body weights of each animal were measured on the day of CFA administration, and later on day 21[21]. Arthritic index is the mean of the score /grade given to the severity of inflammation on the ears, nose, tail, fore paw and hind paw. All the animals were closely observed and scored. An arthritic index for each animal was calculated as the sum of these scores and compared with respective control group[21].

ESR was measured by Westergren's method. Sample of blood (about 3 mL) was obtained by puncturing retro-orbital plexus on 21st day and mixed with 3.8% sodium citrate solution in proportion of four parts of blood to one part of citrate solution. The mixing of blood was done by rotating the sample gently between the palms of hands. The blood was sucked slowly up to the mark zero in the Westergren's tube. The tube was set upright in the Westergren's stand, taking care that no blood escapes. The tube was fixed with the help of screw cap. At the end of one hour and two hours, the upper level of red blood cell column was read. It indicates mm of clear plasma per hour[21]. Serum rheumatoid factor estimation was done by turbidometry method[21]. C-reactive protein (CRP) was measured by turbidometry method[21].

2.8. Histopathology of synovial joint

Rats were sacrificed on 21 day; hind limbs were removed and fixed in 10% buffered formalin. The limbs were decalcified in 5% formic acid, processed for paraffin embedding, sectioned at 5 μ m thicknesses, and subsequently stained with haematoxylin-eosin for examination under a light microscope with 100 \times magnifications. Sections were examined for the presence of hyperplasia of the synovium, pannus formation and destruction of the joint space[20,21].

2.9. Statistical analysis

The results are expressed as the mean \pm SEM. The significant difference between the means (parametric) was evaluated by one-way ANOVA followed by Turkey post hoc multiple comparison test for normal data. $P < 0.05$ was considered as significant.

3. Results

3.1. Phytochemical screening and chromatographic characterization

Chromatographic fingerprinting of fractions of hydroalcoholic extract of root viz., ethyl acetate fraction, chloroform fraction and residual fraction revealed the presence of terpenoids in ethyl acetate fraction and residual

fraction, whereas chloroform fraction does not show any of terpenoid constituents. Ethyl acetate fraction and chloroform fraction showed presence of phenolic compounds in their extract. These results were further extrapolated with standard chromatogram of respective drug, in order to standardization of extract and fraction.

3.2. Toxicity profile of the test plant

Administration of *Hemidesmus indicus* (2 000 mg/kg) did not produce any behavioural abnormalities, but shows 20% mortality (One out of five animals). The mortality was observed 48 h after drug administration. As more than 50% of the tested animals survived, the oral LD₅₀ of *Hemidesmus indicus* in rats was found to be >2 000 mg/kg.

3.3. CFA Freund's adjuvant induced arthritis

Paw edema volume on 21st day was significantly lower in hydroalcoholic extract treated rat than CFA treated rats ($P < 0.05$). The volume of paw edema on 21st day was significantly ($P < 0.05$) lower in ethyl acetate fraction treated rats than chloroform fraction and residual fraction treated rats (Figure 1).

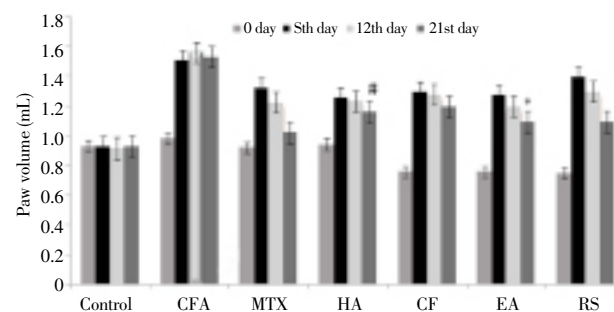


Figure 1. Effect of hydroalcoholic extract and its subfractions of *Hemidesmus indicus* root on paw edema volume.

MTX: Methotrexate; HA: Hydroalcoholic extract; CF: Chloroform fraction; EA: Ethyl acetate fraction; RS: Residual fraction. *: $P < 0.05$, significant different from CF&RS treated groups; #: $P < 0.05$, significant different from EA treated groups.

Body weight in CFA treated rats was significantly reduced compared to control ($P < 0.05$). The body weight reduction in hydroalcoholic extract, chloroform fraction, ethyl acetate fraction and residual fraction treated rats were significantly lesser than that of CFA treated rats. However, in ethyl acetate fraction treated rats, the body weight reduction was significantly lower than chloroform fraction and residual fraction treated rats (Table 1).

Arthritic score, ESR, serum rheumatoid factor, serum CRP and serum nitrite level were significantly increased in CFA treated rats compared with normal control group ($P < 0.05$). Except serum nitrite level, other indexes were significantly decreased in hydroalcoholic extract, chloroform fraction, ethyl acetate fraction and residual fraction treated rats ($P < 0.05$). And there were significant difference in ESR, rheumatoid factor and serum CRP between ethyl acetate fraction group and chloroform fraction/ residual fraction

group ($P<0.05$)(Table 2).

Serum nitrite level was significantly decreased in hydroalcoholic extract treated rats($P<0.05$) compared to CFA treated rats. And rats treated with hydroalcoholic extract showed lower serum nitrite level on 21st day as compared to methotrexate treated rats (Table 2).

3.4. Histopathology of synovial joint

Histology of normal control rats showed intact morphology of synovium and synovial lining of synovial joint. No inflammation, inflammatory cell proliferation and chondrocytes migration was observed (Figure 2A). CFA treated rats showed cartilage destruction, chondrocytes

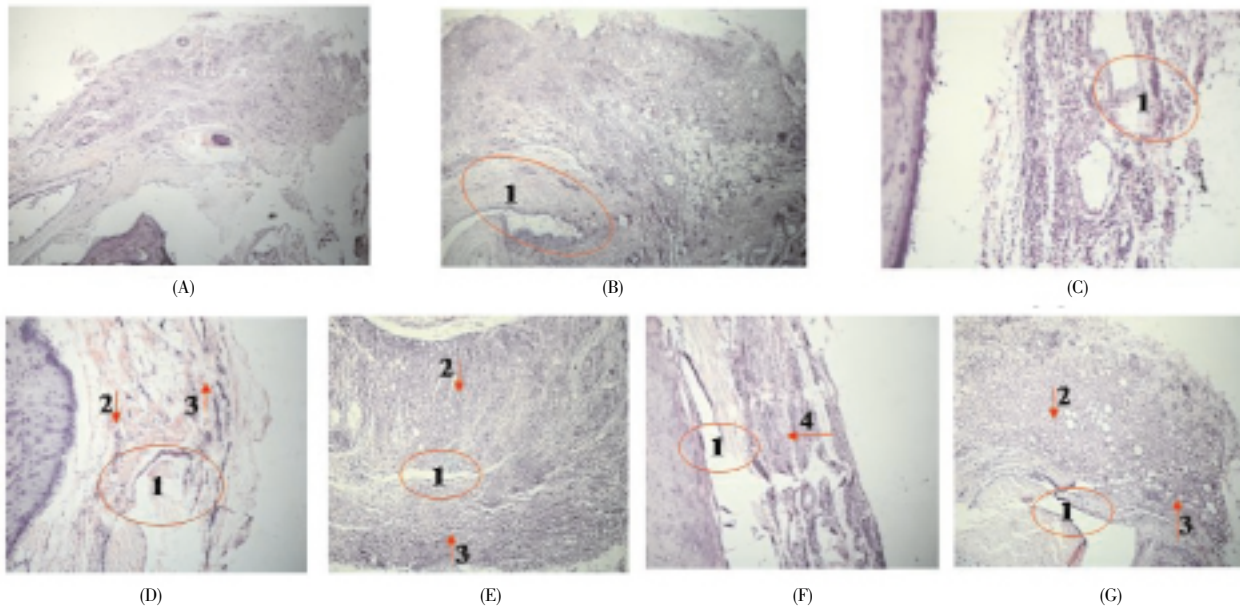


Figure 2. Histopathology of synovial joint.

(A) Normal control; (B) Model control; (C) Methotrexate treated; (D) Hydroalcoholic extract treated; (E) Chloroform fraction treated; (F) Ethyl acetate treated rats; (G) Residual fraction treated.

1: Cartilage destruction; 2: Chondrocytes migration; 3: Vascular proliferation; 4: Severe inflammation.

Table 1

Effect of hydroalcoholic extract and its subfractions of *Hemidesmus indicus* root on average body weight(Mean±SEM).

Treatments	Average body weight			
	0th Day	5th day	12th day	21st day
Control	288.66±9.06	288.33±8.99	285.50±9.20	284.50±9.56
CFA	262.16±7.61*	223.16±7.32*	218.50±4.35*	196.16±2.15*
Methotrexate	268.83±10.90 [#]	263.33±11.22 [#]	263.16±11.49 [#]	260.66±11.19 [#]
Hydroalcoholic extract	269.66±5.17 [#]	263.50±3.94 [#]	257.66±4.63 [#]	255.50±5.21 [#]
Chloroform fraction	262.16±7.61* [△]	225.16±8.02* [△]	221.66±3.12* [△]	199.00±1.31* [△]
Ethyl acetate fraction	260.00±11.25 [#]	233.66±9.29 [#]	230.00±8.92 [#]	221.33±7.07 [#]
Residual fraction	262.16±7.61 [△]	221.33±6.83 [△]	214.50±7.08 [△]	197.16±1.85 [△]

*: $P<0.05$ vs. control group, [#] $P<0.05$ vs. CFA treated group, [△] $P<0.05$ vs. ethyl acetate treated group.

Table 2

Effect of hydroalcoholic extract and its subfractions of *Hemidesmus indicus* root on arthritic index, ESR, serum rheumatoid factor, CRP and serum nitrite level(Mean±SEM).

Treatments	Arthritic index	ESR	Rheumatoid factor	CRP	Serum nitrite level
Control	0.00±0.00	1.33±0.23	9.20±0.82	0.89±0.23	1.95±1.96
CFA	3.66±0.23*	6.08±0.17*	28.83±4.39*	10.63±3.17*	4.50±4.06*
Methotrexate	1.33±0.23 [#]	2.25±0.12 [#]	12.50±1.24 [#]	1.68±0.73 [#]	3.10±2.50 [#]
Hydroalcoholic extract	1.60±0.18 [#]	3.60±0.23 [#]	19.30±2.27 [#]	5.30±0.50 [#]	2.40±1.78 [#]
Chloroform fraction	2.00±0.00 [#]	3.80±0.17 ^{#△}	21.60±1.08 ^{#△}	5.06±0.08 ^{#△}	1.98±0.12
Ethyl acetate fraction	1.80±0.40 [#]	3.30±0.12 [#]	20.30±0.81 [#]	4.80±0.08 [#]	2.01±0.14
Residual fraction	2.00±0.00 [#]	4.30±0.18 ^{#△}	25.30±1.08 ^{#△}	5.20±0.08 ^{#△}	1.96±1.81

*: $P<0.05$ vs. control group, [#] $P<0.05$ vs. CFA treated group, [△] $P<0.05$ vs. ethyl acetate treated group.

migration, decreased synovial space and severe inflammation (Figure 2B). Methotrexate treated rats showed significant protection against cartilage destruction, vascular proliferation, and synovial space thinning and chondrocytes migration (Figure 2C). Hydroalcoholic extract treated rats showed significantly lesser cartilage destruction, synovial space thinning, vascular proliferation and chondrocytes migration (Figure 2D). Chloroform subfraction treated rats showed moderate cartilage destruction and synovial space thinning (circle), increased chondrocytes migration, vascular proliferation and synovial space thinning (Figure 2E). Ethyl acetate treated rats showed minimal inflammation, few inflammatory cells in synovium with no evidence of lymphocytic infiltration cells in synovium or synovial proliferation cells in synovial lining (Figure 2F). Residual subfraction treated rats showed moderate to severe cartilage destruction and synovial space thinning (circle), increased chondrocytes migration, vascular proliferation and synovial space thinning (Figure 2G).

4. Discussion

Various animal models of inflammation are used extensively in research on pathogenesis of inflammatory arthritis. Important criteria to select a model include: 1) capacity to predict efficacy of agents in humans, 2) ease-performing, reproducibility of data, reasonable duration of test period and 3) similar pathology and/or pathogenesis to that of human disease. The animal model in the present study is subjected to thorough critical appraisal and validated as animal models for rheumatoid arthritis[21].

All animals tolerated the experimental procedures well, and showed no evidence of drug toxicity and death up to the completion of study. Dosage selection for fraction of *Hemidesmus indicus* (hydroalcoholic extract–450 mg/kg; chloroform fraction–75 mg/kg; ethyl acetate fraction–60 mg/kg and residual fraction–270 mg/kg) was based on previous observations of its quantitative toxicity assessment of oral root. Because *Hemidesmus indicus* was well-tolerated in the dose used (LD₅₀ was 2 500 mg/kg), various doses of fraction were designed to illuminate the anti-arthritis effect of *Hemidesmus indicus*, and to compare it with positive control group.

It has been reported that induction of adjuvant disease can be done with either Freund's complete agent supplemented with mycobacterium or by injection of the synthetic adjuvant N, N-dioctyldecyl-N', N-bis(2-hydroxy-ethyl) propanediamine. In present study *Hemidesmus indicus* significantly reduced paw on 21st day, during the second and third phases of edema development. The % inhibition of paw edema on 21st day is significantly higher in ethyl acetate fraction treated rats than chloroform fraction and residual fraction treated rats, suggesting its inhibitory effect on the prostaglandin-mediated inflammatory pathway. Activation of polymorphonuclear neutrophils is a primary immunological response to invading pathogens[23].

It has found that the ethyl acetate of *Hemidesmus indicus* roots exhibited significant anti-inflammatory activity in both

acute and subacute inflammation by significant inhibition of inflammation induced by carageenin, bradykinin, 5-hydroxy tryptamine, employing granuloma pouch and cotton pellet granulation methods in rats[24]. In the present study, it was found that ethyl acetate fraction treated rats had significant increase in body weight as compared to arthritic control animals.

The severity of arthritis was expressed as the arthritic score for each individual animal, being the sum of the measures of the four paws subtracted by the measures recorded before the immunization[21]. Arthritic score of ethyl acetate fraction treated group and methotrexate was significant lower than CFA treated rats, indicating their anti-arthritis potential.

ESR is a simple and inexpensive laboratory test for assessing the inflammatory or acute response[25]. Both ethyl acetate fraction and methotrexate can restore the altered haematological profile by increasing Hb count and decreasing the ESR.

The highest levels of rheumatoid factor are usually found in rheumatoid arthritis. Serum rheumatoid factor level in CFA treated rats was increased significantly up to (28.83±4.39) IU/mL as compared to (9.20±0.82) IU/mL in normal control rats. The prompt decrease in rheumatoid factor level after treatment with ethyl acetate fraction and methotrexate indicates their anti-arthritis potential.

CRP is a marker for inflammation, and its levels rise dramatically during inflammatory processes[23]. In the present study the level of CRP was significantly reduced by ethyl acetate fraction, which direct prohibits levels of various cytokines released. The relationship between ESR and serum CRP in rheumatic arthritis patients is roughly linear. In our study both two parameters are influenced by ethyl acetate fraction and show significant linear relationship.

The activity of inducible NO synthase is increased substantially in rheumatoid arthritis. NO is known to induce apoptosis or necrosis in T effector cells and to protect oligodendrocytes against destruction by lipid peroxidation[26]. Inhibition of these two functions of target tissue could lead to the lack or prolong of recovery. Our study showed hydroalcoholic extract of *Hemidesmus indicus* can lower serum nitrite level to alleviate symptoms of rheumatic arthritis.

Methotrexate (low dose) is one of the most successfully used anti-rheumatic agents[20]. The biochemical changes of rheumatic arthritis patients in histopathological studies are partially restored by methotrexate treatment. These arthritic changes, such as increase in synovial cavity, degradation of the cartilage surface, a large number of neutrophils infiltrations in the histopathological tissue section were restored in ethyl acetate fraction treatment group. Thus, peroral supplementation of ethyl acetate fraction prevents progression of rheumatic arthritis by increasing anti-inflammatory cytokines and decreasing pro-inflammatory cytokines which in turn stabilizes lysosome and prevents bone and cartilage damage. The activity is similar to the action of methotrexate.

It is reported that root of *Hemidesmus indicus* contain mostly steroid, terpenoid, flavonoids and saponins[1]. Steroids can decrease inflammation and reduce the activity

of the immune system. Many kinds of triterpenoids from angiosperms are known to impair histamine releasing from mast cells and to exert anti-inflammatory effects. Such a mode of action is possible in this study as well.

The result of the present study suggest that hydroalcoholic extract of *Hemidesmus indicus* root R.Br. is effective on CFA induced arthritis in rats. The ethyl acetate, chloroform & residue subfraction are also effective. However, the ethyl acetate subfraction is more effective as compared to chloroform & residue subfraction. Since terpenes, sterols and phenolic compounds are major phyto-constituents of ethyl acetate fraction, it can be assumed that they might be playing an role in this activity.

Conflict of interest

The authors declare that they have no conflict of interest.

Acknowledgements

The authors would also like to acknowledge Department of Pharmacology, KBIPER, Gandhinagar, Gujarat, India for providing the funds and facilities to carry out the work. One of the authors Mr. Neeraj K. Sethiya is thankful to the University Grants, The MS University of Baroda for providing research fellowship.

References

- [1] Austin A. A review on Indian Sarsaparilla, *Hemidesmus indicus* (L.) R.Br. *J Biol Sci* 2008; **8**(1): 1–12.
- [2] Baheti JR, Goyal RK, Shah GB. Hepatoprotective activity of *Hemidesmus indicus* (L.) R.Br. in rats. *Indian J Exp Biol* 2006; **44**: 399–402.
- [3] Khandelwal VKM, Balaraman R, Panca D, Ravingerova T. *Hemidesmus indicus* and *Hibiscus rosa-sinensis* affect ischemia reperfusion injury in isolated rat hearts. *Evidence-Based Compl & Alt Med* 2011; doi:10.1155/2011/802937.
- [4] Murshed S, Rokeya B, Nahar N, Azad Khan AK, Mosihuzzaman M, Banerjee A, et al. Hypoglycemic and hypolipidemic effect of *Hemidesmus indicus* root on diabetic model rats. *Diabetes Res* 2005; **39**: 15–23.
- [5] Gopi S, Setty OH. Beneficial effect of the administration of *Hemidesmus indicus* against bromobenzene induced oxidative stress in rat liver mitochondria. *J Ethnopharmacol* 2010; **127**: 200–203.
- [6] Ananthi R, Chandra N, Santhiya ST, Ramesh A. Genotoxic and antigenotoxic effects of *Hemidesmus indicus* R. Br. root extract in cultured lymphocytes. *J Ethnopharmacol* 2010; **127**: 558–560.
- [7] Chatterjee I, Chakravarty AK, Gomesa A. *Daboia russellii* and *Naja kaouthia* venom neutralization by lupeol acetate isolated from the root extract of Indian sarsaparilla *Hemidesmus indicus* R.Br. *J Ethnopharmacol* 2006; **106**: 38–43.
- [8] Chakraborty D, Sircar D, Mitra A. Phenylalanine ammonia-lyase-mediated biosynthesis of 2-hydroxy-4-methoxybenzaldehyde in roots of *Hemidesmus indicus*. *J Plant Physiol* 2008; **165**: 1033–1040.
- [9] Thabrewa MI, Mitry RR, Morsy MA, Hughes RD. –Cytotoxic effects of a decoction of *Nigella sativa*, *Hemidesmus indicus* and *Smilax glabra* on human hepatoma HepG2 cells. *Life Sci* 2005; **77**: 1319–1330.
- [10] Previati M, Corbacella E, Astolfi L, Catozzi M, Khan MTH, Lampronti I, et al. Ethanolic extract from *Hemidesmus indicus* (Linn) displays otoprotectant activities on organotypic cultures without interfering on gentamicin uptake. *J Chem Neuroanatomy* 2007; **34**: 128–133.
- [11] Smolen JS, Aletaha D, Machold KP. Therapeutic strategies in early rheumatoid arthritis. *Best Pract Res Clin Rheumatol* 2005; **19**(1): 163–177.
- [12] Mythilypriya R, Shanthy P, Sachdanandam P. Efficacy of Siddha formulation Kalpaamruthaa in ameliorating joint destruction in rheumatoid arthritis in rats. *Chem Biol Interact* 2008; **176**: 243–251.
- [13] Berbert AA, Kondo CRM, Almendra CL, Matsuo T, Dichi I. Supplementation of fish oil and olive oil in patients with rheumatoid arthritis. *Nutrition* 2005; **21**: 131–136.
- [14] Nair V, Singh S, Gupta YK. Evaluation of the disease modifying activity of *Colchicum luteum* Baker in experimental arthritis. *J Ethnopharmacol* 2011; **133**: 303–307.
- [15] Lampronti I, Khan MTH, Borgatti M, Bianchi N, Gambari R. Inhibitory effects of Bangladeshi medicinal plant extracts on interaction between transcription factors & target DNA sequences. *Med Chem* 2005; **1** (4): 327–333.
- [16] Bairwa NK, Sethiya NK, Mishra SH. Protective effect of stem bark of *Ceiba pentandra* Linn. against paracetamol-induced hepatotoxicity in rats. *Phcog Res* 2010; **2**(1): 26–30.
- [17] Sethiya NK, Nahata A, Dixit VK. Anxiolytic activity of *Canscora decussata* in albino rats. *J Compliment Integr Med* 2010; **7** (1): 19.
- [18] Sethiya NK, Trivedi A, Patel MB, Mishra SH. Comparative pharmacognostical investigation on four ethanobotanicals traditionally used as Shankhpushpi in India. *J Adv Pharm Tech Res* 2010; **1** (4): 392–399.
- [19] Heilborna U, Berge OG, Arboreliusc L, Brodina E. Spontaneous nociceptive behaviour in female mice with Freund's complete adjuvant- and carrageenan-induced monoarthritis. *Brain Res* 2007; **1143**: 143–149.
- [20] Banji D, Pinnapureddy J, Banji OJF, Saidulu A, Hayath MS. Synergistic activity of curcumin with methotrexate in ameliorating Freund's Complete Adjuvant induced arthritis with reduced hepatotoxicity in experimental animals. *European J Pharmacol* 2011; **668**: 293–298.
- [21] Asquith DL, Miller AM, McInnes IB, Liew FY. Animal models of rheumatoid arthritis. *Eur J Immunol* 2009; **39**(8): 2040–2044.
- [22] Owoyele VB, Oloriegbe YY, Balogun EA, Soladoye AO. Analgesic and anti-inflammatory properties of *Nelsonia canescens* leaf extract. *J Ethnopharmacol* 2005; **99**: 153–156.
- [23] Lau DC, Dhillon B, Yan H, Szmítko PE, Verma S. Adipokines: molecular links between obesity and atherosclerosis. *Am J Physiol Heart Circ Physiol* 2005; **288** (5): 2031–2041.
- [24] Verma PR, Johrapurkar AA, Chatpalliwar VA, Asnani AJ. Antinociceptive activity of alcoholic extract of *Hemidesmus indicus* R. Br. in mice. *J Ethnopharmacol* 2005; **102**: 298–301.
- [25] Cai X, Wong YF, Zhou H, Xie Y, Liu ZQ, Jiang ZH, et al. The comparative study of Sprague-Dawley and Lewis rats in adjuvant induced arthritis. Naunyn-Schmiedeberg's. *Arch Pharmacol* 2006; **373**: 140–147.
- [26] Yang CJ, Wang XW, Li X, Wu GC, Wang YQ, Ying QLM. A rat model of bone inflammation-induced pain by intra-tibial complete Freund's adjuvant injection. *Neurosci Lett* 2011; **490**: 175–179.