

Contents lists available at [ScienceDirect](#)

Asian Pacific Journal of Tropical Medicine

journal homepage: www.elsevier.com/locate/apjtm

Document heading doi:

Pulmonary nocardiosis due to *Nocardia otitidiscaviarum* in an immunocompetent host— A rare case report

Kusugodlu Ramamoorthi^{1*}, Baise Chandrappagouda Pruthvi¹, Neeleshwara Radhakrishna Rao¹, Jayaprakash Belle¹, Kiran Chawla²

¹Department of Medicine, KMC, Manipal, Manipal University

²Department of Microbiology, KMC, Manipal, Manipal University

ARTICLE INFO

Article history:

Received 22 February 2011

Received in revised form 17 March 2011

Accepted 15 May 2011

Available online 20 May 2011

Keywords:

Nocardiosis

Nocardia otitidiscaviarum

Immunocompetent

Pulmonary

ABSTRACT

Nocardiosis is a localized or disseminated infection caused by soil-borne aerobic actinomycetes. Pulmonary nocardiosis is a rare infection mostly occurring in immunocompromised patients. We reported a case of 36 year old immunocompetent non-smoker female patient with no premorbid illness who presented with fever, cough with scanty sputum, hemoptysis, left sided chest pain and exertional dyspnea for two weeks. There was no past history of tuberculosis, diabetes mellitus or steroid therapy. Chest X-ray showed homogenous peripherally based opacity in the left upper zone. Bronchoscopy was done and brushing sent for culture, which showed colonies with features of *Nocardia* species after 48 hours. Further phenotypic characterization revealed it to be *Nocardia otitidiscaviarum*. Patient was treated with cotrimaxazole for six months after which complete recovery was evidenced symptomatically and radiologically. We report this case to emphasize the fact that among the *Nocardia* species, *Nocardia otitidiscaviarum* as causative agent of pulmonary disease is rarely reported even in immunocompromised individuals.

1. Introduction

Nocardia otitidiscaviarum (*N. otitidiscaviarum*) was first recognized by Snijders in 1924 from a Sumatran cavy or guinea pig with ear disease[1]. *Nocardia* species are gram positive, branching, filamentous aerobic bacteria[2]. It can cause pulmonary infection in both immunocompetent and immunocompromised persons. *N. otitidiscaviarum* is an infrequent cause of human disease and has been isolated in less than 5% cases of all nocardia infections[3]. Pulmonary nocardiosis being the most common manifestation of nocardial disease, other sites of nocardial dissemination include skin, subcutaneous tissues, and the central

nervous system[1,4]. Rapid and accurate identification of aerobic actinomycetes is of increasing importance in clinical microbiology laboratories. We report a case of pulmonary nocardiosis caused by *N. otitidiscaviarum* in an immunocompetent patient.

2. Case report

A 36 years old female patient, who was a agriculturist with no premorbid illness came with the complaints of intermittent, low grade fever, cough with scanty sputum and hemoptysis for 2 weeks and left sided chest pain associated with exertional dyspnea for 1 week. The patient was not diabetic, did not receive steroid therapy and of without history of tuberculosis in the past. On examination vital signs and systemic examinations were unremarkable. Laboratory investigations were within normal limits. Chest

*Corresponding author: Dr. Ramamoorthi K, Senior Resident, Department of Medicine, KMC, Manipal, Udipi district, Karnataka-576104, India.
Tel: 919449615194
Fax: 918202571927
E-mail: rmoorthi414@gmail.com

X-ray showed homogenous peripherally based opacity seen in the left upper zone with no evidence of adjacent rib destruction or calcification (Figure 1). Mantoux test, sputum for acid fast bacilli, and Elisa test for HIV were also found to be negative. Sputum culture was sterile.

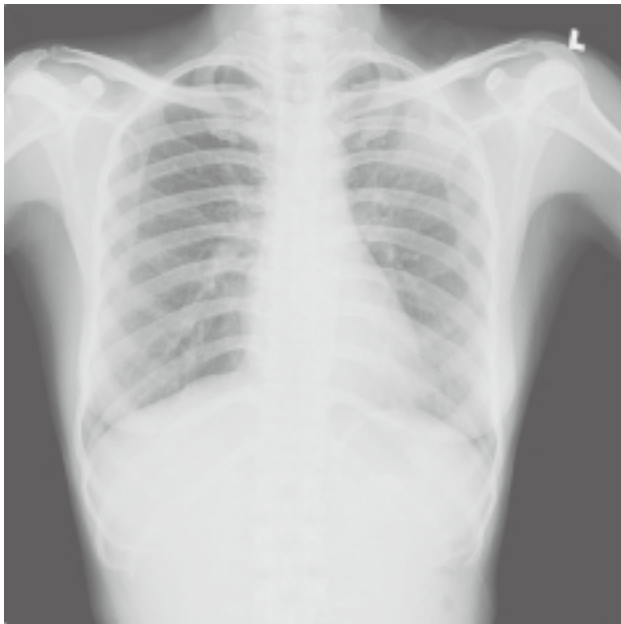

Figure 1. Chest X-ray.

High resolution CT of chest showed peripheral pleural based thin walled cavitary lesion with irregular inner margins, measuring 4.3 cm × 2.8 cm × 5.5 cm in the apico posterior segment of the left upper lobe. The lesion showed predominately peripheral enhancement on post contrast study (Figure 2).

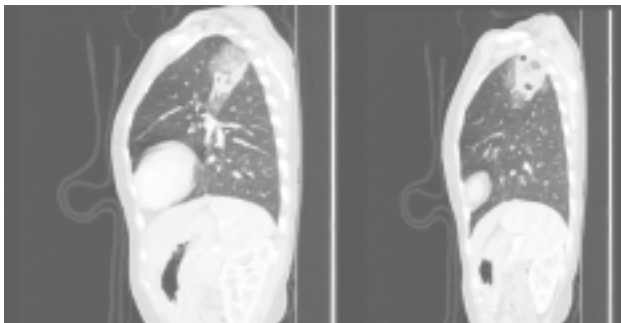


Figure 2. High resolution CT of chest.

Consolidatory changes with ground glass appearance were noted in the adjacent lung parenchyma. Thickening of the left major fissure and pleura adjacent to the lesion and adjacent soft tissue in the chest wall were seen (Figure 2).

Bronchoscopy was done and brushings was sent for culture which was done on sheep blood agar and Sabouraud dextrose agar aerobically at 37°C. Culture showed colonies with features of *Nocardia* species after 48 hours. Further phenotypic characterization confirmed it as *N.*

otitidiscaviarum (Figure 3 & 4). Patient was treated with oral cotrimaxazole. The patient showed symptomatic improvement in one week. A regular follow up and repeat chest X-ray after 2 months showed a decrease in left upper zone shadow. The patient showed complete recovery in 6 months.

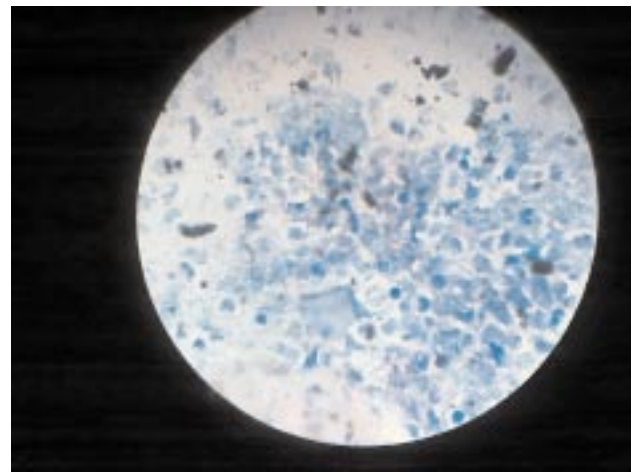


Figure 3. Results of modified acid fast bacilli staining showing the acid fast nature of the branching filamentous forms.

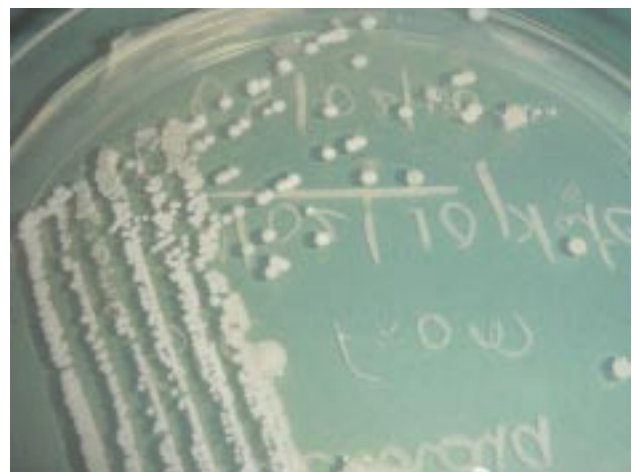

Figure 4. Culture of bronchial brushings.

3. Discussion

Pulmonary nocardiosis in human is caused by inhalation of the sporulated, fragmented nocardial mycelia [2]. *Nocardia asteroides* among the Nocardial genus is the most common pathogen, although *Nocardia brasiliensis*, *Nocardia oitidiscaviarum*, *Nocardia farcinica*, *Nocardia nova* and *Nocardia transvalensis* are also known for their involvement in lungs diseases [2]. These infections usually occur in immunocompromised patients and very rarely in immunocompetent patients [3,4].

N. oitidiscaviarum infections are rare compared to the other species of *Nocardia* and has been described as an

opportunistic pathogen for humans and animals. The most common forms of involvement in human beings are cutaneous, lymphocutaneous, pulmonary infections in both immunocompetent and immunocompromised patients. Low incidence may be attributed to reduced pathogenicity or its lower prevalence in the soil compared with other *Nocardia* species[1,4].

The most common predisposing factors for *Nocardia* infections are chronic obstructive pulmonary disease, neoplastic disease, corticosteroid therapy and HIV infection, hematologic malignancy[1,5]. Pulmonary nocardiosis may manifest like empyema necessitatis, coexist with pulmonary and extrapulmonary tuberculosis, or it may mimic relapse of tuberculosis after completion of antitubercular treatment[6–8].

In this case, clinical picture resembled pulmonary tuberculosis and the diagnosis was made through a culture of bronchial brushings. *N. otitidiscaviarum* is distinct from other species in its ability to hydrolyse both hypoxanthine and xanthine[1,3]. Molecular methods like PCR, RFLP, 16S ribosomal DNA sequencing can also rapidly and accurately detect all medically important *Nocardia* species[1]. In our institute we do not have such molecular diagnostic method to identify the *Nocardia* species and nocardial species identification was done by biochemical tests. *N. otitidiscaviarum* isolates are usually susceptible to amikacin, sulphonamides and fluoroquinolones, but resistant to broad spectrum cephalosporins, amoxicillin and imipenem[1]. For critical patients with nocardial infection, initial therapy with a combination antimicrobial regimen is recommended[5,7]. The mortality due to pulmonary nocardiosis is about 14%–40% which increases significantly when there is dissemination to the central nervous system[9–11].

In conclusion, we would like to emphasize the fact that an increased awareness of the varied presentations of nocardiosis, coupled with a high index of clinical suspicion and microbiological investigations like culture may help to improve survival as evidenced in this case, in an otherwise fatal disease. Further, such cases can be managed by effective treatment with economical drugs and adherence to treatment for sufficient time proves to be curative as evidenced in this case.

Conflict of interest statement

We declare that we have no conflict of interest.

References

- [1] Brown–Elliott BA, Brown JM, Conville PS, Wallace J. Clinical and laboratory features of the *Nocardia* spp. based on current molecular taxonomy. *Clin Microbiol Rev* 2006; **19**(2): 259–282.
- [2] Hui CH, Au VWK, Rowland K, Slavotinek, Gordon DL. Pulmonary nocardiosis re–visited: experience of 35 patients at diagnosis. *Resp Med* 2003; **97**: 709–717.
- [3] Gowrinath K, Prabhu AR, Prakash PY, Chawla K, Baig WW. Pulmonary nocardiosis owing to *Nocardia otitidiscaviarum*. *J Bronchol* 2008; **15**(2): 113–115.
- [4] Betran A, Villuendas MC, Rezusta A, Moles B, Rubio MC, Revillo MJ, et al. Cavitary pneumonia caused by *Nocardia otitidiscaviarum*. *Brazilian J Microbiol* 2010; **41**: 329–332.
- [5] Muñoz oz J, Mirelis B, Aragón LM, Gutiérrez N, Sánchez FM, España ol, et al. Clinical and microbiological features of nocardiosis 1997–2003. *J Med Microbiol* 2007; **56**: 545–540.
- [6] Cadena J, Cadena A, Hallmark K, Ahuja SK. Pulmonary nocardiosis mimicking empyema necessitatis. *J Resp Dis* 2008; **29**(1): 1–3.
- [7] Anil K, Asmita M, Ghanshyam K, Molly M. Pulmonary and extrapulmonary tuberculosis along with pulmonary nocardiosis in a patient with human immunodeficiency virus infection. *J Clin & Diagn Res* 2011; **5**(1): 109–111.
- [8] De S, Desikan P. Pulmonary nocardiosis mimicking relapse of tuberculosis. *BMJ Case Reports* 2009; 11. doi:10.1136/bcr.06.2008.0233.
- [9] Stalin Viswanathan, Vivekanandan Muthu, Nayyar Iqbal. Upper lobe pulmonary edema and dry gangrene in scorpion sting. *Asian Pac J Trop Dis* 2011; **1**(2): 166–168.
- [10] Olusoji D, Eltayeb O, Peter A, Gumusboga M, Etienne D, Rasheed B. Non tuberculosis mycobacteria isolates among new and previously treated pulmonary tuberculosis patients in Nigeria. *Asian Pac J Trop Dis* 2011; **1**(2): 113–115.
- [11] Martínez R, Reyes S, Menéndez R. Pulmonary nocardiosis: risk factors, clinical features, diagnosis and prognosis. *Curr Opin Pulm Med* 2008; **14**(3): 219–227.