



Contents lists available at ScienceDirect

Asian Pacific Journal of Tropical Medicine

journal homepage: www.elsevier.com/locate/apjtm



Document heading doi:

Co-transplantation of macaque autologous Schwann cells and human embryonic nerve stem cells in treatment of macaque Parkinson's disease

Ying Xia¹, Chengchuan Jiang², Zuowei Cao¹, Keshan Shi¹, Yang Wang³

¹Department of Neurosurgery, Haikou Hospital, Xiangya Medical School, Central South University, Haikou 570208, China

²Department of Neurosurgery, Huashan Hospital, Fudan University, Shanghai 200040, China

³Department of Anatomy, Histology and Embryology, Shanghai Medical Center, Fudan University, Shanghai 200032, China

ARTICLE INFO

Article history:

Received 9 November 2011

Received in revised form 15 November 2011

Accepted 15 December 2011

Available online 20 January 2012

Keywords:

Schwann cells

Nerve stem cells

Parkinson's disease

Co-transplantation

Macaque

ABSTRACT

Objective: To investigate the therapeutic effects of co-transplantation with Schwann cells (SCs) and human embryonic nerve stem cells (NSCs) on macaque Parkinson's disease (PD). **Methods:** Macaque autologous SCs and human embryonic NSCs were adopted for the treatment of macaque PD. **Results:** Six months after transplantation, positron emission computerized tomography showed that ¹⁸F-FP-β-CIT was significantly concentrated in the injured striatum in the co-transplanted group. Immunohistochemical staining of transplanted area tissue showed migration of tyroxine hydroxylase positive cells from the transplant area to the surrounding area was significantly increased in the co-transplanted group. **Conclusions:** Co-transplantation of SCs and NSCs could effectively cure PD in macaques. SCs harvested from the autologous peripheral nerves can avoid rejection and the ethics problems, so it is expected to be applied clinically.

1. Introduction

Parkinson's disease (PD) is a common central nervous system degenerative disease characterized symptoms such as resting tremor, hypermyotonia and bradykinesia. The pathological basis of PD is the degeneration of substantia nigra of midbrain dopaminergic neurons and the formation of Lewy's body. The main lesions are confined in the dopaminergic cell aggregation area such as substantia nigra of midbrain, dorsal nucleus of vagus nerve and so on, resulting in deformation and necrosis of dopaminergic cells, reduced production of dopamine and imbalance of dopaminergic system and acetyl cholinergic system, thus causing a series of clinical symptoms.

Numerous animal experiments have shown that neural stem cells (NSCs) transplantation is an effective therapeutic

method for PD[1–4]. However, the results of clinical trials are still not satisfactory[5–7]. It has been indicated that Schwann cells (SCs) could promote the proliferation of embryonic stem cells and differentiation to dopamine neurons *in vitro*[8]. The purpose of our experiment was to observe whether macaque autologous SCs and human embryonic NSCs co-transplantation could enhance the therapeutic effects of cell transplantation on PD, thus providing a basis for pre-clinical experiments.

2. Materials and methods

2.1. Animals and groups

Three healthy adult macaques including two males and one female, aged 5–10 years old, weighing 8–12 kg, were purchased from the Animal Center, Chinese Academy of Science. Macaques were fed in cage separately with food and fruit. Three different transplants were adopted in three macaques, including PBS control group, NSCs group and SCs plus NSCs group.

*Corresponding author: Ying Xia, Doctor, Professor, Department of Neurosurgery, Haikou Hospital, Xiangya Medical School, Central South University, Haikou 570208, China.

E-mail: xiaying008@163.com

Found project: This project is supported by the Hainan Natural Science Foundation, NO. 310147.

2.2. PD modeling

Stereotactic surgery was performed with NARISHIGE SN-2 stereotaxic apparatus in a clean air-conditioned laboratory. 2 mg/mL 6-hydroxy dopa solution (Sigma) was prepared. Basic anesthesia was carried out by intramuscular injection of 8 mg/kg ketamine, followed by intraperitoneal injection of 25 mg/kg pentobarbital, intramuscular injection of 0.1–0.15 mL of 0.5 mg/mL atropine and 0.2 mL of muscle relaxants (Bayer Corporation, used for cats and dogs). The ear bars were accurately inserted into external auditory canals. The readings of two ears bars were kept equal. About 2 cm sagittal incision was made 5 mm from the median sagittal line, with the site 7 mm from the binauricular line as the center. The scalp and periosteum were pulled out, and an 8 mm diameter cranial window was opened with a drill.

After zero calibration of the stereotaxic apparatus, 10 μ L solution (containing 20 μ g 6-OH dopa) was extracted with a Hamilton microsyringe and injected in the following standard targets in order (Table 1). The injection time was 5 min, and the needle was kept for 8 min. 20 sec interval was kept after each 1 mm withdrawing needle within the former 10 mm, and the withdrawing needle was faster slightly within the later 10 mm. After injection, the head wound was washed with 3% hydrogen peroxide and Gentamicin sodium chloride. The continuous suture was carried out for periosteum, and interrupted suture was carried out for scalp.

2.3. Culture, purification and identification of macaque SCs

Autogenic SCs culture and identification were performed in the co-transplanted macaque 4 months after successful modeling.

2.3.1. Nerve ligation

Ectogluteus injection anesthesia was performed with 8 mg/kg ketamine. After routine disinfection, 2 cm skin incision was made behind the leg 3–5 cm above the external malleolus. The sural nerve was separated by blunt dissection. The nerve was ligated with sutural line near the superior extremity of the incision. The skin was sutured and sterilized.

2.3.2. Culture of SCs

7 days after nerve ligation, 1 cm nerve segment was obtained under the ligation site under sterile conditions. The nerve segment was placed into 4 °C of D-Hank buffer, and the skin was sutured. The adhesive tissue around the nerve was removed under an operation microscope. The nerve tract was pulled out from the epineurium, and the perineurium was removed. The nerve was cut into 1 mm segments, with 50 explants in each segment. The nerve segments were implanted into rat tail collagen pre-coated 35 mm diameter plate. The culture medium contained 20% calf serum and 80% DMEM (Gibco Company). The plate was placed in 37 °C incubator (Heraeus) with 5% carbon dioxide. Medium was replaced every other day.

2.3.3. Passage and purification of SCs

Fibroblasts were removed with repeated “explant method”. When SCs covered 100% of the plate, the explants were transplanted into a new plate. The explant-removed SCs were digested for passage with 0.25% trypsin plus 0.01% EDTA (1:1). Immunocytochemical staining for S-100 protein was performed with PAP method. The percentage of S-100 positive cells to total cells was the purity of SCs.

2.4. Harvest, culture and identification of NSCs in human embryonic mesencephal tissue

Stem cells were obtained from two 8–10 weeks aborted embryonic mesencephal tissues, which were approved by hospital ethics committee and the pregnant women.

2.4.1. Sampling

Mesencephalon of fetus was obtained and placed into D-Hank solution. After cleaning, the tissue was cut into pieces and put into 1.5 mL centrifuge tube. Tissue was digested for 20 min with 1 mL 0.125% trypsin at 37 °C, and digestion was stopped with 50 μ L of 1% trypsin inhibitor. Then the digestion product was centrifuged at 1 000/min for 10 min, and the supernatant was removed. The pipette was placed into appropriate amount of cold D-Hank solution in a new 10 mL centrifuge tube, and mixed gently with capillary until the suspension became white. The suspension was filtered with 200 meshes stainless steel filter, and the supernatant was removed. DMEM/F12 culture medium (containing 1% N2, 2% B27 and 20 ng/mL BFGF) was added into tube. The proportion of the dead cells to the active cells was detected with trypan blue staining. Cells were seeded into 25 mL culture flask as 5×10^6 /mL density, and incubated at 37 °C with 5% CO₂ as suspension culture. According to cell growth rate and the pH value, half of the medium was changed per 2 to days. After that, cells were passaged once by mechanical digestion per 5–7 d, and the method was same with the previous method. The 1:2 passage method was used in our study. The original generation nerve spheres were made into single cell suspension, and then cultured.

2.4.2. Identification of NSCs

Suspension cultured nerve spheres were planted into polylysine (50 μ g/mL) pro-coated 24-well plate. Cells were fixed with 4% paraformaldehyde for 30 min, and then indirect cell immunofluorescence was performed. The steps were shown as follows: Cells were washed with 0.01 M PBS for three times, and then cell membrane was perforated with 0.1% Triton. Cells were blocked with normal goat serum, and then incubated with the primary antibody against nestin (1:5 000) in the humid box at 4 °C overnight. Cells were washed with 0.01M PBS for three times, and then incubated with IgG-CY3 fluorescence second antibody (1:5 000) at room temperature for 1 h, and then cells were observed under fluorescence microscope and photos were obtained.

2.5. Preparation of transplant cell suspension before transplantation

2.5.1. Preparation of SCs suspension

SCs were washed with 10% FCS+90% DMEM for three times and with D-Hank twice 2 h before transplant operation. Then cells were digested with 0.25% trypsin, and then centrifuged. 1×10^7 /mL cell suspension was prepared with PBS, and then placed into a 4 °C refrigerator.

2.5.2. Preparation of human embryonic NSCs suspension

Nerve stem cell suspension was prepared 2 h before transplantation. All mesencephal nerve stem cell spheres in the 6th passage were collected. After centrifugation, cells were digested with 0.25% trypsin-EDTA at 37 °C for 15-20 min. Digestion was stopped with 10% fetal calf serum. Cell suspension was mixed gently, and cell density was adjusted with PBS to 1×10^8 /mL, and rapidly stored in a 4 °C refrigerator.

2.6. Cell transplantation

Transplantation was carried out 6 months after 6-OHDA unilateral PD modeling. Three grafts were adopted for three macaques. PBS was injected in the right striatum of the control group. NSCs transplantation was carried out in the right striatum of the stem cell macaque. SCs plus NSCs transplantation was carried out in the right striatum of the co-transplant macaque. Four caudate nucleus of right striatum target and four dorsal caudate putamen targets were chose as the transplant area, with 10 μ L suspension in each target.

2.7. Selection of the transplant target

According to the projection direct of dopaminergic

neurofibril and the distribution area of the target cells, the targets were 4 right caudate nucleus targets and 4 dorsal caudate putamen targets (Table 2).

2.8. Behavior evaluation

Gomez-Mancilla dyscinesia score scale was adopted^[9]: A, Posture: normal, 0; flection to the injured side, 1; flection to the injured opposite side; 2. B, Action: active, 1; passive, 2; without limb-like or fumble-like action, 0; with limb-like or fumble-like action, 1. C, walking: normal, 0; abnormal, 1. D, getting food: normal, 0; abnormal, 1. E, communicate with other macaques: normal, 0; eluding, 1. F, cry, normal, 0; obviously decreased, 1. G, limb trem of injured opposite side: inexistence, 0; existence, 1. Successful model evaluation score should be over 6 scores. For transplantation experiment, the score recovered to 0-4 score or the score decreased over 2 scores was considered as effectiveness. Behavior score of macaque was performed 1, 2, 3, 4, 5 and 6 months after 6-OHDA injury operation and 2 weeks, 1, 2, 3, 4, 5 and 6 months after transplantation.

2.9. Validation of PD model and cell transplantation target with MRI

Head cross section and coronal plane plain scan was performed with GE Signa 3.0T magnetic resonance imaging machine. The base line of cross section plain scanning was the audio orbital line, and the baseline of coronal plane was vertical to the audio orbital line. T1W and T2W imaging was performed by using SE sequence. MRI examination was performed 1 week after injure operation and 1 week after cell transplantation.

Table 1

Site of each injection target (mm).

Order of injection	A (before 0 point)	R (right of 0 point)	H (above of 0 point)
1	7.0	3.0	-0.5
2	9.0	2.5	0.7
3	6.5	2.7	-1.2
4	8.0	2.3	0.0
5	6.0	4.0	-0.9
6	7.5	3.3	-1.3
7	5.0	3.9	0.0

Table 2

Coordinate value of transplant targets (mm).

Order of injection	A (before 0 point)	R (right of 0 point)	H (above of 0 point)
Right caput nuclei caudati	1	21.5	3.5
	2	20.0	4.5
	3	20.0	3.0
	4	18.5	3.5
Right dorsal caudate putamen	1	20.0	8.5
	2	19.5	8.0
	3	19.0	8.5
	4	18.5	8.5

2.10. PET examination

Positron emission computerized tomography (PET) was performed 6 months after 6-OHDA injury operation and 2 as well as 6 months after cell transplantation. The developer ^{18}F -N-(3-Fluoro-propyl)-2- β -carbomethoxy-3- β -(4'-Iodophenyl)demethyl tropane (^{18}F -FP- β -CIT) of dopamine transporter (DAT) was used for DAT examination. BIOGRAPH SENSATION 16 PET/CT was purchased from Siemens, Germany.

2.11. Histology examination

2.11.1. Animal intravascular perfusion and sampling

Macaque brain was detected in histology 6 months after 6-OHDA injure operation. Basal anesthesia was performed with 8 mg/kg ketamine followed by depth of anesthesia with 50 mg/kg pentobarbital sodium. The heart was exposed after thoracotomy. The pericardium was cut, and the inferior vena cava was clasped. The infusion needle was inserted into left ventricle, and the right atrial appendage was cut open. The right atrial appendage was rapidly infused with 1 000 mL warm sodium chloride, followed by 1 000 mL 4% paraformaldehyde fixation solution for 20 min fast followed by slow. After craniotomy, the brain was fixed for 5 days at 4 °C. The coronal plane was determined according to the anatomical atlas. The brain tissue was cut in a coronal incision between A3 mm–A10 mm, and the striatum and substantia nigra were separated. The tissue was separated into two left and right pieces, and each was separated into trisection in coronal plane. These six tissues were numbered and placed into 10%, 20% and 30% sucrose solution in order for gradient dehydration. The tissues were removed after sinking, and embedded with embedding material. 30 μ m brain slices were prepared with frozen section mechanism

2.11.2. TH immunohistochemical staining of brain tissue

The steps of tyroxine hydroxylase (TH) immunohistochemical staining were shown as follows: 1) 30 μ m paraffin section was conventionally deparaffined with xylene following gradient ethanol dehydration; 2) The sections were placed into Sodium Citrate buffer (pH6.0, 2.1 g/L), and treated with microwave for 5 min at 95 °C, 5 min twice, and then cooled down at room temperature for 20 min; 3) The sections were rinsed with PBS for three times; 4) The sections were incubated with 5% calf serum+0.2% Triton \times 100 for 24 h at 4 °C, and then incubated with the primary antibody (TH antibody 1:1 000) at 4 °C overnight; 5) The sections were rinsed with PBS for 10 min for three times; 6) Second antibody: The sections were incubated with biotinylation goat anti-rabbit IgG at room temperature for three hours; 7) The sections were rinsed with PBS for 10 min for three times; 8) The sections were incubated with ABC reagent for 1 h; 9) The sections were rinsed with PBS for 10 min for three times; 10) The colouration was performed with 0.04% DAB (containing 0.01% H_2O_2) for 5–20 min; 11) The sections were

rinsed with lotic water; 12) The sections were sealed after common alcoholic dehydration and clearing with Xylene. All above steps were performed at room temperature except indicated.

3. Results

3.1. Evaluation of macaque PD model

3.1.1. Behavior evaluation

Behavior observations indicated that three macaques immediately showed reduced contralateral limbs activity, hypermytonia and gait abnormalities after right substantia nigra pars compacta injury. When they were fed, the macaques got the food with the right forelimb. The macaques showed sluggish facial expressions and decreased blinking. The left flexor showed hypermytonia, presenting a special flexuosity stance and prostrate action. These three macaques reached 6–8 scores before transplantation, and reached unilateral PD standard.

3.1.2. Injection target detected by MRI

Three model macaques were examined with MRI. T2W sequence showed the clearest picture of the injured site. The target was accurately located in the substantia nigra of deutocerebrum.

3.1.3. Results of PET examination

PET examination for three model macaques showed that ^{18}F -FP- β -CIT was significantly concentrated in the normal (left) striatum, while its radioactive uptake was significantly decreased in the injured (right) striatum.

3.2. Culture and identification of human embryo NSCs

The primary cells showed suspension growth. After 1 day, cells aggregated into a lump, forming different sizes of regular nerve spheres. Most of the cells had good refraction and powerful activity. Small amount of intercellular substance and cells still mixed in the cell suspension, with poor refraction. Cells still showed suspension growth after passage. The nerve spheres had good refraction and powerful activity. The intercellular substance, dead cells and cell debris were gradually decreased (Figure 1). Cells showed indirect immunofluorescence for Nestin (Figure 2).

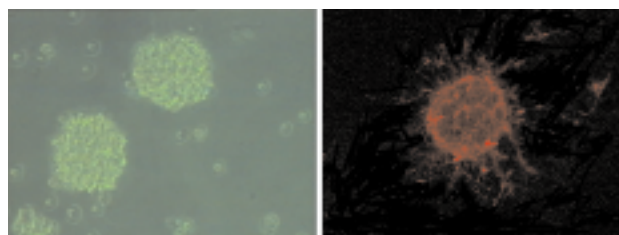


Figure 1

Figure 2

Figure 1. Suspension growth of NSCs (\times 100).

Figure 2. Indirection immunofluorescence result of NSCs(\times 100).

3.3. In vitro growth and identification of macaque autogeneic SCs

Under inverted phase contrast microscope, cells grew surrounding the explant 48 h after explant culture. A large number of SCs grew followed by the initial fibroblasts. Schwann cell was spindle, with bipolar prominence and obvious oval nucleus. With the migration of cells to periphery, the density of SCs was gradually increased, connecting into pieces (Figure 3a). In the eugenic area, the SCs arranged in neat swirling shoulder by shoulder (Figure 3b). SCs showed S-100 positive staining (Figure 4).




Figure 3. In vitro growth of SCs (×100).

a: Growth after 1 week.

b: Growth after 4 weeks.

Figure 4. S-100 positive staining of SCs(×100).

3.4. Behavior evaluation of transplanted macaques

The transplantation effect was observed from the second week after transplantation. The macaques in each group still showed decreased and slow actions. One month after transplant operation, the parameters of dyskinesia of the co-transplanted macaque recovered in different degree, while the stem cell transplanted macaque and the control macaque were not significantly changed. From the second month, the recovery degrees of the stem cell transplanted macaque and the control macaque were over 2 scores, indicating an effective transplantation. Up to 4 months after transplantation, the recovery has been near to normal. The left limb tremor of cell transplanted macaque disappeared, and the left forelimb could get the food independently and recovered the fine movement of getting raisins. The contralateral hypermyotonia was significantly improved, and the posture recovered to normal. The autonomic activities were significantly increased (Figure 5).

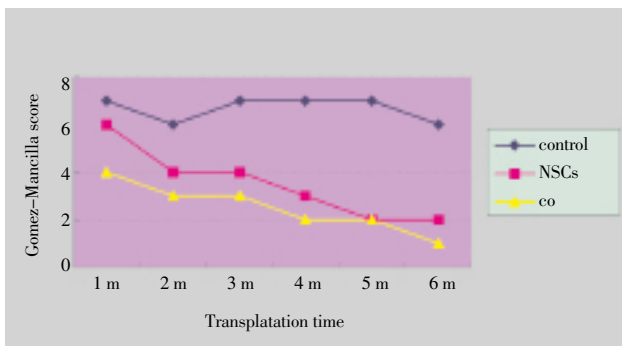


Figure 5. Behavior changes of macaques.

3.5. MRI examination after transplantation

MRI examination was performed in three model macaques. T2W sequence showed the clearest picture. The target was accurately located in the striatum area, which was seen in Figure 6a&b.

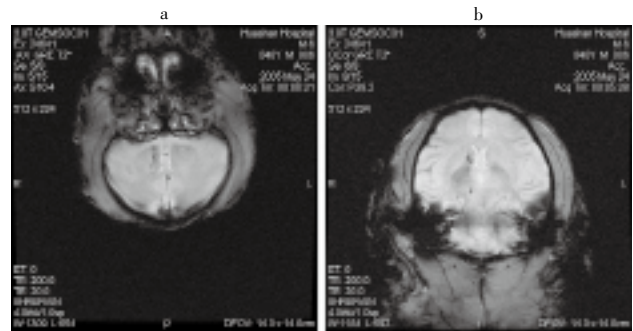


Figure 6. MRI result after transplantation.

a: Cross section of T2W sequence.

b: Coronal section of T2W sequence.

3.6. PET examination result after transplantation

PET result showed that 18F-FP-β-CIT was significantly radioactively concentrated in the normal (left) striatum, while its radioactive uptake was also significantly concentrated in the injured (right) striatum in the co-transplanted macaque 2 months after transplantation. The radioactive uptake was a small quantity concentrated in the injured (right) striatum in the stem cell-transplanted macaque (Figure 7a-c). 6 months after transplantation, 18F-FP-β-CIT was significantly radioactively concentrated in the injured (right) striatum in the co-transplanted macaque and stem cell-transplanted macaque (Figure 8a-c).

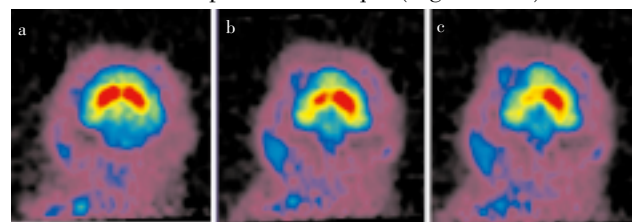


Figure 7. PET result 2 months after transplantation.

a: PET result of co-transplanted macaque.

b: PET result of stem cell transplanted macaque.

c: PET result of control macaque.

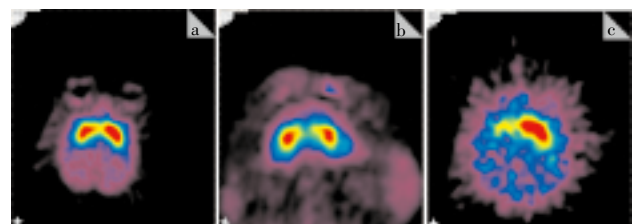


Figure 8. PET result 6 months after transplantation.

a: PET result of co-transplanted macaque.

b: PET result of stem cell transplanted macaque.

c: PET result of control macaque.

3.7. Immunohistochemistry of TH in transplanted brain tissue

The immunohistochemical staining of transplanted area tissue showed that there was no TH positive cell in the striatum of the control macaque (Figure 9a). TH positive cells could be seen in the striatum of the stem cell-transplanted macaque (Figure 9b). In the co-transplanted macaque, the number of TH positive cells was significantly increased, and the cell prominence was also significantly increased (Figure 9c).




Figure 9. TH staining of right striatum (x200).

a: Control macaque
b: NSCs-transplantation macaque
c: Co-transplantation macaque

4. Discussion

So far, all methods for the treatment of PD are to make a balance between dopamine and acetylcholine under a pathological state, thus alleviating the symptoms, but not repairing nerve functions. However, the pathological changes of PD are relatively clear, and the sites of the pathological changes are relatively concentrated. Therefore, cell transplantation is relatively easy, and the clinical and pathological observations are also easier to implement.

With the extension of time, commonly used levodopa (L-dopa) therapy will gradually show the decreased therapeutic efficacy and some complications^[10-12]. Pallidotomy and electric stimulation of subthalamic nucleus have good therapeutic effects for improving movement disorders (especially caused by L-dopa), but less effects for tremor, and the long-term effect is poor, with the recurrence of many symptoms within a few years^[13,14]. In recent years, deep brain stimulation (DBS) has gradually become more common. However, from the view of PD pathogenesis, DBS is still a symptomatic treatment, which can not prevent the progression of the disease, and no long-term effect was reported^[15,16]. Cell transplantation is the best method for PD treatment from the view of theory. According to the anatomical characteristics of substantia nigra-striatum and the mode of action of dopamine neurons in the nerve ending of striatum area, transplantation of cells with dopamine-secreting function can improve the deteriorated substantia nigra dopaminergic neuronal function of PD patients and restore the content of dopamine in the striatum, through a functional "biological micro-pump", thus achieving a long-term effect.

Animal experiments proved that stem cell transplantation was an effective therapeutic method for PD, but the

therapeutic efficacy was unstable clinically, the main reason of which was the low cell survival rate. The transplanted cells can not obtain adequate nutrition because of the striatum lesion caused by the long-term course of PD. Simultaneously, various nutrition factors maintaining cell growth, differentiation and migration are lacking. Therefore, the protective efficacy of was poor in clinical trials^[17-20]. According to the different mechanisms of transplanted cells, both stem cells and SCs could be transplanted together. Stem cells can cure PD through secreting dopamine, while SCs can improve the survival microenvironment of the transplanted stem cells and enhance the survival rate of the transplanted cells and the differentiation rate of the transplanted cells into dopaminergic neurons.

The establishment of PD animal model is the precondition of various experiments. So far, the mouse PD model and rat PD model have been established. These rodent models are able to replicate the clinical symptoms of PD under certain extent. Rat models are widely accepted by researchers due to its economy, easier establishment and direct behavior observation. However, it is not an ideal animal model for human PD due to its different pathophysiology from human PD.

The primate macaque PD model is an ideal animal model, but it is difficult to be applied widely due to its high price. So far, only a little research groups involved in this field. Only three unilateral 6-OHDA partial injure macaque PD model were adopted in our study due to the financial restriction. Human embryonic midbrain NSCs as well as the autologous SCs of macaque were adopted to further validate the efficacy and the clinical application possibility of the co-transplantation combined with MRI and PET.

Our experiment showed that the automatic action of 6-OHDA unilateral injured macaque PD model was significantly decreased, and hypermytonia and resting tremor were shown in the contralateral limb. The macaque showed bradykinesia, gait irregularity, mask-like face and increased grovel action. The dyskinesia score was over 4 scores after 4 months. MRI examination proved that the accurate target is located in the substantia nigra. PET examination showed that the uptake of the injured striatum DAT developer 18F-FP-β-CIT was significantly decreased. The model was stable and reliable, which was consistent with the requirement of experiment. Moreover, transplanted MRI revealed that the transplanted area of right striatum was accurate, which was also consistent with the requirement of experiment.

The effect of transplantation was observed two weeks after transplantation. The transplanted animals in each group still showed reduced movement of left limbs and the movement was slow. During the first month after transplantation, every dyskinesia parameters of the co-transplantation macaque were recovered at different extents, while the SCs-transplanted macaque and the control macaque had no significant changes. After 2 months, the recovery extent of the SCs-transplanted macaque and the control macaque was over 2 points, suggesting that

the transplantation was effective. Up to 4 months after transplantation, the recovery has been near to normal. The left limb tremor of cell transplanted macaque disappeared, and the left forelimb could get the food independently and recovered the fine movement of getting raisins. The contralateral hypermytonia was significantly improved, and the posture recovered to normal. The autonomic activities were significantly increased, while it was not significantly changed in the control macaque. All above suggested that cell transplantation was effective in both macaques, but the praxiology improvement was earlier in the co-transplanted macaque.

During the pathological and biochemical changes of PD, the changes of dopaminergic neuron number on presynaptic membrane of striatum up-regulates or down-regulates the corresponding receptors on postsynaptic membrane. The dopamine transporter (DAT) is also changed, and this change is more specific and more sensitive. Therefore, the change of functional activity and density DAT is an important indicator for reflecting the function of DA neurotransmitter system. As a membrane protein on the presynaptic membrane of dopaminergic neuron, the main function of DAT is to re-uptake of DA from the synaptic gap and to regulate the information transfer of the interaction between DA and its receptor. About 3/4 DA is transferred to presynaptic membrane by DAT for re-use. Currently, the change of DA can not be observed by head CT and MRI. The changes of the function and the density of DAT on DA neurons presynaptic membrane are consistent with the change of DA neurons. Its functional imaging will benefit to reflect the pathological change of substantia nigra DA neurons in PD and evaluate the effects of cell transplantation^[21-23]. In our study, the developer of DAT was F-18 or C-11 labeled cocaine derivative CIT. These developers have high affinity to DAT, and have low non-specificity uptake and a relative slow brain clearance rate. More than 95% of CIT can bind DAT in the basal ganglia after the intravenous injection. Therefore, it is an ideal imaging tracer for DAT. It can reflect the change information of presynaptic dopaminergic neuron directly and sensitively, and imaging earlier than the postsynaptic receptor. Therefore, it can reflect the change of presynaptic dopaminergic system timely, and has a good correlation with PD severity.

PET result showed that 18F-FP- β -CIT was significantly radioactively concentrated in the normal (left) striatum, while its radioactive uptake was also significantly concentrated in the injured (right) striatum in the co-transplanted macaque 2 months after transplantation. The radioactive uptake was a small quantity concentrated in the injured (right) striatum in the stem cell-transplanted macaque. 6 months after transplantation, the developer of 18F-FP- β -CIT was significantly radioactively concentrated in the injured (right) striatum in the co-transplanted macaque and stem cell-transplanted macaque, while it was not significantly changed in the control macaque. The above suggested that

the function of the transplanted human embryonic stem cell presynaptic dopaminergic neuron had been established in the co-transplanted macaque 2 months after transplantation, while the function of the transplanted human embryonic stem cell presynaptic dopaminergic neuron had not been established in the stem cell-transplanted macaque at that time, and it recovered 6 months after transplantation. Although the function of the transplanted human embryonic stem cell presynaptic dopaminergic neuron had not been established in the stem cell-transplanted macaque 2 months after cell transplantation, the praxiology examination showed the effective transplantation, which may be related to the secreted DA by transplanted cells. Although the synapsis function of the transplanted cells was still not established, they could secrete DA, thus enhancing the DA content in the striatum and maintaining the balance between Dopamine and acetylcholine, therefore the symptoms were relieved. In the co-transplanted macaque, the existence of SCs could promote the transformation of NSCs to the dopaminergic neuron, the proliferation of nerve fiber, and the establishment of presynaptic dopaminergic neuron. In addition, the transplanted SCs in striatum may secrete various neurotrophic factors which improve the microenvironment of dopaminergic neuron in transplanted area. Simultaneously, it also promoted the growth and function recovery of the impaired striatum nerve fiber and promoted the budding of remained DA fiber, thus inducing the budding of DA fibers^[24-26].

TH staining of three macaques brain tissue in the transplantation showed that there was no TH-positive cells in the striatum of the control macaque and TH-positive cells could be seen in SCs-transplantation macaque; while increased TH-positive cells could be seen in the co-transplantation macaque, and the protrusions around cells were also significantly increased.

In summary, co-transplantation has been proved to be effective and feasible in both praxiology, molecule (DAT) and histology (brain tissue TH staining). SCs can be derived from the peripheral nerve of the patients. It is easy to be obtained and its injury for patients is small. In addition, patients do not have to worry about the rejection. Therefore, SCs are easy to be accepted by patients and also easy to be applied clinically.

In short, the mechanisms of embryonic brain cell transplantation for treatment of PD may be different in the postoperative early stage and the later stage. The early effect is probably due to the graft-secreted DA, while the maintenance of long-term efficacy is dependent on the re-domination of the transplanted DA fiber to the striatum. In our study, although the symptoms of co-transplantation macaque improved more rapidly, both SCs transplantation macaque and co-transplantation macaque were proved to be effective after 6 months observation. The long-term therapeutic effect of above two methods still needs to be further studied.

Conflict of interest statement

We declare that we have no conflict of interest.

Acknowledgements

We thank Zhongliang Ding and Baodong Jiang for excellent technical assistance. We also thank Xiao Gong for take care macaques.

References

- [1] Deierborg T, Soulet D, Roybon L, Hall V, Brundin P. Emerging restorative treatments for Parkinson's disease. *Prog Neurobiol* 2008; **85**(4): 407–432.
- [2] Daniela F, Vescovi AL, Bottai D. The stem cells as a potential treatment for neurodegeneration. *Methods Mol Biol* 2007; **399**: 199–213.
- [3] Muraoka K, Shingo T, Yasuhara T, Kameda M, Yuen WJ, Uozumi T, et al. Comparison of the therapeutic potential of adult and embryonic neural precursor cells in a rat model of Parkinson disease. *J Neurosurg* 2008; **108**(1): 149–159.
- [4] Redmond DE Jr, Bjugstad KB, Teng YD, Ourednik V, Ourednik J, Wakeman DR, et al. Behavioral improvement in a primate Parkinson's model is associated with multiple homeostatic effects of human neural stem cells. *Proc Natl Acad Sci USA* 2007; **104**(29): 12175–12180.
- [5] Morizane A, Li JY, Brundin P. From bench to bed: the potential of stem cells for the treatment of Parkinson's disease. *Cell Tissue Res* 2008; **331**(1): 323–336.
- [6] Olanow CW, Gracies JM, Goetz CG. Clinical pattern and risk factors for dyskinesias following fetal nigral transplantation in Parkinson's disease: a double blind video-based analysis. *Mov Disord* 2009; **24**(3): 336–343.
- [7] Freed CR, Greene PE, Breeze RE, Tsai WY, DuMouchel W, Kao R, et al. Transplantation of embryonic dopamine neurons for severe Parkinson's disease. *N Engl J Med* 2001; **344**(10): 710–719.
- [8] Grothe C, Timmer M, Scholz T, Winkler C, Nikkhah G, Claus P, et al. Fibroblast growth factor-20 promotes the differentiation of Nurr1-overexpressing neural stem cells into tyrosine hydroxylase-positive neurons. *Neurobiol Dis* 2004; **17**(2): 163–170.
- [9] Gomez-Mancilla B, Bédard PJ. Effect of chronic treatment with (+)-PHNO, a D2 agonist in MPTP-treated monkeys. *Exp Neurol* 1992; **117**(2): 185–188.
- [10] Evans AH, Lawrence AD, Lees AJ. Changes in psychomotor effects of L-dopa and methylphenidate after sustained dopaminergic therapy in Parkinson's disease. *J Neurol Neurosurg Psychiatry* 2009; **80**(3): 267–272.
- [11] Chan PL, Nutt JG, Holford NH. Levodopa slows progression of Parkinson's disease: external validation by clinical trial simulation. *Pharm Res* 2007; **24**(4): 791–802.
- [12] Pascual-Sedano B, Kulisevsky J, Barbanoj M, García-Sánchez C, Campolongo A, Gironell A, et al. Levodopa and executive performance in Parkinson's disease: a randomized study. *J Int Neuropsychol Soc* 2008; **14**(5): 832–841.
- [13] Haffenden A, Khan U, Kiss ZH, Suchowersky O. Surgery for Parkinson's disease improves disability but not impairment components of the UPDRS-II. *Parkinsonism Relat Disord* 2007; **13**(7): 399–405.
- [14] Blomstedt P, Hariz GM, Hariz MI. Pallidotomy versus pallidal stimulation. *Parkinsonism Relat Disord* 2006; **12**(5): 296–301.
- [15] Hariz MI, Rehncrona S, Quinn NP, Speelman JD, Wensing C. Multicenter study on deep brain stimulation in Parkinson's disease: an independent assessment of reported adverse events at 4 years. *Mov Disord* 2008; **23**(3): 416–421.
- [16] Hariz MI, Krack P, Alesch F, Augustinsson LE, Bosch A, Ekberg R, et al. Multicentre European study of thalamic stimulation for parkinsonian tremor: a 6 year follow-up. *J Neurol Neurosurg Psychiatry* 2008; **79**(6): 694–699.
- [17] Trott CT, Fahn S, Greene P, Dillon S, Winfield H, Winfield L, et al. Cognition following bilateral implants of embryonic dopamine neurons in PD: a double blind study. *Neurology* 2003; **60**(12): 1938–1943.
- [18] Brundin P, Pogarell O, Hagell P, Piccini P, Widner H, Schrag A, et al. Bilateral caudate and putamen grafts of embryonic mesencephalic tissue treated with lazarets in Parkinson's disease. *Brain* 2000; **123**(Pt 7): 1380–1390.
- [19] Schumacher JM, Ellias SA, Palmer EP, Kott HS, Dinsmore J, Dempsey PK, et al. Transplantation of embryonic porcine mesencephalic tissue in patients with PD. *Neurology* 2000; **54**(5): 1042–1050.
- [20] López-Lozano JJ, Bravo G, Brera B, Millán I, Dargallo J, Salmeán J, et al. Long-term improvement in patients with severe Parkinson's disease after implantation of fetal ventral mesencephalic tissue in a cavity of the caudate nucleus: 5-year follow up in 10 patients. Clinica Puerta de Hierro Neural Transplantation Group. *J Neurosurg* 1997; **86**(6): 931–942.
- [21] Booij J, Knol RJ. SPECT imaging of the dopaminergic system in (premotor) Parkinson's disease. *Parkinsonism Relat Disord* 2007; **13**(Suppl 3): S425–428.
- [22] Sossi V, de la Fuente-Fernández R, Schulzer M, Troiano AR, Ruth TJ, Stoessl AJ. Dopamine transporter relation to dopamine turnover in Parkinson's disease: a positron emission tomography study. *Ann Neurol* 2007; **62**(5): 468–474.
- [23] Scherfler C, Schwarz J, Antonini A, Grosset D, Valldorola F, Marek K, et al. Role of DAT-SPECT in the diagnostic work up of parkinsonism. *Mov Disord* 2007; **22**(9): 1229–1238.
- [24] Lavdas AA, Papastefanaki F, Thomaidou D, Matsas R. Schwann cell transplantation for CNS repair. *Curr Med Chem* 2008; **15**(2): 151–160.
- [25] Wan H, An Y, Zhang Z, Zhang Y, Wang Z. Differentiation of rat embryonic neural stem cells promoted by co-cultured Schwann cells. *Chin Med J (Engl)* 2003; **116**(3): 428–431.
- [26] Mirsky R, Jessen KR, Brennan A, Parkinson D, Dong Z, Meier C, et al. Schwann cells as regulators of nerve development. *J Physiol Paris* 2002; **96**(1–2): 17–24.