

Total Knee Arthroplasty in Alkaptonuric Ochronosis: the First Case Report in Thailand and Literature Review

Witchuree Wejjakul, M.D., Anuwat Pongkunakorn, M.D.

Department of Orthopaedic Surgery, Lampang Hospital and Medical Education Center, Lampang 52000, Thailand.

ABSTRACT

Ochronosis is a musculoskeletal manifestation found in alkaptonuria which is a rare autosomal recessive disorder caused by the deficiency of homogentistic acid oxidase enzyme. This leads to accumulation and deposition of homogentistic acid (HGA) pigments in skin, sclera, tendon, ligament and cartilage. Ochronosis is asymptomatic until ochronotic arthropathy occurs. We reported a case of 64-year female presented with advanced degenerative changes in the knee, hip, shoulder and lumbo-sacral spine. The operative findings during total knee arthroplasty showed bluish-black discoloration of the entire articular surface. Her urine HGA level was extremely high. Histopathological exam confirmed ochronosis. The literature, differential diagnosis and management of this rare condition are reviewed.

Keywords: Alkaptonuria; ochronosis; arthropathy; osteoarthritis; total knee arthroplasty

Siriraj Med J 2016;68:305-309

E-journal: <https://www.tci-thaijo.org/index.php/sirirajmedj>

INTRODUCTION

Alkaptonuria (AKU) is a rare inborn error of metabolism, inherited with autosomal recessive pattern. The current estimated incidence is 1:250,000 to 1:1,000,000 live births worldwide.¹ It is caused by mutations in the homogentistic acid oxidase (HGO) gene and results in an accumulation of homogentisic acid (HGA), ochronosis, and destruction of connective tissue. Ochronosis is a term which describes a gross bluish-black discoloration of tissues. Virchow firstly described in 1866 about microscopic necropsy findings of tissue hyperpigmentation caused by ochre-colored (yellow-brown) granules deposition.² Although the microscopic finding reveals yellow-

brown granules, the macroscopic finding shows bluish-black discoloration because of a light scattering phenomenon known as the Tyndall effect. Ochronosis arises in approximately 50% of alkaptonuric patients² and results from deposition of HGA pigment in connective tissues; such as cartilage, skin, sclerae, tendons and ligaments. Alkaptonuric ochronosis is usually asymptomatic until arthropathy occurs at fourth to fifth decade of life. Degenerative arthritis is the major clinical manifestation; which usually involves hip and knee, and joint replacement surgery is the unavoidable treatment of choice. Ochronotic arthropathy is often diagnosed intraoperatively with the findings of bluish-black discoloration of articular cartilage, synovium or meniscus. This gives the essential point for orthopaedic surgeon to recognize the typical signs and symptoms of AKU at the first time of patient evaluation. Here we present a case of ochronotic arthropathy incidentally diagnosed

Correspondence to: Anuwat Pongkunakorn

E-mail: dranuwat@hotmail.com

Received 2 March 2016

Revised 4 April 2016

Accepted 7 April 2016

during total knee arthroplasty and some review of the latest literature.

CASE REPORT

A 64-year female patient presented with severe left knee pain for 3 years. She complained about pain on her left knee for over 10 years. Three years ago, the pain got worse, leading to limitation of her daily activities. She could walk with cane, but could not go up or down the stairs. She could bear weight on her right leg during walking with occasionally minimal pain in right knee and both hips. There was moderate difficulty to get up from a chair or bed, but there was no back pain, numbness or weakness. After taking oral analgesic and NSAIDs for years, left knee pain had not improved. Her underlying diseases were hypertension and renal calculi. She had just diagnosed aortic stenosis and regurgitation by echocardiography for 1 year, categorized in New York Functional Class I, and treated by oral medication of diuretic, ACEI and calcium-channel blocker.

The physical examination revealed a short stature woman, 120 cm in height and 38 kg in weight. Her left knee showed valgus alignment and painful crepitus on motion. The range of motion in flexion/extension was 95°/10°. No instability was found. Thorough physical examination demonstrated hyperpigmentation of sclerae, radial side of both index fingers and bluish-black tympanic membranes of both ears. She had passed dark urine since she was young. (Fig 1) The radiographic findings showed 15° valgus tibiofemoral angle, symmetrical narrow joint space, subchondral sclerosis and some osteophytes. (Fig 2) Routine preoperative laboratory showed unremarkable data. The provisional diagnosis of primary osteoarthritis of left knee was given.

She underwent cemented total knee arthroplasty by using lateral parapatellar approach. Posterior stabilized prostheses were implanted and patella was also resurfaced. Intraoperative findings showed black articular cartilage discoloration of femur, tibia and patella. The synovial tissue, menisci and cruciate ligaments were also bluish-black. (Fig 3) She had accidental crack of medial femoral epicondyle, which needed screw fixation and post-

operative hinged knee brace for 3 weeks. (Fig 2) The tissue histological evaluation confirmed ochro-notic staining of degenerate hyaline cartilage and fragments of cartilage deposited in synovial tissues.³ The yellow-brown pigments were surrounded with lots of inflammatory cells. (Fig 4)

Additional postoperative radiological examination of joints and spines were obtained. The pelvic radiographs revealed old fracture of

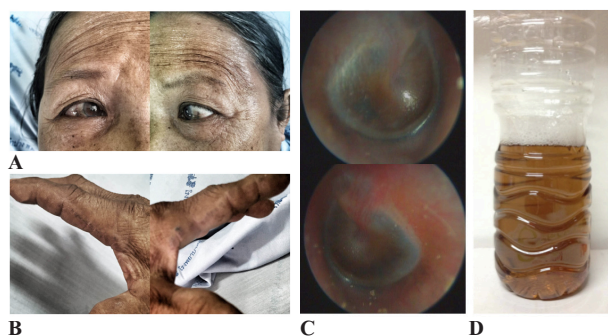


Fig 1. A) Hyperpigmented sclerae B) Hyperpigmentation at radial side of both index fingers C) Bluish-black tympanic membranes of both ears D) Acidic dark urine

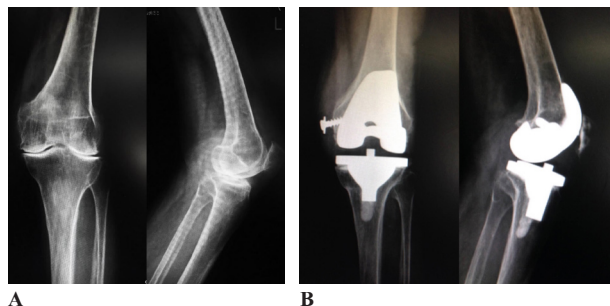


Fig 2. A) Preoperative plain radiographs of left knee show joint space narrowing and subchondral sclerosis B) Postoperative radiographs at 1-month follow-up

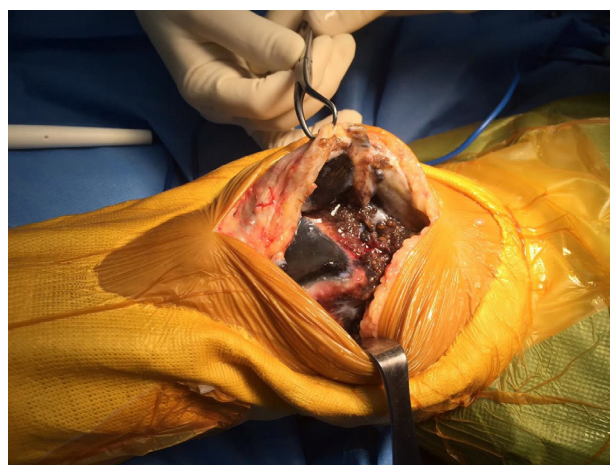

Fig 3. Intraoperative findings show bluish-black discoloration of articular cartilage and synovial tissue of left knee joint

right femoral neck. (Fig 5) She could not recognize how it occurred without previous traumatic event or significant right hip pain. The left hip showed flattening of femoral head and narrow joint space. Her right knee also had osteoarthritic change. Both shoulders showed advanced degeneration. The spine films showed multi-level intervertebral calcification and disc narrowing. (Fig 6) The urine sent to Molecular Genetics Diagnostic Center, Chulalongkorn University showed an extremely large amount of HGA through gas chromatography and mass spectrometry analysis. Her family tree was made and found no additional affected members with this disorder.

At the 5-week postoperative follow-up, knee ROM in flexion/extension was 70°/10°. Manipulation under anesthesia was performed and she could gain 95° of flexion. The Knee Society score and Knee Society function score of left knee improved from 26 to 87 points and 35 to 55 points respectively. She still walked with cane for preventing fall. Her hips conditions were further observed with symptomatic treatment and shoe lift.

DISCUSSION

Ochronotic arthropathy is a rare musculoskeletal disease. There are two etiologies of ochronosis; endogenous and exogenous. The endogenous cause is found in alkaptonuria, an autosomal recessive hereditary disorder with mutation of homogentisate 1,2-dioxygenase gene on chromosome 3q21-23. This results in lack of HGO enzyme to breakdown HGA. Excessive accumulation and renal excretion of HGA brings the dark urine as a dominant characteristic, firstly described by Scribonius in 1584.⁴ The excessive HGA also binds to collagen in connective tissue which makes it become weak and brittle with time, leading to chronic inflammation and degeneration. The exogenous cause is an avoidable dermatitis caused by some compounds such as topical phenol, topical hydroquinone bleaching creams, quinine injections, oral antimalarial drugs, amiodarone, cytotoxic drugs, minocycline, levodopa and methyl dopa.^{5,6} Absence of HGA excretion in urine makes it be distinguishable from the endogenous cause.

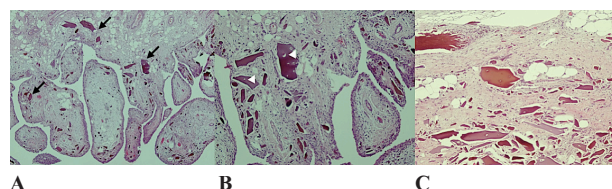


Fig 4. Histological examination reveals **A)** (4x) synovial tissue with brown pigment deposit (black arrows), **B)** (10x) cartilaginous cells (white arrow heads) inside the pigments, **C)** (10x) yellow-brown staining pigment with lots of surrounding inflammatory cells

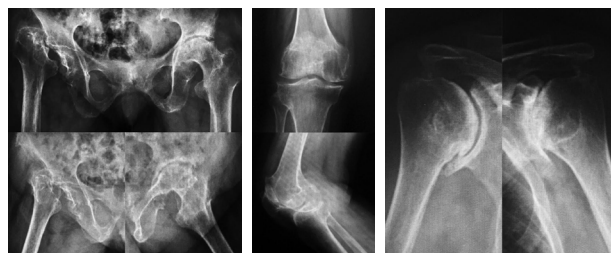

Fig 5. Plain radiographs of the patient show **A)** Old fracture of right femoral neck and flattening of left femoral head with narrowing joint space, **B)** Degenerative change of right knee, **C)** Advanced osteoarthritis of both shoulders

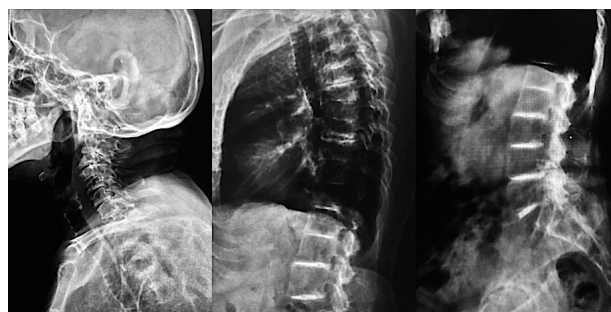

Fig 6. Plain radiographs of spine show multi-level of intervertebral calcification and narrowing disc space

There are many clinical presentations of ochronosis. The symptoms often begin in the fourth to fifth decades of life, with the accumulative time of pigment deposition and decrease in renal clearance of HGA with age.^{4,7} The disease progresses more rapidly in men than women.¹ The first symptom is dark urine which appears when urine HGA oxidizes with the exposed air. Some patients can be diagnosed as AKU at birth by discoloration of diapers. Second manifestation is the skin appearance in a high-concentration area of HGA deposition. The common areas are thenar and hypothenar eminence, side of finger,

eyelid, forehead, cheek, axilla, genital region, nail bed, buccal mucosa and sclera. Thirdly, the hyaline cartilage, a prominent feature is calcified ear cartilage on radiograph. Others are nasal, and laryngeal cartilage which can affect voice change, or costal cartilage which leads to decreased lung function. Fourthly, the articular cartilage of large joints in which the most dominant sites are knee, hip and shoulder respectively. Hand and foot are usually spared.⁹ Tendon and ligament can also be affected, mostly at the hand. An ongoing inflammation can lead to rupture. Valvular heart disease, mainly calcification and regurgitation of aortic and mitral valves, may occur. Valve replacement may be necessary in severe and progressive cases. Moreover, LS spine often shows pathognomonic signs of multi-level calcified intervertebral discs. Renal calculi probably form because of the extremely high level of urinary HGA excretion.¹ All symptoms can be grouped as classic triads which are dark urine at birth, ochronosis in the fourth to fifth decade of life and ochronotic arthropathy around the sixth decade. The confirmed laboratory test is the level of HGA in urine, blood and tissues.⁴

Ochronotic arthropathy of knee and hip usually brings the patient to orthopaedic surgeon and could be started with symptomatic treatment such as rest, physiotherapy, analgesic drugs and NSAIDs. Severe arthropathies mostly end up with total joint replacement. Only 24 cases of ochronotic patients receiving total knee arthroplasties have been reported in 21 literatures worldwide.^{2,3,6,8-13} Most of them were diagnosed intraoperatively with the unique findings of bluish-black articular cartilage, meniscus and synovium. To our knowledge, this patient is the first case report in Thailand. She was incidentally diagnosed as soon as capsulotomy exposed the striking discoloration of articular cartilage and soft tissue. Most previous reports demonstrated excellent outcomes of replacement surgery at the mean age of 55 years.¹ Ozmanevra et al reviewed 13 case reports with 21 TKAs published up to 2011.⁹ There were variations in the type of TKA; five with cemented, nine with cementless, and the remainings were not reported. Eleven of thirteen articles showed symptoms improvement after

TKA. Nevertheless, the black cartilage can heal with no difference from the normal bone, so the cementless prostheses rarely fails.² Spencer et al found no evidence of implant failure or complications after 11 replacements of knee, hip, shoulder and elbow in 3 patients with ochronotic arthritis at 6-12 years follow-up.³

There are some issues of concern about the excessive postoperative bleeding, probably from aggressive synovectomy, and spontaneous rupture of quadriceps tendon has been reported.^{13,14} Our patient had incomplete fracture of medial femoral epicondyle intraoperatively. This was probably from the excessive medial retraction during bone cuts. Medial soft tissue exposure in valgus knee is more difficult when using lateral parapatellar than medial approach. Moreover, in ochronotic knees the menisci are brittle and darkly stained, and the patellar tendon is stiff and attenuated, making patellar dislocation more difficult for surgical exposure.³

AKU is a rare hereditary disease with very low prevalence (1:100,000-250,000) in most ethnic groups.¹⁵ This patient is a sporadic case of AKU without family history. To date neither familial nor sporadic incidence has been specifically estimated. The most frequently cited article for AKU incidence was studied by Phornphutkul et al in 2002.¹ They estimated the current incidence of AKU to be 1 case in 250,000 to 1 million live births. So far, 950 AKU patients have been identified in 40 countries.¹⁶ Most of them have no central national register for this disease. We found only 3 literatures estimating national incidence in France (1:680,000), Slovakia and Dominican Republic (1:19,000).^{15,17,18} It is suggested that more widespread screening should be undertaken to assess the true incidence of this ultra-rare disease.

Currently there is no proven effective treatment for alkaptonuric ochronosis besides taking low tyrosine and phenylalanine diets to reduce the amount of toxic byproduct of HGA. High-dose ascorbic acid (100 mg/kg) is believed to reduce HGA excretion in urine by pressing the conversion of HGA to polymers, but it does not prevent the development of arthropathy.¹⁹ Clinical outcomes of long-term treatment with ascorbic acid (0.25 to 4 g/day) have varied, and overall it has not

been dramatically effective, although controlled trials have never been conducted.²⁰ The benefit of nitisinone which is an inhibitor of HGO is not clear, although it was approved by the U.S. Food and Drug Administration in 2002 for the treatment of hereditary tyrosinemia.^{20,21} Introne et al performed a randomized therapeutic trial in 40 alkaptonuric patients with nitisinone for 3 years. The results showed benefit in decreasing HGA levels in plasma and urine. Nevertheless, hip range of motion and musculoskeletal functions were not different from the untreated group.²²

CONCLUSION

Alkaptonuric ochronosis is a musculoskeletal manifestation that causes discoloration and weakness of connective tissues. It is an uncommon cause of progressive arthropathy that is usually diagnosed from intraoperative findings. This disease could be potentially misdiagnosed as primary osteoarthritis unless thorough history taking and physical examination were achieved. Although the evidences of best treatment for these patients are still lacking, joint replacement surgery provides satisfactory and effective outcomes to improve quality of life.

ACKNOWLEDGMENTS

The authors wish to thank Chanika Phornphutkul, M.D. for reviewing manuscript and Vorasuk Shotelersuk, M.D. for urine organic acid analysis and advice.

REFERENCES

- Phornphutkul C, Introne WJ, Perry MB, Bernardini I, Murphey MD, Fitzpatrick DL, et al. Natural history of alkaptonuria. *N Engl J Med* 2002;347:2111-21.
- Ulucay C, Ozler T, Altintas F, Inan M, Onur A, Kocadal AO. Arthroplasty in ochronosis "tips and pearls in surgery": case series. *J Arthritis* 2013;3:116.
- Spencer J, Gibbons CLM, Sharp R, Carr A, Athanasou N. Arthroplasty for ochronotic arthritis no failure of 11 replacements in 3 patients followed 6-12 years. *Acta Orthop Scand* 2004;75:355-8.
- Kural C, Centinus EM, Kural A, Ugras AA, Kaya I. Knee orthonotic arthropathy and arthroscopic findings. *Acta Orthop Traumatol Turc* 2009;43:67-71.
- Levin CY, Maibach H. Exogenous ochronosis: an update on clinical features, causative agents and treatment options. *Am J Clin Dermatol* 2001;2:213-7.
- Mota PT, Candido R, Pintado C. Alkaptonuria, a rare cause of osteoarthritis- case report. *JSM Clin Case Rep* 2015;3: 1083.
- Mwambingu TL, Hide G. Case 208: alkaptonuria. *Radiology* 2014;272:608-11.
- Chang SS, Ek ET, Pilatsios V. Black bones: a case of incidental discovery of ochronotic arthropathy. *Med J Aust* 2009; 190:390.
- Ozmanevra R, Guran O, Karatosun V, Gunal I. Total knee arthroplasty in ochronosis: a case report and critical review of the literature. *Ekiem Hastalik Cerrahisi* 2013;24:169-72.
- Acar MA, Erkocak OF, Aydin BK, Altan E, Senaran H, Elmadag NM. Patients with black hip and black knee due to ochronotic arthropathy: case report and review of literature. *Oman Med J* 2013;28:448-9.
- Ferreira AMDSM, Santos FL, Costa AMC, Barbosa BMPB, Rocha RMR, Lebre JFF. Knee osteoarthritis secondary to ochronosis- clinical case. *Rev Bras Ortop* 2014; 49:675-80.
- Sivakumar R, Somashekar V, Chidambaram M, Prahalad KS. Ochronosis of the knee treated with total knee arthroplasty: a case report. *Int J Basic Appl Med Sci* 2015;5:264-7.
- Patel VG. Arthroplasty in patients with rare conditions- total knee arthroplasty in ochronosis. *Arthroplasty Today* 2015; 1:77-80.
- Chua SY, Chang HC. Bilateral spontaneous rupture of quadriceps tendon as an initial presentation of alkaptonuria- a case report. *Knee* 2006;13:408-10.
- Aquaron RR. Alkaptonuria in France: past experience and lessons for the future. *J Inher Metab Dis* 2011;34:111-26.
- The AKU Society and the DevelopAKU Consortium. Develop AKU: 950 AKU patients [Internet]. Cambridge (UK); 2014 [cited 2016 Mar 28]. Available from: <http://www.developakure.eu/950-aku-patients/>
- Milch RA. Studies of alcaptonuria: inheritance of 47 cases in eight highly inter-related Dominican kindreds. *Am J Hum Genet* 1960;12:76-85.
- Srsen S, Varga F. Screening for alkaptonuria in the newborn in Slovakia. *Lancet* 1978;2(8089):576.
- Cetinus E, Cever I, Kural C, Erturk H, Akyildiz M. Ochronotic arthritis: case reports and review of the literature. *Rheumatol Int* 2005;25:465-8.
- Kraus VB. Rare osteoarthritis: ochronosis and Kashin-Beck disease. In: Hochberg MC, Silman AJ, Smolen JS, Weinblatt ME, Weisman MH, editors. *Rheumatology*. 6th ed. Philadelphia: Mosby Elsevier; 2013. p.1536-40.
- Suwanarat P, O'Brien K, Perry MB, Sebring N, Bernardini I, Kaiser-Kupfer MI, et al. Use of nitisinone in patients with alkaptonuria. *Metabolism* 2005;54:719-28.
- Introne WJ, Perry MB, Troendle J, Tsilou E, Kayser MA, Suwanarat P, et al. A 3-year randomized therapeutic trial of nitisinone in alkaptonuria. *Mol Genet Metab* 2011;103: 307-14.