

# Multistages and Reinfection of Syphilis: A Case Report with Jarisch Herxheimer Reaction

Pimchaya Udomphan, M.D., Sukhum Jiamton, M.D., M.Sc., Ph.D.

Department of Dermatology, Faculty of Medicine Siriraj Hospital, Mahidol University, Bangkok 10700, Thailand.

## ABSTRACT

Multistage and reinfection of syphilis, which developed genital chancre after secondary syphilis is an uncommon manifestation. Among HIV-positive MSM, concurrent primary chancres with secondary syphilis are common. The Jarisch-Herxheimer reaction (JHR) is a transient immunological phenomenon and increases in incidence among HIV patients. This report demonstrates a case of secondary syphilis and reinfection in a 19-year-old Thai male who presented with multiple erythematous maculopapular rashes on trunk, extremities, palms and soles for 5 days and then had multiple painless genital ulcers 2 days later. He developed Jarisch-Herxheimer reaction after the treatment.

**Keywords:** Multistage and reinfection of syphilis; Jarisch Herxheimer reaction

Siriraj Med J 2016;68:310-312

E-journal: <https://www.tci-thaijo.org/index.php/sirirajmedj>

## INTRODUCTION

Syphilis is a sexually transmitted infection caused by the spirochete *treponema pallidum* and humans are the only natural host<sup>1</sup>. The patients with this intermittently active disease may present with various stages such as primary syphilis characterized by one or more chancres, secondary syphilis which may be localized or diffuse mucocutaneous lesion such as maculopapular rash<sup>2</sup>, roseola syphilitica, lichenoid syphilitic eruption, or patchy nonscarring alopecia described as moth-eaten and generalized lymphadenopathy. Both primary and secondary syphilis is indicated by the presence of laboratory evidence from tissue or serum consistent with syphilis. Latent syphilis is an asymptomatic stage which has no clinical

finding. The seroactivity is by definition the only evidence of infection. Tertiary syphilis diagnosed using CSF examination is an inflammatory lesion of neurological system, cardiovascular system, skin, or bone.<sup>3</sup>

Recently, an increase in the rate of syphilis has been observed in men who have sex with men (MSM) who have HIV coinfection<sup>4</sup>. In Thailand, syphilis has been considered to be a major sexually transmitted infection. Prevalence of syphilis in MSM is significantly associated with younger age and HIV infection. Moreover, in the early stage of syphilis, VDRL titer is higher than 1:32<sup>5</sup>. Men infected with HIV and genital ulcers resulting from syphilis may have secondary syphilis with concurrent primary chancres, and also have multiple chancres<sup>3</sup>.

## CASE REPORT

A 19-year-old Thai male presented at the Dermatologic clinic, Faculty of Medicine Siriraj

Correspondence to: Pimchaya Udomphan

E-mail: [toktak.udomphan@gmail.com](mailto:toktak.udomphan@gmail.com)

Received 18 December 2015

Revised 31 March 2016

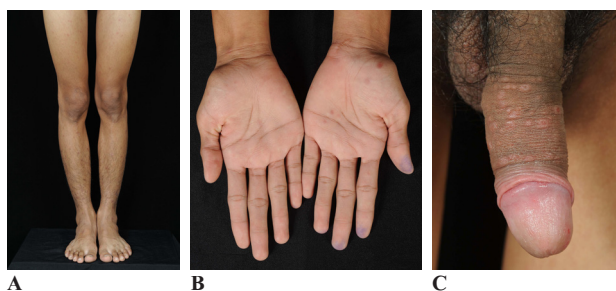
Accepted 7 April 2016

Hospital with multiple non itching erythematous maculopapular lesions on trunk, extremities, palms and soles which had appeared for 5 days. Two days later, he developed multiple painless ulcers on his genitalia. He has had sexual relationships with men over the past few years. Physical examination revealed generalized discrete erythematous maculopapular rash on his trunk, both upper and lower extremities including his palms and soles. He also had multiple painless shallow ulcers on the penile shaft and glans penis and multiple bilateral painless inguinal lymphadenopathy. Examination on his cardiovascular and neurological system was within a normal limit. Dark field microscopy of secretion from base of genital ulcers demonstrated spirochetes. Tzanck smear and gram's stain revealed negative findings. Blood test for VDRL was positive with titer of 1:32 and TPHA titer was less than 1:80. Blood test for anti-HIV was positive.

The treatment in this case was benzathine penicillin G 2.4 million units administered intramuscularly in a single dose and 4 hours later he developed fever with chill, headache, hypotension and flare of erythematous maculopapular rash on trunk and extremities. He came to a community hospital and the basic laboratory tests were normal, (complete blood count and platelet count, blood urea nitrogen, creatinine, electrolyte, liver function test, urine analysis). He received symptomatic and supportive treatment.

## DISCUSSION

Multistage and reinfection of syphilis is an uncommon manifestation of syphilis. Secondary syphilis with concurrent primary chancre is more




**Fig 1** A, B, generalized discrete erythematous maculopapular rash on both legs and palms C) multiple painless shallow ulcers on the penile shaft and glans penis.

likely to develop in HIV-infected men than men without HIV infection<sup>6</sup>. This may be due to more rapid progression of the disease from primary to secondary stage in HIV infected patients or delayed healing of genital ulcer<sup>7</sup>.

However, in this case, the genital chancre was developed after secondary syphilis and his history of unsafe sex was about 20 days before the chancre was developed. It was more likely to be secondary syphilis with reinfection because he always checked his whole body when he took a bath every morning and detected the genital ulcer after the rash. The other causes for developing chancre after secondary syphilis are chancre redux<sup>8</sup>, concurrent infection of primary with secondary syphilis that is asymptomatic and often is unnoticeable. There has been data report for the same disease pattern like this patient.

In this case, the patient had complication of the treatment. The reaction occurred within 4 hours after the administration of benzathine penicillin G. He had fever with chill, headache, hypotension and exacerbation of existing cutaneous lesions. The Jarisch Herxheimer reaction (JHR) is a self-limited clinical syndrome which occurs within 3-12 hours and resolves within 24-36 hours. The pathogenesis of JHR is still unknown. It has been proposed that endotoxin-like materials (lipoprotein) from degenerating *T. pallidum* following treatment of syphilis with the sensitized syphilis tissue can cause aggravation of the lesion<sup>9</sup>. Another proposed etiologic theory



**Fig 2.** Dark-field microscopy of penile ulcer: *Treponema pallidum* move with a characteristic forward and backward motion with rotation.

of the JHR involves massive phagocytosis by mononuclear cells which results in the release and transient elevation of pyrogenic cytokines, such as TNF-alpha (first to rise), IL-6 (rises at the onset of symptoms), and IL-8 (last to rise) in different stages of JHR, thus causing the different symptoms of the reaction<sup>10</sup>. The symptoms of JHR are strongly associated with these cytokine elevations. The JHR must be differential diagnosis from a drug reaction, especially to penicillin. Risk factors of JHR are early syphilis patients who have high RPR titers<sup>10</sup>, secondary and latent syphilis treated<sup>11</sup>. This case was also early syphilis and high VDRL titer. The treatment of JHR is symptomatic such as complete bed rest, fluids resuscitation and antipyretic drugs. The JHR can be prevented with TNF-alpha antibodies and in some case, steroids. Other premedications such as acetaminophen and meptazinol may reduce the symptoms or duration of the JHR<sup>10</sup>.

## ACKNOWLEDGMENTS

The authors are grateful to Dr. Sukhum Jiamton, of Dermatopathology Unit, Dermatology Department, Faculty of Medicine Siriraj Hospital, Mahidol University for additional patient's information.

## REFERENCES

1. Lafond RE, Lukehart SA. Biological basis for syphilis. *Clin Microbiol Rev* 2006;19:29-49.
2. Rompalo AM, Joesoef MR, O'Donnell JA, Augenbraun M, Brady W, Radolf JD, et al. Clinical manifestation of early syphilis by HIV status and gender: Results of the syphilis and HIV study. *Sex Transm Dis* 2001;28:158-65.
3. CDC. Case definitions for infectious conditions under public health surveillance. *MMWR Recomm REP* 2015; 64:34-51.
4. Read P, Fairley CK, Chow EP. Increasing trends of syphilis among men who have sex with men in high income countries. *Sexual Health* 2015;12(2):155-63.
5. Jiamton S, Prasertworonum N, Maneeprasopchoke P, Omcharoen V. Clinical and epidemiological characteristics of patients with syphilis: 5 year-case study from Thailand. *J Med Assoc Thai* 2014;9:97-102.
6. Rompalo AM, Lawlor J, Seaman P, Quinn TC, Zenilman JM, Hook EW. Modification of syphilitic genital ulcer manifestations by coexistent HIV infection. *Sex Transm Dis* 2001;28:440-54.
7. Hutchinson CM, Hook EW, Shepherd M, Verley J, Rompalo AM. Altered clinical presentation of early syphilis in patients with human immunodeficiency virus infection. *Ann Intern Med* 1994;121:94-9.
8. Eccleston K, Collins L, Higgins SP. Primary syphilis. *Int J STD AIDS* 2008;19:145-51.
9. Gelfand JA, Elin RJ, Berry Jr FW, Frank MM. Endotoxemia associated with the Jarisch-Herxheimer reaction. *N Engl J Med* 1976;295:211-13.
10. Belum GR, Belum VR, Aruda SK. The Jarisch-Herxheimer reaction: Revised. *Travel Med Infect Dis* 2010;11:231-7.
11. Li J, Wang LN, Zheng HY. Jarisch-Herxheimer reaction among syphilis patients in China. *J Eur Acad Dermatol Venereology* 2013;10:1304-7.