

Ultrasonographic Evaluation of Cervical Length, Cervical Volume and Cervical Vascularization between 18 and 40 Weeks of Gestation

Chutarat Sirichareon, M.D., Sakita Mounghmaithong, M.D.

Division of Maternal Fetal Medicine, Department of Obstetrics and Gynecology, Faculty of Medicine Siriraj Hospital, Mahidol University, Bangkok 10700, Thailand.

ABSTRACT

Objective: To evaluate the correlation of cervical length, cervical volume and cervical vascularization during pregnancy using 3D power Doppler ultrasonography, and to examine the reliability of these measurements.

Methods: This is a cross-sectional study of 196 pregnant women who delivered at term and had undergone transvaginal 3D power Doppler ultrasonographic examination of the cervix once between 18 and 40 weeks' gestation. Cervical length, cervical volume, vascularization index (VI), flow index (FI) and vascularization flow index (VFI) were measured and calculated. The reliability of the measurements was also evaluated.

Results: Mean cervical length and volume were 35.2 mm. and 28.2 cm³. Mean cervical VI, FI and VFI were 2.65, 38.44 and 1.07, respectively. Cervical length and cervical volume significantly decreased during pregnancy (Spearman's rank correlation coefficient, $Rho = -0.422$ and -0.514 , respectively, correlation significant <0.01). There was a minimal change in the vascular flow indices between 18 and 40 weeks' gestation (Spearman's rank correlation coefficient, Rho , varied from 0.010 to 0.042). Both intraobserver and interobserver agreement for cervical volume measurements were excellent with intraclass correlation coefficient (ICC) values of 0.96, and 0.95 respectively. Intraobserver and interobserver agreement for vascular flow indices measurements were good.

Conclusion: Cervical length and volume significantly decreased with gestational age. Cervical vascularization tends to be increased, but without statistical significance. The measurements were reliable.

Keywords: 3D power Doppler transvaginal ultrasonography in pregnancy; cervical length; cervical volume; cervical vascularization; reliability

Siriraj Med J 2016;68:299-304

E-journal: <https://www.tci-thaijo.org/index.php/sirirajmedj>

INTRODUCTION

Preterm delivery is defined as a delivery at less than 37 weeks of gestation, with the prevalence of 13-15%.^{1,2} Although prediction of preterm delivery has considerably improved, the incidence of spontaneous preterm

delivery continues to rise even in low risk pregnancies. The most effective method to identify pregnancies at risk of preterm delivery is transvaginal ultrasonographic assessment of cervical length.^{3,4} Pregnancy with the diagnosis of short cervix (cervical length less than 25 mm) might have benefit from vaginal or oral administration of progesterone to prolong gestational age.⁵

Cervical remodeling leading to labor, includes increased softness and blood supply.⁶ Changes in tissue perfusion reflected as blood cells movement can be reliably assessed with

Correspondence to: Sakita Mounghmaithong

E-mail: sakitamfm@gmail.com

Received 23 March 2016

Revised 10 June 2016

Accepted 12 July 2016

vascular indices and therefore it would be valuable to know how cervical blood circulation changes during pregnancy.⁷

The three-dimensional (3D) ultrasound technique became clinically available at the beginning of the 1990s. 3D ultrasonography has the potential to provide more accurate volume measurements than does conventional two-dimensional (2D) ultrasonography.⁸ 3D power Doppler ultrasonography may be a more appropriate method for quantification of blood supply to an organ than 2D power Doppler ultrasonography.⁹ For example, it has been used in the assessment of the cervix in pregnancy¹⁰⁻¹², assessment of the quantifications of vascularity in the placenta,¹³ in precancerous lesions and in cervical cancer.^{14,15} The interobserver and intraobserver reproducibility of cervical volume calculations and quantification of power Doppler signals in cervical volumes obtained by 3D scanning of the cervix in pregnant women have been determined.¹⁶ However, only few literatures have been published on the correlation of cervical length, cervical volume and vascular flow indices during pregnancy. However, it is not clear that these indices accurately reflect the degree of cervical vascularization during pregnancy. The aim of this study was to evaluate the correlation of the cervical length, cervical volume and vascular flow indices during pregnancy using 3D power Doppler ultrasonography, and to assess the reliability of these measurements.

MATERIALS AND METHODS

Between September 1st, 2014 and January 31st, 2015, a total of 196 pregnant women were enrolled in the study. The Ethics Committee of Siriraj Hospital, Mahidol University, Thailand, had approved the study protocol (Si.461/2014). Informed consent was obtained from all of the pregnant women involved in the study after the detail of the procedures had been fully explained. Inclusion criteria included maternal age more than 18 years old, singleton pregnancy, gestational age (determined by first or second trimester ultrasonography) between 18 and 40 weeks. The exclusion criteria were spontaneous delivery at less than

37 weeks gestation, previous cone biopsy of the cervix, progesterone usage during pregnancy, medical complications and fetal anomalies.

After routine ultrasound scanning, the pregnant women were asked to empty their bladders and were placed in the lithotomy position. Three-D sonographic studies were performed with a Voluson E8 (GE Medical, USA) with 2.8-10-MHz transvaginal transducer and a 146° field of view. Identical preinstalled ultrasound settings were used, the power Doppler settings being: frequency 3–9 MHz, pulse repetition frequency 0.6 kHz, gain -4.6, wall motion filter “low 1”. The transvaginal ultrasound probe was slowly introduced into the vagina. The cervical length was measured by 2D by using the technique described by K.O. Kagan.¹⁷ Then the power Doppler ultrasound color box was positioned in the same plane, and kept as small as possible to include only the cervix from the internal to the external os. The system was switched into the power Doppler mode and then into the 3D mode. The cervix was centralized within the 3D sector appearing on the ultrasound screen, and data set of volume data were obtained by holding the transducer steadily while its crystals were mechanically rotated across the sector during the sweeping process with a sweep angle of 90°. The duration of the volume acquisition was 10-15 seconds depending on the dimensions of the 3D sector. The scanned volumes were stored digitally for off-line analysis. The virtual organ computer-aided analysis (VOCALTM) software, which is integrated into the Voluson E8 (GE Medical, USA) ultrasound system, was used to calculate cervical volume (mm³) and power Doppler flow indices from the orthogonal multiplanar views of the cervix obtained from the volume acquired (Fig 1). The contour mode in the VOCALTM program was set as manual. Drawing started from a longitudinal section through the cervix. The rotation steps were 30°, i.e. 6 contours of the cervix were drawn manually. Once all contours had been drawn, the volume of the cervix was calculated automatically. Using the histogram facility of the VOCALTM software, the following Doppler flow indices were calculated: vascularization index (VI), flow index (FI) and vascularization flow index (VFI) (Fig 2).

Mean values for cervical length, cervical volume and vascular flow indices are shown in the Table 2. Mean cervical length and cervical volume were 35.2 mm. and 28.2 cm³, respectively. The mean cervical VI, FI and VFI were 2.65, 38.44 and 1.07, respectively.

The cervical length and cervical volume change with gestational age, were shown in Fig 3. Both changes significantly decreased during pregnancy (Spearman's rank correlation coefficient, $Rho = -0.422$ and -0.514 , respectively, correlation significant <0.01). The cervical vascular flow indices also changed with gestational age as shown in Fig 4. There was a minimal change in the vascular flow indices between 18 and 40 weeks' gestation (Spearman's rank correlation coefficient, Rho , varied from 0.010 to 0.042).

TABLE 1. Intraobserver and interobserver differences between the measurements of cervical volume and vascularization.

Measurement	ICC
Intraobserver differences	
Cervical volume	0.967
Vascularization index (VI)	0.994
Flow index (FI)	0.984
Vascularization flow index (VFI)	0.991
Interobserver differences	
Cervical volume	0.957
Vascularization index (VI)	0.977
Flow index (FI)	0.941
Vascularization flow index (VFI)	0.973

TABLE 2. Mean values for cervical length, cervical volume and vascularization indices.

Measurements	Mean \pm SD
Cervical length	35.2 \pm 8.3 mm
Cervical volume	28.2 \pm 9.7 cm ³
Vascularization index (VI)	2.65 \pm 2.01
Flow index (FI)	38.44 \pm 7.30
Vascularization flow index (VFI)	1.07 \pm 0.88

TABLE 3. Cervical length measurement during second trimester.

GA (weeks)	Minimum	Maximum	Mean	SD
18-20 ⁺⁶	29.80	45.20	38.09	3.62
20-22 ⁺⁶	29.10	53.10	39.71	6.66
22-24 ⁺⁶	27.50	49.80	37.74	6.18

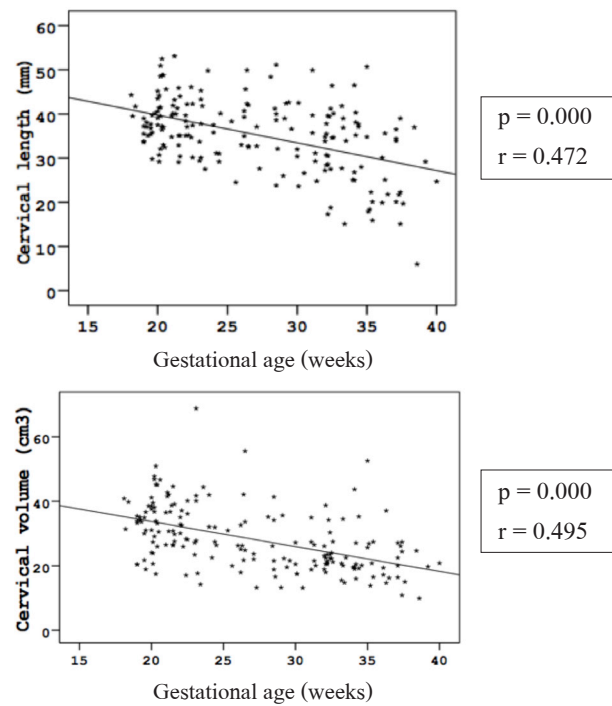


Fig 3. Correlation between cervical length and cervical volume during pregnancy.

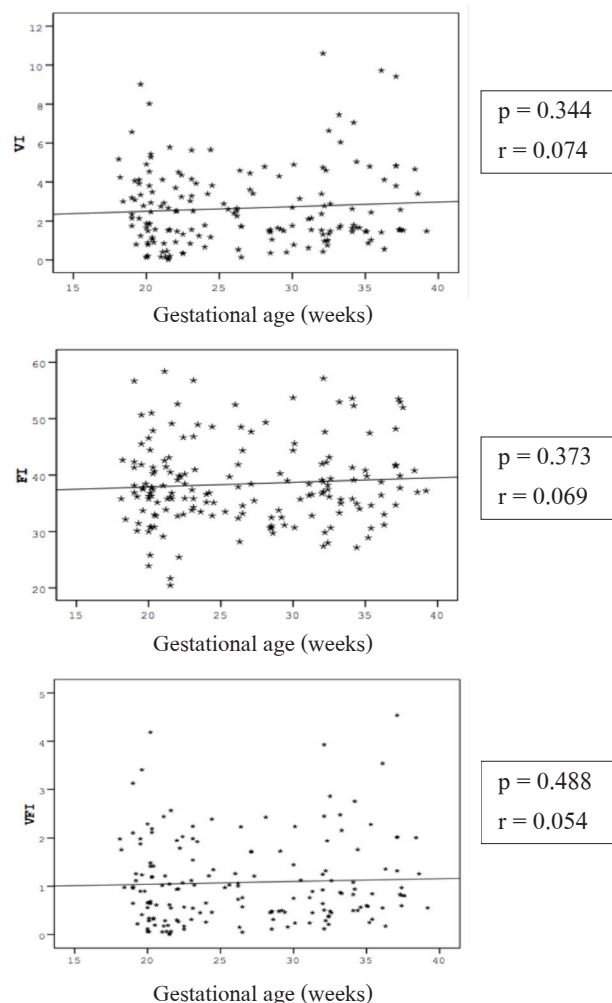


Fig 4. Correlation between cervical vascularization during pregnancy.

DISCUSSION

Our study showed that cervical blood perfusion can be assessed reliably by 3D power Doppler ultrasound measurements. After one-month training of data acquisitions, volumetric measurement and vascularity indices measurement of the first operator by the second operator, we conducted the intraobserver and interobserver reliability on the first thirty subjects from recorded volume data. Intraobserver reliability was performed from two different data acquisitions by the first operator while intraobserver reliability was established by the second operator via the off-line analysis of collected volume data previously acquired by the first operator. Both cervical volume and cervical vascularization have acceptable intraobserver and interobserver variations which were comparable with the previous study.¹⁶

Samutchaikij T, et al.¹² performed a study in Thai pregnant women between 18 and 24 weeks of gestation and found that the reference value of cervical length and cervical volume was 42 mm. and 31.6 cm³, respectively. In our study, when subgroup analysis was done for the same period of gestation and cervical length measurement of this subgroup as shown in Table 3, we found that mean cervical length and cervical volume were 38.5 mm. and 33.34 cm³ respectively, which were slightly shorter, but slightly larger than the previous study. They also found that the reference value for cervical VI, FI and VFI were 6.4, 38.9 and 2.6, respectively. However, we found that mean cervical VI, FI and VFI were 2.58, 38.31 and 1.06, respectively which may be explained by the difference in the initial machine setting of the studies and number of the study population during this gestational period in each study. However, FI seems to have the most promising repeatability among these vascularization indices.

Rovas L, et al.¹¹ found no change in cervical volume during gestation, but we found that in Thai pregnant women, cervical length and cervical volume significantly decreased with gestational age. Also in the same study, they found that, cervical VI, FI and VFI did not change consistently from 17

to 41 weeks of gestation. Our study demonstrated that cervical vascularization tends to be increased, but there was no statistical significance. It may possibly be explained that vascular changes were too small to become detectable with 3D power Doppler ultrasound technique. The exact reasons for the differences in the volume and vascularization between these studies is unclear and could possibly be caused by the heterogeneity of the study design, differences of the targeted period of gestation and variety of the 3D power Doppler techniques or settings. However, a further study with longitudinal design may be more appropriate for the evaluation of cervical vascularization.

In summary, we present the change of cervical length, cervical volume and cervical vascularization during pregnancy using 3D power Doppler ultrasonography. They may be used in conjunction with cervical length measurement during the second trimester period for the prediction of preterm labor.

What is already known on this topic?

Cervical softening and shortening are the major predictors of preterm labor. Cervical length decreases with gestation and was integrated as a part of the routine clinical practice. However, changes in cervical volume and cervical vascularization throughout pregnancy were obscured.

3D power Doppler is a relatively new technique which has been explored for several years for its clinical application. Placenta and cervix were the most important organs which have been investigated. Previous study revealed good reproducibility of this technique. There was no significant change in vascularity indices related with gestational age.

What this study adds?

Cervical volume decreased significantly as the pregnancy progressed which was similar to cervical length. On the other hand, cervical vascularity indices tend to be stable throughout pregnancy which limited the potential to use these as predicting parameter of preterm labor.

REFERENCES

1. Division of Obstetric and Gynecologic Registry, Department of Obstetrics and Gynecology, Faculty of Medicine Siriraj Hospital, Mahidol University. Obstetric and Gynecologic Registry Annual Statistical Report 2013, Bangkok; 2014.
2. Haram K, Mortensen JH, Wollen AL. Preterm delivery: an overview. *Acta Obstet Gynecol Scand* 2003;82:687-704.
3. Committee on Practice Bulletins-Obstetrics, The American College of Obstetricians and Gynecologists. Practice Bulletin no.130: prediction and prevention of preterm birth. *Obstet Gynecol* 2012;120:964-73.
4. Feltovich H, Hall TJ, Berghella V. Beyond cervical length: emerging technologies for assessing the pregnant cervix. *Am J Obstet Gynecol* 2012;207:345-54.
5. Society for Maternal-Fetal Medicine Publications Committee. Progesterone and preterm birth prevention: translating clinical trials data into clinical practice. *Am J Obstet Gynecol* 2012;206:376-86.
6. Eldridge-White R, Easter RA, Heaton DM, O'Day MB, Petersen GC, Shanks RD, et al. Hormonal control of the cervix in pregnant gilts. I. Changes in the physical properties of the cervix correlate temporally with elevated serum levels of estrogen and relaxin. *Endocrinology* 1989;125:2996-3003.
7. Ierullo AM, Fernandez S, Palacio M, Gratacos E, Hernandez-Andrade E. Cervical blood perfusion assessed using power Doppler-derived estimation of fractional moving blood volume: a reproducibility study. *Ultrasound Obstet Gynecol* 2011;38:57-61.
8. Hoesli IM, Surbek DV, Tercanli S, Holzgreve W. Three dimensional volume measurement of the cervix during pregnancy compared to conventional 2D-sonography. *Int J Gynecol Obstet* 1999;64:115-9.
9. Alcázar JL. Three-dimensional power Doppler derived vascular indices: what are we measuring and how are we doing it? [opinion]. *Ultrasound Obstet Gynecol* 2008;32:485-7.
10. Rovas L, Sladkevicius P, Strobel E, Valentin L. Three-dimensional power Doppler ultrasound assessment of the cervix for the prediction of successful induction of labor with prostaglandin in prolonged pregnancy. *J Ultrasound Med* 2005;24:933-9.
11. Rovas L, Sladkevicius P, Strobel E, Valentin L. Reference data representative of normal findings at three-dimensional power Doppler ultrasound examination of the cervix from 17 to 41 gestational weeks. *Ultrasound Obstet Gynecol* 2006;28:761-7.
12. Samutchaikij T, Pitukijronnakorn S, Panburana P. Normal reference of cervical blood perfusion in pregnancy. *J Med Assoc Thai* 2014;97:369-73.
13. Jeong NH, Yang KY, Seol HJ. A longitudinal study of three-dimensional ultrasonographic assessment of the placenta in uncomplicated pregnancies. *Korean J Obstet Gynecol* 2012;55:454-60.
14. Belitsos P, Papoutsis D, Rodolakis A, Mesogitis S, Antsaklis A. Three-dimensional power Doppler ultrasound for the study of cervical cancer and precancerous lesions. *Ultrasound Obstet Gynecol* 2012;40:576-81.
15. Hsu KF, Su JM, Huang SC, Cheng YM, Kang CY, Shen MR, et al. Three-dimensional power Doppler imaging of early-stage cervical cancer. *Ultrasound Obstet Gynecol* 2004;24:664-71.
16. Basgul A, Kavak ZN, Bakirci N, Gokaslan H. Intra- and interobserver agreement on cervical volume and flow indices during pregnancy using transvaginal 3-dimensional ultrasonography and Doppler angiography. *Int J Fertil Womens Med* 2006;51:256-61.
17. Kagan KO, Sonek J. How to measure cervical length? *Ultrasound Obstet Gynecol* 2015;45: 358-62.