

Successful Rescue Cervical Cerclage in Patient with Advanced Cervical Dilatation in Second Trimester: A Case Report

Pavit Sutthritpongsa, M.D., Prapat Wanitpongpan, M.D.

Department of Obstetrics and Gynecology, Faculty of Medicine Siriraj Hospital, Mahidol University, Bangkok 10700, Thailand.

ABSTRACT

Background: Rescue cervical cerclage is a treatment of choice for management of cervical incompetence in the patient with advanced cervical dilatation and membranes bulging in second trimester of gestation, but this type of procedure is technically difficult and associates with high failure rate.

Objective: To describe the technique of rescue cervical cerclage in a patient with advanced cervical dilatation.

Methods: A 36-year-old Thai woman, gravida 1, 22 weeks and 3 days of gestation was admitted due to cervical dilatation with bulging of membranes. A successful rescue cervical cerclage was performed without complication.

Results: The patient delivered a healthy female infant at 33 weeks and 4 days of gestation vaginally after removal of cerclage.

Conclusion: Rescue cervical cerclage is a treatment of choice for management of cervical incompetence in a patient with advanced cervical dilatation and membranes bulging in second trimester of gestation.

Keywords: Cervical cerclage, rescue cervical cerclage, cervical incompetence, McDonald cerclage procedure

Siriraj Med J 2016;68:183-186

E-journal: <http://www.sirirajmedj.com/ojs>

INTRODUCTION

Rescue cervical cerclage is a treatment of choice for management of cervical incompetence in a patient with advanced cervical dilatation and membranes bulging in second trimester of gestation. Due to the difficulty of the procedure along with high failure rate and poor obstetrics outcomes, this type of surgery has remained controversial. However, without this procedure, the loss of pregnancy is definitely inevitable.¹⁻³ The author reported a case of successful rescue cervical cerclage in a patient

with approximately 6-7 centimeters cervical dilatation with bulging membranes in second trimester of gestation.

CASE REPORT

A 36-year-old Thai woman, gravida 1, 22 weeks and 3 days of gestation, with history of prolonged infertility for 7 years, was admitted to the Department of Obstetrics and Gynecology, Faculty of Medicine Siriraj Hospital due to cervical dilatation with bulging of membranes in September 2011. She had minimal vaginal bleeding without lower abdominal pain or uterine contraction. Vaginal examination revealed 6-7 cm cervical dilatation with bulging of the membranes into vagina. She had no fever or evidence of any infection. Her prenatal record was normal. There

Correspondence to: Pavit Sutthritpongsa

E-mail: pavitjug@gmail.com

Received 22 July 2015

Revised 9 November 2015

Accepted 10 November 2015

was no evidence of fetal anomaly on level 2 sonography and her prenatal diagnosis revealed 46 XX chromosomes. The patient and her husband had a strong fertility desire with a high expectation in this pregnancy. After detailed counseling for rescue cervical cerclage, although the outcome of the procedure was frequently poor in the case with advanced cervical dilatation, without cerclage, fetal miscarriage was inevitable so they accepted for the procedure and its possible complications.

A rescue cervical cerclage was performed the next day. After spinal anesthesia, the patient was set on deep Trendelenburg with lithotomy position. The anterior and posterior vaginal retractor was gently placed into vagina and revealed a bulging of membranes through a 7-cm-dilated cervix to mid-vaginal level (Fig 1). The protruded membranes were gently pushed back into the uterus by using a long sponge holder grasping a 14F Foleys catheter. After the membranes were pushed high enough above the internal cervical os, the Foleys' balloon was filled up with 30 cc of normal saline to maintain the position of the membranes (Fig 2). Then the sponge holder was removed. The cervical edges were identified and then grasped with two sponge holders at anterior and posterior portions of the cervix. Then the McDonald cerclage procedure was performed. The two-needle Mersilene cord tape (Cervix-set B Braun) were stitched on the cervix at 5, 7, 2 and 10 o'clock respectively as high as possible at cervico-vaginal junction, then the suture was tied at 12 o'clock and the Foleys' balloon was deflated and removed. Figure 3 showed the cervix after rescue cervical cerclage. No postoperative complication was observed. The patient received tocolytic drug and intravenous antibiotics for 1 day and oral NSAIDs for 7 days. She was discharged 4 days after cerclage.

At 33 weeks and 4 days of gestation, she had preterm labor and cervical dilatation. The cerclage was removed, and the patient received corticosteroid to promote fetal lung maturity with antibiotic prophylaxis for group B Streptococci. She had spontaneous vaginal delivery and a female 1,690 grams infant was born with Apgar scores 9, 10. She and her baby had an uneventful recovery and were discharged 5 days later.

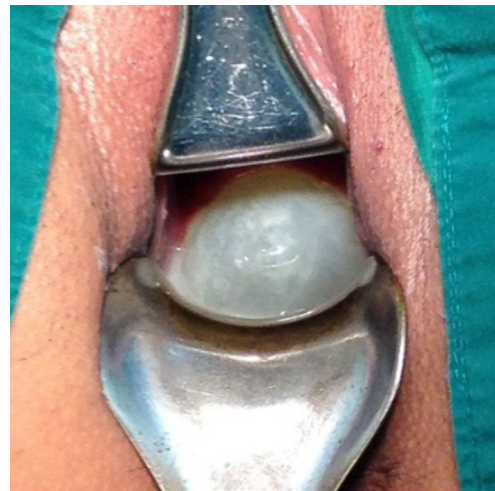

Fig 1. Demonstrated dilated cervix with protruded membranes.

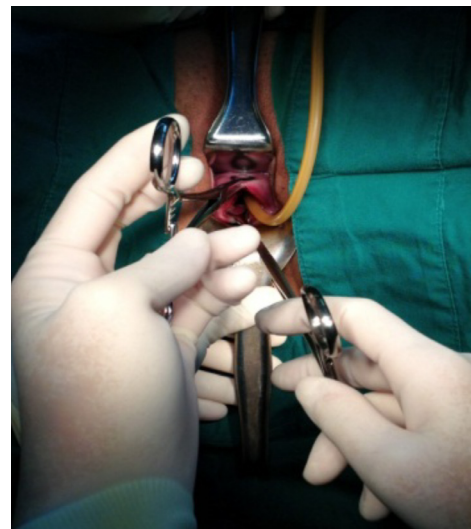


Fig 2. Demonstrated inflated Foleys' catheter inserted into the uterus to maintain the membranes above level of internal os.

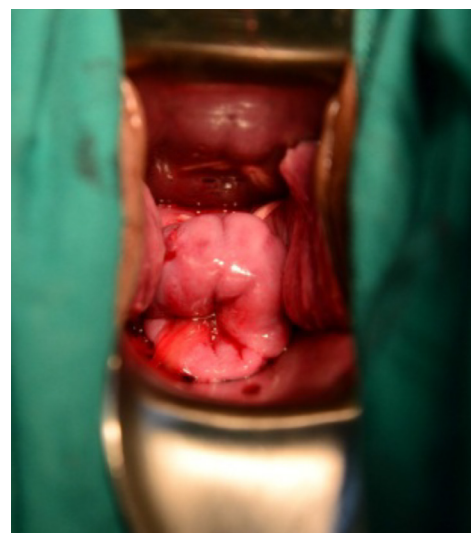


Fig 3. Showed cervix after rescue cerclage procedure.

DISCUSSION

Cervical incompetence or cervical insufficiency is a condition in which the weakness of cervical tissue structure is unable to support and maintain the pregnancy to term.⁴⁻⁶ This usually results in painless cervical dilatation, which is followed by miscarriage in second trimester of gestation or extremely preterm birth. Most of the patients suffer from recurrent second trimester abortion. Cervical cerclage is a treatment of choice for cervical incompetence by increasing cervical strength from the insertion of strong permanent suture material into cervical tissue.⁷⁻⁹ The majority of cerclage procedures are performed electively before the onset of cervical shortening and dilatation in the patients with history of cervical incompetence (History-indicated cerclage) or patients with shortening of the cervix from transvaginal sonography measurement (Ultrasound-indicated cerclage).¹⁰⁻¹² The cerclage procedures in the two groups of patients are usually performed electively in early second trimester up to 24 weeks of gestation with very high success rate (85-90%) and low complication rate.¹²⁻¹⁵

Unfortunately, in patients with advanced cervical dilatation and bulging membranes in second trimester of gestation, cervical cerclage procedure is still controversial due to technical difficulty, poor success rate and poor pregnancy outcomes.^{5,16,17} However, without any intervention, pregnancy loss is inevitable. Emergency cervical cerclage in this situation, referred to rescue or heroic cerclage could prolong pregnancy to reach viable gestation with success rate varied from 12.5 to 63%. High failure rates have been reported if cervical dilatation was more than 4 centimeters and 80% effacement.^{2,3,16,18}

According to the report data, the most important initial step for managing a patient with advanced cervical dilatation in second trimester is detailed counseling to the patient, her couple and her relatives about the procedure, success rate, risk of complications and pregnancy loss. The immediate complications included ruptured membranes during or after procedure, infection and premature contraction which all lead to pregnancy loss. Moreover, the risk of consequent fetal

brain injury and risk of extending pregnancy to severe prematurity should be discussed.^{2,16} The decision for rescue cerclage should be made in a short period because the delay of procedure may increase infection rate from prolonged exposure of the bulging membranes to vaginal microorganism and also increased risk of cerclage failure. There has been insufficient evidence that amniocentesis before rescue cerclage for subclinical chorioamnionitis detection improved the outcomes.^{19,20}

The most important technique of rescue cervical cerclage in the patient with advanced cervical dilatation and bulging membranes was an attempt to push up the membranes back to the uterus above the level of internal os. Gentle pressure with sponge holder with small gauze with deep Trendelenburg position of the patient could achieve this goal, and then the cervical edges were clearly exposed and grasped. The 30 milliliter inflated balloon Foley's catheter was inserted into the uterus to maintain the membranes above the internal os.^{1,2,16,21} The permanent suture was safely inserted around the cervix by McDonald technique thereafter without any risk of membranes rupture caused by needle puncture. Foley's catheter was deflated and the balloon removed after the knot was tightened.

Intraoperative and postoperative tocolytic was administered to reduce intrauterine pressure during operation and to suppress subsequent uterine contraction. NSAIDs was given for reducing inflammatory process which also caused premature uterine contraction. Intravenous antibiotic prophylaxis was given intraoperative and 24 hours postoperative. There has been no evidence to support routine progesterone supplementation in the patients' who undergo cervical cerclage. Life style intervention such as cessation of work, abstinence from coitus, limited activity or absolute bed rest have not been adequately evaluated in any studies, but the patient was advised not to have sexual intercourse due to her advanced degree of cervical dilatation.^{5,7,12}

Timing for removal of the cerclage should be between 36th and 37th weeks of gestation before onset of spontaneous labor. Unless elective cesarean section was scheduled, cerclage removal could be delayed until that time. If the patient had

preterm labor and the delivery was inevitable, the cerclage should be removed to reduce cervical trauma.^{5,7,12}

CONCLUSION

Management of patient with advanced cervical dilatation and bulging membranes is controversial and challenges all obstetricians. Without any intervention, miscarriage is inevitable. Rescue cervical cerclage is the only treatment option in this difficult situation. This case report demonstrated the detailed techniques of rescue cerclage in the patient with severe degree of cervical incompetence with successful results.

REFERENCES

- Cockwell HA, Smith GN. Cervical incompetence and the role of emergency cerclage. *J Obstet Gynaecol Can* 2005;27: 123-9.
- Liddiard A, Bhattacharya S, Crichton L. Elective and emergency cervical cerclage and immediate pregnancy outcomes: a retrospective observational study. *JRSM Short Rep* 2011; 2:91.
- Ventolini G, Genrich TJ, Roth J, Neiger R. Pregnancy outcome after placement of 'rescue' Shirodkar cerclage. *J Perinatol* 2009;29:276-9.
- Woodring TC, Klauser CK, Cromartie DA, Magann EF, Chauhan SP, Morrison JC. When is a cerclage indicated for cervical insufficiency? A literature review. *J Miss State Med Assoc* 2006;47:264-6.
- Ressel GW, Acog. ACOG releases bulletin on managing cervical insufficiency. *Am Fam Physician* 2004;69:436-9.
- Lotgering FK. Clinical aspects of cervical insufficiency. *BMC Pregnancy Childbirth* 2007;7 (Suppl 1):S17.
- Harger JH. Cerclage and cervical insufficiency: an evidence-based analysis. *Obstet Gynecol* 2002;100:1313-27.
- Harger JH. Cervical cerclage: patient selection, morbidity, and success rates. *Clin Perinatol* 1983;10:321-41.
- Abenhaim HA, Tulandi T. Cervical insufficiency: re-evaluating the prophylactic cervical cerclage. *J Matern Fetal Neonatal Med* 2009;22:510-6.
- Blikman MJ, Le TM, Bruinse HW, van der Heijden GJ. Ultrasound-predicated versus history-predicated cerclage in women at risk of cervical insufficiency: a systematic review. *Obstet Gynecol Surv* 2008;63:803-12.
- Fuchs F, Bouyer J, Fernandez H, Gervaise A, Frydman R, Senat MV. Ultrasound cervical length measurement for prediction of delivery before 32 weeks in women with emergency cerclage for cervical insufficiency. *Int J Gynaecol Obstet* 2010;110:245-8.
- Rutanen EM. Cerclage in cervical insufficiency: when and to whom? *Acta Obstetrica et Gynecologica Scandinavica* 2007;86:387-8.
- Rust OA, Atlas RO, Jones KJ, Benham BN, Balducci J. A randomized trial of cerclage versus no cerclage among patients with ultrasonographically detected second-trimester preterm dilatation of the internal os. *Am J Obstet Gynecol* 2000;183:830-5.
- Harger JH. Comparison of success and morbidity in cervical cerclage procedures. *Obstet Gynecol* 1980;56:543-8.
- Harger JH. Effectiveness of cervical cerclage. *Am J Obstet Gynecol* 1984;148:834.
- Namouz S, Porat S, Okun N, Windrim R, Farine D. Emergency cerclage: literature review. *Obstet Gynecol Surv* 2013;68: 379-88.
- O'Brien JM. Management of cervical insufficiency and bulging fetal membranes. *Obstet Gynecol* 2006;107:1421-2.
- Fortner KB, Fitzpatrick CB, Grotegut CA, Swamy GK, Murtha AP, Heine RP, et al. Cervical dilation as a predictor of pregnancy outcome following emergency cerclage. *The journal of maternal-fetal & neonatal medicine : the official journal of the European Association of Perinatal Medicine, the Federation of Asia and Oceania Perinatal Societies, the International Society of Perinatal Obstet*, 2012; 25:1884-8.
- Bujold E, Morency AM, Rallu F, Ferland S, Tetu A, Duperron L, et al. Bacteriology of amniotic fluid in women with suspected cervical insufficiency. *Journal of obstetrics and gynaecology Canada : JOGC = Journal d'obstetrique et gynecologie du Canada : JOGC*. 2008;30:882-7.
- Mays JK, Figueroa R, Shah J, Khakoo H, Kaminsky S, Tejani N. Amniocentesis for selection before rescue cerclage. *Obstet Gynecol* 2000;95:652-5.
- Daskalakis G, Papantoniou N, Mesogitis S, Antsaklis A. Management of cervical insufficiency and bulging fetal membranes. *Obstet Gynecol* 2006;107(2 Pt 1):221-6.